

Paternal mutation of the sulfonylurea receptor (SUR1) gene and maternal loss of 11p15 imprinted genes lead to persistent hyperinsulinism in focal adenomatous hyperplasia.

V Verkarre, J C Fournet, P de Lonlay, M S Gross-Morand, M Devillers, J Rahier, F Brunelle, J J Robert, C Nihoul-Fékété, J M Saudubray, C Junien

J Clin Invest. 1998;**102**(7):1286-1291. <https://doi.org/10.1172/JCI4495>.

Research Article

Congenital hyperinsulinism, or persistent hyperinsulinemic hypoglycemia of infancy (PHHI), is a glucose metabolism disorder characterized by unregulated secretion of insulin and profound hypoglycemia. From a morphological standpoint, there are two types of histopathological lesions, a focal adenomatous hyperplasia of islet cells of the pancreas in approximately 30% of operated sporadic cases, and a diffuse form. In sporadic focal forms, specific losses of maternal alleles (LOH) of the imprinted chromosomal region 11p15, restricted to the hyperplastic area of the pancreas, were observed. Similar mechanisms are observed in embryonal tumors and in the Beckwith-Wiedemann syndrome (BWS), also associated with neonatal but transient hyperinsulinism. However, this region also contains the sulfonylurea receptor (SUR1) gene and the inward rectifying potassium channel subunit (KIR6.2) gene, involved in recessive familial forms of PHHI, but not known to be imprinted. Although the parental bias in loss of maternal alleles did not argue in favor of their direct involvement, the LOH may also unmask a recessive mutation leading to persistent hyperinsulinism. We now report somatic reduction to hemizygosity or homozygosity of a paternal SUR1 constitutional heterozygous mutation in four patients with a focal form of PHHI. Thus, this somatic event which leads both to beta cell proliferation and to hyperinsulinism can be considered as the somatic equivalent, restricted to a microscopic focal lesion, of constitutional uniparental disomy associated [...]

Find the latest version:

<https://jci.me/4495/pdf>



Paternal Mutation of the Sulfonylurea Receptor (SUR1) Gene and Maternal Loss of 11p15 Imprinted Genes Lead to Persistent Hyperinsulinism in Focal Adenomatous Hyperplasia

Virginie Verkarre,*† Jean-Christophe Fournet,** Pascale de Lonlay,*§ Marie-Sylvie Gross-Morand,* Martine Devillers,* Jacques Rahier,** Francis Brunelle,|| Jean-Jacques Robert,§ Claire Nihoul-Fékété,¶ Jean-Marie Saudubray,§ and Claudine Junien*

*INSERM UR 383, †Department of Pathology, §Department of Pediatrics, ||Department of Radiology, ¶Department of Surgery, Hôpital Necker-Enfants Malades, University Paris V, 75743 Paris Cedex 15, France; and **Department of Pathology, University Hospital St-Luc of Louvain, Brussels, Belgium

Abstract

Congenital hyperinsulinism, or persistent hyperinsulinemic hypoglycemia of infancy (PHHI), is a glucose metabolism disorder characterized by unregulated secretion of insulin and profound hypoglycemia. From a morphological standpoint, there are two types of histopathological lesions, a focal adenomatous hyperplasia of islet cells of the pancreas in ~ 30% of operated sporadic cases, and a diffuse form. In sporadic focal forms, specific losses of maternal alleles (LOH) of the imprinted chromosomal region 11p15, restricted to the hyperplastic area of the pancreas, were observed. Similar mechanisms are observed in embryonal tumors and in the Beckwith-Wiedemann syndrome (BWS), also associated with neonatal but transient hyperinsulinism. However, this region also contains the sulfonylurea receptor (SUR1) gene and the inward rectifying potassium channel subunit (KIR6.2) gene, involved in recessive familial forms of PHHI, but not known to be imprinted. Although the parental bias in loss of maternal alleles did not argue in favor of their direct involvement, the LOH may also unmask a recessive mutation leading to persistent hyperinsulinism. We now report somatic reduction to hemizyosity or homozygosity of a paternal SUR1 constitutional heterozygous mutation in four patients with a focal form of PHHI. Thus, this somatic event which leads both to β cell proliferation and to hyperinsulinism can be considered as the somatic equivalent, restricted to a microscopic focal lesion, of constitutional uniparental disomy associated with unmasking of a heterozygous parental mutation leading to a somatic recessive disorder. (*J. Clin. Invest.* 1998. 102:1286–1291.) Key

words: K^+ ATP channel • persistent hyperinsulinism • Beckwith-Wiedemann syndrome • neonatal hypoglycemia • loss of alleles

Introduction

Persistent hyperinsulinemic hypoglycemia of infancy (PHHI)¹ (OMIM 256450) or congenital hyperinsulinism is a glucose metabolism disorder characterized by unregulated secretion of insulin and profound hypoglycemia. The incidence of PHHI in the general population is 1:50,000 live births (1, 2) in which 95% of the cases are sporadic. The incidence for inbred populations, where most of the familial cases are present, is 1:2,500 (3). Treatment of patients with diazoxide and/or somatostatin analogues is not always effective, necessitating an intervention such as pancreatectomy (4). Rare familial forms may be caused by recessive or dominant defects in four different genes: the high-affinity sulfonylurea receptor (SUR1) gene (5–7); the inward rectifying potassium channel subunit (KIR6.2) gene (8, 9); the glutamate dehydrogenase-1 gene (GUD1) (10); and the glucokinase gene (GK) (11). Two types of histopathological lesions are associated with PHHI: a focal form, FoPHHI, and a diffuse form, DiPHHI (12–15). FoPHHI, which represents ~ 30% of operated cases (16), is characterized by focal hyperplasia of islet-like cells, including hypertrophied insulin cells with giant nuclei. In DiPHHI, all the islets of Langerhans throughout the pancreas are irregular in size and contain distinctly hypertrophied insulin cells. These two forms can be distinguished by pancreatic venous sampling (17). Per-operative extemporaneous histological examination is performed to determine whether subtotal or partial pancreatectomy is required (15).

We have shown previously that focal hyperplasia of islet-like cell clusters is clonal in origin. In 10 out of 10 cases of FoPHHI examined, we detected a specific loss of maternal alleles (loss of heterozygosity; LOH) in the p15 region of chromosome 11 (18). The minimal region of LOH in FoPHHI patients is between markers D11S922 in 11pter to D11S921 in

Address correspondence to Claudine Junien, INSERM UR 383, Hôpital Necker-Enfants Malades, Clinique Maurice Lamy, 149, rue de Sèvres, 75743 Paris Cedex 15, France. Phone: 33-1-44-49-44-84; FAX: 33-1-47-83-32-06; E-mail: junien@ceylan.necker.fr

Received for publication 7 July 1998 and accepted in revised form 25 August 1998.

J. Clin. Invest.

© The American Society for Clinical Investigation, Inc.

0021-9738/98/10/1286/06 \$2.00

Volume 102, Number 7, October 1998, 1286–1291

http://www.jci.org

1. *Abbreviations used in this paper:* BWS, Beckwith-Wiedemann syndrome; DiPHHI, diffuse form of PHHI; FoPHHI, focal form of PHHI; HI, hyperinsulinemia; KIR6.2, inward rectifying potassium channel subunit; LOH, loss of heterozygosity; NBF2, nucleotide binding fold 2; PHHI, persistent hyperinsulinemic hypoglycemia of infancy; PKD, polycystic kidney disease; SUR1, high-affinity sulfonylurea receptor 1.

11p15.1 (18). This region includes two clusters of candidate genes. The first cluster corresponds to the 11p15.5 region involved in the Beckwith-Wiedemann syndrome (BWS) which contains an imprinted domain including several imprinted genes, characterized by monoallelic expression (19–22). The maternal LOH at 11p15 associated with FoPHHI involves the loss of a maternally expressed allele of either one or both of the candidate tumor suppressor genes encoding H19 (23) and p57KIP2 (24) and possibly the duplication of the paternally expressed IGF2 gene coding for the growth factor insulin-like growth factor II (25). Similar mechanisms are observed in embryonal tumors (26) and in the BWS which is also associated with neonatal but transient hyperinsulinism (27). The second cluster of genes in 11p15.1 includes the SUR1 gene (28) and the KIR6.2 gene that code for the two subunits of the β cell K^{+}_{ATP} channel (29). Recessive mutations in these genes were identified in familial forms of PHHI (5, 8, 9, 30, 31). Although the parental bias in loss of maternal alleles in FoPHHI did not argue in favor of the direct involvement of the SUR1 and KIR6.2 genes not known to be imprinted, the somatic loss of the 11p15 region could lead to reduction to hemi- or homozygosity of a paternal mutation in either one of these genes.

To understand whether the LOH may also unmask a recessive phenotype responsible for hypersecretion of insulin we looked for deleterious mutations in the SUR1 gene. We found that four FoPHHI patients were constitutionally heterozygous for three new missense mutations in the paternal allele of the SUR1 gene when examined from leukocyte samples and samples taken from pancreas. In all four cases the mutation was also found in leukocyte DNA from their respective fathers. In the hyperplastic cells, because of the maternal allelic loss of the 11p15 region, reduction to hemizygosity or to homozygosity of the inherited paternal SUR1 mutation was observed. Therefore, these data describe the first example of a one-event two-hit mechanism, i.e., a somatic event resulting in both focal hyperplasia and limited hypersecretion of insulin due to loss of functional K^{+}_{ATP} channels.

Methods

Clinical data. Among the 12 patients studied, 10 (Fo1 to Fo10) have been described previously (18) and 2 patients (Fo11 and Fo12) are newly reported. No familial history of hyperinsulinemic hypoglycemia was found. All patients had a neonatal PHHI onset (revealed within 72 h of birth), except patient Fo11 who was diagnosed at 2.5 mo. Both were resistant to diazoxide and underwent partial pancreatectomy. A complete relief of hyperinsulinemic hypoglycemia was obtained and the postoperative plasma glucose levels were strictly normal after a mean follow-up of 33.4 mo (21–45 mo) after surgery.

Tissue samples. Histological diagnosis of focal adenomatous hyperplasia was performed on extemporaneous frozen sections as described (15) and further confirmed after fixation and paraffin embedding. The focal lesion of PHHI is a limited adenomatous hyperplasia of islet cells which consists of an agglomerate of apparently normal well-defined islets surrounded by exocrine elements (ductal and acinar cells) (Fig. 1 A) and including hypertrophied endocrine cells with giant nuclei (32). Outside the lesion, the pancreatic parenchyma is morphologically normal; the islets have a normal size and have a resting appearance with normal nuclear size, no anisokaryosis, and no cellular hypertrophy (15). Pancreatic samples from normal pancreas and from carefully identified focal adenomatous hyperplasia were frozen in liquid nitrogen and stored at -80°C . DNA from the lesion was extracted as previously described (33).

PCR analysis for LOH. The PCR analyses for LOH were per-

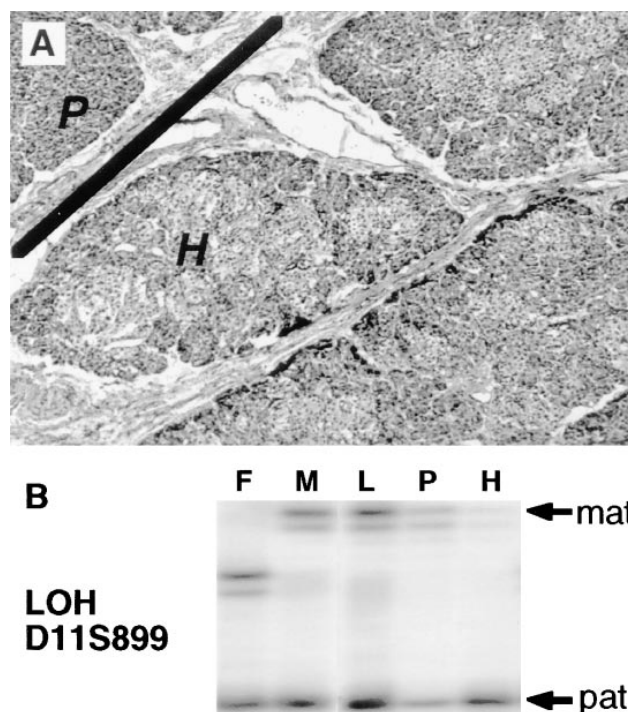


Figure 1. Focal adenomatous hyperplasia with loss of maternal 11p15 alleles. (A) Histopathological findings in patient Fo11. Focal adenomatous hyperplasia (H) of islet cells as shown below the line (hematein and eosin, $\times 40$). Outside the lesion, above the line, the pancreatic (P) parenchyma is morphologically normal. (B) Maternal origin of 11p15 allelic loss in focal hyperplasia. Leukocytes (L), normal pancreas (P), and pancreatic hyperplasia (H) samples were analyzed and compared with leukocyte DNA of the father (F) and the mother (M). In the DNA from the adenomatous hyperplasia sample (H) from patient Fo11, almost complete loss of the maternal allele is observed with marker D11S899 which detects partial maternal LOH.

formed as described previously (18) and the markers D11S922, D11S909, D11S1307, D11S921, D11S899, D11S1324, D11S1360, D11S987, D11S1325, and D11S912 (34) were used to genotype paired samples of DNA extracted from frozen samples of normal pancreas and hyperplastic islet cells, and leukocytes of patients and their parents.

PCR-SSCP and sequence analysis. PCR primer pairs used to amplify exons 33, 34, 35, 36, 37, and 38 coding the NBF2 (nucleotide binding fold 2) domain of the SUR1 gene have been described previously (5). PCR and SSCP analyses were performed using a modified protocol (35). Samples that contained aberrantly migrating fragments were directly sequenced as described (35).

Results

Loss of 11p maternal alleles in focal adenomatous hyperplasia. Using several polymorphic markers, losses of maternal alleles of the 11p15 chromosomal region were found limited to the hyperplastic lesion in 12 patients with focal adenomatous hyperplasia. 10 patients (Fo1 to Fo10) have been published previously (18) and 2 patients, Fo11 (Fig. 1 B) and Fo12 (data not shown), are newly described.

Detection of heterozygous mutations in the SUR1 paternal allele. Since the most commonly deleted region in focal forms also contains the genes for the two subunits of the β cell K^{+}_{ATP} channel, the SUR1 (28) and the KIR6.2 (29) genes involved in

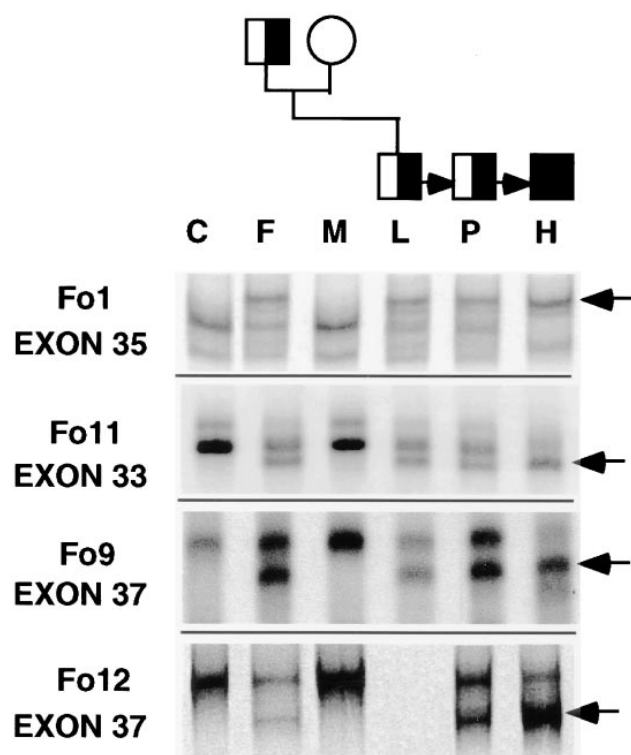


Figure 2. Somatic reduction to hemi- or homozygosity of heterozygous PCR-SSCP patterns of the SUR1 gene in four FoPHHI patients. For each patient, leukocytes (L), normal pancreas sample (P), and pancreatic hyperplasia (H) were analyzed and compared with leukocyte DNA of a control (C), the father (F), and the mother (M). For patients Fo1, Fo11, Fo9, and Fo12, mutations were detected by the presence of a different electrophoretic pattern (→) present in constitutional and hyperplasia samples. The same pattern, i.e., heterozygous in lanes F, L, and P and hemi- or homozygous in lane H, was observed for all four patients, Fo1, Fo9, Fo11, and Fo12 for exons 35, 33, and 37, respectively. Persistence of a faint signal of the wild-type maternal allele in pancreatic hyperplasia (H) can be explained by contamination with stromal or exocrine cells.

recessive familial forms (5, 7–9, 36–38), we looked for deleterious mutations in the SUR1 gene. Since most published mutations were located in the NBF2 domain, we studied the six exons coding for this domain (exons 33–38). As shown in Fig. 2, using SSCP analysis we detected a mobility shift by electrophoresis in constitutional DNA from leukocytes (L) samples and from normal pancreas (P) samples from 4 out of 12 patients, Fo1, Fo9, Fo11, and Fo12. In all four cases the mobility shift was also found in leukocyte DNA from their respective fathers (F). In agreement with the loss of maternal alleles, the signal of the mutant band inherited from the father was enhanced in the DNA from the hyperplastic lesion (H) while the signal of the normal wild-type band inherited from the mother was greatly diminished. The same pattern was observed for all four patients, Fo1, Fo9, Fo11, and Fo12 for exons 35, 33, and 37, respectively (Fig. 2).

Characterization of the SUR1 gene mutations. Mutations in the SUR1 gene displaying such band shifts were identified by nucleotide sequence analysis of PCR products amplified in independent reactions from leukocyte DNA samples (Fig. 3). All four patients were constitutionally heterozygous for three

Table I. Mutations in the NBF2 Domain of the SUR1 Gene

| Patients | Region | Nucleotide substitution | Codon | Amino acid substitution | Mutation |
|--------------|---------|-------------------------|-------|-------------------------|----------|
| Fo11 | Exon 33 | nt 4058 G→C | 1353 | Arg→Pro | R1353P |
| Fo1 | Exon 35 | nt 4261 C→T | 1421 | Arg→Cys | R1421C |
| Fo9 and Fo12 | Exon 37 | nt 4480 C→T | 1494 | Arg→Try | R1494W |

Nucleotide and codon positions are according to the full-length human SUR1 cDNA sequence incorporating the alternative splice form of exon 17 (GenBank accession No. L78208 and L78224).

new missense mutations (Table I). In all four cases, the father was also constitutionally heterozygous for the same mutation found in the proband (Fig. 3 and data not shown). 212 chromosomes from a population of 106 unrelated individuals were tested for the presence of these newly described mutations. In this population and in other individuals reported in the literature (5–8) no such missense mutations were detected, precluding a polymorphism. Furthermore, in all four cases an arginine, a basic amino acid, was replaced by a nonpolar amino acid such as proline (1353), cysteine (1421), or tryptophan (1494), increasing the likelihood that the mutation would result in a change in the protein conformation. Finally, comparison of homologous sequences of five different members of the ATP-binding cassette protein superfamily, the cystic fibrosis transmembrane conductance regulator gene (CFTR, GenBank accession No. M28668), the multidrug resistance associated protein gene (MRP1, No. L05628), the bile canalicular multi-specific organic anion transporter gene (MOAT, No. U63970), the yeast cadmium transporter gene (YCF1, No. L35237), and the P glycoprotein multiple drug resistance 1 (MDR1 No. M14758), revealed that positions 1353, 1421, and 1494 are well-conserved and code for an arginine or another basic amino acid. Taken altogether these data strongly suggest that these missense mutations are deleterious. For the eight remaining patients screening of the remaining exons of the SUR1 gene and of the KIR6.2 gene is underway.

Discussion

We describe for the first time the occurrence of a recessive endocrine disorder which is due to somatic reduction to hemizygosity or homozygosity of a paternally inherited mutation limited to a focal hyperplastic lesion in four patients. In the focal lesion a loss of maternal alleles therefore resulted simultaneously in two different consequences, hyperinsulinemia (HI) and proliferation: the reduction to hemi- or homozygosity of the paternal defective allele of the SUR1 gene with loss of the wild-type maternal allele responsible for hyperinsulinism. HI is the direct consequence of loss of function of the K^+_{ATP} channel as already shown by patch clamp studies (39). In all four cases the father carried the mutant allele therefore excluding the hypothesis of preferential paternal de novo germline mutation. The loss of maternal alleles (18) includes the cluster of imprinted genes in the 11p15.5 region (40) comprising growth factors such as IGF2 (19) and tumor suppressor genes, such as H19 (23) and P57KIP2 (20). This necessarily leads to altered expression of these and other genes in the imprinted domain, suggesting that unbalanced expression of the corresponding gene products may give rise to the increase in proliferation of

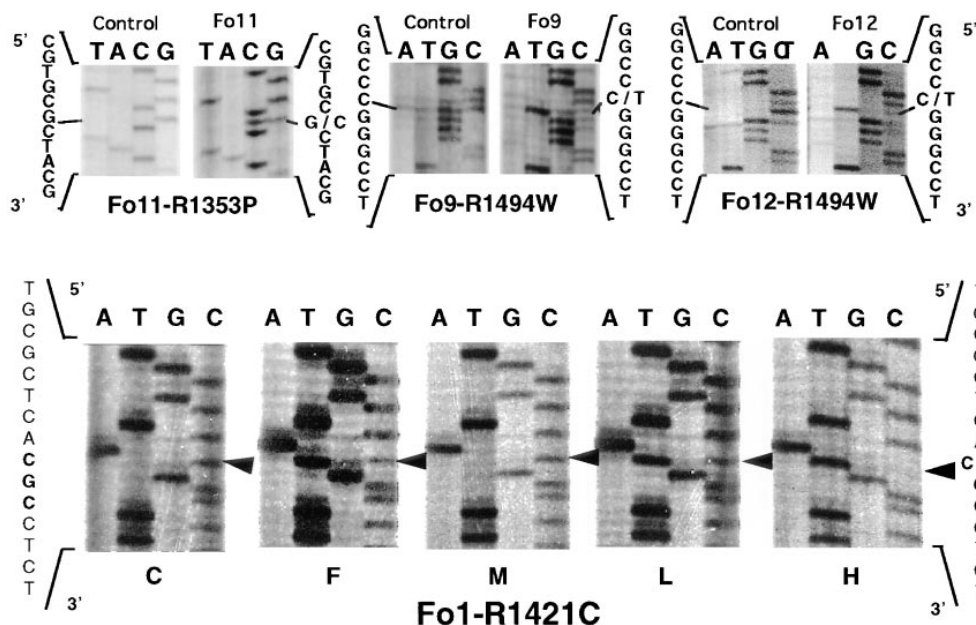


Figure 3. Constitutional missense mutations in the SUR1 gene in four sporadic FoPHHI patients. In patient Fo11, a heterozygous G→C point mutation substitutes an arginine residue for a proline residue at position 1353 in exon 33 (R1353P). In patients Fo9 and Fo12, the sequence revealed the same heterozygous C→T point mutation which substitutes an arginine residue for a tryptophan residue at position 1494 in exon 37 (R1494W). In patient Fo1, a heterozygous transition C→T substitutes an arginine residue for a cysteine residue at position 1421 in exon 35 (R1421C). Leukocytes (L), normal pancreas sample (P), and pancreatic hyperplasia (H) were analyzed and compared with leukocyte DNA of a control (C), the father (F), and the mother (M).

β cells, a striking feature of focal adenomatous hyperplasia, not observed in the diffuse form (32). This altered expression is already well-documented for embryonal tumors, and remarkably in Wilms' tumor (26). However, the transient neonatal HI seen in 50% of BWS patients is in sharp contrast with the severe treatment-resistant HI seen in FoPHHI patients. Thus, HI in BWS, which has never been observed in numerous animal models trying to reproduce the BWS phenotype, remains unexplained (41). Understanding the role of alteration of imprinted genes in HI will require further investigations. Thus, maternal LOH with somatic reduction to homozygosity of the paternal SUR1 mutation can be considered as the somatic equivalent, restricted to this microscopic focal lesion, of constitutional uniparental disomy associated with unmasking of a heterozygous parental mutation leading to a recessive disorder (42). There are several examples of abnormal phenotypes associated with uniparental disomy which can result both from the presence of imprinted genes on the chromosome involved in this non-Mendelian inheritance mechanism and/or from reduction to homozygosity of a mutation associated with an autosomal recessive (42).

In a recent study we report the observation and follow-up of 52 neonates (> 72 h of onset) treated surgically, out of a total of 62 neonatal PHHI patients referred to the Department of Pediatrics (De Lonlay-Debeney, P., F. Poggi-Travert, J. Rahier, C. Sempoux, C.D. Vicci, J.C. Fournet, F. Brunelle, G. Touati, C. Junien, C. Nihoul-Fékété, et al., manuscript submitted for publication). In this series, the minimal proportion of focal cases (22) can be estimated at 35% (22/62). Interestingly, in three other series the percentage of focal forms or so-called "neonatal adenoma" or "focal adenomatosis" was 33%, i.e., 24 cases in a total of 72 patients (4, 12, 16, 43). Thus focal forms represent a significant proportion, one-third, of PHHI cases.

The mechanism involved in FoPHHI is similar to that recently reported for type I autosomal dominant polycystic kidney disease (ADPKD). In PKD, renal cysts are monoclonal and show allelic loss of the unaffected haplotype on chromo-

some 16p13.3 resulting in hemi- or homozygosity for the mutated polycystin allele (44). In PKD the somatic LOH of 16p is a surprisingly frequent event as shown by occurrence of LOH in each cell leading to cyst formation throughout the patient's life (44). In contrast to this recurrent loss of 16p in PKD, the occurrence of LOH necessary for HI to be detectable is probably a rare event. This event must occur in an islet cell at a certain stage, late enough during development since the size of the proliferative lesion only represents a few millimeters (15). Moreover the predominantly neonatal occurrence and the rarity of relapse after partial pancreas resection in 20 cases (De Lonlay-Debeney, P., F. Poggi-Travert, J. Rahier, C. Sempoux, C.D. Vicci, J.C. Fournet, F. Brunelle, G. Touati, C. Junien, C. Nihoul-Fékété, et al., manuscript submitted for publication), after a mean follow-up of 6 yr, precludes a high rate for 11p15 LOH (17, 45). Thus, the window within which the LOH occurs is probably quite narrow during the fetal or neonatal period.

Due to methodological difficulties, the differential diagnosis of these two forms is not widely performed. While the proportion of focal cases may represent about one-third of all neonatal cases, the remaining two-thirds are diffuse cases with either homozygous mutations of SUR1 or KIR6.2 or mutations in other genes such as the glutamate dehydrogenase-1 or other (the only glucokinase mutant described is associated with a milder form) (11). Since heterozygous individuals are more numerous than homozygous individuals, this means that the probability of losing maternal alleles of region 11p15 and of developing focal PHHI is rare. But in countries with a higher prevalence of the disorder, such as Saudi Arabia, it can be assumed that these cases are not so rare and are probably underrecognized. In these countries, an apparently dominant mode of transmission due to the occurrence of a focal form in a heterozygous sibling would remain unmasked because of the high rate of consanguineous mating (> 50%). Moreover this has not been looked at in genetic studies performed on other well-described HI series. In two recent reports there was a strikingly high proportion of supposedly HI chromosomes

(73%) in which the authors failed to detect a mutation after a complete screening of all 39 SUR1 exons and of the one-exon KIR6.2 gene (31, 46). There are several possible explanations, including mutations in untranslated regions of the SUR1 gene for the supposed compound heterozygotes, or mutations in other genes in some of the remaining probands without any detectable mutations. However, linkage analysis in PHHI kindreds did not suggest other localization(s) for the recessive familial forms (36). An additional explanation is that a substantial proportion of their sporadic cases, one-third, are heterozygous for a paternal mutation in either of the two genes SUR1 and KIR6.2 in the chromosomal region 11p15 and lost their maternal wild-type chromosome in their pancreatic lesion.

To define more precisely the risk of occurrence in populations with high consanguinity, but also the risk of recurrence in families with a sporadic case, a systematic search for the mutation in the proband and in relatives would have to be undertaken, together with a retro- or prospective search for focal lesions. An important diagnostic goal is to distinguish patients with focal adenomatous hyperplasia of islet cells from those with the diffuse abnormality because management strategies differ significantly. Medical treatment of patients with diazoxide and/or somatostatin analogues is frequently ineffective, necessitating a 95% pancreatectomy in diffuse forms but only partial pancreatectomy in focal forms, avoiding iatrogenic diabetes (2, 15, 47).

Acknowledgments

We thank Francis Jaubert, Nicole Brousse, Marie-Claire Brusset, Michèle Leborgne, and Myriam Le Strat for their help and contribution to this work.

This work was supported by grants from the "Délégation à la Recherche Clinique, Assistance Publique-Hôpitaux de Paris" (CRC 97 146), INSERM (Contrat Progrès 1998), the Ligue Nationale Contre le Cancer, the Association pour la Recherche contre le Cancer (ARC), the Fondation de France and the Mutuelle Générale de l'Éducation Nationale (MGÉN), and by grant number 3.461593 of the Fondation de Recherche Scientifique et Médicale (FRSM), Brussels. Pascale de Lonlay and Virginie Verkarre were supported by grants from the Evian Foundation and ARC.

References

1. Bruining, G. 1990. Recent advances in hyperinsulinism and the pathogenesis of diabetes mellitus. *Curr. Opin. Pediatr.* 2:758-765.
2. Stanley, C. 1997. Hyperinsulinism in infants and children. *Ped. Clin. N. Am.* 44:363.
3. Mathew, P., J. Young, O. Abu, B. Mulhern, S. Hammoudi, J. Hamdan, and A. Saadi. 1988. Persistent neonatal hyperinsulinism. *Clin. Pediatr.* 27:148-151.
4. Shilyanski, J., S. Fisher, E. Cutz, K. Perlman, and R. Filler. 1997. Is 95% pancreatectomy the procedure of choice for treatment of persistent hyperinsulinemic hypoglycemia of the neonate? *J. Pediatr. Surg.* 32:342-346.
5. Nestorowicz, A., B.A. Wilson, K.P. Schoor, H. Inoue, B. Glaser, H. Landau, C.A. Stanley, P.S. Thornton, J.P. Clement IV, J. Bryan, et al. 1996. Mutations in the sulfonylurea receptor gene are associated with familial hyperinsulinism in Ashkenazi Jews. *Hum. Mol. Genet.* 5:1813-1822.
6. Thomas, P.M., G.J. Cote, N. Wohlk, B. Haddad, P.M. Mathew, W. Rabl, L. Aguilar Bryan, R.F. Gagel, and J. Bryan. 1995. Mutations in the sulfonylurea receptor gene in familial persistent hyperinsulinemic hypoglycemia of infancy. *Science*. 268:426-429.
7. Thomas, P.M., N. Wohlk, E. Huang, U. Kuhnle, W. Rabl, R.F. Gagel, and G.J. Cote. 1996. Inactivation of the first nucleotide-binding fold of the sulfonylurea receptor, and familial persistent hyperinsulinemic hypoglycemia of infancy. *Am. J. Hum. Genet.* 59:510-518.
8. Thomas, P., Y. Ye, and E. Lightner. 1996. Mutation of the pancreatic islet

inward rectifier Kir6.2 also leads to familial persistent hyperinsulinemic hypoglycemia of infancy. *Hum. Mol. Genet.* 5:1809-1812.

9. Nestorowicz, A., N. Inagaki, T. Gono, K. Schoor, B. Wilson, B. Glaser, H. Landau, C. Stanley, P. Thornton, S. Seino, and M. Permutt. 1997. A non-sense mutation in the inward rectifier potassium channel gene, Kir6.2, is associated with familial hyperinsulinism. *Diabetes*. 46:1743-1748.
10. Stanley, C.A., Y.K. Lieu, B. Hsu, A.B. Burlina, C.R. Greenberg, N.J. Hopwood, K. Perlman, B.H. Rich, E. Zammarchi, and M. Poncz. 1998. Hyperinsulinism and hyperammonemia in infants with regulatory mutations of the glutamate dehydrogenase gene. *N. Engl. J. Med.* 338:1352-1357.
11. Glaser, B., P. Kesavan, M. Heyman, E. Davis, A. Cuesta, A. Buchs, C. Stanley, P. Thornton, A. Permutt, F. Matschinsky, and K. Herold. 1998. Familial hyperinsulinism caused by an activating glucokinase mutation. *N. Engl. J. Med.* 338:226-230.
12. Jaffe, R., Y. Hashida, and E. Yunis. 1980. Pancreatic pathology in hyperinsulinemic hypoglycemia of infancy. *Lab. Invest.* 42:356-365.
13. Goossens, A., W. Gepts, J. Saudubray, J. Bonnefont, C. Nihoul-Fékété, P. Heitz, and G. Klöppel. 1989. Diffuse and focal nesidioblastosis. A clinicopathological study of 24 patients with persistent neonatal hyperinsulinemic hypoglycemia. *Am. J. Surg. Pathol.* 13:766-775.
14. Klöppel, G. 1997. Nesidioblastosis. In *Tumors of the Pancreas*. E. Soleia, C. Capella, and G. Klöppel, editors. AFIP, Washington. 238-243.
15. Rahier, J., C. Sempoux, J.-C. Fournet, F. Poggi, F. Brunelle, C. Nihoul-Fékété, J.-M. Saudubray, and F. Jaubert. 1998. Partial or near-total pancreatectomy for persistent neonatal hyperinsulinemic hypoglycemia: the pathologist's role. *Histopathology*. 32:15-19.
16. Filler, R., M. Weinberg, E. Cruz, D. Wesson, and R. Ehrlich. 1991. Current status of pancreatectomy for persistent idiopathic neonatal hypoglycemia due to islet cell dysplasia. *Prog. Pediatr. Surg.* 26:60-75.
17. Dubois, J., F. Brunelle, G. Touati, G. Sebag, C. Nuttin, T. Thach, C. Nihoul-Fékété, J. Rahier, and J. Saudubray. 1995. Hyperinsulinism in children: diagnosis value of pancreatic venous sampling correlated with clinical, pathological and surgical outcome in 25 cases. *Pediatr. Radiol.* 25:512-516.
18. De Lonlay, P., J.-C. Fournet, J. Rahier, M.-S. Gross-Morand, F. Poggi-travers, V. Foussier, J.-P. Bonnefont, M.-C. Brusset, F. Brunelle, J.-J. Robert, et al. 1997. Somatic deletion of the imprinted 11p15 region in sporadic persistent hyperinsulinemic hypoglycemia of infancy is specific of focal adenomatous hyperplasia and endorses partial pancreatectomy. *J. Clin. Invest.* 100:802-807.
19. Giannoukakis, N., C. Deal, J. Paquette, C. Goodyer, and C. Polychronakos. 1993. Parental genomic imprinting of the human IGF2 gene. *Nat. Genet.* 4:98-101.
20. Matsuoka, S., J.S. Thompson, M.C. Edwards, J.M. Barletta, P. Grundy, L.M. Kalikin, J.W. Harper, et al. 1996. Imprinting of the gene encoding a human cyclin-dependent kinase inhibitor, p57KIP2, on chromosome 11p15.5. *Proc. Natl. Acad. Sci. USA*. 93:3026-3030.
21. Hatada, I., J. Inazawa, T. Abe, M. Nakayama, K. Yasuhiko, Y. Jinno, N. Niikawa, S. Ohashi, F. Yoshimutsu, K. Iida, et al. 1996. Genomic imprinting of human p57KIP2 and its reduced expression in Wilms tumors. *Hum. Mol. Genet.* 5:783-788.
22. Zhang, Y., and B. Tycko. 1992. Monoallelic expression of the human H19 gene. *Nat. Genet.* 4:40-44.
23. Hao, Y., T. Crenshaw, T. Moulton, E. Newcomb, and B. Tycko. 1993. Tumour-suppressor activity of H19 RNA. *Nature*. 365:764-767.
24. Matsuoka, S., M. Edwards, C. Bai, S. Parker, P. Zhang, A. Baldini, J. Harper, and S. Elledge. 1995. p57KIP2, a structurally distinct member of the p21CIP1 Cdk inhibitor family, is a candidate tumor suppressor gene. *Genes Dev.* 9:650-662.
25. John, R.M., and M.A. Surani. 1996. Imprinted genes and regulation of gene expression by epigenetic inheritance. *Curr. Opin. Cell Biol.* 8:348-353.
26. Steenman, M., S. Rainier, C. Dobry, P. Grundy, I. Horon, and A. Feinberg. 1994. Loss of imprinting of IGF2 is linked to reduced expression and abnormal methylation of H19 in Wilms' tumour. *Nat. Genet.* 7:433-439.
27. Junien, C. 1992. Beckwith-Wiedemann syndrome, tumorigenesis and imprinting. *Curr. Opin. Genet. Dev.* 2:431-438.
28. Aguilar-Bryan, L., C. Nichols, S. Wechsler, J. Clement, A. Boyd, G. Gonzalez, H. Herrera Sosa, K. Nguy, J. Bryan, and D. Nelson. 1995. Cloning of the beta cell high-affinity sulfonylurea receptor: a regulator of insulin secretion. *Science*. 268:423-426.
29. Inagaki, N., T. Gono, J.P. Clement, N. Namba, J. Inazawa, G. Gonzalez, L. Aguilar-Bryan, S. Seino, and J. Bryan. 1995. Reconstitution of IKATP: an inward rectifier subunit plus the sulfonylurea receptor. *Science*. 270:1166-1170.
30. Thomas, P.M., G.J. Cote, D.M. Hallman, and P.M. Mathew. 1995. Homozygosity mapping, to chromosome 11p, of the gene for familial persistent hyperinsulinemic hypoglycemia of infancy. *Am. J. Hum. Genet.* 56:416-421.
31. Nestorowicz, A., B. Glaser, B.A. Wilson, S.L. Shyng, C.G. Nichols, C.A. Stanley, P.S. Thornton, and M.A. Permutt. 1998. Genetic heterogeneity in familial hyperinsulinism. *Hum. Mol. Genet.* 7:1119-1128.
32. Sempoux, C., Y. Guiot, M.-C. Nolleaux, J.-M. Saudubray, C. Nihoul-Fékété, and J. Rahier. 1998. Pancreatic B-cell proliferation in persistent hyperinsulinemic hypoglycemia of infancy: an immunohistochemical study of 18 cases. *Mod. Pathol.* 11:444-449.

33. Bérout, C., J.-C. Fournet, D. Froger, C. Jeanpierre, D. Droz, Y. Chretien, R. Bouvier, J. Marechal, J. Weissenbach, and C. Junien. 1996. Correlations of allelic imbalance of chromosome 14 with tumor progression and prognostic parameters in renal cell carcinoma. *Genes Chrom. Cancer*. 17:215–224.
34. Weissenbach, J., G. Gyapay, C. Dib, A. Vignal, J. Morissette, P. Millasseau, G. Vaysseix, and M. Lathrop. 1992. A second-generation linkage map of the human genome. *Nature*. 359:794–799.
35. Blanquet, V., C. Turleau, M.-S. Gross-Morand, C. Sénamaud-Beaufort, F. Doz, and C. Besmond. 1995. Spectrum of germline mutations in the RB1 gene: a study of 232 patients with hereditary and non-hereditary retinoblastoma. *Hum. Mol. Genet.* 4:383–388.
36. Glaser, B., K. Chiu, R. Anker, A. Nestorowicz, H. Landau, H. Ben Basat, I.Z. Shloma, N. Kaiser, P. Thornton, and C. Stanley. 1994. Familial hyperinsulinism maps to chromosome 11p14-15.1, 30 cM centromeric to the insulin gene. *Nat. Genet.* 7:185–188.
37. Glaser, B., K. Chiu, L. Liu, R. Anker, A. Nestorowicz, N. Cox, H. Landau, N. Kaiser, P. Thornton, C. Stanley, et al. 1995. Recombinant mapping of the familial hyperinsulinism gene to an 0.8 cM region on chromosome 11p15.1 and demonstration of a founder effect in Ashkenazi Jews. *Hum. Mol. Genet.* 4: 879–886.
38. Thomas, P.M., G.J. Cote, D.M. Hallman, and P.M. Mathew. 1995. Homozygosity mapping, to chromosome 11p, of the gene for familial persistent hyperinsulinemic hypoglycemia of infancy. *Am. J. Hum. Genet.* 56:416–421.
39. Kane, C., R.M. Shepherd, P.E. Squires, P.R.V. Johnson, R.F.L. James, P.J. Milla, A. Aynsley-Green, K.J. Lindley, and M.J. Dunne. 1996. Loss of functional K_{ATP} channels in pancreatic β -cells causes persistent hyperinsulinemic hypoglycemia of infancy. *Nat. Med.* 2:1344–1347.
40. Reik, W., and E. Maher. 1997. Imprinting in clusters: lessons from Beckwith-Wiedemann syndrome. *Trends Genet.* 13:330–337.
41. Hastie, N. 1997. Disomy and disease resolved? *Nature*. 389:785.
42. Ledbetter, D.H., and E. Engel. 1995. Uniparental disomy in humans: development of an imprinting map and its implications for prenatal diagnosis. *Hum. Mol. Genet.* 4:1754–1764.
43. Thomas, C.G., L. Underwood, C. Carney, J.L. Dolcourt, and J.J. Whitt. 1977. Neonatal and infantile hypoglycemia due to insulin excess: new aspects of diagnosis and surgical management. *Ann. Surg.* 185:505–516.
44. Brasier, J., and E. Henske. 1997. Loss of the polycystic kidney disease (PKD1) region of chromosome 16p13 in renal cyst cells supports a loss-of-function model for cyst pathogenesis. *J. Clin. Invest.* 99:194–199.
45. Poggi-Travert, F., J. Rahier, F. Brunelle, C. Fékété, and J.-M. Saudubray. 1994. Hyperinsulinismes de l'enfant: à propos d'une série de 56 cas (1984–1994). In *Journées Parisiennes de Pédiatrie 1994*. Flammarion Médecine-Sciences, Paris. 29–42.
46. Shyng, S.L., T. Ferrigni, J.B. Shepard, A. Nestorowicz, B. Glaser, M.A. Permutt, and C.G. Nichols. 1998. Functional analyses of novel mutations in the sulfonylurea receptor 1 associated with persistent hyperinsulinemic hypoglycemia of infancy. *Diabetes*. 47:1145–1151.
47. Lyonnet, S., J.-P. Bonnefont, J.-M. Saudubray, C. Nihoul-Fékété, and F. Brunelle. 1989. Localization of focal lesion permitting partial pancreatectomy in infants. *Lancet*. II:671.