

A novel phenotype related to partial loss of function mutations of the follicle stimulating hormone receptor.

I Beau, ... , F Kuttenn, M Misrahi

J Clin Invest. 1998;102(7):1352-1359. <https://doi.org/10.1172/JCI3795>.

Research Article

A single natural loss of function mutation of the follicle stimulating hormone receptor (FSHR) has been described to date. Present in the Finnish population it markedly impairs receptor function, blocking follicle development at the primary stage and presenting as primary amenorrhea with atrophic ovaries. When Western European women with this phenotype were examined for FSHR mutations the result was negative, suggesting that other etiologies corresponding to this clinical pattern are markedly more frequent. We now describe a novel phenotype related to mutations provoking a partial loss of function of the FSHR. A woman with secondary amenorrhea had very high plasma gonadotropin concentrations (especially FSH), contrasting with normal sized ovaries and antral follicles up to 5 mm at ultrasonography. Histological and immunohistochemical examination of the ovaries showed normal follicular development up to the small antral stage and a disruption at further stages. The patient was found to carry compound heterozygotic mutations of the FSHR gene: Ile160Thr and Arg573Cys substitutions located, respectively, in the extracellular domain and in the third intracellular loop of the receptor. The mutated receptors, when expressed in COS-7 cells, showed partial functional impairment, consistent with the clinical and histological observations: the first mutation impaired cell surface expression and the second altered signal transduction of the receptor. This observation suggests that a limited FSH effect is sufficient to promote [...]

Find the latest version:

<https://jci.me/3795/pdf>



A Novel Phenotype Related to Partial Loss of Function Mutations of the Follicle Stimulating Hormone Receptor

Isabelle Beau,* Philippe Touraine,‡ Géri Meduri,* Alain Gougeon,§ Agnès Desroches,* Christine Matuchansky,‡ Edwin Milgrom,* Frédérique Kuttent,‡ and Micheline Misrahi*

*INSERM U. 135 Hormones Gènes et Reproduction and Laboratoire d'Endocrinologie et Biologie Moléculaire, Hôpital Bicêtre, Assistance Publique-Hôpitaux de Paris, et Institut Fédératif de Recherche IFR 21, 94275 Le Kremlin Bicêtre, France; ‡Service d'Endocrinologie et Médecine de la Reproduction, Hôpital Necker-Enfants Malades, 75743 Paris Cedex 15, France; and §INSERM U. 407, Faculté de Médecine Lyon-Sud, 69600 Oullins, France

Abstract

A single natural loss of function mutation of the follicle stimulating hormone receptor (FSHR) has been described to date. Present in the Finnish population it markedly impairs receptor function, blocking follicle development at the primary stage and presenting as primary amenorrhea with atrophic ovaries. When Western European women with this phenotype were examined for FSHR mutations the result was negative, suggesting that other etiologies corresponding to this clinical pattern are markedly more frequent.

We now describe a novel phenotype related to mutations provoking a partial loss of function of the FSHR. A woman with secondary amenorrhea had very high plasma gonadotropin concentrations (especially FSH), contrasting with normal sized ovaries and antral follicles up to 5 mm at ultrasonography. Histological and immunohistochemical examination of the ovaries showed normal follicular development up to the small antral stage and a disruption at further stages. The patient was found to carry compound heterozygotic mutations of the FSHR gene: Ile160Thr and Arg573Cys substitutions located, respectively, in the extracellular domain and in the third intracellular loop of the receptor. The mutated receptors, when expressed in COS-7 cells, showed partial functional impairment, consistent with the clinical and histological observations: the first mutation impaired cell surface expression and the second altered signal transduction of the receptor.

This observation suggests that a limited FSH effect is sufficient to promote follicular growth up to the small antral stage. Further development necessitates strong FSH stimulation. The contrast between very high FSH levels and normal sized ovaries with antral follicles may thus be characteristic of such patients. (*J. Clin. Invest.* 1998. 102:1352–1359.) Key words: follicle stimulating hormone receptor • genetic • mutation • premature ovarian failure • infertility

Address correspondence to Dr. M. Misrahi, INSERM U. 135, Hôpital de Bicêtre, 3ème niveau, 78 Rue du Général Leclerc, 94275 Le Kremlin Bicêtre Cedex, France. Phone: 33-1-45-21-33-29; FAX: 33-1-45-21-38-22; E-mail: Micheline.Misrahi@bct.ap-hop-paris.fr

Received for publication 22 April 1998 and accepted in revised form 7 August 1998.

J. Clin. Invest.

© The American Society for Clinical Investigation, Inc.
0021-9738/98/10/1352/08 \$2.00
Volume 102, Number 7, October 1998, 1352–1359
<http://www.jci.org>

Introduction

The gonadotropins follicle stimulating hormone (FSH)¹ and luteinizing hormone (LH) have a central role in the control of follicle growth and function. They act through binding to their cognate receptors belonging to a subgroup of the G protein-coupled receptors (for reviews see references 1 and 2). The particularity of these receptors is to display a large extracellular domain specialized in the binding of the hormone. Genetic defects of the hypothalamo-pituitary-gonadal axis yielding hypogonadism and infertility have been described. At the level of the hypothalamus, Kallmann's syndrome (3, 4) and the recently described mutations in the gonadotropin releasing hormone receptor gene (5, 6) can cause familial hypogonadotropic hypogonadism. At the level of the pituitary, mutations of FSH β (7, 8) or LH β (9) genes have also been detected.

Genetic dysfunctions of gonadotropin receptors have been described. Several cases associated with loss of function mutations of the LH receptor (LHR) have been reported in cases of complete or incomplete male pseudohermaphroditism associated with Leydig cell agenesis or hypoplasia (10–14). Such defects also yield primary amenorrhea in women (12, 15).

In the case of the FSH receptor (FSHR), a single homozygous mutation has been reported to date (Ala189Val) and seems to be very frequent in the Finnish population (16, 17). The patients have a phenotype corresponding to ovarian dysgenesis (primary amenorrhea with streak or hypoplastic ovaries). Histological examination of the ovaries showed follicular development blocked at the stage of primary follicles. After this initial report, several groups have searched for FSHR mutations in patients presenting with ovarian dysgenesis. No mutation was found in German (1), English (18), or French (our unpublished results) patients, suggesting the existence of a very peculiar Finnish isolate. In other populations, non-FSHR-related etiologies of ovarian dysgenesis thus seem to be prevalent.

The phenotype observed in the Finnish patients corresponds to a very marked impairment of FSH function. However, in the case of the thyroid stimulating hormone receptor (TSHR) and LHR, which belong to the same family as the FSHR, or in the case of the gonadotropin releasing hormone receptor, it has been suggested (5) that partial loss of function mutations is more frequent than complete inactivating mutations. Therefore, we searched for patients presenting a phenotype possibly related to such a mutation of the FSHR.

1. *Abbreviations used in this paper:* 3 β -HSD, 3 β -hydroxysteroid dehydrogenase; FSH, follicle stimulating hormone; FSHR, FSH receptor; LH, luteinizing hormone; LHR, LH receptor; P450c17, 17 α hydroxylase cytochrome P450; SHBG, sex hormone binding globulin; TSHR, thyroid stimulating hormone receptor.

In this report, we describe a woman with secondary amenorrhea, very high plasma gonadotropin concentrations (especially FSH), and normal sized ovaries with follicles up to 5 mm at ultrasonography. Histological and immunohistochemical examination of the ovaries showed normal follicular development up to the small antral stage, and a disruption at further stages. The patient was found to carry compound heterozygous mutations of the FSHR gene. The mutated receptors, when expressed in heterologous cells, showed partial functional impairment, consistent with the clinical and histological observations.

Methods

Patient. The proband was 30 yr old. She was the second daughter of two nonconsanguineous parents of Armenian origin, and was unaware of any reproductive anomaly in her family. Her sister (33 yr old) had a 3-yr-old son. Puberty had occurred at 14.5 yr with normal development of secondary sex characteristics. She had oligomenorrhea (three episodes of bleeding per year) for 1.5 yr and then developed amenorrhea at the age of 16.

At the age of 21, she consulted for infertility. Hormonal evaluations revealed high plasma gonadotropin concentrations: FSH: 108 IU/liter (normal: 1.0–9.0 IU), LH: 80.5 IU/liter (normal: 1.4–12 IU/liter), and relatively low estradiol (E2) levels: 20–40 pg/ml (63–126 pmol/liter) (normal: 20–300 pg/ml, 740–1,000 pmol/liter). She was diagnosed as premature menopause and told that her infertility could not be cured. For the next 8 yr she received intermittent treatment with oral estrogen–progestogen combinations which induced cyclical withdrawal bleedings.

The patient's height was 156 cm and her weight was 56 kg. She had normal breast development, normal axillary and pelvic hair, and had no morphotypic abnormalities. Plasma hormone concentrations were determined by radioimmunoassay after 2 yr of treatment withdrawal. Plasma FSH and LH levels were elevated: 126.8 and 43.6 IU/liter, respectively. Plasma estradiol levels were relatively low at 21–40 pg/ml, testosterone was 0.6 ng/ml (2 nmol/liter) (normal: 0.2–0.5 ng/ml, 0.69–1.9 nmol/liter), Δ_4 androstenedione was 1.2 ng/ml (4.2 nmol/liter) (normal: 1.0–1.6 ng/ml 3.5–5.6 nmol/liter), and dehydroepiandrosterone was 3.9 ng/ml (13.6 nmol/liter) (normal 2–12 ng/ml) (6.8–40.8 nmol/liter). Sex hormone binding globulin was normal: 60 nmol/liter (normal range: 47.9±12.9 nmol/liter). The plasma concentration of inhibin B was relatively low: 50 pg/ml (19) in contrast to the very high concentration of plasma FSH. Thyroid function and plasma prolactin concentration were normal. No antithyroid or antiovarian autoantibodies could be detected. The karyotype was 46 XX. A progesterone test (chlormadinone acetate: 10 mg/d administered orally during 10 d) was followed by moderate bleeding lasting 4 d.

Bone mineral density, determined by dual energy x-ray absorptiometry, revealed osteoporosis according to the WHO classification (20): 0.763 g/cm² at the lumbar site (L₁–L₄) and 0.663 g/cm² at the hip site, –2.58 and –2.60 SD, respectively, for the age of the patient.

Pelvic ultrasonography showed a small uterus (45 × 30 × 20 mm). The ovaries were slightly enlarged: 35 × 27 × 17 for the right and 29 × 16 × 14 mm for the left ovary. Numerous follicles up to 5 mm were detected in both ovaries (Fig. 1) and were interspersed throughout the ovaries.

Coelioscopy showed ovaries of an apparently normal size but with a smooth surface without any maturing follicle or corpus luteum. Two biopsies were performed on each ovary. The ovarian biopsies were performed before any stimulation by FSH.

Ovarian stimulation using recombinant FSH (Gonal-F; Serono Laboratories, Boulogne, France) was performed (21) and monitored by estradiol assays and pelvic ultrasonography. An initial dose of 150 IU was given during 5 d. The dosage was then increased by 75 IU every 5 d. A total amount of 5,625 IU was given in 20 d. There was a clear-cut

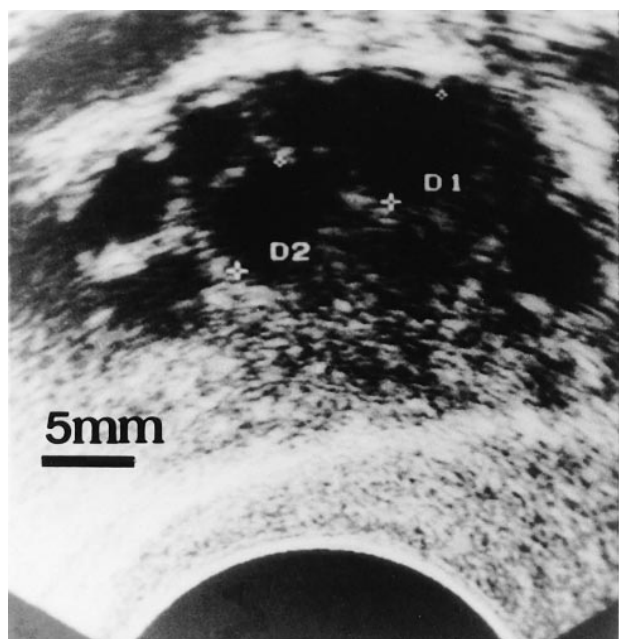


Figure 1. Ultrasonography of the ovaries. Both ovaries exhibited the same sonographic aspect. Note that various follicles of 3–5 mm are seen. A scale (5 mm) is represented. D1 and D2 indicate two of the largest follicles.

but very limited response: plasma estradiol concentrations increased from 20 to 65 pg/ml and the maximal size of the follicles at sonography increased from 5 to 8.3 mm. The parents and the sister agreed to give blood samples for DNA studies but did not wish to undergo clinical investigations. The study was approved by the review boards for human research of the different institutions. Informed consent was obtained from the patient.

DNA sequencing. DNA was extracted from peripheral blood leukocytes. The 10 exons of the human FSHR gene were amplified by PCR and sequenced on both strands using primers described previously (16, 22). Automatic genomic sequencing was performed using a *Taq* dideoxyterminator cycle sequencing kit and a 373 A sequencer (Applied Biosystems, Foster City, CA).

Construction of expression vectors encoding mutated FSHRs. The human FSHR cDNA cloned into the pSG5 expression vector has been described elsewhere (23). The mutations were introduced into the pSG5-FSHR plasmid vector by oligonucleotide-mediated mutagenesis using PCR. The Arg573Cys substitution was engineered with two mutagenic primers: a direct primer A1: GATCGCCAAGT-GCATGGCCAT and a reverse primer B1: CCATGCACTTGGC-GATCCTGG starting, respectively, at positions 1707 and 1724 of the cDNA sequence (+1 corresponds to the first nucleotide of the initiation codon. The mutated base is underlined). Two other primers were used: primer C1: GCTGCTCATTGCATCAGTTGATATCCATAC and primer D1: GAGGGACAAGTATGTAAGTGAACCAC-TGG starting, respectively, at position 1245 and 2036 of the cDNA sequence. A fragment of 821 bp containing the mutation was constructed in two pieces. The first fragment was obtained by PCR using oligonucleotides A1 and D1. The second fragment was obtained using oligonucleotides B1 and C1. The full-length product of 821 bp was obtained by hybridization of the two fragments and PCR amplification using primers C1 and D1. After digestion with *Pf*MI (there are two *Pf*MI sites located, respectively, at 413 and 298 bases away from the mutation) the fragment was ligated into the pSG5-hFSHR vector previously digested with *Pf*MI.

The Ile160Thr substitution was generated using a similar strategy. Two mutagenic primers were used: a direct primer A2: ACATCCA-

CACAACTGAAAGAAATCTTTTCG and a reverse primer B2: GAATTTCTTTTCAGTTGTGTGGATGTTTATG starting at position 467 and 492 of the cDNA sequence, respectively (the mutated base is underlined). The two other primers were C2: GGACCTG-GAGAAAATAGAGATCTCTCAGAA and D2: GACCCCTAGC-CTGAGTCATATAATCAACTT and started at position 210 and 929 of the cDNA sequence, respectively.

The full-length fragment of 719 bp containing the Ile160Thr mutation was digested with AflII and Bsu36I (the restriction sites were located, respectively, 141 bp upstream and 242 bp downstream from the mutation), purified, and ligated to the pSG5-FSHR vector digested with the same restriction enzymes.

All constructs were verified by double-strand sequencing.

Study of FSH binding to the wild-type and mutated receptors. COS-7 cells were transfected using Superfect (QIAGEN Inc., Chatsworth, CA). 48 h later, cells were incubated for 1 h at 30°C with 400,000 cpm/ml of iodinated FSH (sp act 135 μ Ci/ μ g; Amersham, Arlington Heights, IL) as described previously (23) in the absence or in the presence of increasing concentrations of unlabeled recombinant FSH. Nonspecific binding was determined in samples containing an excess (10 μ g/ml) of unlabeled FSH and subtracted from the total binding. All experiments were performed twice in triplicate. Transfection efficiencies were estimated by cotransfecting pRSV- β gal and measuring β -galactosidase activity in the cells. They were in a very similar range when expression vectors encoding either the wild-type or the mutated FSHRs were used.

cAMP assay. cAMP assays were performed as described previously (23) after 45 min of incubation of transfected cells with variable concentrations of FSH (10^{-11} – 10^{-7} M) (Metrodine; Serono Laboratories).

Immunofluorescence and confocal microscopy. Antibody FSHR 323 (23) was used, as described previously (24, 25), to study by indirect immunofluorescence FSHR expression in transfected COS-7 cells. This antibody (5 μ g/ml), which recognizes the receptor ectodomain, was incubated with the cells for 1 h at 4°C in PBS containing 1% BSA. The cells were washed and fixed for 15 min in 3% paraformaldehyde. After saturation with PBS, 1% BSA for 1 h the cells were incubated for 1 h with a Cy3-labeled rabbit anti-mouse

IgG (Sigma Chemical Co., St. Louis, MO). The cells were washed and mounted with a fluorescence mounting medium (DAKO, Santa Barbara, CA).

In some experiments, the cells were fixed with 3% paraformaldehyde in PBS and permeabilized with 0.075% saponin in PBS, 1% BSA (26). The cells were then incubated with antibody FSHR 323 for 2 h at room temperature and further processed as described above.

A Zeiss microscope (Axiovert 135M) was used in conjunction with a confocal laser scanning unit (Zeiss LSM410) (24).

Histological and immunocytochemical studies of the ovaries. One biopsy from each ovary was frozen in liquid nitrogen and preserved at -196° C until use. The two other fragments were fixed in buffered 10% formalin and embedded in paraffin.

Gonadotropin receptors could only be studied on frozen sections. LH and FSHRs were immunolabeled as described (23, 27) using antibodies LHR 29 (10 μ g/ml), LHR 74 (5 μ g/ml), and FSHR 323 (3 μ g/ml). Controls omitting primary or secondary antibodies or using antigen-saturated antibodies have been described (27). Steroidogenic enzymes were studied on frozen sections as described (28). Anti- 3β -hydroxysteroid dehydrogenase (3β -HSD) (dilution 1:6,000) (29), anti- 17α hydroxylase cytochrome P450 (P450c17) (dilution 1:10,000) (30), and anti-aromatase cytochrome P450 (dilution 1:3,000) (31) antibodies were used.

The steroidogenic enzymes were also studied in formol-fixed paraffin-embedded sections. After deparaffinization and antigen retrieval, the same antibodies were used but at a twofold higher concentration (except for anti-P450c17 which was used at 1:6,000 dilution). In all cases, the bound immunoglobulins were revealed with biotinylated secondary antibodies and peroxidase-labeled streptavidin (LSAB2 immunostaining kit; DAKO) according to the manufacturer's instructions.

Endogenous peroxidase inhibition was performed with PBS 3% H_2O_2 (Merck, Darmstadt, Germany) for 5 min. Aminoethylcarbazole (Sigma) was used as a chromogen. The sections were lightly counterstained with Meyer's hematoxylin. Replacement of the specific primary monoclonal antibodies with preimmune mouse immunoglobulins (Sigma) of the same subclass and at the same concentration and

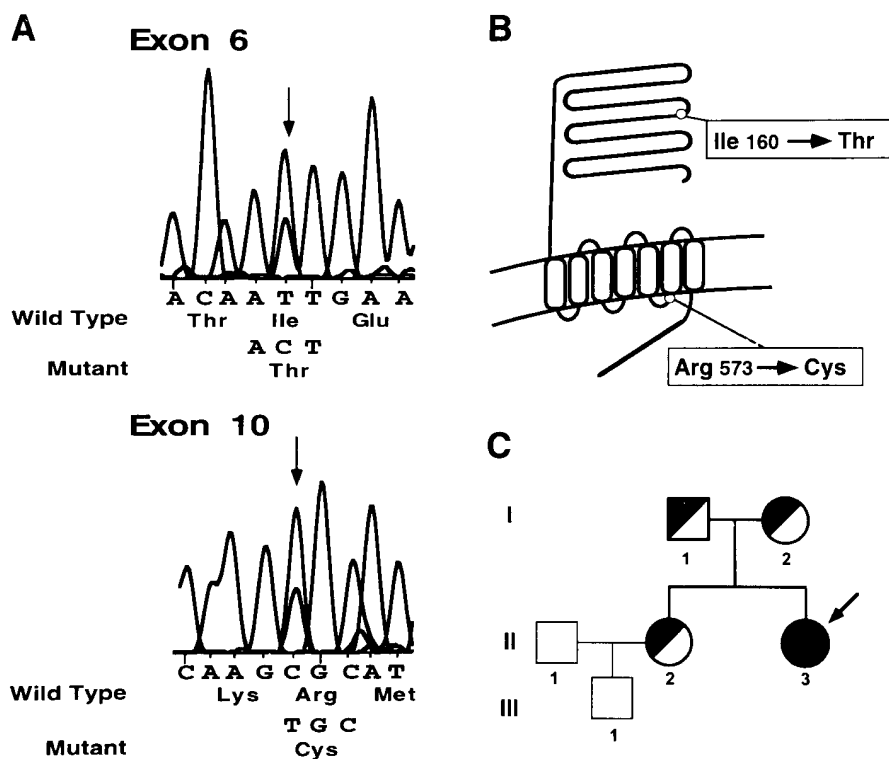


Figure 2. Automatic DNA sequencing (A) and location (B) of the two mutations found in the patient. Pedigree of the family (C). In A the heterozygotic mutations are indicated by arrows. In C the proband is indicated by an arrow. Solid symbols denote affected subjects, half solid symbols denote unaffected heterozygotes, circles denote female family members and squares are male family members. Members of the family who have been studied are represented by bold symbols.

replacement of rabbit antibodies with rabbit immunoglobulins resulted in absence of staining.

Results

Sequencing of the FSHR gene. Sequencing of the complete coding region of the FSHR gene in the patient revealed two transversions (Fig. 2, *A* and *B*) yielding an Ile160Thr substitution in the sixth exon of the receptor (extracellular domain), and an Arg573Cys substitution in the tenth exon of the receptor (third intracellular loop). A control population of 50 subjects did not display these mutated amino acids. The father and the unaffected sister of the patient were heterozygous for the Arg573Cys mutation, while the mother carried only the Ile160Thr mutation (Fig. 2 *C*).

Expression of the mutated receptors. The mutations were engineered in vitro into expression vectors and were used for transient transfections of COS-7 cells.

Binding of ^{125}I -FSH was studied in the presence or the absence of unlabeled FSH. There was a dramatic reduction in FSH binding of the Ile160Thr mutant, whereas the Arg573Cys FSHR mutant bound FSH with an affinity similar to that of the wild-type receptor (Fig. 3 *A*).

COS-7 cells transfected with the expression vectors were incubated with increasing concentrations of FSH and the accumulation of cAMP was measured. The biological activities of both mutated receptors were markedly impaired (Fig. 3 *B*). No stimulation was observed at low concentrations of FSH. At high concentrations of FSH, a limited stimulation of adenylate cyclase was observed for both mutants, the maximal responses being $\sim 30\%$ and $\sim 10\%$ for the Arg573Cys and the Ile160Thr mutants, respectively, when compared with the wild-type receptor.

Cell surface expression of the receptors was then analyzed. The transfected cells were either permeabilized by saponin or not treated and incubated with antireceptor ectodomain antibody (see Methods). Confocal microscopic examination of permeabilized cells showed expression of mutated and wild-type receptors (Fig. 4, *a*, *c*, and *e*). With nonpermeabilized

cells, wild-type receptor and the Arg573Cys mutant (Fig. 4, *b* and *f*) were observed at the cell surface, whereas the expression at the cell membrane of the Ile160Thr mutant was markedly altered, no receptor molecules being detected with this method at the cell surface (Fig. 4 *d*).

Histological and immunocytochemical studies of the ovarian biopsies. The surface epithelium and the ovarian stroma of the patient did not differ from those in normal cyclic ovaries. Primordial, primary, and secondary follicles did not exhibit morphological abnormalities and their density in the ovarian cortex was similar to that observed in ovulating women of the same age (Fig. 5 *A*).

One small antral follicle (~ 0.5 mm) could be examined in detail. It showed a normal granulosa and theca interna which appeared hypertrophic in places. Immunohistochemistry was performed using monoclonal antibodies directed against the LHRs and FSHRs and polyclonal antibodies against steroidogenic enzymes. Immunostaining of $\beta\text{-HSD}$ (Fig. 5 *B*) and P450c17 (Fig. 5 *C*) allowed the delineation of the hypertrophic theca interna. No aromatase cytochrome P450 activity could be detected in the granulosa cells (not shown), which is a normal observation for a follicle of 0.5 mm (31–35).

Immunocytochemical analysis of the FSHR (Fig. 5 *D*) showed strong staining on granulosa cells. This contrasted with the immunostaining of the LHR which was barely visible (Fig. 5 *E*). In normal women, follicles of a similar size exhibited strong LHR immunolabeling of the theca interna (see Fig. 5 *F*).

Several larger antral follicles (~ 2 –5 mm, still corresponding to a small antral stage) were found on the paraffin-embedded sections and they showed a very characteristic staining pattern (Fig. 5, *G* and *H*). The theca interna of these follicles was markedly thickened and consisted of several layers of polygonal cells with a round central nucleus and abundant cytoplasm containing lipid droplets. These cells had the features of luteinized cells. Most of the granulosa cells had disappeared, with only very sparse cells were found in some folds. The latter cells did not express aromatase (not shown). Expression of aromatase in follicles of this size in normal women remains controversial (31–35). Immunocytochemical staining for $\beta\text{-HSD}$ (Fig. 5 *G*)

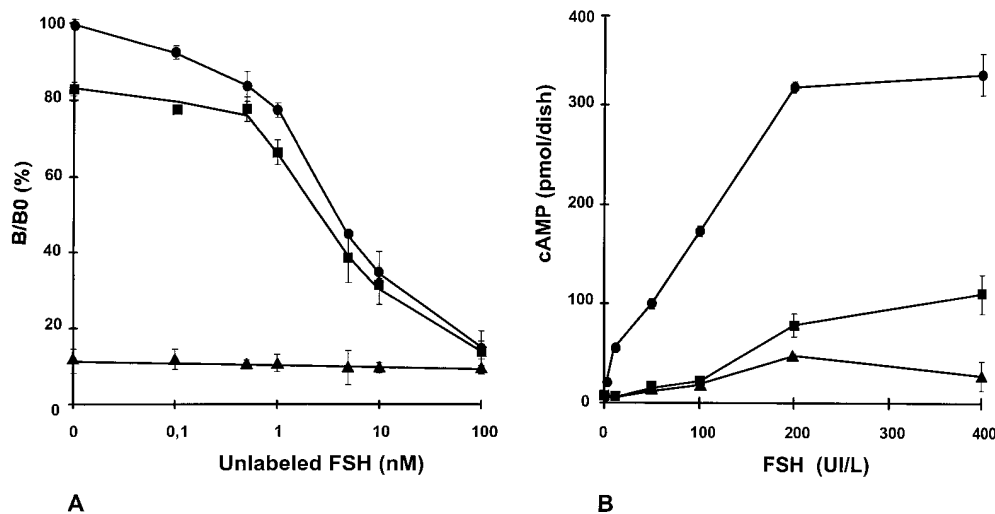


Figure 3. Functional studies of the wild-type and mutant FSHRs. COS-7 cells were transfected with expression vectors encoding wild-type or mutated receptors. *A* shows ligand binding. The cells were incubated with ^{125}I -FSH in the absence or in the presence of increasing concentrations of unlabeled FSH (see Methods). The K_d was 5.4 nM for the wild-type, and 6.7 nM for the Arg573Cys mutant receptors, respectively. Each point represents the mean (\pm SE) of triplicate determinations. Three experiments were performed with similar results and did not show statistically significant differences in the concentrations of

binding sites of wild-type and Arg573Cys mutant. *B* shows FSH-induced cyclase activation of receptors. Transfected cells were incubated for 45 min with increasing concentrations of FSH and the accumulation of cAMP was measured (see Methods). Three experiments were performed with similar results. Circles correspond to the wild-type, squares to the Arg573Cys, and triangles to the Ile160Thr FSHR mutants.

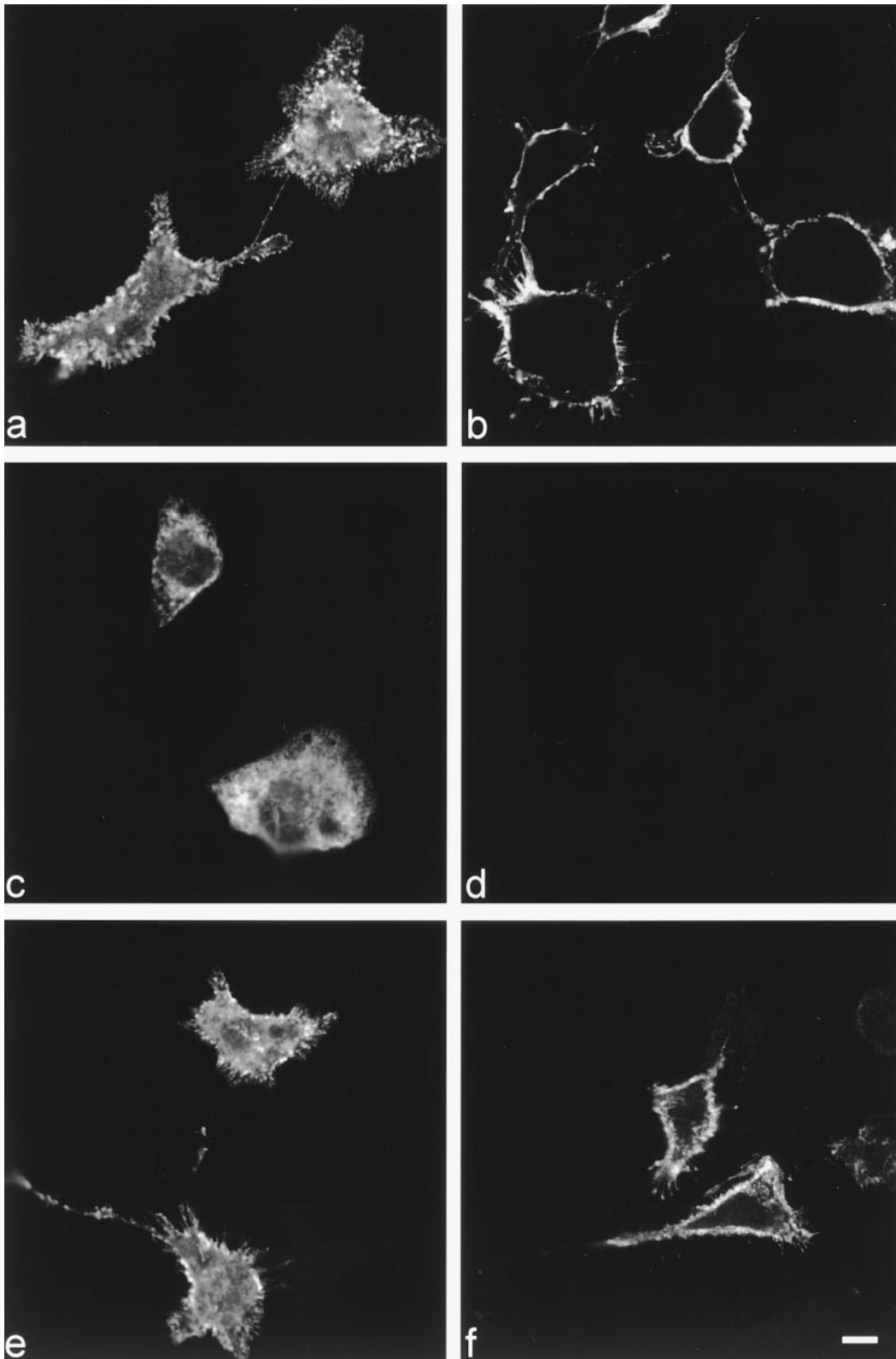


Figure 4. Cell surface expression of wild-type and mutated FSHRs. COS-7 cells were transfected with expression vectors encoding either the wild-type (*a* and *b*) or the mutated Ile160Thr (*c* and *d*) or Arg573Cys (*e* and *f*) receptors. Permeabilized (*a*, *c*, and *e*) or nonpermeabilized (*b*, *d*, and *f*) cells were incubated with the monoclonal FSHR 323 antibody. Confocal microscopy was used to study the cellular distribution of receptors.

and P450c17 (Fig. 5 *H*) confirmed the hypertrophy of the theca interna. A few cells were observed in the periphery of the theca interna which expressed aromatase (not shown). Since follicles of this size were not present in the frozen sections, we could not examine them for FSHR and LHR distribution.

Discussion

We report here the case of a woman who presented secondary amenorrhea associated with high plasma levels of gonadotropins, especially FSH. The particularity in this context was the

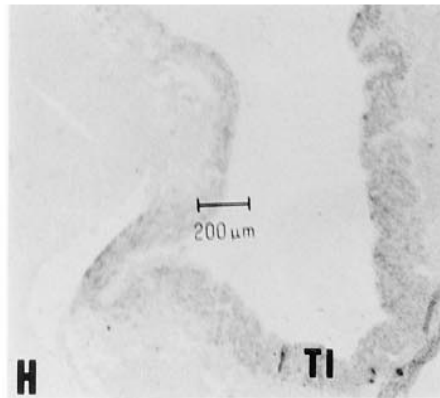
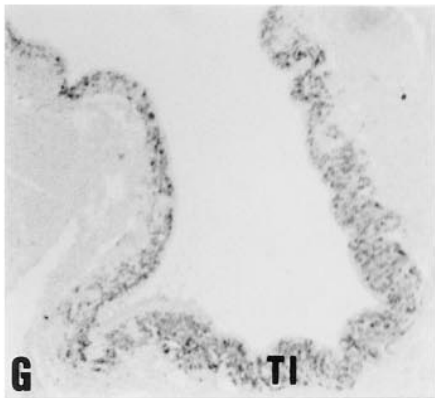
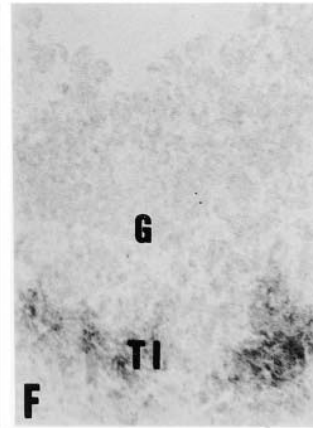
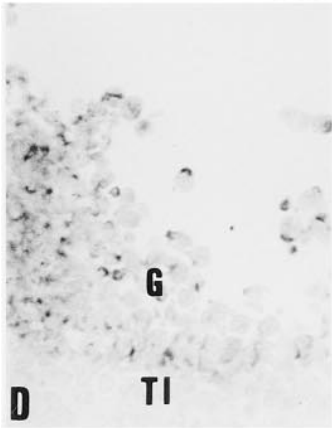
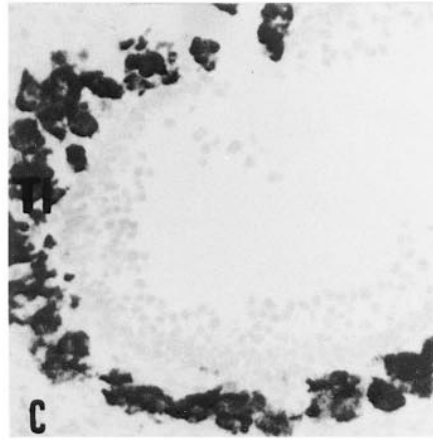
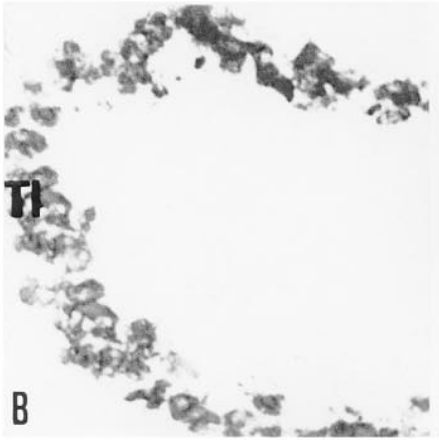
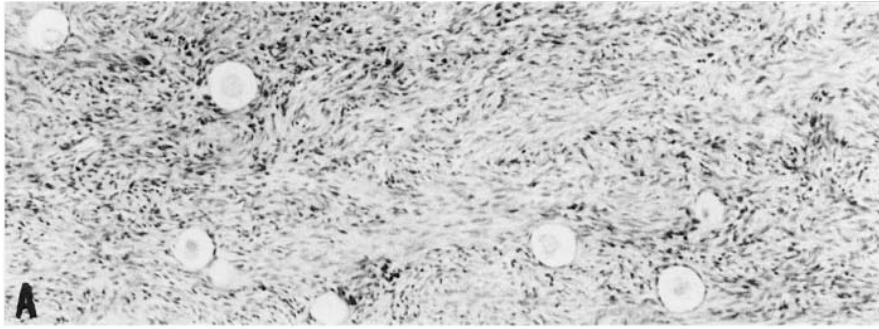


Figure 5. Conventional histology and immunocytochemical study of the ovaries of the patient. (A) Primordial and primary follicles: conventional histology of a section of paraffin-embedded ovarian tissue ($\times 40$). Normal morphology and density of the follicles. (B–E) Small antral follicle (0.6 mm). Frozen sections of the patient’s ovary were immunostained for 3β -HSD (B) ($\times 200$), P450c17 (C) ($\times 200$), FSHR (D) ($\times 400$), and LHR (E) ($\times 400$). As a control we show (F) a frozen section of an ovary obtained from a normal woman (hysterectomy for fibroma). A small antral follicle (0.7 mm) was immunostained with anti-LHR antibodies ($\times 400$). Note in the patient’s ovary the strong labeling of granulosa cells (G) with the anti-FSHR antibody, the very weak staining of some theca interna (TI) cells with the anti-LHR antibody, and the strong staining of a hypertrophied theca interna with anti- 3β -HSD and anti-P450c17 antibodies. In contrast note the strong LHR immunostaining of the control follicle taken from a normal woman. (G and H) Larger antral follicle (~ 2 mm). Sections were immunostained for 3β -HSD (G) and P450c17 (H). This follicle has an hypertrophied theca interna (TI) and a few residual granulosa cells. $\times 70$.

finding of normal sized ovaries and follicular development proceeding up to the small antral stages.

Analysis of the patient’s DNA showed the presence of mutated amino acids in the extracellular domain (Ile160Thr) and

in the third extracellular loop (Arg573Cys) of the FSHR. Hydrophobic (Val or Ile) or positively charged (Arg or Lys) residues are constantly found at these positions in FSHR, LHR, and TSHR of different species, suggesting an important func-

Table I. Mutated Residues in Human FSHR

		160	573
FSHR	human	IHTIERN-----IAKRMAM	
	rat	IHTIARN-----IAKRMAT	
	pig	IHTVERN-----IAKRMAM	
	sheep	IHTVERN-----IAKRMAM	
	bovine	IHTVERN-----IAKRMAM	
LHR	human	ITTIIPGN-----IAKKMAI	
	rat	ITTIIPGN-----IAKKMAI	
	pig	ITTIIPAN-----IAKKMAV	
	mouse	ITTIIPGN-----IAKKMAI	
TSHR	human	MTSIPVN-----IAKRMAV	
	rat	MTSVPEN-----IAKRMAV	
	mouse	MTSVPEN-----IAKRMAV	

Comparison with residues present in FSHR of other species and in LHR or TSHR. FSHR, LHR, and TSHR sequences were obtained from the SWISS PROT library. They were aligned using the MegAlign program and the Clustal Method (DNA Star 3.12). The residues corresponding to FSHR Ile160 and Arg573 are shown. Note the conservation of hydrophobic residues in the former and of basic residues in the latter.

tional role (Table I). The roles of the extracellular domain in hormone binding and of the third extracellular loop in coupling to G proteins for LHRs and TSHRs have been studied (36–38). However, no such studies have been performed to date on the FSHR (1). Furthermore, there was an impaired expression at the cell surface of the Ile160Thr FSHR mutant. Similar alterations of cell trafficking have been described for TSHRs (39), LHRs (40), and FSHRs (16). It may be noted that a mutation at residue 567 provokes constitutive activation of the FSHR (41) while substitution of cysteine for arginine at position 573 impairs Gs coupling.

In the Finnish population, the Ala189Val mutation led to nearly complete alteration of FSHR function. Ovarian histology demonstrated normal development up to primary follicles, confirming that these initial stages are not gonadotropin dependent (16, 17). A similar observation has been made in mice harboring a deletion of the FSH β gene (42). In our patient, who had incomplete alteration of FSHR function, follicular development proceeded up to the stage of a small antrum (5 mm at sonography). This confirms that basal follicular growth requires only moderate FSH action (low but not absent FSH secretion, or residual FSHR function) (34, 35). However, follicular selection and preovulatory development are dependent on more intense FSH stimulation. Due to receptor inadequacy, this could not be achieved in our patient even in the presence of very high concentrations of FSH in blood and probably led to the degeneration of the larger antral follicles with nearly complete disappearance of the granulosa cells and with an absence of aromatase in the few cells which remained. Administration of high doses of exogenous FSH only slightly increased plasma estrogen concentration and follicular size.

Estrogen activity was subnormal in this patient. She had normal levels of sex hormone binding globulin and responded to a progesterone test but her bone density was reduced. The origin of the estrogen is unknown. Estrogen may have been produced by peripheral aromatization of androgens or it may have been secreted by the ovary; some aromatase-containing cells were observed in the outer layers of the theca interna, confirming previous reports (32, 43).

The presence of very high levels of LH contrasted with normal androgens in blood. This was possibly related to the important downregulation of the LHR (2, 28).

In the past, a variety of different phenotypes has been mixed together within the generic term “resistant ovary syndrome” (44, 45). The first phenotype corresponded to hypergonadotropic primary amenorrhea with streak ovaries including primordial follicles. This phenotype corresponds to the Finnish isolate analyzed by Aittomäki et al. (16). However, it also corresponds to other more frequent etiologies than FSHR defects. Indeed, patients with this phenotype have been studied in different countries and no genetic abnormality of the FSHR has been detected outside of Finland (1, 18, and our unpublished results).

Our patient presented a different phenotype: secondary amenorrhea, subnormal estrogenic activity, and normal sized ovaries including numerous follicles with development up to the small antral stages. Patients presenting with similar phenotype have been observed previously (44, 46) but the etiology was unknown. Such cases may not be uncommon since an ultrasonographic study of patients with premature ovarian failure revealed that approximately one-third of them had normal-sized ovaries with follicular development up to 7.2 mm (47).

Indeed, we have detected recently another patient presenting with a similar phenotype. DNA studies showed mutations of the FSHR. This patient is currently under study. It may be important to distinguish such cases from other syndromes such as premature menopause (which was the initial diagnosis for our patient), since the presence of ovarian follicles in these patients may allow the treatment of their infertility in the future (44, 48).

Acknowledgments

We thank Serono Laboratories for providing recombinant FSH (Gonal-F) and P. Leclerc (Service commun de microscopie confocale, IFR21) for his help in confocal microscopy analysis.

References

1. Simoni, M., J. Gromoll, and E. Nieschlag. 1997. The follicle-stimulating hormone receptor: biochemistry, molecular biology, physiology, and pathophysiology. *Endocr. Rev.* 18:739–773.
2. Misrahi, M., M.T. Vu Hai, N. Ghinea, H. Loosfelt, G. Meduri, M. Atger, A. Jolivet, B. Gross, J.F. Savouret, P. Dessen, and E. Milgrom. 1993. Molecular and cellular biology of gonadotropin receptors. In *The Ovary*. E.Y. Adashi and C.K. Leung, editors. Raven Press, New York. 57–92.
3. Bick, D., B. Franco, R.J. Sherins, B. Heye, L. Pike, J. Crawford, A. Madalena, B. Incerti, A. Pragliola, T. Meitinger, and A. Ballabio. 1992. Intragenic deletion of the KALIG-1 gene in Kallmann's syndrome. *N. Engl. J. Med.* 326: 1752–1755.
4. Hardelin, J.P., J. Leveilliers, I. del Castillo, M. Cohen-Salmon, R. Legouis, S. Blanchard, S. Compain, P. Bouloux, J. Kirk, C. Moraine, et al. 1992. X-chromosome-linked Kallmann's syndrome: stop mutations validate the candidate gene. *Proc. Natl. Acad. Sci. USA.* 89:8190–8194.
5. de Roux, N., J. Young, M. Misrahi, R. Genet, P. Chanson, G. Schaison, and E. Milgrom. 1997. A family with hypogonadotropic hypogonadism and mutations in the gonadotropin-releasing hormone receptor. *N. Engl. J. Med.* 337: 1597–1602.
6. Layman, L.C., D.P. Cohen, M. Jin, J. Xie, Z. Li, R.H. Reindollar, S. Bolbolan, D.P. Bick, R.R. Sherins, L.W. Duck, et al. 1998. Mutations in gonadotropin-releasing hormone receptor gene cause hypogonadotropic hypogonadism. *Nat. Genet.* 18:14–15.
7. Matthews, C.H., S. Borgato, P. Beck-Peccoz, M. Adams, Y. Tone, G. Gambino, S. Casagrande, G. Tedeschini, A. Benedetti, and V.K.K. Chatterjee. 1993. Primary amenorrhea and infertility due to a mutation in the β subunit of follicle-stimulating hormone. *Nat. Genet.* 5:83–86.
8. Layman, L.C., E.J. Lee, D.B. Peajk, A.B. Nammoum, K.V. Vu, B.L. Van Lingen, M.R. Gray, P.G. McDonough, R.H. Reindollar, and J.L. Jameson.

1997. Delayed puberty and hypogonadism caused by mutations in the follicle-stimulating hormone β -subunit gene. *N. Engl. J. Med.* 337:607–611.
9. Weiss, J., L. Axelrod, R.W. Whitcomb, P.E. Harris, W.F. Crowley, and J.L. Jameson. 1992. Hypogonadism caused by a single amino acid substitution in the β subunit of luteinizing hormone. *N. Engl. J. Med.* 326:1799–1803.
10. Kremer, H., R. Kraaij, S.P.A. Toledo, M. Post, J.B. Fridman, C.Y. Van Reen, E. Milgrom, H.H. Ropers, E. Mariman, A.P.N. Themmen, and H.G. Brunner. 1995. Male pseudohermaphroditism due to a homozygous missense mutation of the luteinizing hormone receptor gene. *Nat. Genet.* 9:160–164.
11. Laue, L.L., S.M. Wu, M. Kudo, A.J.W. Hsueh, G.B. Cutler, Jr., J.E. Griffin, J.D. Wilson, C. Brain, A.C. Berry, D.B. Grant, and W.Y. Chan. 1995. A nonsense mutation of the human luteinizing hormone receptor gene in Leydig cell hypoplasia. *Hum. Mol. Genet.* 4:1429–1433.
12. Latronico, A.C., J. Anast, I.J. Arnhold, R. Rapaport, B.B. Mendonca, W. Castro, C. Tsigos, and G.P. Chrousos. 1996. Testicular and ovarian resistance to luteinizing hormone caused by inactivating mutations of the luteinizing hormone-receptor gene. *N. Engl. J. Med.* 334:507–512.
13. Laue, L.L., S.M. Wu, M. Kudo, C.J. Bourdony, G.B. Cutler, Jr., A.J.W. Hsueh, and W.Y. Chan. 1996. Compound heterozygous mutations of the luteinizing hormone receptor gene in Leydig cell hypoplasia. *Mol. Endocrinol.* 10: 987–997.
14. Misrahi, M., G. Meduri, S. Pissard, C. Bouvattier, I. Beau, H. Loosfelt, A. Jolivet, E. Milgrom, and P. Bougnères. 1997. Comparison of immunocytochemical and molecular features with the phenotype in a case of incomplete male pseudohermaphroditism associated with a mutation of the luteinizing hormone receptor. *J. Clin. Endocrinol. Metab.* 82:2159–2165.
15. Toledo, S.P.A., H.G. Brunner, R. Kraaij, M. Post, P.L.M. Dahia, C.Y. Hayashida, H. Kremer, and A.P.N. Themmen. 1996. An inactivating mutation of the LH receptor causes amenorrhea in a 46 XX female. *J. Clin. Endocrinol. Metab.* 81:3850–3854.
16. Aittomäki, K., J.L.D. Lucena, P. Pakarinen, P. Sistonen, J. Tapanainen, J. Gromoll, R. Kaskikari, E.M. Sankila, H. Lehtväslaiho, A.R. Engel, et al. 1995. Mutation in the follicle-stimulating hormone receptor gene causes hereditary hypergonadotropic ovarian failure. *Cell.* 82:959–968.
17. Aittomäki, K., R. Herva, U.H. Stenman, K. Juntunen, P. Ylöstalo, O. Hovatta, and A. de la Chapelle. 1996. Clinical features of primary ovarian failure caused by a point mutation in the follicle-stimulating hormone receptor gene. *J. Clin. Endocrinol. Metab.* 81:3722–3726.
18. Conway, E., W. Höppner, J. Gromoll, M. Simoni, and G.S. Conway. 1997. Mutations of the FSH receptor gene are rare in familial and sporadic premature ovarian failure. *J. Endocrinol.* 152(Suppl.):P257.
19. Groome, N.P., P.J. Illingworth, M. O'Brien, R. Pai, F.E. Rodger, J.P. Mather, and A.S. McNeilly. 1996. Measurement of dimeric inhibin B throughout the human menstrual cycle. *J. Clin. Endocrinol. Metab.* 81:1401–1405.
20. Kanis, J.A., and the WHO Study Group. 1994. Assessment of fracture risk and its application to screening for postmenopausal osteoporosis: synopsis of a WHO report. *Osteoporosis Int.* 4:368–381.
21. Bergh, C., C.M. Howles, K. Borg, L. Hamberger, B. Josefsson, L. Nilsson, and M. Wikland. 1997. Recombinant human follicle stimulating hormone (r-hFSH; Gonal-F) versus highly purified urinary FSH (Metrodin HP): results of a randomized comparative study in women undergoing assisted reproductive techniques. *Hum. Reprod.* 12:2133–2139.
22. Gromoll, J., E. Pökel, and E. Nieschlag. 1996. The structure and organization of the human follicle-stimulating hormone receptor gene. *Genomics.* 35: 308–311.
23. Vannier, B., H. Loosfelt, G. Meduri, C. Pichon, and E. Milgrom. 1996. Anti-human FSH receptor monoclonal antibodies: immunocytochemical and immunocytochemical characterization of the receptor. *Biochemistry.* 35:1359–1366.
24. Beau, I., M. Misrahi, B. Gross, B. Vannier, H. Loosfelt, M.T. Vu Hai, C. Pichon, and E. Milgrom. 1997. Basolateral localization and transcytosis of gonadotropin and thyrotropin receptors expressed in MDCK cells. *J. Biol. Chem.* 272: 5241–5248.
25. de Roux, N., M. Misrahi, R. Brauner, M. Houang, J.C. Carel, M. Granier, Y. Le Bouc, N. Ghinea, A. Boumedienne, J.E. Toublanc, and E. Milgrom. 1996. Four families with loss of function mutations of the TSH receptor. *J. Clin. Endocrinol. Metab.* 81:4229–4235.
26. Le Bivic, A., Y. Sambuy, A. Patzak, N. Patil, M. Chao, and E. Rodriguez-Boulan. 1991. An internal deletion in the cytoplasmic tail reverses the apical localization of human NGF receptor in transfected MDCK cells. *J. Cell Biol.* 115:607–618.
27. Meduri, G., N. Charnaux, H. Loosfelt, A. Jolivet, F. Sypratos, S. Brailly, and E. Milgrom. 1997. LH/hCG receptors in breast cancer. *Cancer Res.* 57:857–864.
28. Meduri, G., M.T. Vu Hai, A. Jolivet, S. Takemori, S. Kominami, M.A. Driancourt, and E. Milgrom. 1996. Comparison of cellular distribution of LH receptors and steroidogenic enzymes in the porcine ovary. *J. Endocrinol.* 148: 435–446.
29. Dupont, E., V. Luu The, F. Labrie, and G. Pelletier. 1990. Light microscopic immunocytochemical localization of 3β -hydroxy-5-ene-steroid dehydrogenase/ $\Delta 5$ - $\Delta 4$ isomerase in the gonads and adrenal glands of the guinea pig. *Endocrinology.* 126:2906–2909.
30. Kominami, S., K. Shinzawa, and S. Takemori. 1983. Immunochemical studies on cytochrome P450 in adrenal microsomes. *Biochim. Biophys. Acta.* 755:163–169.
31. Kitawaki, J., N. Yoshida, and Y. Osawa. 1989. An enzyme-linked immunosorbent assay for quantitation of aromatase cytochrome P-450. *Endocrinology.* 124:1417–1423.
32. Inkster, S.E., and A.M.H. Brodie. 1991. Expression of aromatase cytochrome P-450 in premenopausal and postmenopausal human ovaries: an immunocytochemical study. *J. Clin. Endocrinol. Metab.* 73:717–726.
33. Tamura, T., J. Kitawaki, T. Yamamoto, Y. Osawa, S. Kominami, S. Takemaris, and H. Okadah. 1992. Immunohistochemical localization of 17 α -hydroxylase/C17-20 lyase and aromatase cytochrome P450 in the human ovary during the menstrual cycle. *J. Endocrinol.* 135:589–595.
34. Gougeon, A. 1996. Regulation of ovarian follicular development in primates: facts and hypotheses. *Endocr. Rev.* 17:121–155.
35. Hillier, S.G. 1994. Current concepts of the roles of follicle stimulating hormone and luteinizing hormone in folliculogenesis. *Hum. Reprod.* 9:188–191.
36. Segaloff, D.L., and M. Ascoli. 1993. The lutropin/choriogonadotropin receptor 4 years later. *Endocr. Rev.* 14:324–347.
37. Themmen, A.P.N., and H.G. Brunner. 1996. Luteinizing hormone receptor mutations and sex differentiation. *Eur. J. Endocrinol.* 134:533–540.
38. Misrahi, M., and E. Milgrom. 1997. The TSH receptor. In *Pharmacotherapeutics of the Thyroid Gland*. A.P. Weetman and A. Grossman, editors. Springer-Verlag, Berlin/Heidelberg/New York. 128:33–73.
39. Abramowicz, M.J., L. Duprez, J. Parma, G. Vassart, and C. Heinrichs. 1997. Familial congenital hypothyroidism due to inactivating mutation of the thyrotropin receptor causing profound hypoplasia of the thyroid gland. *J. Clin. Invest.* 99:3018–3024.
40. Rozell, T.G., H. Wang, X. Liu, and D.L. Segaloff. 1995. Intracellular retention of mutant gonadotropin receptors results in loss of hormone binding activity of the follitropin receptor but not the lutropin/choriogonadotropin receptor. *Mol. Endocrinol.* 9:1727–1736.
41. Gromoll, J., M. Simoni, and E. Nieschlag. 1996. An activating mutation of the follicle-stimulating hormone receptor autonomously sustains spermatogenesis in a hypophysectomized man. *J. Clin. Endocrinol. Metab.* 81:1367–1370.
42. Kumar, T.R., Y. Wang, L. Naifang, and M.M. Matzuk. 1997. Follicle stimulating hormone is required for ovarian follicle maturation but not male fertility. *Nat. Genet.* 15:201–204.
43. McNatty, K.P., A. Makris, C. De Grazia, R. Osathanondh, and K.J. Ryan. 1980. Steroidogenesis by recombined follicular cells from the human ovary in vitro. *J. Clin. Endocrinol. Metab.* 51:1286–1292.
44. Menon, V., R. Logan Edwards, W.R. Butt, M. Bluck, and S.S. Lynch. 1984. Review of 59 patients with hypergonadotropic amenorrhea. *Br. J. Obstet. Gynaecol.* 91:63–66.
45. Conway, G.S. 1997. Premature ovarian failure. *Curr. Opin. Obstet. Gynecol.* 9:202–206.
46. Starup, J., V. Sele, and B. Henriksen. 1971. Amenorrhoea associated with increased production of gonadotrophins and a morphologically normal ovarian follicular apparatus. *Acta Endocrinol.* 66:248–256.
47. Mehta, A.E., I. Matwijiw, E.A. Lyons, and C. Faiman. 1992. Noninvasive diagnosis of resistant ovary syndrome by ultrasonography. *Fertil. Steril.* 57: 56–61.
48. Shangold, M.M., R.N. Turksoy, R.A. Bashford, and C.B. Hammond. 1977. Pregnancy following the “insensitive ovary syndrome.” *Fertil. Steril.* 28: 1179–1181.