

## Osteoclasts are essential for TNF- $\alpha$ -mediated joint destruction

Kurt Redlich, ... , Erwin F. Wagner, Georg Schett

*J Clin Invest.* 2002;110(10):1419-1427. <https://doi.org/10.1172/JCI15582>.

Article Immunology

The detailed cellular and molecular mechanisms leading to joint destruction in rheumatoid arthritis, a disease driven by proinflammatory cytokines, are still unknown. To address the question of whether osteoclasts play a pivotal role in this process, transgenic mice that express human TNF (hTNFtg) and that develop a severe and destructive arthritis were crossed with osteopetrotic, *c-fos*-deficient mice (*c-fos*<sup>-/-</sup>) completely lacking osteoclasts. The resulting mutant mice (*c-fos*<sup>-/-</sup>hTNFtg) developed a TNF-dependent arthritis in the absence of osteoclasts. All clinical features of arthritis, such as paw swelling and reduction of grip strength, progressed equally in both groups. Histological evaluation of joint sections revealed no difference in the extent of synovial inflammation, its cellular composition (except for the lack of osteoclasts), and the expression of matrix metalloproteinase-3 (MMP-3) and MMP-13. In addition, cartilage damage, proteoglycan loss, and MMP-3, -9, and -13 expression in chondrocytes were similar in hTNFtg and *c-fos*<sup>-/-</sup>hTNFtg mice. However, despite the presence of severe inflammatory changes, *c-fos*<sup>-/-</sup>hTNFtg mice were fully protected against bone destruction. These data reveal that TNF-dependent bone erosion is mediated by osteoclasts and that the absence of osteoclasts alters TNF-mediated arthritis from a destructive to a nondestructive arthritis. Therefore, in addition to the use of anti-inflammatory therapies, osteoclast inhibition could be beneficial for the treatment of rheumatoid arthritis.

Find the latest version:

<https://jci.me/15582/pdf>



# Osteoclasts are essential for TNF- $\alpha$ -mediated joint destruction

Kurt Redlich,<sup>1</sup> Silvia Hayer,<sup>2</sup> Romeo Ricci,<sup>3</sup> Jean-Pierre David,<sup>3</sup> Makiyeh Tohidast-Akrad,<sup>4</sup> George Kollias,<sup>5</sup> Günter Steiner,<sup>1</sup> Josef S. Smolen,<sup>1</sup> Erwin F. Wagner,<sup>3</sup> and Georg Schett<sup>1</sup>

<sup>1</sup>Department of Internal Medicine III, Division of Rheumatology, University of Vienna, Vienna, Austria

<sup>2</sup>Institute of Medical Biochemistry, Vienna Biocenter, Vienna, Austria

<sup>3</sup>Research Institute of Molecular Pathology, Vienna, Austria

<sup>4</sup>Ludwig Boltzmann Institute for Rheumatology, Vienna, Austria

<sup>5</sup>Institute of Immunology, Biomedical Science Research Center Alexander Fleming, Vari, Greece

The detailed cellular and molecular mechanisms leading to joint destruction in rheumatoid arthritis, a disease driven by proinflammatory cytokines, are still unknown. To address the question of whether osteoclasts play a pivotal role in this process, transgenic mice that express human TNF (hTNFtg) and that develop a severe and destructive arthritis were crossed with osteopetrotic, *c-fos*-deficient mice (*c-fos*<sup>-/-</sup>) completely lacking osteoclasts. The resulting mutant mice (*c-fos*<sup>-/-</sup>hTNFtg) developed a TNF-dependent arthritis in the absence of osteoclasts. All clinical features of arthritis, such as paw swelling and reduction of grip strength, progressed equally in both groups. Histological evaluation of joint sections revealed no difference in the extent of synovial inflammation, its cellular composition (except for the lack of osteoclasts), and the expression of matrix metalloproteinase-3 (MMP-3) and MMP-13. In addition, cartilage damage, proteoglycan loss, and MMP-3, -9, and -13 expression in chondrocytes were similar in hTNFtg and *c-fos*<sup>-/-</sup>hTNFtg mice. However, despite the presence of severe inflammatory changes, *c-fos*<sup>-/-</sup>hTNFtg mice were fully protected against bone destruction. These data reveal that TNF-dependent bone erosion is mediated by osteoclasts and that the absence of osteoclasts alters TNF-mediated arthritis from a destructive to a nondestructive arthritis. Therefore, in addition to the use of anti-inflammatory therapies, osteoclast inhibition could be beneficial for the treatment of rheumatoid arthritis.

*J. Clin. Invest.* 110:1419–1427 (2002). doi:10.1172/JCI200215582.

## Introduction

Rheumatoid arthritis (RA) is the most severe chronic joint disease by virtue of persistent inflammation and destruction of cartilage and bone. The latter is a characteristic feature of RA usually not observed in other forms of inflammatory arthritis and constitutes a major cause of progressive disability and crippling of RA patients (1). The mechanisms leading to joint destruction still have not been fully elucidated. As a typical histopathological feature, a hyperplastic and hypercellular synovial membrane is built up in which lymphocytes, macrophage-like cells, and fibroblast-like cells accumulate. Experimental evidence suggests

that erosive arthritis caused by grafting human rheumatoid synovial membrane into the knee joints of SCID mice is dependent on macrophages and fibroblast-like cells (2). Furthermore, synovial fibroblasts express cathepsins, matrix metalloproteinases (MMPs) (3–5), and a vacuolar-type ATPase that could contribute to bone matrix degradation (6). The molecular players in RA are still poorly understood. Proinflammatory cytokines, in particular TNF- $\alpha$  and IL-1, have proven to be major contributors to this disease (7). In fact, mice overexpressing the proinflammatory cytokine TNF develop a destructive arthritis (8). Moreover, blocking TNF improves signs and symptoms of RA and arrests progression of erosions in a large number of RA patients (9) by reducing several cytokines and other inflammation-associated molecules (10). Nevertheless, many patients do not respond to inhibition of TNF, and in many the erosive process continues despite significant effects of anti-inflammatory therapies (9).

Recently the role of osteoclasts in bone destruction of RA has attracted growing interest (11). Osteoclast precursors and mature osteoclasts are abundant at sites of arthritic bone erosions (12, 13). Several studies have shown that both receptor activator of NF- $\kappa$ B ligand (RANKL), an essential factor for osteoclast differentiation (14, 15), and its receptor RANK, are

Received for publication April 1, 2002, and accepted in revised form September 17, 2002.

**Address correspondence to:** Georg Schett, Department of Internal Medicine III, Division of Rheumatology, University of Vienna, Währinger Gürtel 18–20, A-1090, Vienna, Austria. Phone: 43-1-40400-4300; Fax: 43-1-40400-4306; E-mail: georg.schett@akh-wien.ac.at.

Kurt Redlich and Silvia Hayer contributed equally to this work.

**Conflict of interest:** The authors have declared that no conflict of interest exists.

**Nonstandard abbreviations used:** rheumatoid arthritis (RA); matrix metalloproteinase (MMP); receptor activator of NF- $\kappa$ B ligand (RANKL); human TNF-transgenic (hTNFtg); murine soluble TNF receptor type 1 (mTNF-R1); hematoxylin and eosin (H&E); tartrate-resistant acid phosphatase (TRAP).

expressed on cells of the RA synovial membrane (16). However, RANKL also regulates interactions between T cells and dendritic cells. Local T cell activation is associated with the expression of RANKL and subsequently with joint destruction in an animal model of arthritis (17). In fact, administration of osteoprotegerin, a naturally occurring inhibitor of RANKL (14), leads to protection from bone destruction in experimental arthritis (17, 18). However, as RANKL and RANK are not involved only in osteoclast differentiation but also in other cell-cell interactions, including those of T cells and antigen-presenting cells, it is not clear on which particular cells the protective effects of osteoprotegerin or lack of RANKL on arthritic destruction are mainly exerted (17, 19, 20).

*c-fos*, a component of the dimeric transcription factor AP-1, is a key regulator of bone cell proliferation and differentiation (21). Mice transgenic for *c-fos* develop osteosarcomas (21), whereas *c-fos* knockout (*c-fos*<sup>-/-</sup>) mice are osteopetrotic (22). These *c-fos* mutant mice completely lack functional osteoclasts, but have increased numbers of bone marrow macrophages, whereas other hematopoietic lineages, including T cells, develop normally.

In the present study we investigated whether bone erosions can occur in an osteoclast-free model of arthritis. We generated *c-fos*<sup>-/-</sup> hTNF-transgenic (*c-fos*<sup>-/-</sup>hTNFtg) mice and provide evidence that arthritic erosions cannot develop in the absence of osteoclasts.

## Methods

**Animals.** The heterozygous Tg197 TNF transgenic mice (C57/BL6) have been described previously (8). These mice develop a chronic inflammatory and destructive polyarthritis within 4–6 weeks of birth. *c-fos*<sup>-/-</sup> mice (C57/BL6/129sv/cp) were generated as previously described (23). hTNFtg and *c-fos*<sup>-/-</sup> mice were intercrossed to obtain double mutant animals. F2 generations were used and all data were generated from littermates. A total number of 39 mice (wild type, *n* = 5; hTNFtg, *n* = 17; *c-fos*<sup>-/-</sup>, *n* = 5; and *c-fos*<sup>-/-</sup>hTNFtg, *n* = 12) were investigated. *c-fos*<sup>-/-</sup> mice lack tooth eruption, therefore they had to be fed with a wet diet. For breeding purposes, hTNFtg mice were treated with 0.2 mg of an anti-TNF monoclonal antibody (Centocor Inc., Leiden, The Netherlands) twice weekly in order to prevent arthritis. All animal procedures were approved by the local ethical committee.

**Clinical assessment.** Clinical evaluation was started 4 weeks after birth and was performed weekly. Arthritis was evaluated in a blinded manner as described previously (24). Briefly, joint swelling was examined using a clinical score graded from 0 to 3 (0, no swelling; 1, mild swelling of toes and ankle; 2, moderate swelling of toes and ankle; 3, severe swelling of toes and ankle). In addition, grip strength of each paw was analyzed on a wire 3 mm in diameter, using a score from 0 to -4 (0, normal grip strength; -1, mildly reduced grip strength; -2, moderately reduced

grip strength; -3, severely reduced grip strength; -4, no grip strength at all). Animals were sacrificed by cervical dislocation, the blood was withdrawn by heart puncture, and the paws of all animals were collected for histology. The latest evaluation was performed 10 weeks after birth.

**ELISAs.** Analysis of serum levels of hTNF and murine soluble TNF receptor type 1 (mTNF-R1) was performed by ELISA. Tests were established according to the manufacturer's recommendations (R&D Systems Inc., Minneapolis, Minnesota, USA). The lowest levels of detection were 0.18 pg/ml for the hTNF ELISA and 5 pg/ml for the TNF-R1 ELISA, respectively.

**Histological assessment.** Hind and front paws and the right knees were fixed in 4.0% formalin overnight and then decalcified in 14% EDTA with pH adjusted to 7.2 by addition of ammonium hydroxide (Sigma-Aldrich, St. Louis, Missouri, USA) at 4°C until the bones were pliable. Serial paraffin sections (2 µm) of all four paws and the right knee joint were stained with hematoxylin and eosin (H&E), or with toluidine blue for tartrate-resistant acid phosphatase (TRAP) activity, and analyzed by immunohistochemical methods. TRAP staining was performed as previously described (16). For immunohistochemistry, deparaffinized, ethanol-dehydrated tissue sections were boiled for 2 minutes in 10 mM sodium citrate buffer (pH 6.0) using a 700-W microwave oven, then allowed to cool to room temperature and rinsed in detergent solution (0.5% Tween in PBS) for 10 minutes. Tissue sections were blocked for 20 minutes in PBS containing 20% rabbit serum followed by incubation for 1 hour at room temperature with the following antibodies: goat polyclonal anti-calcitonin receptor antibody (Santa Cruz Biotechnology Inc., Santa Cruz, California, USA) diluted 1:500 in PBS containing 1% BSA (Sigma-Aldrich); rat monoclonal anti-fibroblast antibody (Biogenesis, Poole, United Kingdom) diluted 1:40; rat monoclonal anti-macrophage (F4/80) antibody (Serotec Inc., Raleigh, North Carolina, USA) diluted 1:80; rat monoclonal

**Table 1**

Cellular composition and MMP expression is not influenced by the absence of *c-fos*, despite the absence of osteoclasts and reduced MMP-9 expression

	hTNFtg	<i>c-fos</i> <sup>-/-</sup> hTNFtg
Fibroblasts (anti-fibroblast)	42.5% ± 3.2%	42.6% ± 2.8%
Macrophages (F4/80)	49.0% ± 2.3%	46.2% ± 1.6%
T cells (anti-CD3)	3.3% ± 0.8%	2.6% ± 0.3%
Osteoclasts (TRAP <sup>+</sup> MNCs)	2.2% ± 0.1%	0% <sup>A</sup>
MMP-3	32.8% ± 1.5%	32.3% ± 0.8%
MMP-9	35.2% ± 1.4%	20.0% ± 1.3% <sup>A</sup>
MMP-13	35.0% ± 2.1%	38.0% ± 3.3%

Inflammatory synovial tissue was stained for fibroblasts (anti-fibroblast), macrophages (F4/80), and T cells (anti-CD3) as well as for osteoclasts (TRAP-positive multinucleated cells; TRAP<sup>+</sup> MNCs), MMP-3, MMP-9, and MMP-13 in hTNFtg and *c-fos*<sup>-/-</sup>hTNFtg mice. Percentages of stained cells are given. Data are shown as mean ± SEM. <sup>A</sup>Significantly different from hTNFtg (*P* < 0.05).

anti-CD3 antibody (Novocastra Laboratories Inc., Newcastle, United Kingdom) diluted 1:100; mouse monoclonal anti-MMP-3; mouse monoclonal anti-MMP-9; and mouse monoclonal anti-MMP-13 antibody (all from Lab Vision Corp., Fremont, California, USA) diluted 1:100. After sections were rinsed, endogenous peroxidase was blocked with 0.3% hydrogen peroxide in Tris-buffered saline (10 mM Tris-HCl and 140 mM NaCl, pH 7.4) for 10 minutes. This was followed by 30 minutes of incubation with a biotinylated species-specific anti-IgG secondary antibody (Vector Laboratories Inc., Burlingame, California, USA). Then sections were incubated with the VECTASTAIN ABC reagent (Vector Laboratories Inc.) for another 30 minutes using 3,3-diaminobenzidine (Sigma-Aldrich) for the color reaction, resulting in brown staining of antigen-expressing cells.

For quantification of the areas of inflammation, H&E-stained sections (five per mouse) were evaluated. The sum of the areas of inflammation for each single mouse was calculated by evaluating all digital, carpal, and tarsal joints as well as the right knee joint. The same H&E-stained sections were analyzed as described above for quantification of erosions. The number of osteoclasts was counted as described above from TRAP-stained serial sections. Cartilage breakdown (i.e., proteoglycan loss and matrix dissolution) was determined from toluidine blue-stained serial sections by assessing cartilage area as well as a cartilage score according to the method of Joosten et al. (25), with modifications. Breakdown was scored on a scale from 0 to 3 (0, fully stained cartilage; 1, destained cartilage; 2, destained cartilage with synovial cell invasion; 3, complete loss of cartilage). Quantification of immunohistochemical sections was performed by counting both total cell numbers and the numbers of positively stained cells from at least three different sites of three individual sections per mouse. A total of 12 mice ( $n = 3$  of each group) was included in this immunohistochemical analysis.

**Ex vivo osteoclastogenesis.** For RANKL-induced osteoclast differentiation, spleen cells were plated overnight and nonadherent cells were recovered and plated in 24-well plates ( $10^6$  cells per well) in the presence of 20 ng/ml M-CSF and 50 ng/ml RANKL (both from R&D Systems Inc.). Osteoclast differentiation was evaluated after 4 days of culture by TRAP staining using the Leukocyte Acid Phosphatase Kit from Sigma-Aldrich.

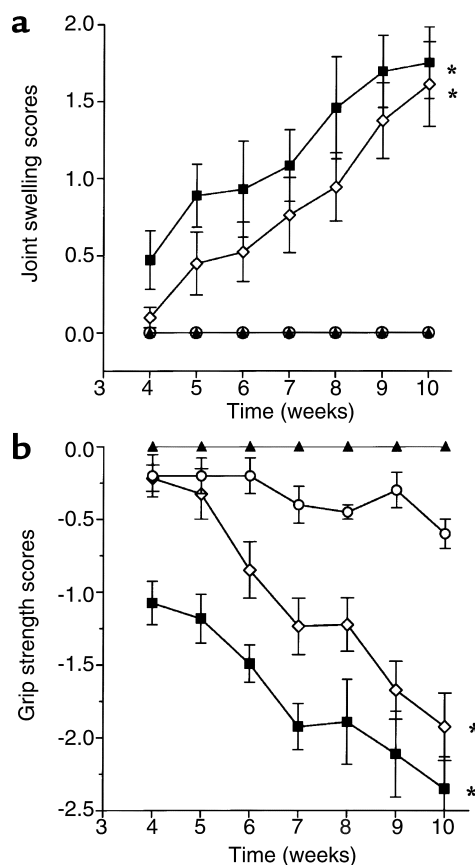
**Statistical analysis.** Data are shown as mean  $\pm$  SEM. Group mean values were compared by two-tailed Student  $t$  test. For correlation analysis, the nonparametric Spearman test was used.

## Results

*c-fos*<sup>-/-</sup>hTNFtg mice show a significant reduction of body weight, are osteopetrotic, and display arthritis. In order to obtain an osteoclast-free model of TNF-dependent arthritis, the osteopetrotic *c-fos* mutant mice were

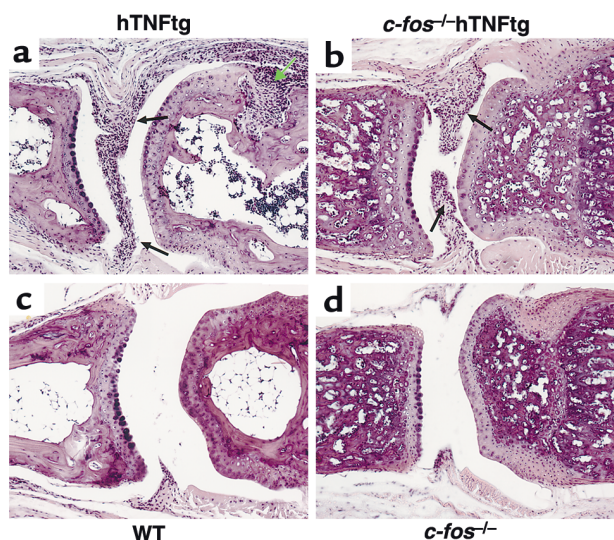
crossed with hTNF-transgenic mice. The offspring of all four genotypes (wild-type, hTNFtg, *c-fos*<sup>-/-</sup>, and *c-fos*<sup>-/-</sup>hTNFtg) were born at Mendelian frequency and were viable. Compared with the wild-type genotype, mice of all other genotypes showed a significant reduction in body weight, which was most prominently seen in *c-fos*<sup>-/-</sup>hTNFtg mice (-43%) but was also found in *c-fos*<sup>-/-</sup> (-23%) and hTNFtg mice (-16%). *c-fos*<sup>-/-</sup>hTNFtg mice were toothless and displayed severe osteopetrosis as previously described for the *c-fos*<sup>-/-</sup> mice (22).

**Clinical signs of arthritis are c-fos independent.** We next analyzed whether the absence of *c-fos* alters the clinical course of TNF-driven arthritis, indicated by increasing joint swelling and reduction of grip strength over time. Mice lacking the hTNF transgene (wild-type and *c-fos*<sup>-/-</sup> mice) showed no signs of joint swelling during the observation period (Figure 1a). In contrast, in hTNFtg mice, joint swelling started at week 4 (mean swelling score  $\pm$  SEM,  $0.1 \pm 0.07$ ) and increased weekly to a maximum at week 10 ( $1.6 \pm 0.27$ ).



**Figure 1**

There are no differences in the clinical course of arthritis between hTNFtg and *c-fos*<sup>-/-</sup>hTNFtg mice. Clinical course of arthritis indicated by (a) joint swelling and (b) grip strength was assessed in wild-type mice (filled triangles), *c-fos*<sup>-/-</sup> mice (open circles), hTNFtg mice (open diamonds), and *c-fos*<sup>-/-</sup>hTNFtg mice (filled squares). Asterisks indicate a significant ( $P < 0.01$ ) increase in joint swelling and decrease in grip strength in hTNFtg and *c-fos*<sup>-/-</sup>hTNFtg mice compared with baseline and with wild-type and *c-fos*<sup>-/-</sup> mice.



**Figure 2**

Severe joint inflammation is seen in hTNFtg and *c-fos*<sup>-/-</sup>hTNFtg mice, but no signs of bone erosions are found in *c-fos*<sup>-/-</sup>hTNFtg mice. H&E-stained sections of a digital joint of an hTNFtg (a), a *c-fos*<sup>-/-</sup>hTNFtg (b), a wild-type (WT) (c), and a *c-fos*<sup>-/-</sup> mouse (d). Inflammatory tissue (indicated by black arrows) and erosion (indicated by a green arrow) are present in the hTNFtg mice. *c-fos*<sup>-/-</sup>hTNFtg mice show only inflammatory tissue (black arrows) and no erosions. Wild-type and *c-fos*<sup>-/-</sup> mice lack any signs of inflammation and served as controls. Magnification: x50.

In the *c-fos*<sup>-/-</sup>hTNFtg group, joint swelling was also present as early as week 4 ( $0.5 \pm 0.19$ ) and increased significantly thereafter ( $1.8 \pm 0.23$ ). Joint swelling did not differ significantly between the two hTNFtg groups at any individual point in time, clearly indicating that *c-fos* is not required for the development of inflammatory arthritis.

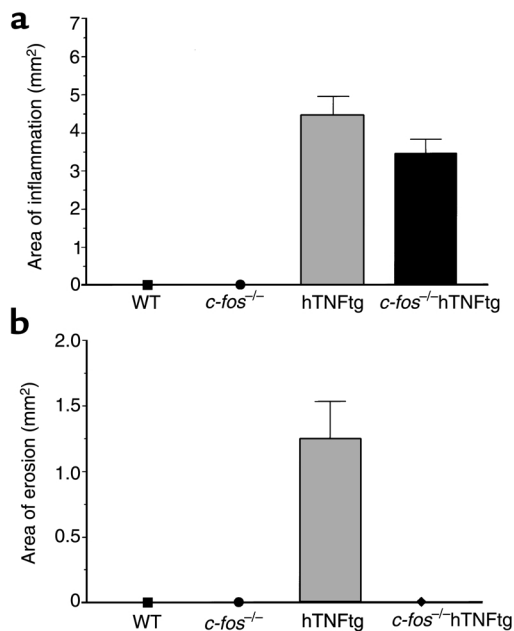
Grip strength was assessed as a surrogate marker for joint function (Figure 1b). The grip strength of hTNFtg mice significantly decreased (week 4,  $-0.2 \pm 0.09$ ; week 10,  $-1.9 \pm 0.23$ ;  $P < 0.01$ ), showing that hTNFtg leads to progressive loss of joint function. As expected, mice lacking *c-fos* (*c-fos*<sup>-/-</sup> and *c-fos*<sup>-/-</sup>hTNFtg mice) had lower grip strengths on the basis of their skeletal abnormalities (23) compared with wild-type and hTNFtg mice. *c-fos*<sup>-/-</sup>hTNFtg animals showed reduced grip strength from the start of observation (week 4,  $-1.1 \pm 0.15$ ), with progressive deterioration continuing up to week 10 ( $-2.4 \pm 0.22$ ;  $P < 0.01$ ). There were no significant differences in grip strength between hTNFtg and *c-fos*<sup>-/-</sup>hTNFtg mice during later stages of arthritis. Thus, TNF-dependent development of clinical arthritis and functional impairment is not altered despite the absence of *c-fos*.

Histological examination revealed a complete lack of bone erosions in *c-fos*<sup>-/-</sup>hTNFtg mice. Based on the fact that *c-fos*<sup>-/-</sup>hTNFtg and hTNFtg mice developed similar clinical symptoms of arthritis, we further evaluated arthritic lesions by quantitative histological analysis to estimate the amount of inflammatory tissue and erosions.

Representative histologies of a digital joint are shown in Figure 2. hTNFtg mice developed not only intense inflammation, but also severe bone erosions (Figure 2a). In contrast, *c-fos*<sup>-/-</sup>hTNFtg mice, while showing a degree of inflammatory tissue similar to that in hTNFtg animals, had a highly conserved joint architecture, and no histological signs of bone erosions were seen (Figure 2b). Animals of both control groups, wild-type (Figure 2c) and *c-fos*<sup>-/-</sup> (Figure 2d), lacked any sign of joint inflammation or destruction. As previously described for *c-fos*<sup>-/-</sup> mice, *c-fos*<sup>-/-</sup>hTNFtg mice exhibited osteopetrosis with thickening of the trabecular bones and narrowing of the bone marrow cavity.

Quantification of inflammatory tissue in digital, carpal, and tarsal joints and the right knee joints revealed a similar degree of inflammation in hTNFtg mice ( $4.4 \pm 0.5$  mm<sup>2</sup>) and *c-fos*<sup>-/-</sup>hTNFtg mice ( $3.4 \pm 0.4$  mm<sup>2</sup>) (Figure 3a). However, quantitative evaluation of bone destruction in the same sections showed severe erosive changes in hTNFtg mice ( $1.2 \pm 0.3$  mm<sup>2</sup>), while bone erosions were completely absent in *c-fos*<sup>-/-</sup>hTNFtg mice (Figure 3b). Thus *c-fos* knockout mice are protected against TNF-induced bone erosion, but not inflammation.

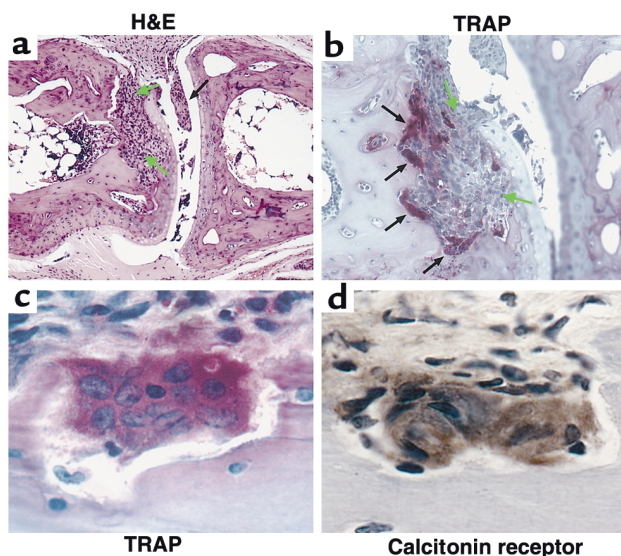
*Cellular composition and MMP expression in joints of c-fos*<sup>-/-</sup>hTNFtg animals show no changes beyond the absence of osteoclasts and lower MMP-9 expression. To address whether the absence of *c-fos* alters inflammatory



**Figure 3**

No difference is found in the amount of inflammatory tissue between *c-fos*<sup>-/-</sup>hTNFtg and hTNFtg mice, but *c-fos*<sup>-/-</sup>hTNFtg mice show a complete lack of bone erosions. Mean areas of (a) inflammation and (b) erosions are shown for wild-type, *c-fos*<sup>-/-</sup>, hTNFtg, and *c-fos*<sup>-/-</sup>hTNFtg mice. Mice lacking the hTNF transgene (wild-type and *c-fos*<sup>-/-</sup>) showed no signs of inflammation. No erosions were detectable in *c-fos*<sup>-/-</sup>hTNFtg mice in contrast to hTNFtg mice. Mice lacking the hTNF transgene also showed no erosions.





**Figure 4**  
There are abundant osteoclasts at the site of erosions in hTNFtg mice. Histology of a proximal interphalangeal joint of an hTNFtg mouse is shown. Serial sections were stained with either H&E (a), TRAP (b and c), or calcitonin receptor (d). Inflammation (indicated by black arrows) with subsequent subchondral bone erosion (indicated by green arrows) was found only in hTNFtg mice (a). TRAP staining revealed a remarkable number of TRAP-positive multinucleated cells (black arrows) in hTNFtg mice at erosion sites (b and c). These TRAP-positive cells also showed positive staining for the calcitonin receptor (d). Magnification: a,  $\times 100$ ; b,  $\times 200$ ; c and d,  $\times 400$ .

responses, the cellular composition and MMP expression of synovial inflammatory tissue was assessed in hTNFtg and *c-fos*<sup>-/-</sup>hTNFtg mice by immunohistochemistry (Table 1). Both cell numbers and distribution of distinct cell populations were similar among hTNFtg (fibroblasts,  $42.5\% \pm 3.2\%$ ; macrophages,  $49.0\% \pm 2.3\%$ ; T cells,  $3.3\% \pm 0.8\%$ ) and *c-fos*<sup>-/-</sup>hTNFtg animals (fibroblasts,  $42.6\% \pm 2.8\%$ ; macrophages,  $46.2\% \pm 1.6\%$ ; T cells,  $2.6\% \pm 0.3\%$ ). However, osteoclasts were found only in hTNFtg mice ( $2.2\% \pm 0.1\%$ ). Furthermore, the expression of MMP-3 ( $32.8\% \pm 1.5\%$  vs.  $32.3\% \pm 0.8\%$ ) and MMP-13 ( $35.0\% \pm 2.1\%$  vs.  $38.0\% \pm 3.3\%$ ) was unchanged. A large number of cells in *c-fos*<sup>-/-</sup>hTNFtg mice expressed MMP-9 ( $20.0\% \pm 1.3\%$ ), although this was lower than in hTNFtg animals ( $35.2\% \pm 1.4\%$ ;  $P < 0.05$ ). This reduction must be seen in the light of the lack of osteoclasts, since MMP-9 is the key MMP of osteoclasts (3). Moreover, MMP-9 was similarly expressed by chondrocytes from hTNFtg and *c-fos*<sup>-/-</sup>hTNFtg mice (see below). Thus, with the exception of osteoclasts and MMP-9 expression, the cellular composition and MMP expression of synovial inflammatory tissue in *c-fos*<sup>-/-</sup>hTNFtg mice did not differ from their hTNFtg littermates with erosive arthritis.

*The absence of c-fos has no influence on hTNF and mTNF-R1 levels.* To assess whether the lack of bone erosions observed in *c-fos*<sup>-/-</sup>hTNFtg mice was due to a change in the level of expression of the hTNF

transgene, all animal sera were screened for the amount of circulating hTNF. hTNF was detectable only in the serum of hTNFtg and *c-fos*<sup>-/-</sup>hTNFtg mice (Table 2). No significant difference in hTNF serum levels was found between the two groups, indicating that the absence of *c-fos* had no influence on the expression of hTNF. We also measured the serum levels of murine soluble mTNF-R1, since it mediates the activity of hTNF in hTNFtg mice, and found all four groups expressing TNF-R1 without significant differences (Table 2).

*TNF and RANKL cannot rescue osteoclastogenesis in vitro in the absence of c-fos.* To analyze whether the expression of hTNFtg or RANKL could rescue osteoclastogenesis in *c-fos*-deficient mice, spleen cells from *c-fos*<sup>-/-</sup>, hTNFtg, and *c-fos*<sup>-/-</sup>hTNFtg mice were cultured either with M-CSF or M-CSF and RANKL. When cultured with M-CSF and RANKL, no osteoclasts could be generated in vitro from either *c-fos*<sup>-/-</sup> spleen cells or *c-fos*<sup>-/-</sup>hTNFtg spleen cells (data not shown). In contrast, osteoclast formation was observed when hTNFtg spleen cells were cultured in the presence of M-CSF and RANKL, but not M-CSF alone. Thus, osteoclast differentiation is also impaired in *c-fos*<sup>-/-</sup>hTNFtg cells in vitro.

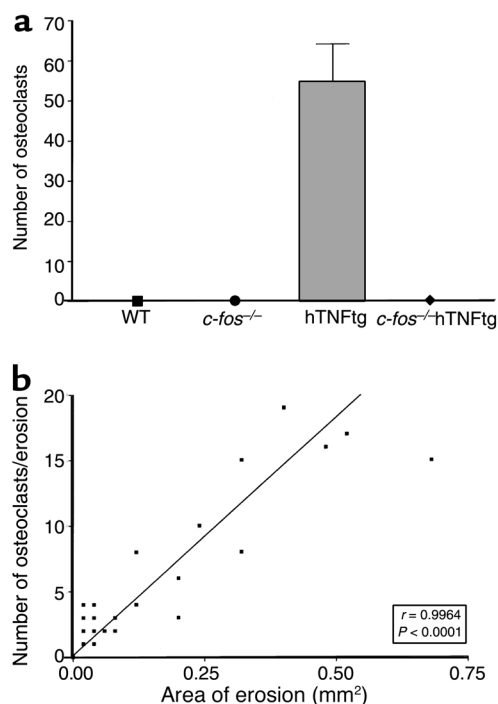
*Complete absence of osteoclasts in c-fos<sup>-/-</sup>hTNFtg mice and strong correlation between the number of osteoclasts and the size of erosions in hTNFtg mice.* The failure of spleen cells from *c-fos*<sup>-/-</sup>hTNFtg mice to differentiate into osteoclasts in vitro did not exclude the possibility that osteoclasts could be generated in these animals in vivo, particularly since TNF has been shown to be able to induce osteoclast differentiation even in the absence of RANKL in vitro (26). We therefore assessed the presence and number of osteoclasts in both hTNFtg and *c-fos*<sup>-/-</sup>hTNFtg mice. In hTNFtg mice, initial destruction of bone is usually observed at the cartilage-pannus junction, with subsequent progressive resorption of the subchondral bone (Figure 4a). TRAP staining of these areas revealed numerous mono- and multinucleated TRAP-positive cells. Whereas the mononuclear TRAP-positive cells were interspersed within the pannus, multinucleated TRAP-positive cells were almost exclusively found attached to the bone at resorption lacunae (Figure 4b). Analysis of serial sections revealed that TRAP-positive multinucleated cells (Figure 4c) also expressed the calcitonin receptor (Figure 4d).

**Table 2**

The absence of *c-fos* has no influence on levels of hTNF and TNF-R1

Group	hTNF (ng/ml)	mTNF-R1 (ng/ml)
WT	ND	846 $\pm$ 38
<i>c-fos</i> <sup>-/-</sup>	ND	780 $\pm$ 160
hTNFtg	65 $\pm$ 8	1,106 $\pm$ 197
<i>c-fos</i> <sup>-/-</sup> hTNFtg	62 $\pm$ 10	913 $\pm$ 293

Serum levels of hTNF and mTNF-R1 were measured 10 weeks after birth at the end of the experiment in wild-type, *c-fos*<sup>-/-</sup>, hTNFtg, and *c-fos*<sup>-/-</sup>hTNFtg mice. Data are shown as mean  $\pm$  SEM. ND, not detectable.



**Figure 5**  
Size of bone erosions is strongly correlated to number of osteoclasts. Numbers of osteoclasts assessed by histological quantification of TRAP-positive multinucleated cells in all joints at erosion sites are shown for wild-type, *c-fos*<sup>-/-</sup>, hTNFtg, and *c-fos*<sup>-/-</sup>hTNFtg mice (a). The areas of erosions given in mm<sup>2</sup> were highly correlated to the numbers of osteoclasts per compartment (b).

Detailed quantitative analyses revealed a large number of osteoclasts at erosion sites in hTNFtg mice (mean  $\pm$  SEM,  $54.3 \pm 9.6$ ) but a complete lack of osteoclasts in *c-fos*<sup>-/-</sup>hTNFtg mice (Figure 5a). In fact, there was a highly significant correlation between osteoclast numbers and the area size of erosions ( $r = 0.9964$ ;  $P > 0.0001$ , Figure 5b).

*Proteoglycan content is reduced in cartilage of hTNFtg and c-fos*<sup>-/-</sup>hTNFtg mice. We also investigated whether the absence of *c-fos* had an influence on cartilage breakdown in arthritic joints (Table 3). Interestingly, direct invasion of inflammatory tissue into the cartilage was rarely observed in hTNFtg and *c-fos*<sup>-/-</sup>hTNFtg mice. However, in hTNFtg mice, while the cartilage maintained its architecture, the underlying adjacent bone underwent rapid resorption. Quantitative assessment of cartilage destruction revealed no significant difference in cartilage area between wild-type (mean  $\pm$  SEM,  $1.9 \pm 0.3$  mm<sup>2</sup>) and *c-fos*<sup>-/-</sup> mice ( $2.1 \pm 0.4$  mm<sup>2</sup>). Compared with these controls, both TNFtg groups of mice showed a trend toward lower amounts of cartilage, although this did not reach significance (hTNFtg,  $1.5 \pm 0.2$  mm<sup>2</sup>; *c-fos*<sup>-/-</sup>hTNFtg,  $1.7 \pm 0.2$  mm<sup>2</sup>). However, qualitative assessment of cartilage breakdown including proteoglycan loss, synovial cell invasion, and cartilage destruction (cartilage score) revealed significant alterations of cartilage in both hTNFtg and *c-fos*<sup>-/-</sup>hTNFtg mice compared with wild-type and

*c-fos*<sup>-/-</sup>controls. In fact, hTNFtg and *c-fos*<sup>-/-</sup>hTNFtg mice did not significantly differ in their cartilage scores (Table 3). These findings are illustrated by toluidine blue staining of articular cartilage showing a marked reduction of proteoglycan content, predominantly at sites adjacent to inflammatory tissue in both hTNFtg (Figure 6a) and *c-fos*<sup>-/-</sup>hTNFtg (Figure 6b) mice compared with controls (Figure 6, c and d). The capacity of TNF to induce MMP expression in chondrocytes was not altered by the deficiency of *c-fos*, since MMP-3, MMP-9, and MMP-13 were similarly induced in hTNFtg and *c-fos*<sup>-/-</sup>hTNFtg mice (Table 3). This suggests that independent of *c-fos*, the inflammatory process led to significant induction of MMP expression and degradation of cartilage matrix.

## Discussion

This study provides unequivocal evidence that osteoclasts are pivotal cells in destructive arthritis by demonstrating that the absence of osteoclasts completely prevents bone resorption in TNF-mediated arthritis. The model used is based on a combination of two different molecular and cellular pathophysiological abnormalities: the absence of *c-fos* leads to a selective absence of the osteoclast lineage (22), and the overexpression of hTNF results in a severe and destructive arthritis independent of T cell and B cell immunity through the signaling of TNF-R1 (8). Whereas hTNFtg mice show rapidly progressive bone erosions in inflamed joints, *c-fos*<sup>-/-</sup>hTNFtg mice are completely protected from bone destruction, despite the severe arthritis from which these animals suffer. Indeed, the clinical and histological extent of inflammation and MMP expression were similar in hTNFtg and *c-fos*<sup>-/-</sup>hTNFtg mice, indicating that *c-fos* is not critically involved in TNF-mediated joint inflammation. Thus this model clearly separates inflammation from bone destruction and suggests the presence of distinct molecular mechanisms leading to the phenotype of destructive arthritis.

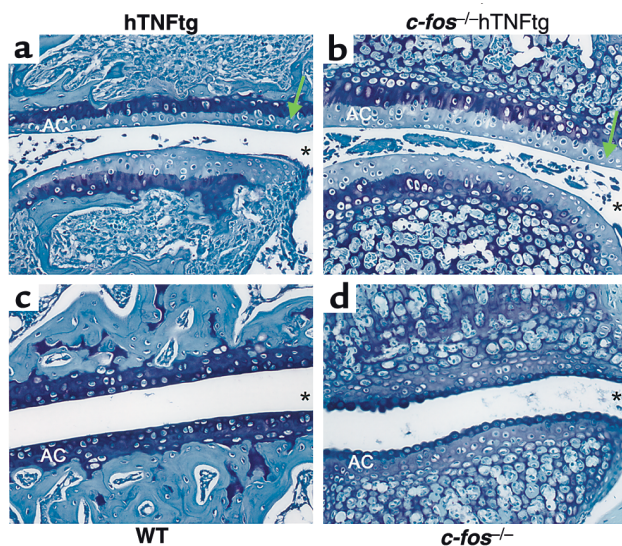
The molecular and cellular mechanisms of bone destruction in RA have long remained an enigma and are currently the object of scientific debate. Invasion of a hypertrophic synovial membrane is the typical

**Table 3**

Cartilage breakdown is dependent on TNF but not *c-fos*

Group	WT	<i>c-fos</i> <sup>-/-</sup>	hTNFtg	<i>c-fos</i> <sup>-/-</sup> hTNFtg
<sup>A</sup> Cartilage area	$1.9 \pm 0.3$	$2.1 \pm 0.4$	$1.5 \pm 0.2$	$1.7 \pm 0.2$
<sup>B</sup> Cartilage score	0	$0.1 \pm 0.1$	$1.4 \pm 0.1$	$1.2 \pm 0.1$
MMP-3	0	0	$33.3 \pm 5.2$	$33.0 \pm 3.0$
MMP-9	0	0	$20.5 \pm 1.5$	$22.0 \pm 1.1$
MMP-13	0	0	$36.3 \pm 4.3$	$35.7 \pm 1.8$

<sup>A</sup>Quantitative assessment of cartilage area (mean  $\pm$  SEM in mm<sup>2</sup>). <sup>B</sup>Cartilage scores were determined using an arbitrary scoring ranging from 0 to 3 (0, fully stained cartilage; 1, destained cartilage; 2, destained cartilage with synovial cell invasion; 3, complete loss of cartilage). Analyses were performed with toluidine blue-stained sections. For cartilage staining with MMP-3, MMP-9, and MMP-13 in hTNFtg and *c-fos*<sup>-/-</sup>hTNFtg mice, percentages of positively stained chondrocytes are given. All data are shown as mean  $\pm$  SEM.



**Figure 6**  
Proteoglycan content is similarly reduced in cartilage of hTNFtg and *c-fos*<sup>-/-</sup>hTNFtg mice. Toluidine blue staining of articular cartilage was performed in hTNFtg (a), *c-fos*<sup>-/-</sup>hTNFtg (b), wild-type (c), and *c-fos*<sup>-/-</sup> mice (d). A marked reduction of proteoglycan content indicated by decreased staining intensity (green arrows) was found in hTNFtg and *c-fos*<sup>-/-</sup>hTNFtg mice. Asterisks indicate the joint space. AC indicates articular cartilage. Magnification: ×200.

histopathological feature of bone erosion in RA (27), and thus the infiltration of synovial inflammatory tissue into bone has long been considered a pathogenetic mechanism of bone erosion. Moreover, experimental evidence has suggested that cells, especially activated fibroblasts within the synovial membrane, may directly participate in the invasion (2) and resorption of bone in RA. On the other hand, the cell typically designed for bone resorption is the osteoclast, which harbors a number of specific tools for this special purpose (28, 29). Therefore, there has been growing scientific interest in the hypothetical responsibility of osteoclasts for local bone resorption in arthritis (30). Indeed, the whole range of signals essential for osteoclastogenesis is found overexpressed in human RA. Aside from the well-known presence of TNF and IL-1 (31, 32), osteoclastogenic cytokines such as M-CSF and RANKL (in combination with its receptor RANK) are found in synovial inflammatory tissue (33). Furthermore, RA synovial tissue can be considered a suitable microenvironment for osteoclastogenesis, since synovial T cells and fibroblasts express RANKL in situ (16, 17), potentially serving as nursing cells (34), and a large number of cells of the monocyte/macrophage lineage, possibly serving as osteoclast progenitors, accumulate in the inflammatory lesions of RA (35). In fact, both osteoclast progenitors and mature osteoclasts have been described as being present at the site of bone erosions in human RA (12, 13, 36). Nevertheless, linking the mere presence of osteoclasts at the site of bone erosion to an essential role in inducing these lesions appeared far more difficult.

Several experimental animal models of arthritis indicate an important role for osteoclasts in local bone erosion. Treatment with osteoprotegerin prevents local bone erosion in adjuvant arthritis (17) by blocking the osteoclastogenic properties of activated RANKL-expressing T cells. Furthermore, osteoprotegerin significantly reduces local bone erosion in a TNF-driven model of arthritis (18), which is T cell- and B cell-independent, suggesting that RANKL expression by immunocompetent cells is not a paradigm for osteoclast-mediated local bone resorption. Further evidence comes from the study of osteoclast-free *RANKL*<sup>-/-</sup> mice, which are almost completely protected from local bone erosion but not from arthritis induced by serum transfer from K/BxN mice (37). This latter model is T cell- and B cell-independent, although immune-complex mediated. All these models thus suggest that intact RANKL/RANK interaction is of central importance for osteoclast-mediated local bone erosion.

However, RANKL/RANK signaling is not confined to osteoclast development but is also important in the interaction of T cells with dendritic cells (38), and the effect of a blockade of RANKL/RANK signaling on these dendritic cell functions and antigen presentation is unclear. In fact, most experimental models of RA are dependent on immunocompetent cells or their products. Furthermore, there is experimental evidence for RANKL/RANK-independent mechanisms of osteoclastogenesis; in particular, TNF and IL-1 may be involved in such situations (26).

The *c-fos*<sup>-/-</sup>hTNFtg arthritis model allows definitive conclusions on the role of osteoclasts in destructive arthritis for several reasons. Our model is distinct from autoimmune models of arthritis, since it does not depend on autoantibodies, immune complexes, or T cells, but rather on cytokine-driven inflammation (39). The knockout system used selectively inhibits osteoclast differentiation (40). If TNF had intrinsic osteoclastogenic properties mediated through signaling via TNF-R1 (41) and independent of the RANKL/RANK system (26), the overexpression of TNF in *c-fos*<sup>-/-</sup>hTNFtg mice would have allowed observation of such effects. In contrast, similar to *c-fos*<sup>-/-</sup> mice, *c-fos*<sup>-/-</sup>hTNFtg animals had a selective deficiency of osteoclast differentiation in vitro as well as in vivo.

The interaction of RANKL/RANK and *c-fos* is not fully elucidated. However, it is evident that *c-fos* is an essential differentiation signal downstream of RANK in osteoclast precursor cells, and moreover, *c-fos* is part of an IFN- $\beta$ -driven negative feedback loop for RANKL/RANK (42). Given that *c-fos* is part of the AP-1 transcription factor complex, which is often activated in the signaling of proinflammatory cytokines, the finding of a similar clinical course and a similar histological degree of inflammation and cellular composition and MMP expression in inflammatory tissue in hTNFtg and *c-fos*<sup>-/-</sup>hTNFtg mice was



somewhat surprising. Although several signaling steps, such as MAPK/SAPK kinase activation (43), *c-jun/c-fos* overexpression (44), and increased AP-1 binding to DNA (45) have been described in human RA and animal models of RA, our data indicate that *c-fos* is not an essential part of inflammatory signaling of TNF-mediated arthritis.

Our findings clearly separate the mechanisms involved in joint inflammation and those of local bone destruction. The pathways leading to cartilage destruction, however, may be different, and much less is known about how to differentiate cartilage breakdown from bone erosion and/or inflammation. In the adjuvant arthritis model described by Kong et al. (17), osteoprotegerin treatment not only protected rats from bone damage but also from cartilage breakdown, suggesting that these two pathomechanisms are linked to each other. In contrast, in the serum transfer model described by Pettit et al. (37), significant proteoglycan loss and cartilage destruction was evident in the absence of local bone erosion. Thus mechanisms independent of RANKL-driven and osteoclast-mediated bone erosion, which induce cartilage breakdown, have to be postulated. Similarly, in the present model, lack of *c-fos* did not reduce inflammation-mediated changes of cartilage. Cartilage damage, as indicated by proteoglycan loss, cartilage destruction, and increased MMP-3, MMP-9, and MMP-13 expression in chondrocytes, was similar in hTNFtg and *c-fos*<sup>-/-</sup>hTNFtg mice. This clearly demonstrates that targeting of *c-fos* uncouples cartilage damage from bone erosion in this TNF-driven model of arthritis. Interestingly, the amount of cartilage destruction due to invasion of inflammatory tissue was relatively low compared with findings in the K/BxN serum transfer arthritis in *RANKL*<sup>-/-</sup> mice, in which adhesion to and invasion of the cartilage surface is far more pronounced (37).

In summary, we have shown that osteoclasts are the essential link between synovial inflammation and bone destruction. Despite severe synovial inflammation triggered by the overexpression of proinflammatory cytokines, articular bone remains well preserved in the absence of osteoclasts. Thus, inflammatory synovitis and joint destruction are two different processes, and inhibition of osteoclast differentiation and/or activation changes a destructive arthritis to a nondestructive form. Therefore these findings have important therapeutic implications: since the osteoclast renders chronic inflammation of the joint erosive, future therapies of destructive arthritis will have to take inhibition of osteoclasts into consideration.

## Acknowledgments

This study was supported by the START price of the Austrian Science Fund (G. Schett), the Interdisciplinary Cooperative Project (ICP) of the Austrian Federal Ministry for Education, Science and Culture and

the City of Vienna, and a grant from the Austrian National Bank (project 8715, G. Schett). The Research Institute of Molecular Pathology is supported by Boehringer Ingelheim.

1. Scott, D.L., et al. 2000. The links between joint damage and disability in rheumatoid arthritis. *Rheumatology*. **39**:122–132.
2. Sack, U., et al. 1999. Systemic characteristics of chronic arthritis induced by transfer of human rheumatoid synovial membrane into SCID mice (human/murine SCID arthritis). *J. Autoimmun.* **13**:335–346.
3. Okada, Y., et al. 1995. Localization of matrix metalloproteinase 9 (92-kilodalton gelatinase/type IV collagenase = gelatinase B) in osteoclasts: implications for bone resorption. *Lab. Invest.* **72**:311–322.
4. Neuhold, L.A., et al. 2001. Postnatal expression in hyaline cartilage of constitutively active human collagenase-3 (MMP-13) induces osteoarthritis in mice. *J. Clin. Invest.* **107**:35–44.
5. van Meurs, J., et al. 1999. Cleavage of aggrecan at the Asn341-Phe342 site coincides with the initiation of collagen damage in murine antigen-induced arthritis: a pivotal role for stromelysin 1 in matrix metalloproteinase activity. *Arthritis Rheum.* **42**:2074–2084.
6. Pap, T., et al. 1999. Membrane-type-1 matrix metalloproteinase is abundantly expressed in fibroblasts and osteoclasts at the bone-implant interface of aseptically loosened joint arthroplasties in situ. *J. Rheumatol.* **26**:166–169.
7. Feldmann, M., Brennan, F.M., and Maini, R.N. 1996. Role of cytokines in rheumatoid arthritis. *Annu. Rev. Immunol.* **14**:397–440.
8. Keffer, J., et al. 1991. Transgenic mice expressing human tumour necrosis factor: a predictive genetic model of arthritis. *EMBO J.* **10**:4025–4031.
9. Lipsky, P.E., et al. 2000. Infliximab and methotrexate in the treatment of rheumatoid arthritis. Anti-Tumor Necrosis Factor Trial in Rheumatoid Arthritis with Concomitant Therapy Study Group. *N. Engl. J. Med.* **343**:1594–1602.
10. Charles, P., et al. 1999. Regulation of cytokines, cytokine inhibitors, and acute-phase proteins following anti-TNF- $\alpha$  therapy in rheumatoid arthritis. *J. Immunol.* **163**:1521–1528.
11. Romas, E., Gillespie, M.T., and Martin, T.J. 2002. Involvement of receptor activator of NF $\kappa$ B ligand and tumor necrosis factor- $\alpha$  in bone destruction in rheumatoid arthritis. *Bone*. **30**:340–346.
12. Bromley, M., and Woolley, D.E. 1984. Chondroclasts and osteoclasts at subchondral sites of erosion in the rheumatoid joint. *Arthritis Rheum.* **27**:968–975.
13. Gravalles, E.M., et al. 1998. Identification of cell types responsible for bone resorption in rheumatoid arthritis and juvenile rheumatoid arthritis. *Am. J. Pathol.* **152**:943–951.
14. Simonet, W.S., et al. 1997. Osteoprotegerin: a novel secreted protein involved in the regulation of bone density. *Cell*. **89**:309–319.
15. Yasuda, H., et al. 1998. Osteoclast differentiation factor is a ligand for osteoprotegerin/osteoclastogenesis-inhibitory factor and is identical to TRANCE/RANKL. *Proc. Natl. Acad. Sci. USA*. **95**:3597–3602.
16. Gravalles, E.M., et al. 2000. Synovial tissue in rheumatoid arthritis is a source of osteoclast differentiation factor. *Arthritis Rheum.* **43**:250–258.
17. Kong, Y.Y., et al. 1999. Activated T cells regulate bone loss and joint destruction in adjuvant arthritis through osteoprotegerin ligand. *Nature*. **402**:304–309.
18. Redlich, K., et al. 2002. Tumor necrosis factor  $\alpha$ -mediated joint destruction is inhibited by targeting osteoclasts with osteoprotegerin. *Arthritis Rheum.* **46**:785–792.
19. Kong, Y.Y., et al. 1999. OPG is a key regulator of osteoclastogenesis, lymphocyte development and lymph-node organogenesis. *Nature*. **397**:315–323.
20. Fata, J.E., et al. 2000. The osteoclast differentiation factor osteoprotegerin-ligand is essential for mammary gland development. *Cell*. **103**:41–50.
21. Jochum, W., Passegue, E., and Wagner, E.F. 2001. AP-1 in mouse development and tumorigenesis. *Oncogene*. **20**:2401–2412.
22. Grigoriadis, A.E., et al. 1994. c-Fos: a key regulator of osteoclast-macrophage lineage determination and bone remodeling. *Science*. **266**:443–448.
23. Wang, Z.Q., et al. 1992. Bone and haematopoietic defects in mice lacking c-fos. *Nature*. **360**:741–745.
24. Schett, G., et al. 2001. Adenovirus-based overexpression of tissue inhibitor of metalloproteinases 1 reduces tissue damage in the joints of tumor necrosis factor- $\alpha$ -transgenic mice. *Arthritis Rheum.* **44**:2888–2898.
25. Joosten, L.A., et al. 1999. Protection against cartilage and bone destruction by systemic interleukin-4 treatment in established murine type II collagen-induced arthritis. *Arthritis Res.* **1**:81–91.
26. Kobayashi, K., et al. 2000. Tumor necrosis factor  $\alpha$  stimulates

- osteoclast differentiation by a mechanism independent of the ODF/RANKL-RANK interaction. *J. Exp. Med.* **191**:275–286.
27. Lee, D.M., and Weinblatt, M.E. 2001. Rheumatoid arthritis. *Lancet.* **358**:903–911.
  28. Teitelbaum, S.L. 2000. Bone resorption by osteoclasts. *Science.* **289**:1504–1508.
  29. Suda, T., et al. 1999. Modulation of osteoclast differentiation and function by the new members of the tumor necrosis factor receptor and ligand families. *Endocr. Rev.* **20**:345–357.
  30. Goldring, S.R., and Gravalles, E.M. 2000. Pathogenesis of bone erosions in rheumatoid arthritis. *Curr. Opin. Rheumatol.* **12**:195–199.
  31. Chu, C.Q., Field, M., Feldmann, M., and Maini, R.N. 1991. Localization of tumor necrosis factor alpha in synovial tissues and at the cartilage-pannus junction in patients with rheumatoid arthritis. *Arthritis Rheum.* **34**:1125–1132.
  32. Deleuran, B.W., et al. 1992. Localization of interleukin-1 alpha, type 1 interleukin-1 receptor and interleukin-1 receptor antagonist in the synovial membrane and cartilage/pannus junction in rheumatoid arthritis. *Br. J. Rheumatol.* **31**:801–809.
  33. Romas, E., et al. 2000. Expression of osteoclast differentiation factor at sites of bone erosion in collagen-induced arthritis. *Arthritis Rheum.* **43**:821–826.
  34. Takayanagi, H., et al. 1997. A new mechanism of bone destruction in rheumatoid arthritis: synovial fibroblasts induce osteoclastogenesis. *Biochem. Biophys. Res. Commun.* **240**:279–286.
  35. Itonaga, I., Fujikawa, Y., Sabokbar, A., Murray, D.W., and Athanasou, N.A. 2000. Rheumatoid arthritis synovial macrophage-osteoclast differentiation is osteoprotegerin ligand-dependent. *J. Pathol.* **192**:97–104.
  36. Shimizu, S., Shiozawa, S., Shiozawa, K., Imura, S., and Fujita, T. 1985. Quantitative histologic studies on the pathogenesis of periarticular osteoporosis in rheumatoid arthritis. *Arthritis Rheum.* **28**:25–31.
  37. Pettit, A.R., et al. 2001. TRANCE/RANKL knockout mice are protected from bone erosion in a serum transfer model of arthritis. *Am. J. Pathol.* **159**:1689–1699.
  38. Anderson, D.M., et al. 1997. A homologue of the TNF receptor and its ligand enhance T-cell growth and dendritic-cell function. *Nature.* **390**:175–179.
  39. Douni, E., et al. 1995. Transgenic and knockout analyses of the role of TNF in immune regulation and disease pathogenesis. *J. Inflamm.* **47**:27–38.
  40. Matsuo, K., et al. 2000. Fos1 is a transcriptional target of c-Fos during osteoclast differentiation. *Nat. Genet.* **24**:184–187.
  41. Azuma, Y., Kaji, K., Katogi, R., Takeshita, S., and Kudo, A. 2000. Tumor necrosis factor-alpha induces differentiation of and bone resorption by osteoclasts. *J. Biol. Chem.* **275**:4858–4864.
  42. Takayanagi, H., et al. 2002. RANKL maintains bone homeostasis through c-Fos-dependent induction of interferon-beta. *Nature.* **416**:744–749.
  43. Schett, G., et al. 2000. Activation, differential localization, and regulation of the stress-activated protein kinases, extracellular signal-regulated kinase, c-Jun N-terminal kinase, and p38 mitogen-activated protein kinase, in synovial tissue and cells in rheumatoid arthritis. *Arthritis Rheum.* **43**:2501–2512.
  44. Han, Z., Boyle, D.L., Manning, A.M., and Firestein, G.S. 1998. AP-1 and NF-kappaB regulation in rheumatoid arthritis and murine collagen-induced arthritis. *Autoimmunity.* **28**:197–208.
  45. Asahara, H., et al. 1997. Direct evidence of high DNA binding activity of transcription factor AP-1 in rheumatoid arthritis synovium. *Arthritis Rheum.* **40**:912–918.