

# In vivo and in vitro characterization of neonatal hyperparathyroidism resulting from a de novo, heterozygous mutation in the Ca<sup>2+</sup>-sensing receptor gene: normal maternal calcium homeostasis as a cause of secondary hyperparathyroidism in familial benign hypocalciuric hypercalcemia.

M Bai, ... , E M Brown, B Steinmann

*J Clin Invest.* 1997;**99**(1):88-96. <https://doi.org/10.1172/JCI119137>.

## Research Article

We characterized the in vivo, cellular and molecular pathophysiology of a case of neonatal hyperparathyroidism (NHPT) resulting from a de novo, heterozygous missense mutation in the gene for the extracellular Ca<sup>2+</sup> (Ca<sup>2+</sup>(o))-sensing receptor (CaR). The female neonate presented with moderately severe hypercalcemia, markedly undermineralized bones, and multiple metaphyseal fractures. Subtotal parathyroidectomy was performed at 6 wk; hypercalcemia recurred rapidly but the bone disease improved gradually with reversion to an asymptomatic state resembling familial benign hypocalciuric hypercalcemia (FBHH). Dispersed parathyroid cells from the resected tissue showed a set-point (the level of Ca<sup>2+</sup>(o) half maximally inhibiting PTH secretion) substantially higher than for normal human parathyroid cells (approximately 1.8 vs. approximately 1.0 mM, respectively); a similar increase in set-point was observed in vivo. The proband's CaR gene showed a missense mutation (R185Q) at codon 185, while her normocalcemic parents were homozygous for wild type (WT) CaR sequence. Transient expression of the mutant R185Q CaR in human embryonic kidney (HEK293) cells revealed a substantially attenuated Ca<sup>2+</sup>(o)-evoked accumulation of total inositol phosphates (IP), while cotransfection of normal and mutant receptors showed an EC<sub>50</sub> (the level of Ca<sup>2+</sup>(o) eliciting a half-maximal increase in IPs) 37% higher than for WT CaR alone (6.3±0.4 vs. 4.6±0.3 mM Ca<sup>2+</sup>(o), respectively). Thus this de novo, heterozygous CaR mutation may exert a dominant negative action on the normal CaR, producing NHPT [...]

Find the latest version:

<https://jci.me/119137/pdf>



# In Vivo and In Vitro Characterization of Neonatal Hyperparathyroidism Resulting from a De Novo, Heterozygous Mutation in the $\text{Ca}^{2+}$ -sensing Receptor Gene: Normal Maternal Calcium Homeostasis as a Cause of Secondary Hyperparathyroidism in Familial Benign Hypocalciuric Hypercalcemia

Mei Bai,\* Simon H.S. Pearce,† Olga Kifor,\* Sunita Trivedi,\* Urs G. Stauffer,§ Rajesh V. Thakker,‡ Edward M. Brown,\* and Beat Steinmann||

\*Endocrine-Hypertension Division, Department of Medicine, Brigham and Women's Hospital, Boston, Massachusetts 02115; †MRC Molecular Endocrinology Group, Royal Postgraduate Medical School, Hammersmith Hospital, London, United Kingdom; and

§Department of Surgery and ||Division of Metabolic and Molecular Diseases, University Children's Hospital, CH-8032 Zurich, Switzerland

## Abstract

We characterized the in vivo, cellular and molecular pathophysiology of a case of neonatal hyperparathyroidism (NHPT) resulting from a de novo, heterozygous missense mutation in the gene for the extracellular  $\text{Ca}^{2+}$  ( $\text{Ca}_o^{2+}$ )-sensing receptor (CaR). The female neonate presented with moderately severe hypercalcemia, markedly undermineralized bones, and multiple metaphyseal fractures. Subtotal parathyroidectomy was performed at 6 wk; hypercalcemia recurred rapidly but the bone disease improved gradually with reversion to an asymptomatic state resembling familial benign hypocalciuric hypercalcemia (FBHH). Dispersed parathyroid cells from the resected tissue showed a set-point (the level of  $\text{Ca}_o^{2+}$  half maximally inhibiting PTH secretion) substantially higher than for normal human parathyroid cells ( $\sim 1.8$  vs.  $\sim 1.0$  mM, respectively); a similar increase in set-point was observed in vivo. The proband's CaR gene showed a missense mutation (R185Q) at codon 185, while her normocalcemic parents were homozygous for wild type (WT) CaR sequence. Transient expression of the mutant R185Q CaR in human embryonic kidney (HEK293) cells revealed a substantially attenuated  $\text{Ca}_o^{2+}$ -evoked accumulation of total inositol phosphates (IP), while cotransfection of normal and mutant receptors showed an  $\text{EC}_{50}$  (the level of  $\text{Ca}_o^{2+}$  eliciting a half-maximal increase in IPs) 37% higher than for WT CaR alone ( $6.3 \pm 0.4$  vs.  $4.6 \pm 0.3$  mM  $\text{Ca}_o^{2+}$ , respectively). Thus this de novo, heterozygous CaR mutation may exert a dominant negative action on the normal CaR, producing NHPT and more severe hypercalcemia than typically seen with FBHH. Moreover, normal maternal calcium homeostasis promoted additional secondary hyperparathy-

roidism in the fetus, contributing to the severity of the NHPT in this case with FBHH. (*J. Clin. Invest.* 1997; 99:88–96.) Key words: neonatal hyperparathyroidism • familial benign hypocalciuric hypercalcemia •  $\text{Ca}_o^{2+}$ -sensing receptor • missense mutation •  $\text{Ca}_o^{2+}$ -regulated PTH release • inositol phosphates

## Introduction

Neonatal hyperparathyroidism (NHPT)<sup>1</sup> is defined as symptomatic hypercalcemia with skeletal manifestations of hyperparathyroidism in the first 6 mo of life. It often presents in the first few days of life with severe PTH-dependent hypercalcemia, hypotonia, constipation, and respiratory distress (1–3). The latter is partly a consequence of severe bony undermineralization, resulting in multiple fractures of the ribs and elsewhere. NHPT was first described as a sporadic disorder more than 60 yr ago (4); subsequently its familial occurrence in pairs of siblings was documented, suggesting an autosomal recessive mode of inheritance in some cases (5, 6). Spiegel et al. first noted a case of NHPT born to an affected member of a family with autosomal dominant hypercalcemia (7). The salient clinical features of this form of hypercalcemia were first clearly delineated by Foley et al. (8), who called it familial benign hypercalcemia (FBH)—a term also employed by Heath et al. in their studies on this syndrome (9). Marx et al. and others confirmed the association between NHPT and the same autosomal dominant hypercalcemic condition (10–13), which they called familial hypocalciuric hypercalcemia (FHH) (11). We refer to this same condition here as familial benign hypocalciuric hypercalcemia (FBHH) in recognition of the contributions of both Foley et al. and Marx et al. to its clinical description. Marx et al. suggested in 1982 that some cases of NHPT might be the homozygous form of FBHH, because children with NHPT were encountered in families with both parents affected by FBHH (3). However, NHPT has also been noted in cases where only one parent had clinically apparent FBHH (3, 7, 14–18), and many further cases of NHPT appear to be sporadic, with both parents being normocalcemic (1, 19–26). Thus the nature of the genetic defect and how it produces two different hypercalcemic syndromes was obscure.

In 1992, Chou et al. showed linkage of the disease gene for

Part of this study was presented at the 46th Annual Meeting of the American Society of Human Genetics in San Francisco from 29 October to 2 November 1996.

Address correspondence to Prof. Dr. Med. Beat Steinmann, Division of Metabolic and Molecular Diseases, University Children's Hospital, Steinwiesstrasse 75, CH-8032 Zurich, Switzerland. FAX: 41-1-266-7167; E-mail: binges@kispi.unizh.ch

Received for publication 26 July 1996 and accepted in revised form 24 October 1996.

*J. Clin. Invest.*

© The American Society for Clinical Investigation, Inc.

0021-9738/97/01/0088/09 \$2.00

Volume 99, Number 1, January 1997, 88–96

1. Abbreviations used in this paper: CaR,  $\text{Ca}^{2+}$ -sensing receptor; FBHH, familial benign hypocalciuric hypercalcemia; NHPT, neonatal hyperparathyroidism.

FBHH to the long arm of chromosome 3 (27). Subsequently, additional workers confirmed this finding but also demonstrated that a similar phenotype was linked to the short arm of chromosome 19 (28) in one family and to a locus on neither chromosome 3 nor 19 in another (29). The following year, Polak et al. (30) and then others (31–35) identified missense, inactivating mutations in one allele of the extracellular  $\text{Ca}^{2+}$ -sensing receptor (CaR) in FBHH. The CaR is a G protein-coupled receptor that plays a key role in  $\text{Ca}^{2+}$  homeostasis by conferring upon parathyroid, kidney, thyroidal C-cells, and several other cell types the capacity to sense minute changes in the extracellular ionized calcium concentration ( $\text{Ca}_o^{2+}$ ; 36, 37). Indeed, the clinical features of FBHH and of a subsequently identified form of autosomal dominant hypocalcemia (ADH) resulting from CaR-activating mutations have shed considerable light on the physiological roles of the CaR (38–41). In FBHH, there is both a reduction in parathyroid glandular responsiveness to  $\text{Ca}_o^{2+}$  (i.e., an increase in set-point, the level of  $\text{Ca}_o^{2+}$  half maximally inhibiting PTH release; 42, 43) and inappropriately avid renal tubular  $\text{Ca}^{2+}$  reabsorption (9, 12, 13). This abnormal renal  $\text{Ca}^{2+}$  handling results from reduced sensitivity of CaRs in the distal tubule to the direct calciuric action of hypercalcemia (44). Relative hypocalciuria persists following parathyroidectomy (12, 45, 46), indicating that it is an intrinsic property of the kidney (i.e., PTH-independent). Conversely, in ADH the set-point for  $\text{Ca}_o^{2+}$ -regulated PTH release is reduced (47), and there is excessive  $\text{Ca}^{2+}$  excretion despite hypocalcemia (38, 48), due to the effects of activating CaR mutations on parathyroid and renal function.

The availability of the cloned CaR has permitted reevaluation of the etiology of NHPT and its relationship to FBHH. Some cases of NHPT arising in FBHH families with consanguineous marriages of affected family members are, in fact, the homozygous form of FBHH (34, 49). Recently, however, Pearce et al. have shown that NHPT with severe bone disease can result from de novo mutations in the CaR gene (35). We now document the third reported case of a de novo heterozygous CaR mutation causing NHPT. We have also carried out a variety of studies in vivo and in vitro that clarify the pathophysiology of this case by demonstrating that this patient's mutation produces an unusual degree of hypercalcemia because the mutant CaR exerts a dominant negative effect, interfering in some way with the function of the wild type receptor.

## Methods

**Clinical laboratory assays.** Blood and urine samples (obtained at the time of drawing blood) were collected randomly while the patient was hospitalized or in the outpatient clinic. Some samples were stored at  $-70^\circ\text{C}$  until analyzed. Calcium, magnesium, phosphorus, creatinine, alkaline phosphatase and protein were quantitated with a Synchrotron CX7 Clinical Chemistry Analyzer (Beckman Instruments, Inc., Fullerton, CA). Amino acids were determined with a System 6300 High Performance Amino Acid Analyzer (Beckman Instruments, Inc.). Intact PTH was determined by a luminescence immunoassay (Immulite; Diagnostic Products Corp., Los Angeles, CA). Calcitonin, 1,25-dihydroxyvitamin D and 25-hydroxyvitamin D were determined by radioimmunoassay and competitive binding assay, respectively (Nichols Institute Diagnostics, San Juan Capistrano, CA).

**Mutational analyses.** Genomic DNA extracted from the proband's leukocytes was amplified using PCR and 12 pairs of oligonucleotide primers spanning the entire 3234 bp coding sequence of the CaR (30, 35). The products were used to detect single stranded con-

formational polymorphisms (SSCP) as described before (35). Abnormal SSCP's were analyzed by DNA sequencing and confirmed by hybridization to sequence-specific  $^{32}\text{P}$ -end-labeled oligonucleotides (SSO) of wild type (5' CTTTCCTCCGAACCATCCC) and mutant sequence (5' CTTTCCTCCAAACCATCCC) (35, 50). Paternity was assessed using five highly polymorphic loci, D3S1267, D3S1303, D13S153, Rb1.20, and DXS1232 (51, 52). The analyses on DNA from the patient and her parents were made after informed consent.

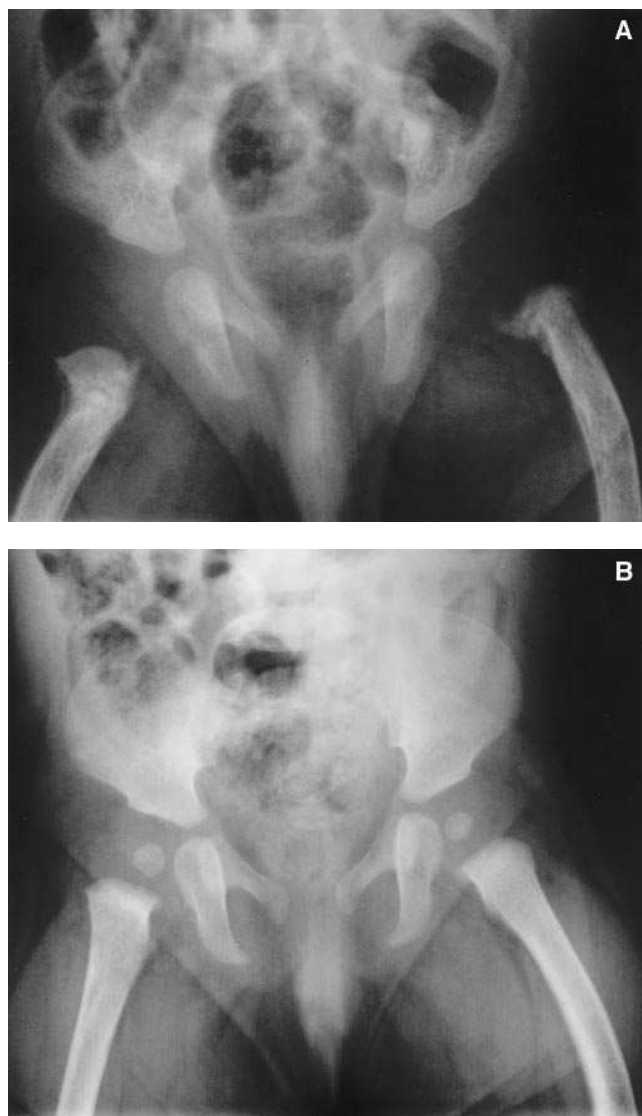
**Determination of  $\text{Ca}_o^{2+}$ -regulated PTH release in vitro.** Dispersed parathyroid cells were prepared by collagenase and DNase digestion (53) of parathyroid tissue removed at surgery on the proband, which had been transported on ice overnight from Zurich to Boston. We showed previously that normal and pathological parathyroid tissue maintained on ice overnight prior to preparing dispersed cells exhibits a  $\text{Ca}_o^{2+}$ -regulated PTH secretion indistinguishable from that of cells prepared immediately after tissue procurement (53, 54). Cellular viability, determined by trypan blue exclusion, exceeded 90%. To study PTH release, parathyroid cells were incubated in duplicate or triplicate at  $37^\circ\text{C}$  in Eagle's Minimal Essential Medium (containing Earle's salts, with  $\text{NaHCO}_3$ ,  $\text{Ca}_o^{2+}$  and  $\text{Mg}_o^{2+}$  deleted, and fortified with 25 mM Hepes, pH 7.45) with 0.5 mM  $\text{Mg}_o^{2+}$ , varying  $\text{Ca}_o^{2+}$  (see Results) and 2% FBS to minimize loss of intact PTH released into the medium due to degradation or adsorption to glass or plasticware (53, 55). After incubation for 1 h at  $37^\circ\text{C}$ , the cells were sedimented for 5 min at 100 g and the supernatant was stored at  $-80^\circ\text{C}$  before determination of immunoreactive intact PTH by immunoradiometric assay using a kit (Allegro; Nichols Institute Diagnostics). A sample was initially tested at three different dilutions to determine the optimal dilution for assay of all of the samples. The result revealed that the measured value of PTH was independent of the dilution used (i.e., diluted in parallel with the standard curve).

**Reconstruction of the human CaR and site-directed mutagenesis.** To facilitate site-directed mutagenesis, we have reconstructed the human  $\text{Ca}_o^{2+}$ -sensing receptor cDNA (HuPCaR4.0; generously provided by NPS Pharmaceuticals, Inc, Salt Lake City, UT) (56). We divided the coding region of the CaR cDNA into five segments of about 450 base pairs (bp) each and one 900 bp segment by creating five unique restriction sites (URSS), BspEI, NheI, AflII, HpaI, and XhoI, in that order, without changing the predicted amino acid sequence (56). The sequences of the six cassettes and the full coding sequence of the reconstructed receptor were confirmed by DNA sequencing. Site-directed mutagenesis to produce the proband's mutation was performed using the approach described by Kunkel (57), as described in detail previously (56). Incorporation of the desired mutation was confirmed by sequencing the entire cassette, which was then cloned into a suitable plasmid containing the rest of the wild type receptor cDNA.

**Transient expression of the wild type CaR and a receptor bearing the R185Q mutation in human embryonic kidney (HEK293) cells, and determination of total inositol phosphates.** The full length wild type (WT) human CaR and the mutant (R185Q) receptor were cloned into the KpnI and XbaI sites of the mammalian expression vector, pcDNA3 (Invitrogen Corp., San Diego, CA). Lipofectamine (GIBCO-BRL, Gaithersburg, MD) was employed for transfection (56). The HEK293 cells used for transient transfection were provided by NPS Pharmaceuticals, Inc., and were cultured in DMEM with 10% FBS. The DNA-liposome complex was prepared by mixing CaR DNA (0.156  $\mu\text{g}$  for expression of the wild type or R185Q mutant [R185Q] CaR individually) and Lipofectamine in OPTI-MEM I Reduced Serum Medium (GIBCO-BRL) and incubating the mixture at room temperature for 30 min. The DNA-lipofectamine mixture was then diluted with OPTI-MEM I Reduced Serum Medium and added to 90% confluent HEK293 cells in 24-well plates (Costar Corp., Cambridge, MA) for subsequent determination of inositol phosphates (IPs) as described below. After 5 h incubation at  $37^\circ\text{C}$ , equal amounts of OPTI-MEM I Reduced Serum Medium with 20% FBS were added to the medium over the transfected cells. The latter was then replaced with fresh DMEM with 10% FBS at 24 h after the transfection. The

expression of CaR protein was assayed 48 h after the start of transfection. For coexpression of wild type and mutant CaRs, 0.156  $\mu\text{g}$  of each cDNA were mixed and used to transfect HEK293 cells ( $\text{EC}_{50}$  was independent of the amount of DNA transfected over a fourfold range including 0.156  $\mu\text{g}$ ). To determine  $\text{Ca}_o^{2+}$ -elicited changes in IPs, HEK293 cells prelabeled overnight with [ $^3\text{H}$ ]myo-inositol (25  $\mu\text{Ci}$ /well; DuPont–New England Nuclear, Boston, MA) were incubated with varying  $\text{Ca}_o^{2+}$  for 30 min in the presence of 10 mM LiCl (58). The reactions were terminated with 10% ice cold TCA (final wt/vol). After centrifugation to remove insoluble debris, TCA was extracted with water-saturated diethylether. Total IPs were separated on Dowex columns and quantitated using a liquid scintillation counter (58).

**Statistical analyses.** The mean  $\text{EC}_{50}$ s (the effective concentration of an agonist giving one half of the maximal response) for the wild type and mutant receptors in response to increasing concentrations of  $\text{Ca}_o^{2+}$  was calculated from the  $\text{EC}_{50}$ s for all of the individual experiments and is expressed with the SEM as the index of dispersion.



**Figure 1.** Radiological findings in the pelvis and femora. Generalized osteopenia, metaphyseal fractures of the proximal femora, and periosteal calcifications are seen at 3 wk of age (A) and are no longer present at 4.5 mo of age (B) (Courtesy of Dr. G. Eich).

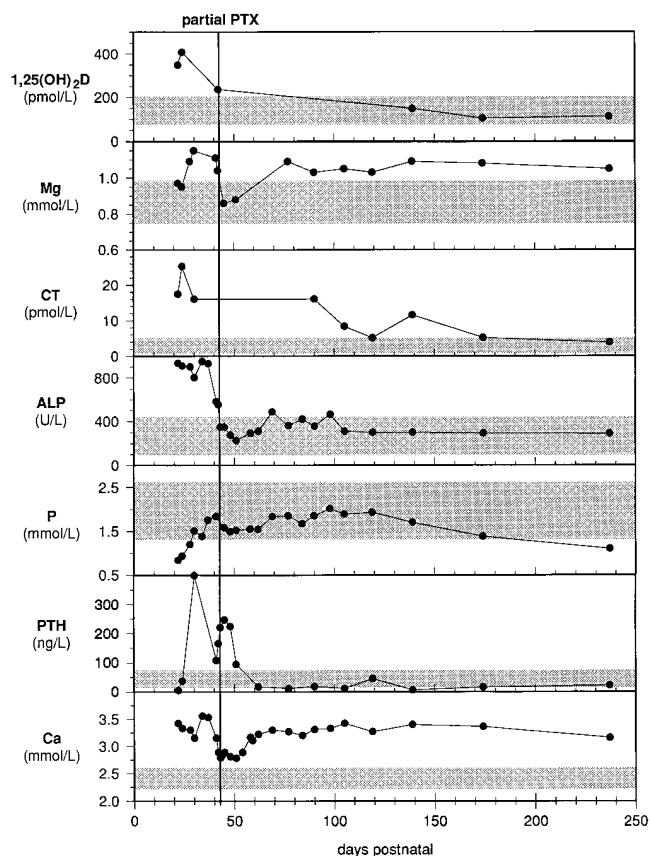
Comparison of the  $\text{EC}_{50}$ s and other statistical comparisons were carried out using Student's *t* test.

## Results

### Case history of the proband

**Gestational history.** The proband (DS—see subject II-1 in Fig. 5) is the first child, born in 1995 after a term gestation. Pregnancy was complicated by vaginal bleeding in the 14th week, necessitating hospitalization for 10 d; no other therapeutic actions were taken except for bed rest. During the pregnancy, the mother had no fevers or skin rashes and received no medications other than magnesium. Because of an abnormal cardiocogram, the fetal membranes were cut. The amniotic fluid was clear and delivery was assisted by vacuum extraction. Weight was 2,500 g, length 48 cm, and head circumference 31 cm; Apgar scores were 9/10/10.

**Clinical findings.** The girl had a large cephalohematoma, very soft skull, large fontanels, and wide open sutures. Both femora were bowed, and the left leg was inwardly rotated. The sclerae were slightly bluish. X rays revealed diffuse osteopenia and fractures. She was referred to the University Children's Hospital, Zurich, at 3 wk of age because of suspected osteogenesis imperfecta. She was alert, with normal muscle tone



**Figure 2.** Time course for selected biochemical determinations in the proband's serum. Abbreviations are as follows: 1,25(OH)<sub>2</sub>D, 1,25-dihydroxyvitamin D; Mg, serum total magnesium concentration; CT, calcitonin; ALP, alkaline phosphatase; P, phosphorus; PTH, intact parathyroid hormone; Ca, total calcium concentration; PTX, parathyroidectomy; shaded areas indicate the normal ranges.

and normal deep tendon reflexes, was not constipated and had no polyuria, polydipsia, or respiratory embarrassment. She was breast-fed and received no vitamin D supplements. Skeletal radiographs confirmed severe generalized osteopenia and metaphyseal fractures of the proximal humeri and proximal and distal femora with periosteal calcification (Fig. 1A). There were no Wormian bones but there were marked impressiones digitatae of the frontal bones. The lamina durae of the teeth were demineralized. The cortices of the long bones were indistinct and appeared split, typical of chronic hyperparathyroidism. Thyroid ultrasound revealed four, 2–3-mm, clear ellipsoid structures at the expected locations of the parathyroid glands at 3 wk, which decreased somewhat in size at 5 wk.

**Laboratory studies.** Fig. 2 shows selected biochemical parameters pre- and postoperatively (all normal ranges shown are age-specific, normative values for the local institution where the studies were performed). Initial total serum calcium was 3.33 mmol/liter (normal 2.2–2.6), phosphorus 0.93 mmol/liter (normal 1.3–2.6), magnesium 0.95 mmol/liter (normal 0.74–0.98), alkaline phosphatase 909 U/liter (normal 87–439), serum total protein 58 g/liter (normal 48–76), and calcium to creatinine clearance ratio 0.0022 (normal > 0.012). Maximal tubular reabsorption of phosphorus (TmP) was 0.83 mmol/liter glomerular filtrate (normal  $2.13 \pm 0.12$ ), and urinary phosphoethanolamine and amino acids were normal. Intact PTH was 38.5 ng/liter (normal 12–72), calcitonin 25.3 pmol/liter (normal 0.6–4.8), 1,25-dihydroxyvitamin D ( $1,25(\text{OH})_2\text{D}$ ), 408 pmol/liter (normal 70–200) and 25-hydroxyvitamin D ( $25(\text{OH})\text{D}$ ) 73 nmol/liter (normal 27–105). These results made osteogenesis imperfecta very unlikely, excluded hypophosphatasia and were strongly indicative of NHPT.

**Clinical course.** At 6 wk of age, total parathyroidectomy was attempted. Four ellipsoid structures were identified and removed; the central part of each was processed for histology,

and the rest was put in sterile culture medium with 10% FBS and sent by overnight mail to E.M. Brown for study of  $\text{Ca}_o^{2+}$ -regulated PTH secretion in vitro (see below). Histology of the upper two structures confirmed that they were parathyroid tissue with normal morphology by light and electron microscopy, without clear cell hyperplasia; the other two resected structures were normal thyroid. The postoperative course was uneventful. Hypercalcemia recurred rapidly and hypermagnesemia, elevated PTH and calcitonin persisted (Fig. 2), indicating incomplete parathyroidectomy. The patient has since done well clinically; length and head circumference followed the 3rd centile; weight followed the 10th centile. X rays at 8 wk showed marked improvement, and at 4.5 mo (Fig. 1B) the bony structures were almost normal. The valgus deformity of the femora was unchanged. At 3.5 and 4.5 mo the only abnormality was the slightly soft occipital bones, which normalized at 5.5 mo. At 12 mo, the child was normal by clinical examination with normal, straight legs.

**Biochemical course (Fig. 2).** Serum calcium decreased 3 d before and reached an approximately steady state level 15 d after partial parathyroidectomy. Serum phosphorus gradually increased from markedly reduced to low-normal values before surgery and became low again after 200 d of age (low normal phosphorus levels have been observed in such patients before [3]). Alkaline phosphatase approached normal levels before surgery, while  $1,25(\text{OH})_2\text{D}$  was elevated before surgery and became normal afterward.  $25(\text{OH})\text{D}$  was normal throughout. Urinary calcium to creatinine clearance ratio was low (between 0.0005 and 0.0056;  $n = 12$ ) and was unaffected by surgery. TmP was low (0.83–1.20 mmol/liter of glomerular filtration rate;  $n = 3$ ) until 28 d of age, increased but remained at subnormal values (1.43–1.80 mmol/liter GFR;  $n = 8$ ) between 30 and 140 d of age, and again decreased further (1.12 and 0.87 mmol/liter GFR) at 176 and 240 d of age, respectively.

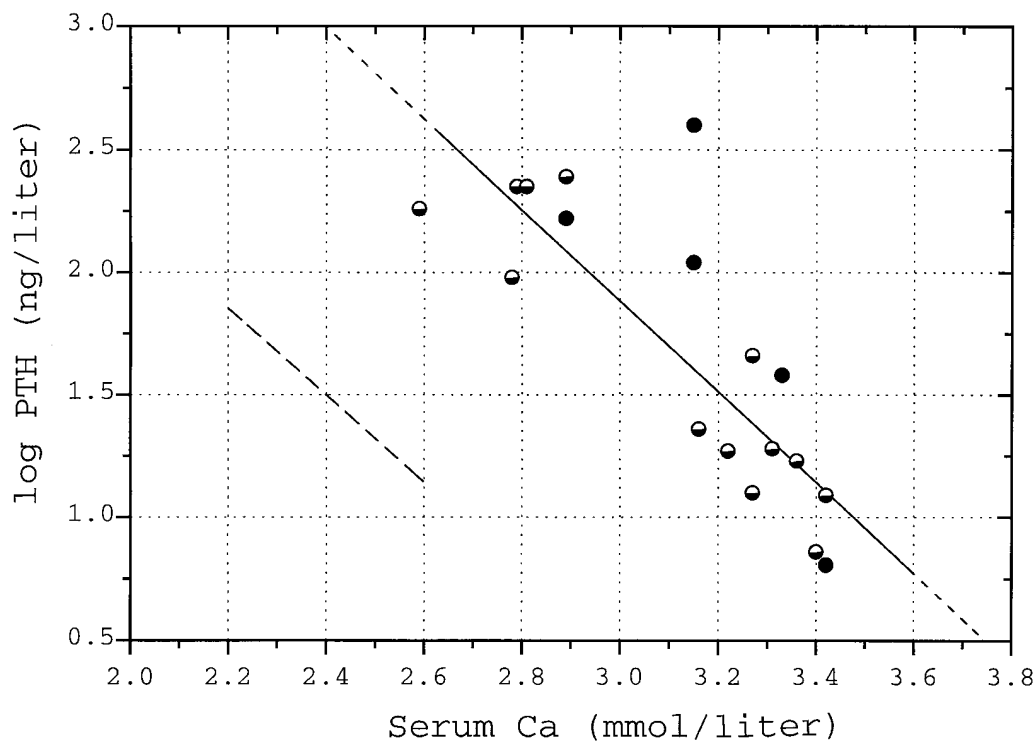
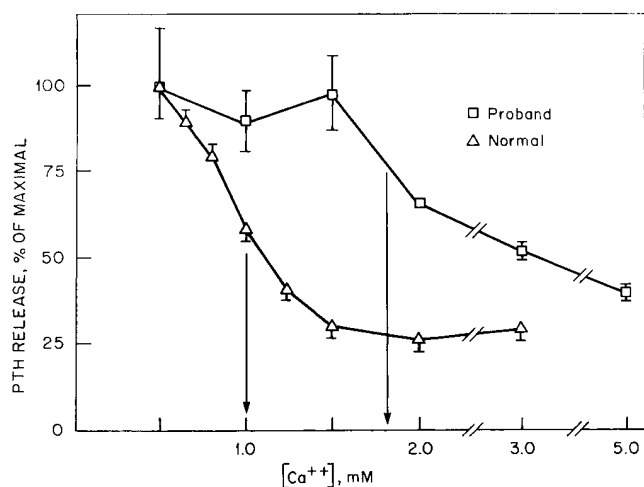


Figure 3. Relationship between the proband's serum total calcium concentration and circulating intact PTH levels. Samples were drawn both before (closed circles) and after partial parathyroidectomy (half-filled circles) ( $\log \text{PTH} = 7.35 - 1.81 \times \text{Ca}$ ;  $n = 18$ ;  $r = -0.807$ ,  $P < 0.001$ ). Broken line indicates the relationship in normal control subjects.



**Figure 4.**  $\text{Ca}_o^{2+}$ -regulated intact PTH release in vitro from dispersed parathyroid cells prepared from the proband's resected parathyroid tissue. Dispersed parathyroid cells were prepared, incubated with varying levels of  $\text{Ca}_o^{2+}$  for 1 h, and intact PTH determined by immunoradiometric assay as described in Methods. Open triangles represent the mean  $\pm$  SEM for results obtained previously for normal human parathyroid glands prepared from several normal human parathyroid glands (59), while the open squares represent the mean  $\pm$  the range for either two or three separate incubations of parathyroid cells prepared from the proband's resected parathyroid glands. Note that the set-point for normal human parathyroid cells is  $\sim 1.0$  mM while that for the proband's parathyroid cells is  $\sim 1.8$  mM.

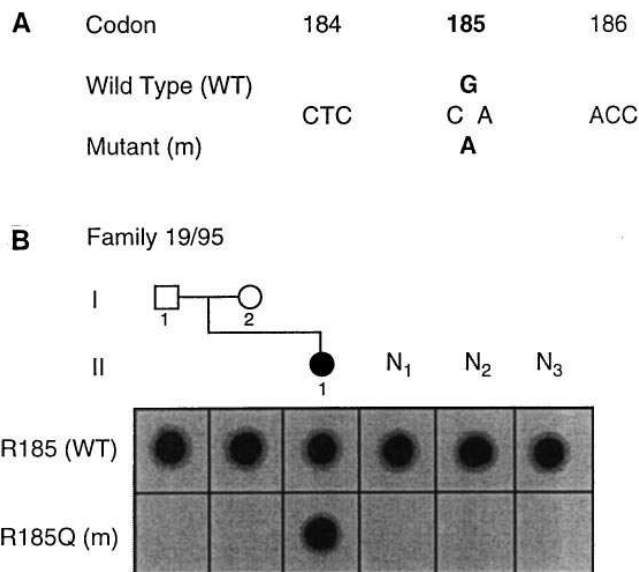
The high serum alkaline phosphatase, low phosphorus, high  $1,25(\text{OH})_2\text{D}$ , and low TmP before partial parathyroidectomy were interpreted, in retrospect, as evidence of secondary hyperparathyroidism with decreasing severity in an FBHH infant born to a normal (e.g., unaffected by FBHH) mother. The observed decrease in parathyroid size by ultrasound may have reflected diminishing secondary hyperparathyroidism.

Serum magnesium concentrations were elevated and correlated weakly with total serum calcium ( $\text{Mg}^{++} = 0.41 + 0.19 \times \text{Ca}^{++}$ ;  $n = 15$ ;  $r = 0.474$ ;  $P = 0.05\text{--}0.10$ ) as has been documented previously in patients with FBHH (13). The cause of the elevated calcitonin is perhaps the hypercalcemia per se.

**Family history.** The parents are healthy, normal by clinical examination and reportedly nonconsanguineous, and originate from the same area of Switzerland. The father is 30 and the mother 26 yr old. No inherited diseases are present in the parents' families. Laboratory findings in the mother (serum calcium 2.31, phosphorus 1.32, alkaline phosphatase 96, and PTH 11.9) and the father (serum calcium 2.50, phosphorus 1.19, alkaline phosphatase 44, and PTH 36.8) were normal on three separate occasions (only the first is shown here), excluding maternal hypo- or pseudohypoparathyroidism, and were not suggestive of FBHH.

#### Relationship between $\text{Ca}_o^{2+}$ and intact PTH in vivo and in vitro

Fig. 3 shows the inverse relationship between serum calcium concentration and circulating intact PTH levels at various times before and after subtotal parathyroidectomy. Relative to the relationship for normals, the patient exhibits a shift to the right in the relationship between  $\text{Ca}_o^{2+}$  and PTH by about 0.75 mM. Fig. 4 shows the relationship between  $\text{Ca}_o^{2+}$  and intact PTH release in vitro from dispersed parathyroid cells prepared

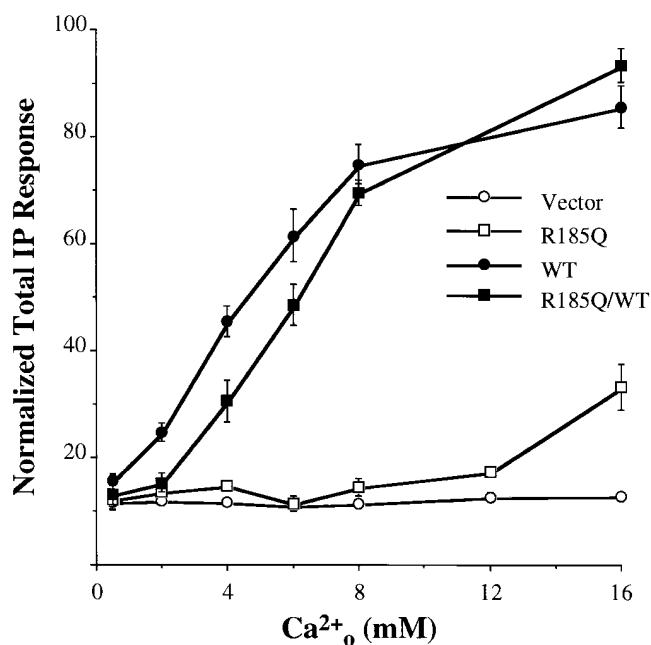


**Figure 5.** Missense mutation in exon 4 of the CaR gene in family 19/95. The symbols used for the pedigree members are as follows: open square—unaffected father; open circle—unaffected mother; filled circle—affected girl. The DNA sequence (A) shows a transition of the wild type (WT) G to the mutant (m) A at the second position of codon 185, which would result in a change from an arginine (R) to a glutamine (Q) residue. The presence of this mutation (R185Q) the proband (II-1) and its absence from 55 normocalcemic individuals (N1-3 shown) was demonstrated (B) by sequence specific oligonucleotide (SSO) hybridization analysis (35, 50) as it was not associated with an alteration of a restriction enzyme site. Thus the three unrelated normal individuals (N1-3) and the unaffected parents I-1 and I-2 were found to have only the wild type (WT) sequence (R185) and none of the mutant sequence (R185Q) and were, therefore, homozygous for the wild type sequence. However, the affected individual (II-1) has both the wild type and mutant sequence, demonstrating the heterozygosity of this de novo mutation.

from parathyroid tissue removed at the time of partial parathyroidectomy. The set-point for  $\text{Ca}_o^{2+}$ -regulated PTH release was about 1.8 mM, about 0.8 mM higher than the set-point for normal human parathyroid cells (1.0 mM) studied previously (53, 54; normal human parathyroid tissue was not available for concurrent analysis).

#### CaR mutational analysis

Analysis of the entire coding region of the CaR for single stranded conformational polymorphisms (SSCP) in DNA from the proband (subject II-1 in Fig. 5) revealed a single abnormal pattern of migration in the 5' fragment of exon 4. Subsequent DNA sequence analysis demonstrated a G to A transition at the second position of codon 185 (Fig. 5), predicting a change from arginine to glutamine (R185Q) within the CaR extracellular domain. This missense mutation was confirmed by SSO (Fig. 5); it was not found in genomic DNA from her normocalcemic parents (subjects I-1 and I-2 in Figure 5) either by direct DNA sequence analysis or SSO (Fig. 5). Nonpaternity was excluded by demonstrating sharing of alleles between father and daughter at five highly polymorphic genetic markers, D3S1267, D3S1303, D13S153, Rb1.20, and DXS1232 (51, 52), thereby demonstrating that this was a de novo heterozygous mutation in the proband. This mutation was not present



**Figure 6.** Ca<sup>2+</sup><sub>o</sub>-regulated total inositol phosphates (IPs) in HEK293 cells transiently transfected with the wild type human CaR (wt) alone, a receptor harboring the proband's R185Q mutation alone (R185Q), or both receptors (R185Q/wt), and in mock-transfected HEK293 cells (293). Mutagenesis of the wild type human CaR to produce the R185Q mutation, transient transfection of HEK293 cells, and determination of the effects of Ca<sup>2+</sup><sub>o</sub> on total inositol phosphates (a measure of the total turnover of phosphoinositides by phospholipase C) in cells prelabeled with [<sup>3</sup>H]inositol were performed as described in Methods. Note that the mutant receptor is markedly less responsive to Ca<sup>2+</sup><sub>o</sub> than the wild type (wt) CaR and that coexpression of the WT and mutant CaRs shifts the EC<sub>50</sub> for the wt to the right by 37%.

in 55 unrelated normocalcemic individuals analyzed by SSO; thus it is not a common polymorphism.

#### *Effect of the mutation on high Ca<sup>2+</sup><sub>o</sub>-elicited accumulation of IPs*

To explore the functional impact of the proband's heterozygous R185Q mutation, we compared its capacity to mediate Ca<sup>2+</sup><sub>o</sub>-elicited, phospholipase C (PLC)-dependent increases in cellular levels of inositol phosphates with that of the wild type CaR when transiently expressed in HEK293 cells. Expression of the WT CaR conferred 5–10-fold increases in total IPs at high levels of Ca<sup>2+</sup><sub>o</sub>, with half of the maximal increase in IPs at 4.6±0.3 mM Ca<sup>2+</sup><sub>o</sub> (Fig. 6). In contrast, nontransfected cells showed no alterations in IPs at any concentration of Ca<sup>2+</sup><sub>o</sub> tested, while the mutant receptor showed a marked increase in the Ca<sup>2+</sup><sub>o</sub> level required to elicit increases in IPs. Since in this patient FBHH was caused by the presence of this mutation in the heterozygous state, we also assessed the relationship between Ca<sup>2+</sup><sub>o</sub> and IPs in HEK293 cells cotransfected with equal amounts (0.156 μg) of the cDNAs for the wild type and mutant receptors. Fig. 6 shows that there is nearly a 37% increase in the EC<sub>50</sub> for stimulation of the accumulation of IPs by Ca<sup>2+</sup><sub>o</sub> in the cotransfected cells (EC<sub>50</sub> = 6.3±0.4 mM; n = 6) relative to those transfected with wild type receptor alone (EC<sub>50</sub> = 4.6±0.3 mM; n = 6; P < 0.05; a total of six separate transfections in three experiments carried out on three different days).

## Discussion

In the present study we report *in vivo* and *in vitro* studies in an infant who presented with the clinical syndrome of NHPT and subsequently, following partial parathyroidectomy, reverted to a more benign form of hypercalcemia, FBHH. This case represents the third well documented example of a *de novo* heterozygous mutation in the Ca<sup>2+</sup><sub>o</sub>-sensing receptor gene as a cause of NHPT (35) and provides considerable insight into the mechanisms through which this CaR mutation contributed to the relatively severe clinical phenotype in this patient.

Genetic analysis of the proband and her parents excluded nonpaternity and documented that hypercalcemia resulted from a *de novo* mutation in one allele of the CaR, with a G to A transition in the second position of codon 185 substituting a glutamine for the normal arginine within the CaR extracellular domain. Most of the mutations causing FBHH that have been described to date have been missense mutations falling within two general regions of the receptor. About two-thirds are within the first 300 amino acids of the extracellular domain, while the remaining one-third are just proximal to the first transmembrane segment or within the transmembrane segments and intra- or extracellular loops (30–35, 37). In a few cases other forms of mutations have also been identified. Pearce et al. described a nonsense mutation at codon 607 predicting a receptor protein truncated just proximal to the first membrane-spanning segment that would presumably be inactive (35). The same group also identified a single base deletion accompanied by a nucleotide transition at an adjacent position in codon 747 of the CaR, which would cause a frame shift leading to premature termination of the receptor protein at codon 776 (35). Finally, Janicic et al. described several families from Nova Scotia, Canada, in whom affected family members have the insertion of an alu sequence at codon 876 within the predicted carboxyl-terminal tail of the receptor (34, 60).

While the mechanisms through which the FBHH mutations described to date cause reduced activity of the receptor are not well understood, recent studies in which these mutant CaRs were expressed in HEK293 cells have provided some insights in this regard (56). Of the three mutations that cause truncated receptors, two are inactive, exhibiting essentially no high Ca<sup>2+</sup><sub>o</sub>-evoked increases in Ca<sub>i</sub> (the frame shift mutation at codon 747 [61] and the alu insertion [M. Bai, N. Janicic, E.M. Brown, and G.N. Hendy, unpublished observations]). Western analysis confirms that truncated (albeit biologically inactive) receptor proteins are in fact produced. A few missense mutations, although permitting production of a full-length, nonglycosylated, initial biosynthetic product, are not processed to the fully mature glycosylated form of CaR that most likely resides on the cell surface and show severe reductions in biological activity (56). Most of the missense mutations, on the other hand, including R185Q, appear to reach the cell surface in a form that is similar in size and degree of glycosylation to that of the wild type receptor, at least as assessed by Western analysis (56). Additional studies will be needed to document directly that these mutant CaRs are expressed on the cell surface. Some of the mutant receptors show only modest reductions in apparent affinity for Ca<sup>2+</sup><sub>o</sub> and other CaR agonists (e.g., Gd<sup>3+</sup>). These mutations may interfere with the capacity of the respective receptors to bind ligand (if present in the extracellular domain) or, perhaps, to couple to G-protein(s) and initiate intracellular signaling (i.e., R795W, which is within the third

intracellular loop and likely interferes with the coupling of the CaR to its G protein(s) [30, 56].

Of interest, the same R185Q mutation identified in the present proband has been described previously (30) in a U.S. kindred (family A in Marx et al. [3]). Indeed, two neonates in one branch of this family presented with NHPT. Affected family members, in general, have a degree of hypercalcemia (a mean of 3.08 mM with a range of 2.72–3.43 mM; 3) that is similar to that of our proband and more severe than encountered in most FBHH kindreds.

What are the factors determining the degree of severity of hypercalcemia in individuals with heterozygous FBHH mutations? Of note, patients with mutations producing the most severe functional defects, such as E297K, R66C, G143E (56), and the nonsense mutation just proximal to the first transmembrane domain (35), have very mild hypercalcemia. These cases in effect represent null mutations (e.g., no functional protein is produced by the abnormal allele) and are similar in this regard to the mice that have recently been developed with targeted disruption of the CaR gene (62). Heterozygous mice have ~50% reductions in CaR protein in parathyroid and kidney as assessed by immunohistochemistry and Western analysis, respectively, and exhibit mild, ~10% increases in serum calcium concentration (61). It is likely in these mice and in humans with “null” mutations that the hypercalcemia is solely due to reduction in the level of expression of the receptor from the normal allele (i.e., a gene dosage effect).

In families with more severe hypercalcemia in affected heterozygous individuals, as in those with the R185Q mutation, on the other hand, there appears to be a dominant negative effect, where the abnormal receptor interferes in some way with the function of the normal receptor. In the present study, using  $\text{Ca}_o^{2+}$ -induced changes in inositol phosphates as the readout, HEK293 cells cotransfected with both wild type and mutant receptors showed an increase in  $\text{EC}_{50}$  relative to that observed with transfection of the wild type receptor alone. A similar shift in  $\text{EC}_{50}$  was observed previously when we studied  $\text{Ca}_o^{2+}$ -elicited changes in  $\text{Ca}_i$  in HEK cells cotransfected with wild type receptor and the mutant receptor harboring the R185Q mutation (56, 63). This result suggests that the abnormal receptor interferes in some manner with the function of the normal receptor. We have not yet identified how this putative interference takes place. It might involve mechanisms such as (a) a reduced quantity of normal receptor reaching the cell surface, (b) sequestration of G proteins by the abnormal receptor thereby limiting the capacity of the wild type receptor to initiate intracellular signaling, or (c) direct, cell surface interactions between normal and abnormal receptors that inhibit the activity of the former. Further studies will be necessary to distinguish among these possibilities.

An additional factor that may have contributed to the severity of the initial clinical presentation in the present case is that a child with abnormal parathyroid set-point for  $\text{Ca}_o^{2+}$ -regulated PTH release was gestated in a normal mother. There is normally about a 0.25 mM gradient in  $\text{Ca}_o^{2+}$  between maternal and fetal blood, with the latter greater than the former, because of the placental calcium pump. If the set-point of the fetal parathyroids is increased, the fetus will sense  $\text{Ca}_o^{2+}$  in cord blood as abnormally low, thereby producing some degree of secondary hyperparathyroidism on top of the already abnormal set-point of the fetal parathyroids. This hypothesis is borne out by the observation that in all 10 of the reported

cases of NHPT in children with one FBHH parent the affected parent has been the father (3, 7, 14–18). Indeed, patient A-26 in the kindred with the same R185Q mutation (30) as in our patient inherited the abnormal CaR allele from her father and was born to a healthy mother (3). She presented with neonatal hyperparathyroidism and had a serum calcium of 3.47 mM. She subsequently underwent total parathyroidectomy at 2 wk of age, and the four resected glands were enlarged and showed clear cell hyperplasia. The presence of an FBHH fetus in a normal mother would be analogous to the severe secondary (albeit normocalcemic) hyperparathyroidism that can be observed in normal infants born to hypocalcemic mothers with hypoparathyroidism or pseudohypoparathyroidism (64, 65). The latter situation may be associated with severe hyperparathyroid bone disease in the early postnatal period but usually improves gradually over time as the fetal calcium concentration is no longer regulated to a significant extent by the maternal mineral ion homeostatic system. In an analogous fashion, our proband showed an improvement in her intact PTH level postnatally, due to partial parathyroidectomy and/or rather the natural history of this condition. The levels of PTH were still markedly elevated postoperatively, however, and only gradually returned to steady state levels within the normal range characteristic of FBHH. At this point her biochemical findings were similar to the previously described family (3) with the R185Q mutation (30).

In summary, we have described a child with a de novo heterozygous missense mutation in the  $\text{Ca}_o^{2+}$ -sensing receptor presenting in the neonatal period as NHPT, who subsequently reverted to a biochemical picture more characteristic of FBHH. The more severe hypercalcemia and secondary hyperparathyroidism in this case, relative to other cases in which a child with FBHH is born to a normal mother, most likely relates to the dominant negative effect of this particular mutation on the function of the normal CaR. It will be of interest to determine to what extent previous cases of NHPT which did not appear to represent cases of homozygous FBHH are the result of a similar scenario, where the nature of the specific mutation impacts on the level of serum calcium and/or PTH level. Alternatively, there may be additional, yet-to-be-discovered factors accounting for the relatively wide spectrum of severity in the clinical presentation of NHPT.

## Acknowledgments

We thank Dr. P. Trost for referral of the patient as well as Drs. U. Willi and G. Eich (Division of Radiology, University Children's Hospital) and Drs. T. Stallmach and M.A. Spycher (Department of Pathology, University of Zurich) for their help.

The authors gratefully acknowledge the following grant support: from the U.S. Public Health Service (DK41415 to E.M. Brown, DK44588 to E.M. Brown and O. Kilfor, DK46422 and DK48330 to E.M. Brown and DK09436 to M. Bai), the St. Giles Foundation (to E.M. Brown), NPS Pharmaceuticals, Inc. (to E.M. Brown), the Medical Research Council (to S.H.S. Pearce and R.V. Thakker), and the Swiss National Science Foundation, grant 32-42198.94 (to B. Steinmann).

## References

1. Pratt, E., B. Geren, and E. Neuhauser. 1947. Hypercalcemia and idiopathic hyperplasia of the parathyroid glands in an infant. *J. Pediatr.* 30:388–399.
2. Heath, D. 1994. Familial hypocalciuric hypercalcemia. *In* The Parathy-



- roids. J. Bilezikian, R. Marcus, and M. Levine, editors. Raven Press, New York. 699-710.
3. Marx, S., M. Attie, A. Spiegel, M. Levine, R. Lasker, and M. Fox. 1982. An association between neonatal severe primary hyperparathyroidism and familial hypocalciuric hypercalcemia in three kindreds. *N. Engl. J. Med.* 306:257-284.
  4. Landon, J. 1932. Parathyroidectomy in generalized osteitis fibrosa cystica. *J. Pediatr.* 1:544-560.
  5. Goldbloom, R., D. Gillis, and M. Prasad. 1972. Hereditary parathyroid hyperplasia. A surgical emergency of early infancy. *Pediatrics.* 49:514-523.
  6. Hillman, D., C. Sriver, S. Pedvis, and I. Shragovitch. 1964. Neonatal familial primary hyperparathyroidism. *N. Engl. J. Med.* 270:483-490.
  7. Spiegel, A., H. Harrison, S. Marx, E. Brown, and G. Aurbach. 1977. Neonatal primary hyperparathyroidism with autosomal dominant inheritance. *J. Pediatr.* 90:269-272.
  8. Foley, T., H. Harrison, C. Arnaud, and H. Harrison. 1972. Familial benign hypercalcemia. *J. Pediatr.* 81:1060-1067.
  9. Law, W.J., and H. Heath III. 1985. Familial benign hypercalcemia (hypocalciuric hypercalcemia). Clinical and pathogenetic studies in 21 families. *Ann. Intern. Med.* 105:511-519.
  10. Fujita, T., N. Watanabe, M. Fukase, M. Tsutsumi, T. Fukami, Y. Imai, K. Sakaguchi, S. Okada, M. Matsuo, and H. Takemine. 1983. Familial hypocalciuric hypercalcemia involving four members of a kindred including a girl with severe neonatal primary hyperparathyroidism. *Min. Electrolyte Metab.* 9:51-54.
  11. Marx, S., D. Fraser, and A. Rapoport. 1985. Familial hypocalciuric hypercalcemia. Mild expression of the disease in heterozygotes and severe expression in homozygotes. *Am. J. Med.* 78:15-22.
  12. Steinmann, B., H. Gnehm, V. Rao, H.P. Kind, and A. Prader. 1984. Neonatal severe primary hyperparathyroidism and alkaptonuria in a boy born to related parents with familial hypocalciuric hypercalcemia. *Helv. Paediatr. Acta.* 39:171-186.
  13. Marx, S.J., M.F. Attie, M.A. Levine, A.M. Spiegel, R.W. Downs, and R.D. Lasker. 1981. The hypocalciuric or benign variant of familial hypercalcemia: clinical and biochemical features in fifteen kindreds. *Medicine (Baltimore).* 60:397-412.
  14. Thompson, N., L. Carpenter, D. Kessler, and R. Nishiyama. 1978. Hereditary neonatal hyperparathyroidism. *Arch. Surg.* 113:100-103.
  15. Page, L., and J. Haddow. 1987. Self limited neonatal hyperparathyroidism in familial hypocalciuric hypercalcemia. *J. Pediatr.* 111:261-264.
  16. Wilkinson, H., and J. James. 1993. Self limited neonatal hyperparathyroidism associated with familial hypocalciuric hypercalcemia. *Arch. Dis Child.* 69:319-321.
  17. Fujimoto, Y., H. Hazama, K. and K. Oku. 1990. Severe primary hyperparathyroidism in a neonate having a parent with hypercalcemia: treatment by total parathyroidectomy and simultaneous heterotopic autotransplantation. *Surgery.* 108:933-938.
  18. Sopwith, A., C. Burns, D. Grant, G. Taylor, E. Wolf, and G. Besser. 1984. Familial hypocalciuric hypercalcemia: association with neonatal primary hyperparathyroidism and possible linkage with HLA haplotypes. *Clin. Endocrinol.* 21:57-64.
  19. Fretheim, B., and O. Gardborg. 1965. Primary hyperparathyroidism in an infant. *Acta Chir Scand.* 129:557-566.
  20. Randall, C., and S. Lauchlan. 1963. Parathyroid hyperplasia in an infant. *Am. J. Dis Child.* 105:364-367.
  21. Bradford, W., J. Wilson, and J. Gaede. 1973. Primary neonatal hyperparathyroidism—an unusual cause of failure to thrive. *Am. J. Clin. Pathol.* 59:267-275.
  22. Rhone, D. 1975. Primary neonatal hyperparathyroidism. Report of a case and review of the literature. *Am. J. Clin. Pathol.* 64:488-499.
  23. Ch'ng, J., A. Kaiser, J. Lynn, and G. Joplin. 1984. Post-parathyroidectomy restoration of normal calcium homeostasis in neonatal primary hyperparathyroidism. *Acta Endocrinol.* 105:350-353.
  24. Dezetaux, C., J. Hyde, H. Hoey et al. 1984. Neonatal hyperparathyroidism. *Eur. J. Pediatr.* 142:135-136.
  25. Meeran, K., M. Husain, M. Puccini, H. Scott, C. Dionisi-Vici, D.R. Harvey, J. Lynn, and R.V. Thekker. 1994. Neonatal primary hyperparathyroidism masked by vitamin D deficiency. *Clin. Endocrinol.* 41:531-534.
  26. Harris, S., and A. D'Ercole. 1989. Neonatal hyperparathyroidism: the natural course in the absence of surgical intervention. *Pediatrics.* 83:53-56.
  27. Chou, Y.-H., E. Brown, T. Levi, G. Crowe, A. Atkinson, H. Arnqvist, G. Toss, G.E.-H. Fuleihan, J. Seidman, and C.E. Seidman. 1992. The gene responsible for familial hypocalciuric hypercalcemia maps to chromosome 3 in four unrelated families. *Nature Genet.* 1:295-300.
  28. Heath, H., C. Jackson, B. Otterud, and M. Leppert. 1993. Genetic linkage analysis of familial benign (hypocalciuric) hypercalcemia: evidence for locus heterogeneity. *Am. J. Hum. Genet.* 53:193-200.
  29. Trump, D., M. Whyte, C. Wooding, J. Pang, S. Pearce, D. Kocher, and R. Thakker. 1995. Linkage studies in a kindred from Oklahoma with familial benign (hypocalciuric) hypercalcemia and developmental elevations in serum parathyroid hormone levels, indicate a third locus for FHH. *Hum. Genet.* 96:183-187.
  30. Pollak, M., E. Brown, Y.-H. Chou, S. Hebert, S. Marx, B. Steinmann, T. Levi, C. Seidman, and J. Seidman. 1993. Mutations in the human  $Ca^{2+}$ -sensing receptor gene cause familial hypocalciuric hypercalcemia and neonatal severe hyperparathyroidism. *Cell.* 75:1297-1303.
  31. Chou, Y.-H., M. Pollak, M. Brandi, G. Toss, H. Arnqvist, A. Atkinson, S. Papapoulos, S. Marx, E. Brown, J. Seidman, and C. Seidman. 1995. Mutations in the human calcium-sensing receptor gene. *Am. J. Hum. Genet.* 56:1075-1079.
  32. Heath, H., III, S. Odelberg, C. Jackson, B. Teh, N. Hayward, C. Larson, N. Buist, K. Krapcho, B. Hung, I. Capuano, et al. 1996. Clustered inactivating mutations and benign polymorphisms of the calcium receptor gene in familial benign hypocalciuric hypercalcemia suggest receptor functional domains. *J. Clin. Endocrinol. Metab.* 81:1312-1317.
  33. Aida, K., S. Koishi, M. Inoue, M. Nakazato, M. Tawata, M., and Onaya. 1995. Familial hypocalciuric hypercalcemia associated with mutation in the human  $Ca^{2+}$ -sensing receptor gene. *J. Clin. Endocrinol. Metab.* 80:2594-2598.
  34. Janicic, N., Z. Pausova, D.E.C. Cole, and G.N. Hendy. 1995. Insertion of an alu sequence in the  $Ca^{2+}$ -sensing receptor gene in familial hypocalciuric hypercalcemia and neonatal severe hyperparathyroidism. *Am. J. Hum. Genet.* 56:880-886.
  35. Pearce, S., D. Trump, C. Wooding, G. Besser, S. Chew, D. Heath, I. Hughes, and R. Thakker. 1995. Calcium-sensing receptor mutations in familial benign hypercalcemia and neonatal hyperparathyroidism. *J. Clin. Invest.* 96:2683-2692.
  36. Brown, E., G. Gamba, D. Riccardi, D. Lombardi, R. Butters, O. Kifor, A. Sun, M. Hediger, J. Lytton, and S. Hebert. 1993. Cloning and characterization of an extracellular  $Ca^{2+}$ -sensing receptor from bovine parathyroid. *Nature (Lond.)* 366:575-580.
  37. Brown, E., M. Pollak, C. Seidman, J. Seidman, Y.-H. Chou, D. Riccardi, and S. Hebert. 1995. Calcium-ion-sensing cell-surface receptors. *New Engl. J. Med.* 333:234-240.
  38. Baron, J., K. Winer, J. Yanovski, A. Cunningham, L. Laue, D. Zimmerman, and G. Cutler, Jr. 1996. Mutations in the  $Ca^{2+}$ -sensing receptor gene cause autosomal dominant and sporadic hypoparathyroidism. *Hum. Mol. Genet.* 5:601-606.
  39. Pollak, M., E. Brown, H. Estep, P. McLaine, O. Kifor, J. Park, S. Hebert, C. Seidman, and J. Seidman. 1994. An autosomal dominant form of hypocalcemia caused by a mutation in the human  $Ca^{2+}$ -sensing receptor gene. *Nature Genet.* 8:303-308.
  40. Pearce, S., M. Coulthard, P. Kendall-Taylor, and R. Thakker. 1995. Autosomal dominant hypocalcaemia associated with a mutation in the calcium-sensing receptor. *J. Bone Mineral Res.* 10:S176 (Abstr. 149).
  41. Perry, Y., D. Finegold, M. Armitage, and R. Ferrell. 1994. A missense mutation in the Ca-sensing receptor causes familial autosomal dominant hypoparathyroidism. *Am. J. Hum. Genet.* 55(Suppl.):A17(Abstr.).
  42. Khosla, S., P.R. Ebeling, A.F. Firek, M.M. Burritt, P.C. Kao, and H. Heath III. 1993. Calcium infusion suggests a "set-point" abnormality of parathyroid gland function in familial benign hypercalcemia and more complex disturbances in primary hyperparathyroidism. *J. Clin. Endocrinol. Metab.* 76:715-720.
  43. Auwerx, J., M. Demedts, and R. Bouillon. 1984. Altered parathyroid set point to calcium in familial hypocalciuric hypercalcemia. *Acta Endocrinol.* 106:215-218.
  44. Brown, E., and S. Hebert. 1995. A cloned  $Ca^{2+}$ -sensing receptor: A mediator of direct effects of extracellular  $Ca^{2+}$  on renal function? *J. Am. Soc. Nephrol.* 6:1530-1540.
  45. Davies, M., P. Adams, and G. Lumb. 1984. Familial hypocalciuric hypercalcemia: Evidence for continued enhanced renal tubular reabsorption of calcium following total parathyroidectomy. *Acta Endocrinol.* 106:499-504.
  46. Attie, M., J.J. Gill, J. Stock, A. Spiegel, R. Downs, M. Levine, and S. Marx. 1983. Urinary calcium excretion in familial hypocalciuric hypercalcemia. *J. Clin. Invest.* 72:667-676.
  47. Estep, H., Z. Mistry, P. and P.K. Burke. 1981. Familial idiopathic hypocalcemia. In Proceedings and Abstracts of the 63rd Annual Meeting of the Endocrine Society. Cincinnati: Endocrine Society. 275(Abstr.).
  48. Davies, M., Z. Mughal, P. Selby, D. Tymms, E. and Mawer. 1995. Familial benign hypocalcemia. *J. Bone Miner. Res.* 10 (Suppl. 1):S507.
  49. Pollak, M., Y.-H. Chou, S. Marx, B. Steinmann, D. Cole, M. Brandi, S. Papapoulos, F. Menko, G. Hendy, E. Brown, et al. 1994. Familial hypocalciuric hypercalcemia and neonatal severe hypercalcemia: The effects of mutant gene dosage on phenotype. *J. Clin. Invest.* 93:1108-1112.
  50. Thakker, R., M. Pook, C. Wooding, M. Bocsarro, M. Scanarini, and R. Clayton. 1993. Association of somatotropinomas with loss of alleles on chromosome 11 and gsp mutations. *J. Clin. Invest.* 91:2815-2821.
  51. Yandell, D., and T. Dryja. 1989. Detection of genetic polymorphisms by enzymatic amplification and direct genomic sequencing. *Am. J. Hum. Genet.* 45:547-555.
  52. Gyapay, G., J. Morissette, A. Vignal, C. Dib, C. Fizames, P. Millasseau, S. Marc, G. Bernardi, M. Lathrop, and J. Weissenbach. 1994. The 1993-4 Gene-thon human genetic linkage map. *Nature Genet.* 7:246-249.
  53. LeBoff, M., D. Shoback, E. Brown, J. Thatcher, R. Lembruno, D. Beaudoin, M. Henry, R. Wilson, J. Pallotta, S. Marynick, et al. 1985. Regulation of parathyroid hormone release and cytosolic calcium by extracellular calcium in

- dispersed and cultured bovine and pathological human parathyroid cells. *J. Clin. Invest.* 75:49–57.
54. Brown, E., R. Wilson, J. Thatcher, and S. Marynick. 1981. Abnormal calcium-regulated PTH release in normal parathyroid glands from patients with an adenoma. *Am. J. Med.* 71:565–570.
55. Fuleihan, G., C. Chen, S. Rivkees, S. Marynick, J. Stock, J. Pallotta, and E. Brown. 1989. Calcium-dependent release of N-terminal fragments and intact immunoreactive parathyroid hormone by human pathological parathyroid tissue in vitro. *J. Clin. Endocrinol. Metab.* 69:860–867.
56. Bai, M., S. Quinn, S. Trivedi, O. Kifor, S. Pearce, M. Pollak, K. Krapcho, S. Hebert, and E. Brown. 1996. Expression and characterization of inactivating and activating mutations of the human  $\text{Ca}^{2+}$ -sensing receptor. *J. Biol. Chem.* 271:19537–19545.
57. Kunkel, T. 1985. Rapid and efficient site-specific mutagenesis without phenotype selection. *Proc. Natl. Acad. Sci. USA.* 82:488–492.
58. Kifor, O., I. Kifor, and E.M. Brown. 1992. Effects of high extracellular calcium concentrations on phosphoinositide turnover and inositol phosphate metabolism in dispersed bovine parathyroid cells. *J. Bone Miner. Res.* 7:1327–1335.
59. Brown, E., R.E. Wilson, R. Eastman, J. Pallotta, and S. Marynick. 1982. Abnormal regulation of parathyroid hormone release by calcium in secondary hyperparathyroidism due to chronic renal failure. *J. Clin. Endocrinol. Metab.* 54:172–179.
60. Janicic, N., Z. Pausova, D.E.C. Cole, and G. Hendy. 1995. *De novo* expansion of an alu insertion mutation of the  $\text{Ca}^{2+}$ -sensing receptor gene in familial hypocalciuric hypercalcemia and neonatal severe hyperparathyroidism. *J. Bone Miner. Res.* 10 (Suppl. 1):S191.
61. Pierce, S.H.S., M. Bai, S.J. Quinn, O. Kifor, E.M. Brown, and R.V. Thakker. 1996. Functional characterization of calcium-sensing receptor mutations expressed in human embryonic kidney cells. *J. Clin. Invest.* 98:1860–1866.
62. Ho, C., D.A. Conner, M. Pollak, D.J. Ladd, O. Kifor, H. Warren, E.M. Brown, C.E. Seidman, and J.G. Seidman. 1995. A mouse model for familial hypocalciuric hypercalcemia and neonatal severe hyperparathyroidism. *Nature Genet.* 11:389–394.
63. Steinmann, B., M. Bai, S. Pierce, R.V. Thakker, and E.M. Brown. 1996. Neonatal severe hyperparathyroidism due to a *de novo* heterozygous mutation in the extracellular calcium-receptor (CAR). *Am. J. Hum. Genet.* 59:A286.
64. Stewart, A., and A.E. Broadus. 1987. Mineral Metabolism. In *Endocrinology and Metabolism*. 2nd ed. P. Felig, J.D. Baxter, A.E. Broadus, and L.A. Frohman, editors. McGraw-Hill, Inc., New York. 1317–1453.
65. Aurbach, G., S. Marx, and A. Spiegel. 1985. Parathyroid hormone, calcitonin, and the calciferols. 7th ed. In *Textbook of Endocrinology*. J.D. Wilson and D. Foster, editors. W.B. Saunders, Philadelphia. 1137–1217.