

In vivo cyclooxygenase expression in synovial tissues of patients with rheumatoid arthritis and osteoarthritis and rats with adjuvant and streptococcal cell wall arthritis.

H Sano, T Hla, J A Maier, L J Crofford, J P Case, T Maciag, R L Wilder

J Clin Invest. 1992;**89**(1):97-108. <https://doi.org/10.1172/JCI115591>.

Research Article

Cyclooxygenase (COX), or prostaglandin (PG) H synthase, plays a role in inflammatory diseases, but very limited data exist on the regulation of COX in vivo. We, therefore, studied the in vivo expression of COX in synovia from patients with rheumatoid arthritis (RA) and osteoarthritis (OA), as well as joints of rats with streptococcal cell wall (SCW) and adjuvant arthritis. Extensive and intense intracellular COX immunostaining, which correlated with the extent and intensity of mononuclear cell infiltration, was observed in cells throughout RA synovia. Significantly less or equivocal staining was noted in OA and normal human synovia. Similarly, COX immunostaining was equivocal in the joints of normal and arthritis-resistant F344/N rats. In contrast, high level expression developed rapidly in euthymic female Lewis (LEW/N) rats throughout the hindlimb joints and overlying tissues including skin, preceding or paralleling clinically apparent experimental arthritis. COX was expressed in the joints of athymic LEW.rnu/rnu rats 2-4 d after injection of SCW or adjuvant but was not sustained. Physiological doses of antiinflammatory glucocorticoids, but not progesterone, suppressed both arthritis and COX expression in LEW/N rats. These observations suggest that, in vivo, (a) COX expression is upregulated in inflammatory joint diseases, (b) the level of expression is genetically controlled and is a biochemical correlate of disease severity, (c) sustained high level up-regulation is T cell dependent, and (d) [...]

Find the latest version:

<https://jci.me/115591/pdf>



In Vivo Cyclooxygenase Expression in Synovial Tissues of Patients with Rheumatoid Arthritis and Osteoarthritis and Rats with Adjuvant and Streptococcal Cell Wall Arthritis

Hajime Sano, Timothy Hla,* Jeanette A. M. Maier,* Leslie J. Crofford, John P. Case, Thomas Maciag,* and Ronald L. Wilder
Connective Tissue Section, Arthritis and Rheumatism Branch, National Institute of Arthritis and Musculoskeletal and Skin Disease, National Institutes of Health, Bethesda, Maryland 20892; and *Laboratory of Molecular Biology, Jerome H. Holland Laboratory for the Biomedical Sciences, American Red Cross, Rockville, Maryland 20855

Abstract

Cyclooxygenase (COX), or prostaglandin (PG) H synthase, plays a role in inflammatory diseases, but very limited data exist on the regulation of COX in vivo. We, therefore, studied the in vivo expression of COX in synovia from patients with rheumatoid arthritis (RA) and osteoarthritis (OA), as well as joints of rats with streptococcal cell wall (SCW) and adjuvant arthritis. Extensive and intense intracellular COX immunostaining, which correlated with the extent and intensity of mononuclear cell infiltration, was observed in cells throughout RA synovia. Significantly less or equivocal staining was noted in OA and normal human synovia. Similarly, COX immunostaining was equivocal in the joints of normal and arthritis-resistant F344/N rats. In contrast, high level expression developed rapidly in euthymic female Lewis (LEW/N) rats throughout the hindlimb joints and overlying tissues including skin, preceding or paralleling clinically apparent experimental arthritis. COX was expressed in the joints of athymic LEW.rnu/rnu rats 2–4 d after injection of SCW or adjuvant but was not sustained. Physiological doses of antiinflammatory glucocorticoids, but not progesterone, suppressed both arthritis and COX expression in LEW/N rats. These observations suggest that, in vivo, (a) COX expression is upregulated in inflammatory joint diseases, (b) the level of expression is genetically controlled and is a biochemical correlate of disease severity, (c) sustained high level up-regulation is T cell dependent, and (d) expression is down-regulated by antiinflammatory glucocorticoids. (*J. Clin. Invest.* 1992; 89:97–108.) Key words: dexamethasone • glucocorticoids • Lewis rats • prostaglandins • prostaglandin H synthase

Introduction

Exaggerated and dysregulated biosynthesis of prostaglandins (PGs), particularly PGE₂, by synovial tissues is widely considered to play a role in the erosion of cartilage and juxtaarticular

bone in rheumatoid arthritis (RA)¹ (1, 2). Cyclooxygenase (COX), or PGH synthase (E.C. 1.14.99.1), the first enzyme of the pathway in which arachidonic acid is oxidized to PGs, is usually described as the rate-limiting step in PG production (3). Use of COX inhibitors (nonsteroidal antiinflammatory drugs) in the treatment of RA is universal and further illustrates the perceived importance of this enzyme (4). These drugs also have powerful antiinflammatory effects on experimental models of arthritis (5). To understand the pathogenesis of inflammatory joint and other inflammatory diseases, mechanisms regulating the expression of this enzyme must be defined. Although the regulation of COX has been studied extensively in vitro (3), often with conflicting results, few studies have addressed the regulation of COX expression in vivo (6). We have, therefore, studied the in vivo expression of COX in synovial tissues of patients with RA and osteoarthritis (OA) and in the joints of rats with streptococcal cell wall (SCW) and adjuvant arthritis (AA). Our data provide potentially important insights into the regulation of COX in vivo and its role in inflammatory joint diseases.

Methods

Human tissue specimens. Synovial specimens were obtained intraoperatively from the knees of patients with RA, OA, or a traumatic injury at time of arthroscopic biopsy or total joint replacement. All 19 patients with RA met the 1987 revised criteria for the classification of RA (7). No attempt was made to segregate RA or OA patients on basis of duration of disease or clinically assessed disease activity. The specimens were preserved in 10% formalin, embedded in paraffin, and sectioned (6 μ m) onto gelatin-coated slides.

SCW and AA. Euthymic, virus-antibody-free, inbred euthymic female Lewis (LEW/N) and F344/N female rats were obtained from Harlan Sprague Dawley, Inc., Indianapolis, IN, and congenitally athymic nude LEW.rnu/rnu rats were obtained from the Small Animal Section, Veterinary Resources Branch, National Institutes of Health, Bethesda, MD. The rats were housed in cages with filter tops (Lab Products Inc., Maywood, NJ) in an environment free of known microbial pathogens. They were ~ 6 wk old and weighed 80–100 g at the initiation of each experiment. The preparation of cell wall peptidoglycan-polysaccharide fragments from group A streptococci and the induction of polyarthritis in LEW/N female rats were done as described in detail previously (8, 9). Briefly, a sterile aqueous suspension of soni-

Dr. Case's current address is Department of Pharmacology, M-036, School of Medicine and Center for Molecular Genetics, University of California at San Diego, La Jolla, CA 92093.

Address reprint requests to Dr. Wilder, Building 10, Room 9N240, National Institute of Arthritis and Musculoskeletal and Skin Diseases, National Institutes of Health, Bethesda, MD 20892.

Received for publication 20 December 1990 and in revised form 11 July 1991.

1. **Abbreviations used in this paper:** AA, adjuvant arthritis; COX, cyclooxygenase; EGF, epidermal growth factor; H&E, hematoxylin and eosin; HBGF-1, heparin binding growth factor-1; OA, osteoarthritis; PDGF, platelet-derived growth factor; PLA₂, phospholipase A₂; SCW, streptococcal cell wall; TGF, transforming growth factor; TNF, tumor necrosis factor.

cated SCW fragments in PBS, pH 7.4, was injected intraperitoneally into rats at a dose equivalent to 20 μ g of cell wall rhamnose per gram of body weight. This dose has been shown previously to induce acute and chronic polyarthritis in LEW/N female rats, and acute, but not chronic, polyarthritis in athymic nude LEW.rnu/rnu rats with 100% incidence. Relatively arthritis-resistant F344/N female rats were also injected. Rats injected with SCW (day 0) were killed in pairs at days 1–4 and 28, respectively. AA was induced in female LEW/N rats and clinically scored as described (10). 200 μ l of a suspension of pulverized *Mycobacterium butyricum* (Difco Laboratories, Inc., Detroit, MI) at 10 mg/ml in mineral oil (paraffin oil, heavy; Fisher Scientific Co., Pittsburgh, PA) were injected intradermally in 25- μ l aliquots in eight different locations, four on each side, of the cervical/periscapular region with a 25-gauge needle while the animals were under light anesthesia (day 0). Athymic LEW.rnu/rnu and arthritis-resistant F344/N rats, which do not develop clinically apparent AA, were also injected with the adjuvant suspension. Rats injected with adjuvant (day 0) were killed in pairs at 2-d intervals through the preclinical stages of disease until the development of maximal clinical arthritis (day 18). Hindfoot specimens were preserved in 10% formalin, decalcified in EDTA, embedded in paraffin, and sectioned (6 μ m) onto gelatin-coated microscope slides.

Glucocorticoid treatment of AA LEW/N rats. On the day of injection of adjuvant (day 0), the LEW/N rats were implanted intraperitoneally with Alzet No. 2002 mini-osmotic pumps (Alza Corp., Palo Alto, CA) as described by Lorberbaum-Galski et al. (11) containing dexamethasone (Sigma Chemical Co., St. Louis, MO) dissolved in 10% ethanol/90% normal saline at 0.167 mg/ml which was calculated to deliver 0.02 μ g/g body weight per d. Control rats were implanted with pumps containing vehicle alone. Rats in each group were assessed for arthritis and killed in pairs on days 4, 8, and 12 (as well as at day 0). The tissues were processed for immunohistology and hematoxylin and eosin (H & E) staining as described above.

Treatment of acute SCW arthritis LEW/N rats with glucocorticoids or progesterone. Beginning on the day of SCW (day 0) injection, the LEW/N rats were injected intraperitoneally with 1 ml of PBS containing 2% DMSO and progesterone (0.025 or 0.25 μ g/g body weight, Sigma Chemical Co.) or dexamethasone (0.005, 0.025, or 0.05 μ g/g body weight, Sigma Chemical Co.) twice a day. Control rats were injected with vehicle alone (PBS with 2% DMSO). Rats in each group were assessed for arthritis and killed at day 3. Tissues were processed for immunohistology and H & E staining as described above.

COX antibody preparation and characterization. Antiserum to ovine COX was produced in rabbits as previously described (12). The IgG fraction of antiserum was purified by absorption to Protein A-Sepharose CL-4B (Pharmacia LKB Biotechnology, Uppsala, Sweden) and elution with 0.1 M acetic acid in 0.15 M NaCl. The eluted proteins were neutralized and dialyzed against PBS. The antibody was further characterized by Western blot analysis as follows. Purified COX (10 ng per lane) was run on a 7% polyacrylamide gel under nonreducing conditions. Proteins were transferred electrophoretically to a nitrocellulose membrane (0.2 μ m pore size; Schleicher & Schuell, Inc., Keene, NH) in transfer buffer (25 mM Tris-HCl, pH 7.4, 200 mM glycine, 0.02% [wt/vol] SDS, 20% [vol/vol] methanol) for 2 h at 400 mA as described (13). The filter was blocked by incubation for 1 h in 50 mM Tris-HCl, pH 7.4 (TBS), containing 150 mM NaCl and 5% BSA. The blot was incubated with either 2 μ g/ml of anti-COX IgG or anti-COX IgG preincubated for 1 h with 50 ng of purified COX in TBS containing 5% BSA. After washing four times in TBS with 0.05% Triton X-100, the filter was incubated with alkaline phosphatase-conjugated anti-rabbit IgG and with 5-bromo-4-chloro-3-indolyl phosphate/nitro blue tetrazolium (Promega Biotech, Madison, WI) according to the manufacturer's instruction.

The specificity of the IgG anti-COX was further confirmed by absorption on purified ram seminal COX (Oxford Biomedical Research, Oxford, MI) coupled to cyanogen bromide-activated Sepharose 4B (Sigma Chemical Co.) (14). COX antibody was added to the COX-Sepharose conjugate and incubated at room temperature for 2 h. The

suspension was packed in a 0.7 \times 4-cm column and washed with phosphate buffer (20 mM sodium phosphate, pH 7.3, with 0.5 M NaCl) until the OD₂₈₀ returned to base line. The unbound IgG (affinity-negative) was devoid of anti-COX activity. The antibody bound to the affinity column was eluted with thiocyanate buffer (3 M KSCN with 0.5 M ammonium hydroxide) and dialyzed against several changes of cold PBS. This affinity-purified IgG anti-COX was highly reactive in western blot analysis and immunohistochemistry (see below).

Immunohistochemistry. Immunoperoxidase staining with Vectastain ABC kit (Vector Laboratories, Inc., Burlingame, CA) followed the manufacturer's suggested protocol (15). All procedures were performed at room temperature. The sections were deparaffinized and endogenous peroxidase activity was exhausted by incubating in 0.3% peroxide in methanol for 45 min. The sections were preincubated with 0.1% BSA in PBS for 20 min and with diluted goat serum (1:66.7) for 20 min followed by incubation in a humid chamber with anti-COX antibody 50–75 μ g/ml, purified normal rabbit IgG (50–75 μ g/ml, Jackson ImmunoResearch Laboratories, Inc., West Grove, PA), or anti-COX antibody absorbed with COX-Sepharose conjugate. After 30–40 min, the sections were washed in PBS and incubated with biotinylated goat anti-rabbit IgG for 30 min, the sections were further washed with PBS and incubated with an avidin and biotinylated horseradish peroxidase complex for 45 min. Finally, the sections were washed and color was developed by immersing the sections in a solution of 0.05% wt/vol 3,3-diaminobenzidine tetrahydrochloride (Sigma Chemical Co.), 0.04% wt/vol nickel chloride, and 0.01% hydrogen peroxide in 0.05 M Tris, pH 7.4, for 2–7 min. The sections were counterstained with 0.5% light green SF (Roboz Surgical Instrument Co. Inc., Washington, DC). Positive staining was indicated by brownish-black deposits, and background staining was green. In all cases, control stains with rabbit IgG or anti-COX antibody absorbed with COX-Sepharose conjugate were negative.

For each tissue specimen, the extent and intensity of staining with COX antibody was graded on a scale of 0–4+ by a blinded observer on two separate occasions using coded slides and an average score calculated. This methodology is identical to methodology employed in earlier studies from our laboratories (16). Specifically, the observer assessed all tissue on the slides to assign the scores. Thus, a 4+ grade implies that all staining was maximally intense throughout the specimen; 0 implies that staining was absent throughout the specimen. Particular attention was also given to the histological structures that stained most intensely. Mononuclear cell infiltration was assessed similarly on H & E-stained sections cut from the same paraffin blocks used for antibody staining. Thus, a 4+ grade implies that all tissues were intensely infiltrated with mononuclear cells; 0 implies that mononuclear cell infiltration was absent throughout.

Statistical analysis. Analyses of data were performed using the Wilcoxon rank-sum test and Spearman's rank correlation (17).

Results

COX immunostaining on synovial tissues from patients with RA and OA. To study COX protein expression, we utilized the polyclonal antiserum raised against the purified ovine seminal

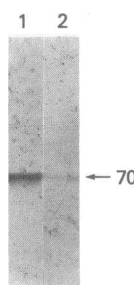


Figure 1. Western blot analysis of anti-COX antibody. Purified COX (10 ng per lane) was run on 7% polyacrylamide gel under nonreducing conditions. Protein was transferred electrophoretically to a nitrocellulose membrane as described in Methods. The blot was incubated with 2 μ g/ml of anti-COX IgG (lane 1) or anti-COX IgG preincubated with 50 ng of purified COX (lane 2), and visualized with the alkaline phosphatase reagent and 5-bromo-4-chloro-3-indolyl phosphate/nitro blue tetrazolium. Molecular mass marker is shown in kilodaltons.

vesicle COX (12). The IgG fraction of anti-COX antibody was used to immunohistochemically stain synovia from patients with RA and OA. Western blot analysis of the purified COX antibody confirmed that the COX antibody recognized the purified ovine COX (70 kD; lane 1 in Fig. 1). The reactivity of COX antibody was inhibited by preincubation of the antibody with purified COX (lane 2). As shown in a representative syno-

vial tissue section, diffuse and intense intracellular staining was observed within the synovial lining cell layer (Fig. 2, *A* and *C*). Prominent cytoplasmic COX staining was also observed in the sublining stromal fibroblast-like cells (Fig. 2, *A*, *C*, and *D*), vascular endothelial cells (Fig. 2 *D*) and mononuclear inflammatory cells (Fig. 2, *A*, *C*, and *D*). Control immunostaining with anti-COX antibody preabsorbed with COX-Sepharose

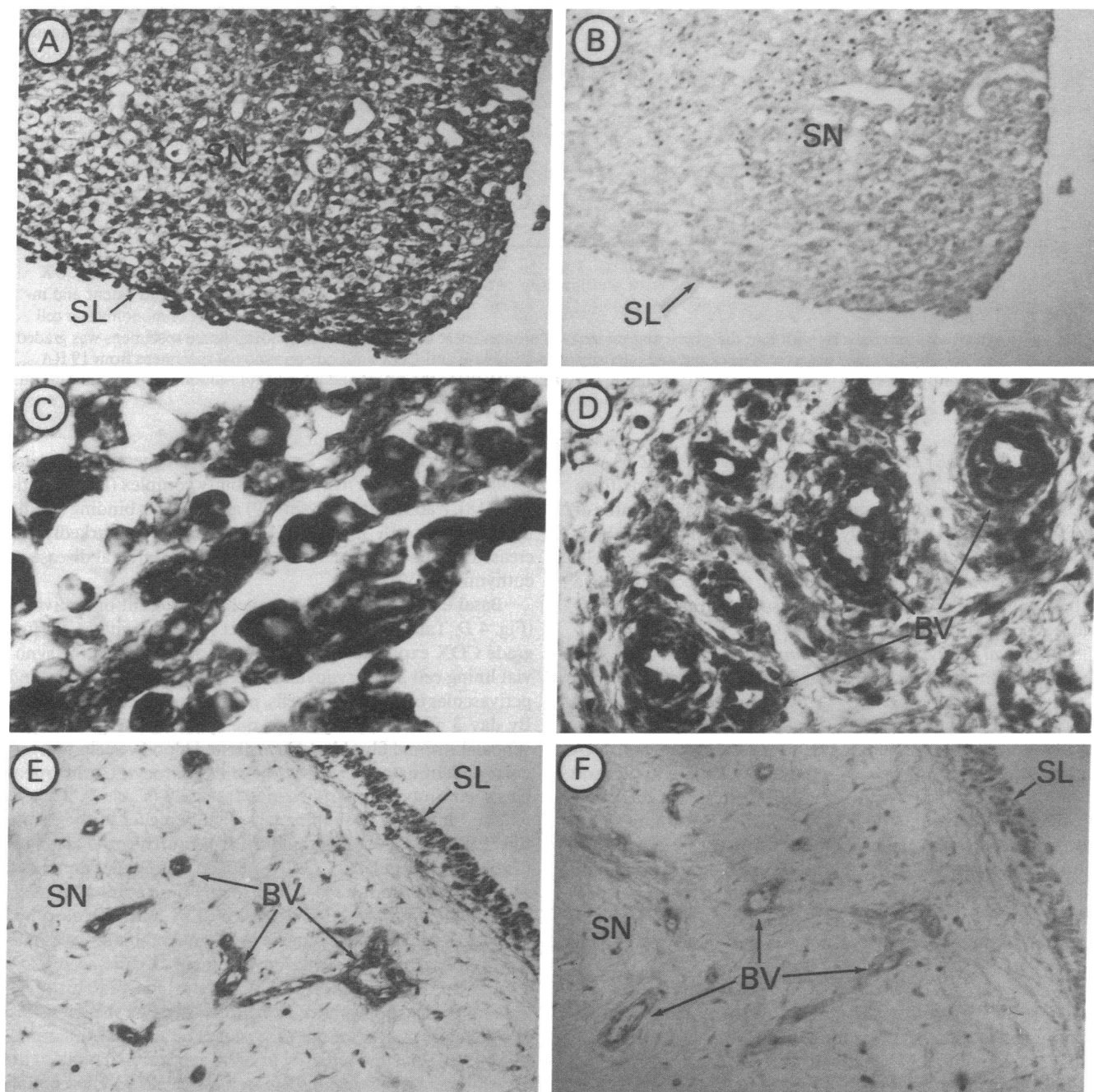


Figure 2. Representative COX immunoperoxidase-stained sections of synovium from patients with RA and OA. Sections from synovium of patients with RA and OA were stained using anti-COX IgG (50 μ g/ml) as described in Methods. Positive staining was indicated by brownish-black deposits and background staining was green on original sections. In this photograph, positive staining is indicated by black deposits. Control staining with anti-COX IgG absorbed with COX-Sepharose conjugate or nonspecific rabbit IgG was uniformly negative. (*A*, *C*, and *D*) Representative RA synovium stained with anti-COX IgG ($\times 62$, $\times 312$, $\times 125$ on original photographs, respectively). (*B*) RA synovium stained with anti-COX IgG absorbed with COX-Sepharose conjugate ($\times 62$ on original photograph). (*E*) Representative OA synovium stained with anti-COX IgG ($\times 62$ on original photograph). (*F*) OA synovium stained with nonspecific rabbit IgG ($\times 62$ on original photograph). The labels denote synovial lining cell layer (*SL*), sublining stromal tissue cells (*SN*), and blood vessels (*BV*).

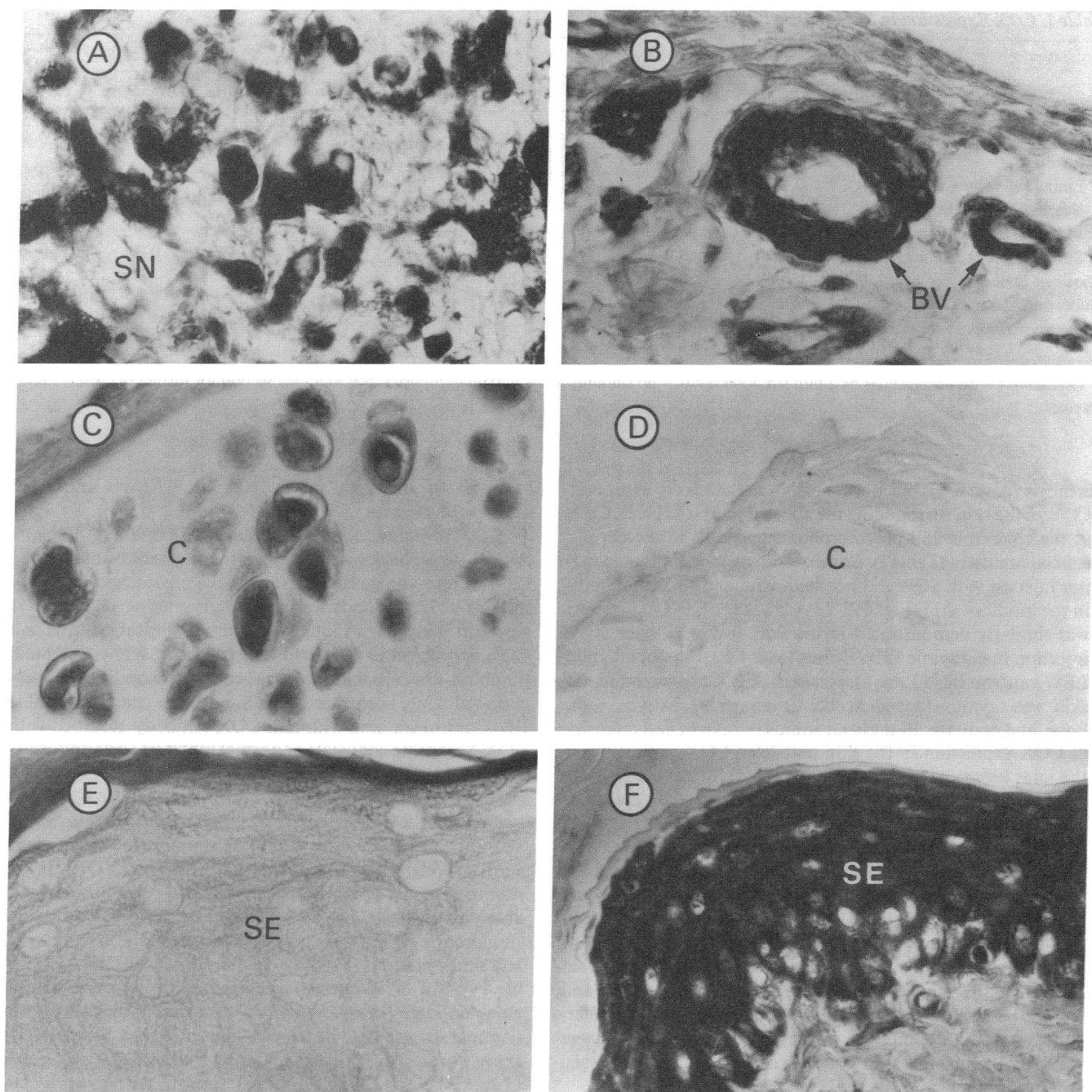


Figure 4. COX immunostaining in SCW-injected euthymic LEW/N rats. Sections (A–F) were stained with anti-COX IgG (75 μ g/ml) as described in Methods. Positive staining is indicated by black deposits. Control staining with anti-COX IgG absorbed with COX-Sepharose conjugate or normal rabbit IgG (75 μ g/ml) was uniformly negative. (A, B, and C) Representative hindfoot joints from SCW-injected euthymic LEW/N rats with chronic arthritis at day 28 ($\times 312$, $\times 312$, $\times 250$ on original photographs, respectively). (D) A representative hindfoot joint from non-cell wall-injected euthymic LEW/N rat ($\times 312$ on original photograph). (E and F) Hindfoot skin from a non-cell wall-injected and a SCW-injected euthymic LEW/N rat with chronic arthritis at day 28 ($\times 312$ and $\times 250$ on original photographs, respectively). The labels denote cartilage (C), subsynovial tissue (SN), blood vessels (BV), and skin epidermis (SE).

antigens (18), transin/stromelysin (19), and HBGF-1 (16) has been noted. Histologically and radiologically apparent marginal erosions develop during this phase of the disease at the junctions of synovium with bone and cartilage and eventually the severely involved joints are destroyed (9, 19).

During the chronic phase, euthymic LEW/N (Fig. 4, A–C), but not athymic LEW.rnu/rnu nor arthritis-resistant F344/N

rats, intensely expressed COX in the cytoplasm of cells throughout the involved joints including the synovial-lining cell layer, sublining stromal cells (Fig. 4 A), blood vessels (Fig. 4 B), cartilage chondrocytes (Fig. 4 C), and bone matrix cells as well as ligamentous and tendinous structures (Table I).

In addition to the staining of connective tissue and bone, both SCW-injected euthymic and athymic rats with acute

Table I. COX Expression in SCW-injected Rats*

	Day 0			Day 3			Day 28		
	LEW/N	LEW.rnu/rnu	F344/N	LEW/N	LEW.rnu/rnu	F344/N	LEW/N	LEW.rnu/rnu	F344/N
Skin epidermis	0-1+	0	0-±	3+	2+	0-1+	3-4+	0	0
Synovium									
Lining cell layer	0	0	0	2+	1+	0	2-3+	0	0
Vascular endothelium	0	0	0	2+	1+	0	2+	0	0
Mononuclear inflammatory cells	NP [‡]	NP	NP	3+	1-2+	NP	3-4+	NP	NP
Stromal fibroblast-like cells	0	0	0	2-3+	1-2+	0	3-4+	0-1+	0
Cartilage chondrocytes	0	0	0	2+	1-2+	0-±	2-3+	0	0-±
Subchondral bone	0	0	0	1-2+	1-2+	0	2+	0	0
Bone marrow	0	0	0	2+	1-2+	0	3+	0	0

* Graded 0-4+ on coded slides by a blinded observer: 0 = no staining, 4+ = maximal intensity. See Methods section for further details. [‡] Not present.

arthritis (days 1-4), but not F344/N rats, intensely expressed COX in the skin surrounding the affected joints (Table I). Cells in the epidermis and polymorphonuclear cells in the dermis stained intensely (Table I). Control euthymic and athymic rats not injected with SCW did not stain with anti-COX antibody in the hindfoot skin (Fig. 4 E, Table I). Since COX expression was similarly demonstrated in the skin at day 28 after SCW injection in euthymic LEW/N rats (Fig. 4 F), but not athymic LEW.rnu/rnu rats (Table I), persistent COX expression in the skin was thymus-dependent like its expression in synovium, bone, and cartilage. In these rat strains the extent and intensity of COX expression in the skin paralleled COX expression in the joint lesions of SCW arthritis (Table I).

COX immunostaining in adjuvant-injected euthymic LEW/N, athymic LEW.rnu/rnu, and euthymic F344/N rats. The injection of a suspension of heat-killed mycobacteria in mineral oil induces chronic, destructive peripheral arthritis in LEW/N rats, but not athymic LEW.rnu/rnu rats, that appears clinically on or about day 10 after adjuvant injection (10, 20). F344/N female rats developed equivocal or very low grade clinically apparent arthritis (data not shown). Clinically apparent arthritis in LEW/N rats is considered to be T cell mediated and may be passively transferred by lymphocytes (21, 22). To determine when COX expression was first detected in AA, rats were killed at 2-d intervals after injection of adjuvant and examined immunohistochemically.

Although basal expression of COX was absent or equivocal, low grade COX expression was readily demonstrated by day 4 after injection with adjuvant in synovial lining cell layer (Fig. 5 A), synovial stromal fibroblast-like cells (Fig. 5 A), blood vessels (Fig. 5 A), cartilage chondrocytes (Fig. 5 C), subchondral bone, bone marrow cells, and skin epidermis (Fig. 5 E) in both LEW/N and LEW.rnu/rnu rats without clinical or histologically apparent inflammation. Up-regulated COX expression was not noted in F344/N rats at any time point (Table II). By days 10-18 after injection with adjuvant, COX was intensely expressed in synovial lining cell layer, synovial stromal fibroblast-like cells, blood vessels, cartilage chondrocytes, subchondral bone, bone marrow cells, and skin epidermis in euthymic LEW/N rats, but expression in LEW.rnu/rnu rats decreased to levels similar to controls (Table II). Control staining with anti-COX antibody absorbed with COX-Sepharose conjugate (Fig.

5, B and D) or normal rabbit IgG (Fig. 5 F) was uniformly negative in all cases.

COX immunostaining in adjuvant-injected LEW/N rats treated with glucocorticoids. Treatment of adjuvant-injected LEW/N rats with dexamethasone in the physiological concentrations (0.02 µg/g body weight per d), beginning at the time of adjuvant injection, strikingly suppressed clinical arthritis and COX expression in synovial lining cell layer, synovial stromal fibroblast-like cells, blood vessels, cartilage chondrocytes, subchondral bone, bone marrow cells, and skin epidermis (Table III). Control staining with anti-COX antibody absorbed with COX-Sepharose conjugate or normal rabbit IgG was uniformly negative.

COX immunostaining in SCW-injected LEW/N rats treated with glucocorticoids or progesterone. Treatment of SCW-injected LEW/N rats with dexamethasone (1, 5, or 10 µg/d) strikingly suppressed clinical arthritis and COX expression in synovial lining cell layer (Fig. 6 D), synovial stromal fibroblast-like cells (Fig. 6 D), blood vessels (Fig. 6 D), cartilage chondrocytes (Fig. 6 F), subchondral bone, bone marrow cells, and skin epidermis (Fig. 6 H) in dose-dependent manner (Table IV). All SCW-injected control rats treated with vehicle alone or progesterone (5 or 50 µg/d), a steroid without anti-inflammatory activity, developed clinically and histologically acute, severe, SCW arthritis and high level COX expression (Table IV, Fig. 6, A, C, E, and G). Control staining with anti-COX antibody absorbed with COX-Sepharose conjugate (Fig. 6 B) or normal rabbit IgG was uniformly negative. Additional control staining included anti-COX antibody plus dexamethasone (0.75, 7.5, or 75 µg/ml). The addition of dexamethasone to the antibody solution did not influence immunoreactivity, i.e., the results to the staining reaction were identical to Fig. 6, A, C, E, and G.

Discussion

COX is the first enzyme of the pathway in which arachidonic acid is converted to PGs (3). COX is located in the endoplasmic reticulum and nuclear membrane but not in the plasma membrane or mitochondrial membrane of cultured fibroblasts (3, 23). Increased COX enzyme activity is considered the critical factor in driving increased PG synthesis in an inflammatory site (3).

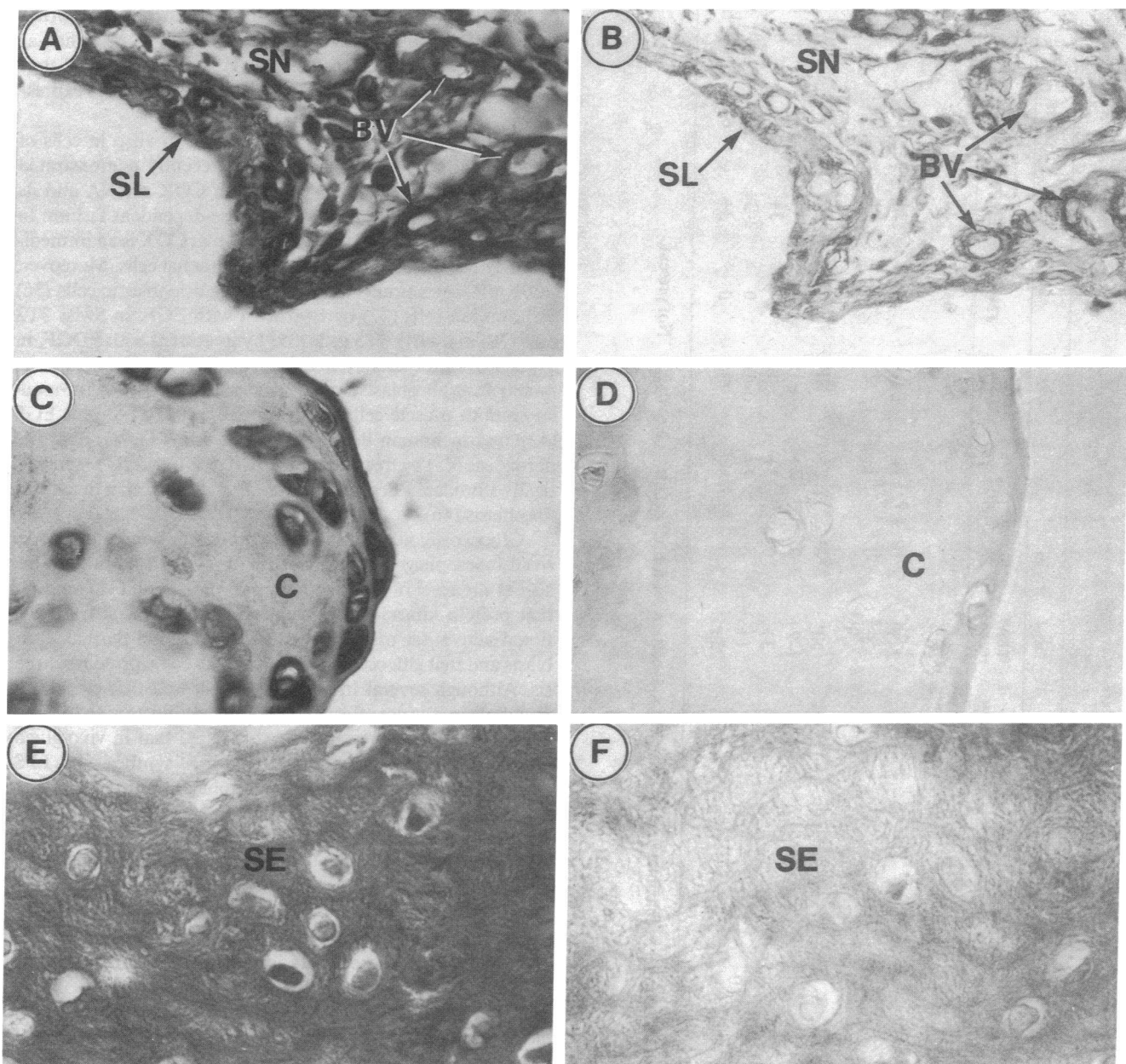


Figure 5. COX immunostaining in adjuvant-injected euthymic LEW/N rats. Sections were stained with anti-COX IgG (75 μ g/ml) as described in Methods. Positive staining is indicated by black deposits. Control staining with anti-COX IgG absorbed with COX-Sepharose conjugate or normal rabbit IgG (75 μ g/ml) was uniformly negative. (A and C) A representative hindfoot joint from adjuvant-injected euthymic LEW/N rat without clinically apparent arthritis at day 4 stained with anti-COX IgG ($\times 250$ on original photographs). (B and D) A representative hindfoot joint from adjuvant-injected euthymic LEW/N rat at day 4 stained with anti-COX IgG absorbed with COX-Sepharose conjugate and normal rabbit IgG, respectively ($\times 250$ on original photographs). (E and F) Hindfoot skin from adjuvant-injected euthymic LEW/N rat at day 4 stained with anti-COX IgG and normal rabbit IgG, respectively ($\times 312$ on original photographs). The labels denote synovial lining cell layer (SL), sublining stromal tissue cells (SN), blood vessels (BV), cartilage (C), and skin epidermis (SE).

Because rheumatoid synovial cells produce high levels of PGE₂ that can accelerate bone resorption by osteoclasts (2) and because COX inhibitors (NSAIDs) are used extensively in the treatment of RA and other inflammatory diseases (4) and effectively modulate various rat models of arthritis (5), study of COX regulation is important. Cytokines, such as interleukin 1 (IL-1) (24, 25), platelet-derived growth factor (PDGF) (25, 26), transforming growth factor- β (TGF- β) (27, 28), epidermal growth factor (EGF) (29), HBGF-1 (16), and tumor necrosis

factor (TNF) (30) have been implicated in the pathophysiology of RA, and the effects of some of these cytokines on COX expression on cells in vitro have been reported. For example, the stimulation of secreted PGE₂ production by IL-1 was reported to correlate with an increase of COX protein in rheumatoid synovial cells in the absence of serum (31). TGF- β , on the other hand, increases COX mRNA in these cells and appears to synergize with IL-1 in increasing PGE₂ production (32). Similar synergistic effects were observed with IL-1 and PDGF in

Table II. COX Expression in Adjuvant-injected Rats*

	Day 0			Day 2			Day 4			Day 10			Day 18		
	LEW/N	LEW.rmu/rmu	F344/N	LEW/N	LEW.rmu/rmu	F344/N	LEW/N	LEW.rmu/rmu	F344/N	LEW/N	LEW.rmu/rmu	F344/N	LEW/N	LEW.rmu/rmu	F344/N
Skin epidermis	0-1+	0	0-±	1+	ND*	0-±	2+	3+	0-±	3+	0-1+	0-±	3+	0	0-±
Synovium															
Lining cell layer	0	0	0	1+	ND	0	2+	2-3+	0	3+	0-1+	0	3+	0	0
Vascular endothelium	0	0	0	1+	ND	0	2+	2+	0	3+	0	0	3+	0	0
Mononuclear inflammatory cells	NP*	NP	NP	NP	ND	NP	NP	NP	NP	2+	NP	NP	3+	NP	NP
Stromal fibroblastlike cells	0	0	0	0-1+	ND	0	2+	1-2+	0	2+	0-1+	0	4+	0	0
Cartilage chondrocytes	0	0	0	0-1+	ND	0	1-2+	3+	0	3+	0-1+	0-±	3+	0	0
Subchondral bone	0	0	0	0	ND	0	1+	1+	0	2+	0-1+	0	2-3+	0	0
Bone marrow	0	0	0	0-1+	ND	0	1+	3+	0	3+	1+	0	3+	0	0

* Graded 0-4+ on coded slides by a blinded observer: 0 = no staining, 4+ = maximal intensity. See Methods section for further details. † Not done. ‡ Not present.

increasing PGE₂ production (33). IL-1 has also been reported to increase phospholipase A₂ (PLA₂) activity in rat synovial fibroblasts (34). Therefore, these in vitro results suggest that there may be species and/or cell-type variation in COX expression.

COX expression has also been studied in vitro in cells of nonsynovial origin. Maier et al. (35) recently demonstrated that IL-1 α stimulates the expression of COX mRNA and its translation product in a time- and dose-dependent fashion in human endothelial cells and suggested that COX is an immediate-early response gene in human endothelial cells. Moreover, COX mRNA is upregulated in murine osteoblastic cells (36) and amnion cells (37) by treatment with EGF, in Swiss 3T3 cells (38) and NIH 3T3 cells (39) by treatment with PDGF, in Swiss 3T3 fibroblasts by treatment with TNF (40), in normal human lung fibroblasts by treatment with TGF- β (41), in vascular smooth muscle cells by treatment with TGF- β plus EGF (42), and in human dermal fibroblast cells (43, 44) and 3T3 fibroblasts (45) by treatment with IL-1. TNF and IL-1 synergistically stimulate PG synthesis via COX induction in Swiss 3T3 fibroblasts (46).

Glucocorticoids inhibit PG synthesis in bone marrow-derived macrophages not only at the level of PLA₂ protein but also at the level of COX protein (46). Raz et al. (47) reported that protein kinase C participates in IL-1-induced transcriptional activation of COX synthesis in human dermal fibroblasts and that glucocorticoids inhibit the COX protein synthesis. Although several in vivo studies showed that eicosanoid metabolism was not affected by steroid administration (48, 49), Masferrer et al. (6) recently demonstrated that in vivo glucocorticoid administration inhibited COX synthesis by LPS-stimulated mouse peritoneal macrophages, but did not alter COX activity present in non-adherent cells (lymphocytes, PMNs) or renal cells. They suggested that suppression of COX expression by glucocorticoids may be cell-type specific. Glucocorticoids are, of course, the most potent inhibitors known of the inflammation of RA (4), AA (5), and SCW arthritis (50).

Although the data on COX expression in vitro are extensive, and much indirect data implicate COX involvement in RA, no direct data have been published on in vivo COX expression in RA; however, Masferrer et al. (6) recently, as noted above, demonstrated that LPS in vivo stimulated COX protein synthesis in the mouse peritoneal macrophages but not in the kidney. Moreover, as discussed above, it is indeed difficult to extrapolate the in vitro data to in vivo COX expression. In the present study, we have attempted to address this issue. We detected COX immunohistochemically at high levels, relative to OA and normal subjects, in the synovial lining cell layer, synovial sublining fibroblast-like cells, blood vessels, and inflammatory cells of RA patients. The extent and intensity of COX immunostaining correlated with the extent and intensity of synovial mononuclear cell infiltration. In LEW/N rats with SCW arthritis and AA, COX was expressed early in the synovium, cartilage, bone and bone marrow, and the skin epidermis. In athymic LEW.rmu/rmu rats, COX was also expressed at day 3 after SCW injection and at days 2-7 after adjuvant injection, but the upregulated expression of COX was not sustained. Persistent high level COX expression, like clinically apparent arthritis (18), was observed only in euthymic LEW/N rats implying that chronic, high-intensity expression of COX is T cell dependent. Moreover, in arthritis-resistant F344/N rats, COX

Table III. COX Expression in Adjuvant-injected LEW/N Rats Treated with Glucocorticoids*

	Day 0	Day 4: Treatment with		Day 8: Treatment with		Day 12: Treatment with	
	No treatment	Vehicle	Glucocorticoids	Vehicle	Glucocorticoids	Vehicle	Glucocorticoids
Skin epidermis	0-1+	2+	0-1+	3+	0-1+	3+	0-1+
Synovium							
Lining cell layer	0	2+	0-±	2+	0	3+	0-±
Vascular endothelium	0	2+	0	2+	0	2-3+	0
Mononuclear inflammatory cells	NP†	NP	NP	NP	NP	3-4+	NP
Stromal fibroblast-like cells	0	2+	0	2+	0	3+	0
Cartilage chondrocytes	0	1-2+	0	2+	0	2-3+	0-±
Subchondral bone	0	1+	0	2+	0	2+	0
Bone marrow	0	1+	0-±	2-3+	0-±	3+	0-±

* Graded 0-4+ on coded sections by a blinded observer: 0 = no staining, 4+ = maximal intensity. See Methods section for further details. † Not present.

expression was absent or equivocal after injection with SCW or adjuvant. These data support the view that upregulation of COX gene expression is associated with severe joint inflammation. We have also recently observed similar correlations of COX expression in LEW/N and F344/N rats after injection of carrageenin: i.e., high levels of COX immunoreactivity in LEW/N and low levels in F344/N rats in the aseptic granulomas (data not shown).

Our data are also consistent with previous work on mechanisms determining the susceptibility and resistance of LEW/N and F344/N rats, respectively, to SCW arthritis (50, 51) and other inflammatory diseases including carrageenin-induced granuloma. F344/N female rats show a rapid and robust increase in plasma adrenocorticotrophic hormone and corticosteroid levels, as well as increased hypothalamic release and synthesis of corticotropin releasing hormone, in response to SCW, IL-1, and many other stressful stimuli. This response is profoundly blunted and delayed in LEW/N rats. In present study, we found that glucocorticoids administered in physiologically relevant doses at the time of adjuvant and SCW injection suppressed both arthritis and COX expression in LEW/N rats in a

dose-dependent manner. But progesterone, a steroid without antiinflammatory activity, did not suppress arthritis nor COX expression. We suspect, but did not formally prove, that increased plasma glucocorticoids may have down-regulated disease and COX synthesis in F344/N rats. Previously, we have showed that corticosteroid receptor antagonists precipitated severe, acute, SCW-induced inflammatory disease in this, otherwise, relatively resistant rat strain (50). Although additional experiments are required, our data are consistent with the view that COX expression may be negatively regulated in vivo by glucocorticoids in physiologically relevant concentrations.

We have measured the mRNA levels for COX by using oligonucleotide primers designed against the human endothelial cell COX cDNA in the reverse transcriptase-polymerase chain reaction (35). In contrast to the immunoreactive COX protein levels which showed a strong correlation with the disease phenotype, the mRNA levels for COX did not change in a similar manner (data not shown). Recent discovery of the second gene for COX (52, 53) as well as our own data (T. Hla, unpublished data) indicate that COX-1 and COX-2 genes are expressed and regulated differentially in many cell types. Of

Table IV. Day 3 COX Expression in SCW-injected LEW/N Rats Treated with Glucocorticoids or Progesterone*

	Vehicle	Treatment with Glucocorticoids			Progesterone	
		µg/d				
		1	5	10	5	50
Skin epidermis	2+	1-2+	±-1+	0-1+	2-3+	2-3+
Synovium						
Lining cell layer	2+	0-1+	0-±	0-±	2+	1-2+
Vascular endothelium	2+	0-1+	0-±	0-±	2+	2-3+
Mononuclear inflammatory cells	2+	0-±	±-1+	NP†	2+	2-3+
Stromal fibroblast-like cells	2-3+	1+	0-±	0-±	2+	2-3+
Cartilage chondrocytes	2+	1+	±-1+	0	1-2+	2+
Subchondral bone	1-2+	±-1+	0-±	0-±	2+	1-2†
Bone marrow	2+	±-1+	±-1+	0-±	1-2+	1-2+

* Graded 0-4+ on coded slides by a blinded observer: 0 = no staining, 4+ = maximal intensity. See Methods section for further details. † Not present.

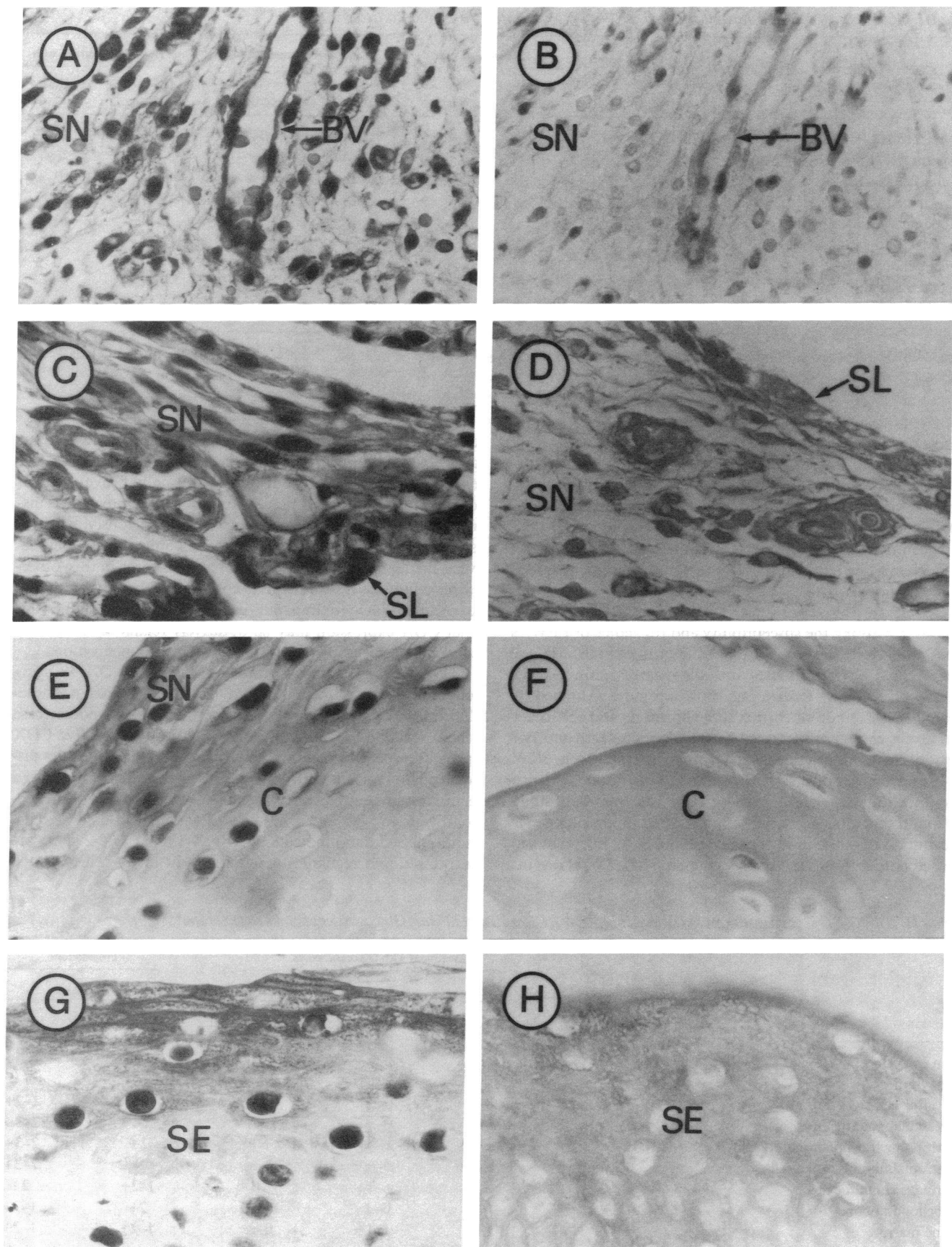


Figure 6. COX immunostaining in SCW-injected euthymic LEW/N rats treated with glucocorticoids. Sections from SCW-injected LEW/N rats treated with vehicle or dexamethasone and killed at day 3 were stained with anti-COX IgG (75 μ g/ml) as described in Methods. Positive staining

importance, the polypeptide product of the COX-2 gene is highly homologous to COX-1 polypeptide (70% identity), suggesting that our polyclonal antibodies may cross-react with both forms of COX. Since the rat homologues of COX-1 and COX-2 cDNA have not been cloned, we cannot, at this point, determine the gene expression of COX-1 and COX-2 in SCW- and adjuvant-induced arthritis models. Further studies, with gene-specific probes as well as isotype-specific antisera, will be necessary to determine the contribution of COX-1 and COX-2 gene expression in inflammatory joint diseases.

The *in vivo* data that we have presented suggest that up-regulated COX expression may be one of the earliest *in vivo* biochemical markers of the inflammatory cascade in RA in humans and SCW and AA in LEW/N rats. Up-regulated COX expression *in vivo* parallels the up-regulated expression of class II MHC antigens (18), transin/stromelysin (19, 54), and HBGF-1 (16), which are *in vivo* factors also implicated in these diseases. The data also suggest that the expression of these factors may be genetically controlled and mechanistically linked.

Acknowledgments

We would like to thank Drs. Hereward Cattell, Patrick Caufield, Anthony Unger, Edward Bieber, Lewis Ottenritter, and Randall Lewis for their help in obtaining synovial tissues. We also gratefully acknowledge Drs. Elaine F. Remmers, Ellen A. Goldmuntz, Joseph M. Cash, and Barbara Misiewicz-Poltorak for their suggestions and critical review of the manuscript.

This study was supported in part by a postdoctoral fellowship from the Arthritis Foundation to Dr. Hla and by National Institutes of Health grants HL-32348, HL-35627, and AG-07450 and American Heart Association grant-in-aid no. 881281 from the Maryland Affiliate to Dr. Maciag.

References

- Robinson, D. R., A. H. Tashjian, Jr., and L. Levine. 1975. Prostaglandin-stimulated bone resorption by rheumatoid synovia: a possible mechanism for bone destruction in rheumatoid arthritis. *J. Clin. Invest.* 56:1181-1188.
- Dayer, J.-M., S. M. Krane, R. G. G. Russell, and D. R. Robinson. 1976. Production of collagenase and prostaglandins by isolated adherent rheumatoid synovial cells. *Proc. Natl. Acad. Sci. USA.* 73:945-949.
- Needleman, P., J. Turk, B. A. Jakschik, A. R. Morrison, and J. B. Lefkowitz. 1986. Arachidonic acid metabolism. *Annu. Rev. Biochem.* 55:69-102.
- Abramson, S. B., and G. Weissmann. 1989. The mechanisms of action of nonsteroidal antiinflammatory drugs. *Arthritis Rheum.* 32:1-9.
- Billingham, M. E. J. 1983. Models of arthritis and the search for anti-arthritis drugs. *Pharmacol. Ther.* 21:389-428.
- Masferrer, J. L., B. S. Zweifel, K. Seibert, and P. Needleman. 1990. Selective regulation of cellular cyclooxygenase by dexamethasone and endotoxin in mice. *J. Clin. Invest.* 86:1375-1379.
- Arnett, F. C., S. M. Edworthy, D. A. Bloch, D. J. McShane, J. F. Fries, N. S. Cooper, L. A. Healey, S. R. Kaplan, M. H. Liang, H. S. Luthra, et al. 1988. The American Rheumatism Association 1987 revised criteria for the classification of rheumatoid arthritis. *Arthritis Rheum.* 31:315-324.
- Wilder, R. L., G. B. Calandra, A. J. Garvin, K. D. Wright, and C. T. Hansen. 1982. Strain and sex variation in the susceptibility to streptococcal cell wall-induced polyarthritis in the rat. *Arthritis Rheum.* 25:1064-1072.
- R. L. Wilder. 1988. Streptococcal cell wall-induced polyarthritis in rats. In *CRC Handbook of the Rheumatic Diseases*. Volume I. R. A. Greenwald and H. S. Diamond, editors. CRC Press, Inc., Boca Raton, FL. 33-40.
- Case, J. P., H. Lorberbom-Galski, R. Lafyatis, D. FitzGerald, R. L. Wilder, and I. Pastan. 1989. Chimeric cytotoxin IL-2-PE40 delays and mitigates adjuvant-induced arthritis in rats. *Proc. Natl. Acad. Sci. USA.* 86:287-291.
- Lorberbom-Galski, H., R. Lafyatis, J. P. Case, D. Fitzgerald, R. L. Wilder, and I. Pastan. 1991. Administration of IL-2-PE40 via osmotic pumps prevents adjuvant-induced arthritis in rats: improved therapeutic index of IL-2-PE40 administered by continuous infusion. *Int. J. Immunopharmacol.* 13:305-315.
- Hla, T., M. Farrell, A. Kumar, and J. M. Bailey. 1986. Isolation of the cDNA for human prostaglandin H synthase. *Prostaglandins.* 32:829-845.
- Towbin, H., T. Staehelin, and J. Gordon. 1979. Electrophoretic transfer of proteins from polyacrylamide gels to nitrocellulose sheets: procedure and some applications. *Proc. Natl. Acad. Sci. USA.* 76:4350-4354.
- Johnstone, A., and R. Thorpe. 1987. *Immunocytochemistry in Practice*. Blackwell Scientific Publications, Boston, MA. 306 pp.
- Hsu, S. M., L. Raine, and H. Fanger. 1981. Use of avidin-biotin-peroxidase complex (ABC) in immunoperoxidase techniques: a comparison between ABC and unlabeled antibody (PAP) procedures. *J. Histochem. Cytochem.* 29:577-580.
- Sano, H., R. Forough, J. A. M. Maier, J. P. Case, A. Jackson, K. Engleka, T. Maciag, and R. L. Wilder. 1990. Detection of high levels of heparin binding growth factor-1 (acidic fibroblast growth factor) in inflammatory arthritic joints. *J. Cell Biol.* 110:1417-1426.
- Remington, R. D., and M. A. Schork. 1985. *Statistics with Applications to the Biological and Health Sciences*. Prentice-Hall, Inc., Englewood Cliffs, NJ. 415 pp.
- Wilder, R. L., J. B. Allen, and C. Hansen. 1987. Thymus-dependent and -independent regulation of Ia antigen expression *in situ* by cells in the synovium of rats with streptococcal cell wall-induced arthritis: differences in site and intensity of expression in euthymic, athymic, and cyclosporin A-treated LEW and F344 rats. *J. Clin. Invest.* 79:1160-1171.
- Case, J. P., H. Sano, R. Lafyatis, E. F. Remmers, G. K. Kumkumian, and R. L. Wilder. 1989. Transin/stromelysin expression in the synovium of rats with experimental erosive arthritis: *in situ* localization and kinetics of expression of the transformation-associated metalloproteinase in euthymic and athymic Lewis rats. *J. Clin. Invest.* 84:1731-1740.
- Pearson, C. M., and F. D. Wood. 1959. Studies of polyarthritis and other lesions induced in rats by injection of Mycobacterial adjuvant. I. General clinical and pathologic characteristics and some modifying factors. *Arthritis Rheum.* 2:440-459.
- Kayashima, K., T. Koga, and K. Onoue. 1976. Role of T lymphocytes in adjuvant arthritis. I. Evidence for the regulatory function of thymus-derived cells in the induction of the disease. *J. Immunol.* 117:1878-1882.
- Taurog, J. D., G. P. Sandberg, and M. L. Mahowald. 1983. The cellular basis of adjuvant arthritis. II. Characterization of the cells mediating passive transfer. *Cell. Immunol.* 80:198-204.
- DeWitt, D. L., T. E. Rollins, J. S. Day, J. A. Gauger, and W. L. Smith. 1981. Orientation of the active site and antigenic determinants of prostaglandin endoperoxidase synthase in the endoplasmic reticulum. *J. Biol. Chem.* 256:10375-10382.
- Arend, W., and J.-M. Dayer. 1990. Cytokines and cytokine inhibitors or antagonists in rheumatoid arthritis. *Arthritis Rheum.* 33:305-315.
- Remmers, E. F., R. Lafyatis, G. K. Kumkumian, J. P. Case, M. B. Sporn, and R. L. Wilder. 1990. Cytokines and growth regulation of synoviocytes from patients with rheumatoid arthritis and rats with streptococcal cell wall arthritis. *Growth Factors.* 2:179-188.
- Remmers, E. F., H. Sano, R. Lafyatis, J. P. Case, G. K. Kumkumian, T. Hla, T. Maciag, and R. L. Wilder. 1991. Production of platelet-derived growth factor B chain (PDGF-B/c-sis) mRNA and immunoreactive PDGF B-like polypeptide by rheumatoid synovium: coexpression with heparin-binding acidic fibroblast growth factor-1. *J. Rheumatol.* 18:7-13.
- Lafyatis, R., N. L. Thompson, E. F. Remmers, K. C. Flanders, N. S. Roche, S.-J. Kim, J. P. Case, M. B. Sporn, A. B. Roberts, and R. L. Wilder. 1989. Transforming growth factor- β production by synovial tissues from rheumatoid

is indicated by black deposits. Control staining with anti-COX IgG absorbed with COX-Sepharose conjugate or normal rabbit IgG (75 μ g/ml) was uniformly negative. (A, C, and E) Representative hindfoot joints from SCW-injected, vehicle-treated euthymic LEW/N rats stained with anti-COX IgG ($\times 140$, $\times 200$, and $\times 200$ on original photographs, respectively). (B) A representative hindfoot joint from SCW-injected vehicle treated LEW/N rats stained with anti-COX IgG absorbed with COX-Sepharose conjugate ($\times 140$ on original photograph). (D and F) Representative hindfoot joints from SCW-injected, dexamethasone-treated LEW/N rats stained with anti-COX IgG ($\times 200$ on original photographs). (G and H) Representative hindfoot skin from SCW-injected vehicle and dexamethasone treated LEW/N rats, respectively, stained with anti-COX IgG ($\times 200$ on original photographs). The labels denote synovial lining cell layer (SL), subsynovial tissue (SN), blood vessels (BV), cartilage (C), and skin epidermis (SE).

patients and streptococcal cell wall arthritic rats: studies on secretion by synovial fibroblast-like cells and immunohistologic localization. *J. Immunol.* 143:1142-1148.

28. Wilder, R. L., R. Lafyatis, A. B. Roberts, J. P. Case, G. K. Kumkumian, H. Sano, M. B. Sporn, and E. F. Remmers. 1990. Transforming growth factor- β in rheumatoid arthritis. *Ann. NY Acad. Sci.* 593:197-207.

29. Shiozawa, S., K. Shiozawa, Y. Tanaka, I. Morimoto, M. Uchihashi, T. Fujita, K. Hirohata, Y. Hirata, and S. Imura. 1989. Human epidermal growth factor for the stratification of synovial lining layer and neovascularisation in rheumatoid arthritis. *Ann. Rheum. Dis.* 48:820-828.

30. Yocum, D. E., L. Esparza, S. Dubry, J. B. Benjamin, R. Volz, and P. Scuderi. 1989. Characteristics of tumor necrosis factor production in rheumatoid arthritis. *Cell. Immunol.* 122:131-145.

31. O'Neill, L. A. J., M. L. Barret, and G. P. Lewis. 1987. Induction of cyclooxygenase by interleukin-1 in rheumatoid synovial cells. *FEBS (Fed. Eur. Biochem. Soc.) Lett.* 212:35-39.

32. Case, J. P., J. A. M. Maier, T. Hla, H. Sano, L. J. Crofford, T. Maciag, and R. L. Wilder. 1990. Complex regulation of cyclooxygenase (COX) mRNA levels and prostaglandin E_2 (PGE_2) production by cytokines and cAMP in rheumatoid synovial fibroblasts (SFBs). *Arthritis Rheum.* 33:S17. (Abstr.).

33. Kumkumian, K. G., R. Lafyatis, E. F. Remmers, J. P. Case, S.-J. Kim, and R. L. Wilder. 1989. Platelet-derived growth factor and IL-1 interactions in rheumatoid arthritis: regulation of synovocyte proliferation, prostaglandin production, and collagenase transcription. *J. Immunol.* 143:833-837.

34. Godfrey, R. W., W. J. Johnson, and S. T. Hoffstein. 1988. Interleukin-1 stimulation of phospholipase activity in rat synovial fibroblasts: possible regulation by cyclooxygenase products. *Arthritis Rheum.* 31:1421-1428.

35. Maier, J. A. M., T. Hla, and T. Maciag. 1990. Cyclooxygenase is an immediate-early gene induced by interleukin-1 in human endothelial cells. *J. Biol. Chem.* 265:10805-10808.

36. Yokota, K., M. Kusaka, T. Ohshima, S. Yamamoto, N. Kurihara, T. Yoshino, and M. Kumegawa. 1986. Stimulation of prostaglandin E_2 synthesis in cloned osteoblastic cells of mouse (MC3T3-E1) by epidermal growth factor. *J. Biol. Chem.* 261:15410-15415.

37. Casey, M. L., K. Korte, and P. C. MacDonald. 1988. Epidermal growth factor stimulation of prostaglandin E_2 biosynthesis in amnion cells: induction of prostaglandin H_2 synthase. *J. Biol. Chem.* 263:7846-7854.

38. Habenicht, A. J. R., M. Goerig, J. Grulich, D. Rothe, R. Gronwald, U. Loth, G. Schettler, B. Kommerell, and R. Ross. 1985. Human platelet-derived growth factor stimulates prostaglandin synthesis by activation and rapid *de novo* synthesis of cyclooxygenase. *J. Clin. Invest.* 75:1381-1387.

39. Lin, A. H., M. J. Bienkowski, and R. R. Gorman. 1989. Regulation of prostaglandin H synthase mRNA levels and prostaglandin biosynthesis by platelet-derived growth factor. *J. Biol. Chem.* 264:17379-17383.

40. Burch, R. M., and C. W. Tiffany. 1989. Tumor necrosis factor causes amplification of arachidonic acid metabolism in response to interleukin 1, bradykinin, and other agonists. *J. Cell. Physiol.* 141:85-89.

41. Diaz, A., D. G. Baker, D. L. Dewitt, and S. A. Jimenez. 1990. Transform-

ing growth factor- β stimulates the expression of prostaglandin synthase in normal human fibroblasts. *Ann. NY Acad. Sci.* 593:306-309.

42. Bailey, J. M., A. N. Makheja, J. Pash, and M. Verma. 1988. Corticosteroids suppress cyclooxygenase messenger RNA levels and prostanoicid synthesis in cultured vascular cells. *Biochem. Biophys. Res. Commun.* 157:1159-1163.

43. Raz, A., A. Wyche, N. Siegel, and P. Needleman. 1988. Regulation of fibroblast cyclooxygenase synthesis by interleukin-1. *J. Biol. Chem.* 263:3022-3028.

44. Korn, J. H., E. Downie, G. J. Roth, and S.-Y. Ho. 1989. Synergy of interleukin 1 (IL-1) with arachidonic acid and A23187 in stimulating PGE synthesis in human fibroblasts: IL-1 stimulates fibroblast cyclooxygenase. *Clin. Immunol. Immunopathol.* 50:196-204.

45. Burch, R. M., J. R. Connor, and J. Axelrod. 1988. Interleukin 1 amplifies receptor-mediated activation of phospholipase A_2 in 3T3 fibroblasts. *Proc. Natl. Acad. Sci. USA.* 85:6306-6309.

46. Goppelt-Strube, M., D. Wolter, and K. Resch. 1989. Glucocorticoids inhibit prostaglandin synthesis not only at level of phospholipase A_2 but also at the level of cyclo-oxygenase/PGE isomerase. *Br. J. Pharmacol.* 98:1287-1295.

47. Raz, A., A. Wyche, and P. Needleman. 1989. Temporal and pharmacological division of fibroblast cyclooxygenase expression into transcriptional and translational phases. *Proc. Natl. Acad. Sci. USA.* 86:1657-1661.

48. Nasjletti, A., A. Erman, L. M. Cagen, and P. G. Baer. 1984. Plasma concentrations, renal excretion, and tissue release of prostaglandins in the rat with dexamethasone-induced hypertension. *Endocrinology.* 114:1033-1040.

49. N  ray-Fejes-T  th, A., G. Fejes-T  th, C. Fisher, and J. C. Fr  lich. 1984. Effect of dexamethasone on in vivo prostanoicid production in the rabbit. *J. Clin. Invest.* 74:120-123.

50. Sternberg, E. M., J. M. Hill, G. P. Chrousos, T. Kamilaris, S. J. Listwak, P. W. Gold, and R. L. Wilder. 1989. Inflammatory mediator-induced hypothalamic-pituitary-adrenal axis activation is defective in streptococcal cell wall arthritis-susceptible Lewis rats. *Proc. Natl. Acad. Sci. USA.* 86:2374-2378.

51. Sternberg, E. M., W. S. Young, III., R. Bernardini, A. E. Calogero, G. P. Chrousos, P. W. Gold, and R. L. Wilder. 1989. A central nervous system defect in biosynthesis of corticotropin-releasing hormone is associated with susceptibility to streptococcal cell wall-induced arthritis in Lewis rats. *Proc. Natl. Acad. Sci. USA.* 86:4771-4775.

52. Rosen, G. D., T. M. Brinkenmeier, A. Raz, and N. J. Holtzman. 1989. Identification of a cyclooxygenase-related gene and its potential role in prostaglandin formation. *Biochem. Biophys. Res. Commun.* 164:1358-1365.

53. Xie, W., J. G. Chipman, D. L. Robertson, R. L. Erikson, and D. L. Simmons. 1991. Expression of a mitogen-responsive gene encoding prostaglandin synthase is regulated by mRNA splicing. *Proc. Natl. Acad. Sci. USA.* 88:2692-2696.

54. Case, J. P., R. Lafyatis, E. F. Remmers, G. Kumkumian, and R. L. Wilder. 1989. Transin/stromelysin expression in rheumatoid synovium: a transformation-associated metalloproteinase secreted by phenotypically invasive synovitis. *Am. J. Pathol.* 135:1055-1064.