

## Multiple tissues express alpha 1-antitrypsin in transgenic mice and man.

J A Carlson, ... , M J Finegold, S L Woo

*J Clin Invest.* 1988;**82**(1):26-36. <https://doi.org/10.1172/JCI113580>.

### Research Article

Hepatocytes are considered to be the predominant source of alpha 1-antitrypsin (AAT), the major antiprotease in human plasma. The development of emphysema in the hereditary PiZ AAT deficiency state suggests that inhibition of leukocyte elastase in the lung is a major function of this protein. In addition, patients with AAT deficiency are at increased risk for developing cholestasis in infancy and chronic liver disease as adults. The mechanism for hepatic cell injury, however, is not understood. Transgenic mice that express the normal human AAT gene demonstrate abundant AAT in hepatocytes and specific cell types of numerous nonhepatic tissues. Immunoperoxidase techniques have previously disclosed AAT in many of the cell types seen in transgenic mice; however, the issue of local synthesis vs. endocytosis in these cell types has remained unresolved. In this study, AAT mRNA was seen in a variety of tissues in the transgenic mouse.

Immunoelectron microscopy of renal tubular and small intestinal epithelial cells in the transgenic mice demonstrated AAT within the cisternae of the rough endoplasmic reticulum, as in hepatocytes. These findings support the possibility of local synthesis in the various cell types. The results suggest that in addition to maintaining tissue integrity in the lung, the protease/antiprotease balance may have physiological functions in other organs as well.

**Find the latest version:**

<https://jci.me/113580/pdf>



# Multiple Tissues Express Alpha<sub>1</sub>-Antitrypsin in Transgenic Mice and Man

Joyce A. Carlson,\* Beverly Barton Rogers,<sup>†</sup> Richard N. Sifers,<sup>§</sup> Hal K. Hawkins,<sup>‡</sup> Milton J. Finegold,<sup>‡</sup> and Savio L. C. Woo<sup>§||†</sup>  
Departments of \*Gastroenterology, <sup>‡</sup>Pathology, and <sup>§</sup>Cell Biology; <sup>||</sup>Institute of Molecular Genetics; and <sup>†</sup>Howard Hughes Medical Institute, Baylor College of Medicine, Houston, Texas 77030

## Abstract

Hepatocytes are considered to be the predominant source of alpha<sub>1</sub>-antitrypsin (AAT), the major antiprotease in human plasma. The development of emphysema in the hereditary PiZ AAT deficiency state suggests that inhibition of leukocyte elastase in the lung is a major function of this protein. In addition, patients with AAT deficiency are at increased risk for developing cholestasis in infancy and chronic liver disease as adults. The mechanism for hepatic cell injury, however, is not understood. Transgenic mice that express the normal human AAT gene demonstrate abundant AAT in hepatocytes and specific cell types of numerous nonhepatic tissues. Immunoperoxidase techniques have previously disclosed AAT in many of the cell types seen in transgenic mice; however, the issue of local synthesis vs. endocytosis in these cell types has remained unresolved. In this study, AAT mRNA was seen in a variety of tissues in the transgenic mouse. Immunoelectron microscopy of renal tubular and small intestinal epithelial cells in the transgenic mice demonstrated AAT within the cisternae of the rough endoplasmic reticulum, as in hepatocytes. These findings support the possibility of local synthesis in the various cell types. The results suggest that in addition to maintaining tissue integrity in the lung, the protease/antiprotease balance may have physiological functions in other organs as well.

## Introduction

Alpha<sub>1</sub>-antitrypsin (AAT)<sup>1</sup> is the predominant antiprotease in the human circulation. Hepatocytes are considered to be the major source of this plasma protein (1). AAT has been identified in a variety of human tissues by immunoperoxidase or immunofluorescence studies (2–8), but *de novo* synthesis has been demonstrated only in hepatocytes and in primary cultures of blood monocytes and tissue macrophages (9–11). The naturally occurring deficiency state of AAT, referred to as the PiZ phenotype, results from a single base mutation with a resulting charged amino acid substitution (12). The mutant protein accumulates within the rough endoplasmic reticulum (RER) at its site of synthesis, causing a subsequent deficiency

of the circulating protein. The initial clinical correlate of early onset panlobular emphysema (13) was later joined by neonatal cholestasis and juvenile cirrhosis (14). An increased risk for cirrhosis and hepatoma has been unequivocally demonstrated for adult PiZ subjects (15). Sporadic reports have associated the PiZ phenotype with renal disease (16–18), gastric and duodenal ulcers (19), pancreatitis (20), panniculitis (21), and many other conditions, although a pathogenetic relationship is speculative.

We have recently generated transgenic mice bearing a 14.4-kb DNA construct containing the human structural gene for normal (PiM) AAT with 2.0 and 2.3 kb of its 5' and 3' flanking regions (12). This fragment apparently contains the promoter, enhancer, and tissue-specific *cis*-acting elements for normal regulation of gene transcription. Four pedigrees of mice with multiple gene copy numbers and high plasma levels of human AAT have been shown to contain high levels of human AAT mRNA in their livers. The unexpected finding of significant but less abundant expression in other tissues (12) has led to further investigation. In this study, immunohistochemical techniques are coupled with specific mRNA analysis to evaluate the possibility of synthesis of AAT in various tissues of transgenic mice. Results are compared with previous reports and additional studies on human tissues.

## Methods

**Mice.** Transgenic mice were generated by the injection of the human structural gene for AAT including 2.0 and 2.3 kb of its 5' and 3' flanking regions, respectively. Pedigrees were obtained in which the progeny bore ~ 10, 30, 50, or 100 gene copies per cell as determined by Southern blot analysis of mouse tail DNA (12).

**Antiserum.** Enrichment for mouse AAT from pooled normal mouse serum was accomplished by passage over a column of Affi-gel Blue (Bio-Rad Laboratories, Richmond, CA) (22) and verified by Western blotting analysis (23), using a rabbit anti-rat AAT IgG fraction prepared by Dr. Hernan Grenett (Dept. of Cell Biology, Baylor College of Medicine) as first antibody. Protein from enriched fractions was coupled to cyanogen bromide Sepharose (Pharmacia Fine Chemicals, Piscataway, NJ) according to manufacturer's instructions. Polyclonal goat anti-human AAT IgG obtained from Cappel Laboratories (Malvern, PA) was subjected to extensive affinity chromatography on this support. Specificity for human AAT was then demonstrated by Western blotting analysis of a wide range of mouse and human serum sample volumes. The affinity-purified goat anti-human AAT was used for all immunological methods to follow, unless otherwise specified.

**Histology.** Several mice from each pedigree were killed for histological analysis. Tissues examined were brain, thyroid, parathyroid, adrenal and salivary glands, thymus, heart, lung, liver, kidney, spleen, pancreas, esophagus, stomach, proximal and distal small intestine, colon, rectum, skeletal muscle, reproductive organs, skin, and bone. Tissues for light microscopy were fixed in Carson's 10% phosphate-buffered formalin, pH 7.4 (Stat Lab Medical Products, Kemp, TX) and embedded in paraffin. Sections were stained with hematoxylin-eosin and periodic acid-Schiff (PAS) with and without diastase digestion. Alternate sections were dewaxed and treated with 0.1% pepsin in 0.01

Address reprint requests to Dr. Savio L. C. Woo, Howard Hughes Medical Institute, Baylor College of Medicine, One Baylor Plaza, Texas Medical Center, Houston, TX 77030.

Received for publication 19 May 1987 and in revised form 26 January 1988.

1. Abbreviations used in this paper: AAT, alpha<sub>1</sub>-antitrypsin; RER, rough endoplasmic reticulum.

J. Clin. Invest.

© The American Society for Clinical Investigation, Inc.

0021-9738/88/07/0026/11 \$2.00

Volume 82, July 1988, 26–36

N HCl (Sigma Chemical Co., St. Louis, MO) rinsed, and incubated overnight with goat anti-human AAT (1:6,000 dilution). Standard immunoperoxidase procedures were then performed (24). A human liver section from a PiZ infant was used as a positive control with each series of sections. The secondary antibody without the primary antibody (goat anti-human AAT) was applied as a negative control on each tissue. Additional negative controls included staining of corresponding tissues from nontransgenic mice and substitution of nonimmunized goat serum for the primary antibody.

Corresponding tissues from human autopsy cases or surgical specimens were treated identically for comparison. Cases were selected randomly and did not include PiZ human subjects.

**Electron microscopy.** Tissues were fixed overnight in 0.1 M phosphate buffer, pH 7.4, containing 3% glutaraldehyde. Tissue was then placed in the phosphate buffer containing 6.85% sucrose for 30 min and transferred to 0.1 M phosphate buffer containing 1% OsO<sub>4</sub> for 2 h. Tissues were dehydrated in increasing concentrations of ethanol, rinsed with propylene oxide, and embedded in Araldite resin according to standard procedures. 80-nm-thick sections were examined using a JEOL 100 CX transmission electron microscope.

**Ultrastructural immunocytochemistry.** Tissue was fixed for 24 h in 0.1 M phosphate buffer, pH 7.4, containing 1% glutaraldehyde and 0.2% picric acid. Specimens were washed in 0.1 M phosphate buffer, pH 7.4, dehydrated to 70% ethanol, and embedded in London Resin white acrylic resin with overnight thermal polymerization at 60°C (25). 85-nm-thick sections were collected on formvar-coated gold slot grids. Colloidal gold particles 7–15 µm in diameter were prepared using tannic acid and citrate as reducing agents (26). Goat anti-rabbit IgG (Tago Inc., Burlingame, CA) was dialyzed overnight against 0.005 M Hepes buffer, pH 7.0, and bound to the colloidal gold (27). Thin sections on grids were incubated overnight on drops of rabbit anti-human AAT (Dako Corp., Santa Barbara, CA) in PBS. Controls were incubated with no primary antiserum and with rabbit antisera against other antigens. After washing in PBS with 0.5% BSA, sections were incubated for 30 min on drops of goat-anti-rabbit-IgG-gold in PBS. Sections were rinsed and stained with 2% uranium acetate.

**S<sub>1</sub>-nuclease protection assays.** Total RNA was prepared from tissues by the method of Chirgwin et al. (28). 10 µg of total RNA from liver and kidney and 50 µg from remaining organs were analyzed. Adrenal glands from six animals were pooled before the preparation of total RNA. Larger samples were chosen because immunohistochemistry had revealed intracellular AAT in a small subpopulation of cells in these tissues. The RNA samples were hybridized to a 1,400-nucleotide <sup>32</sup>P-end-labeled human AAT cDNA probe containing the 5' noncoding region, in which sequence homologies were minimal between mouse and human cDNAs. Unprotected probe was digested with S<sub>1</sub> nuclease and nucleic acids were precipitated, dried, and resuspended in an alkaline buffer to degrade RNA.

Electrophoresis was performed on remaining cDNA fragments in a 1.2% agarose gel. The gel was dried and radiolabeled cDNA fragments were visualized by autoradiography. Details of the procedure have been reported (12).

## Results

### *Demonstration of human AAT in tissues of transgenic mice*

**Liver.** Immunoperoxidase staining of liver sections from transgenic mice revealed AAT within hepatocytes and Kupffer cells. Positive cells were most frequently pericentral in location. Intensity varied from weak diffuse staining (10 gene copies) to globular aggregates (100 gene copies) of AAT within 5–30% of the hepatocytes, with similar distributions seen in the PAS-stained sections. Aggregates could be located within the RER by electron microscopy (Fig. 1 A). Transgenic mouse liver containing abundant AAT by immunoperoxidase stain-

ing was not stained when the antibody to human alpha<sub>1</sub>-antichymotrypsin was substituted (polyclonal goat antibody; Dako Corp.).

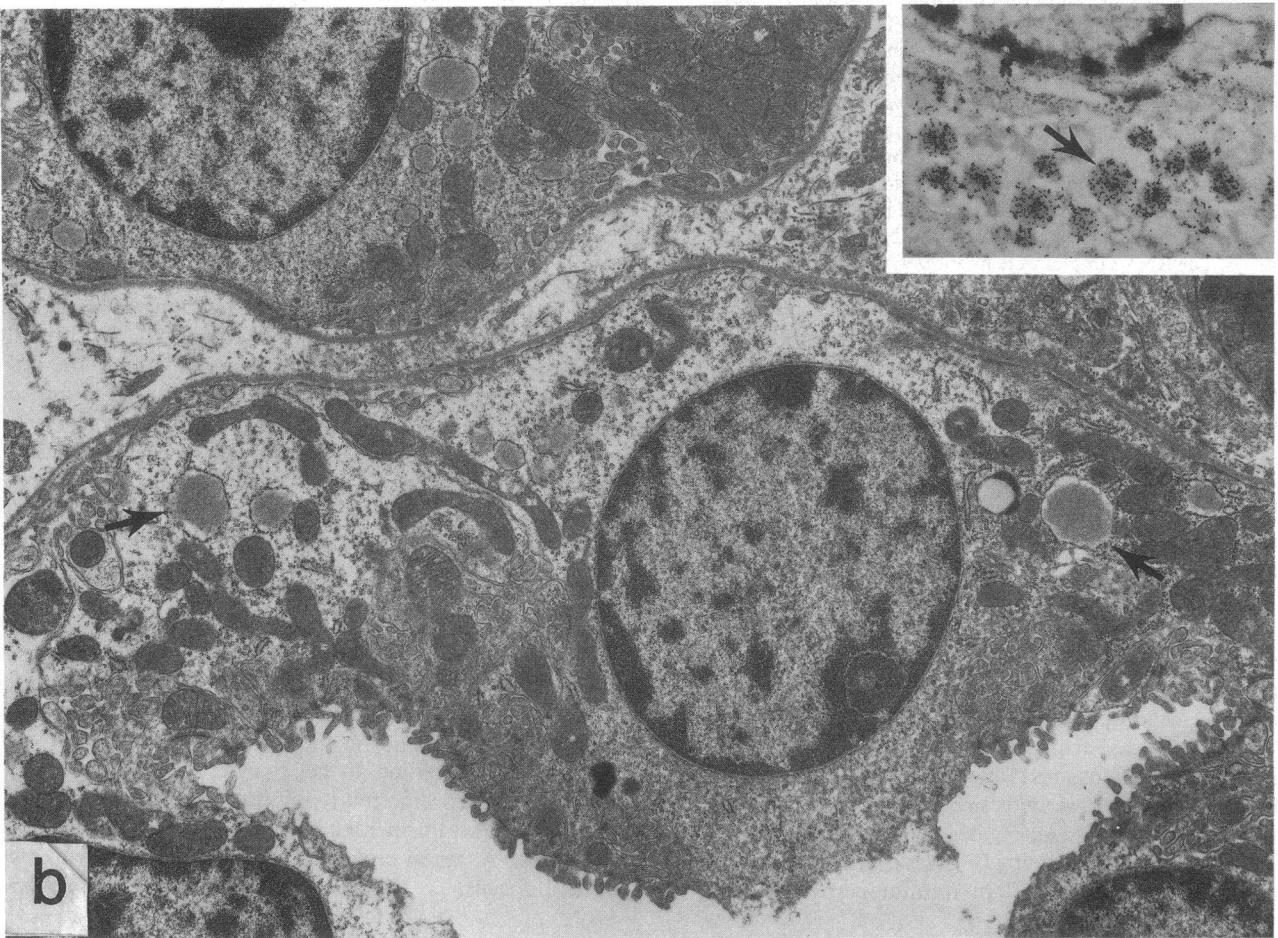
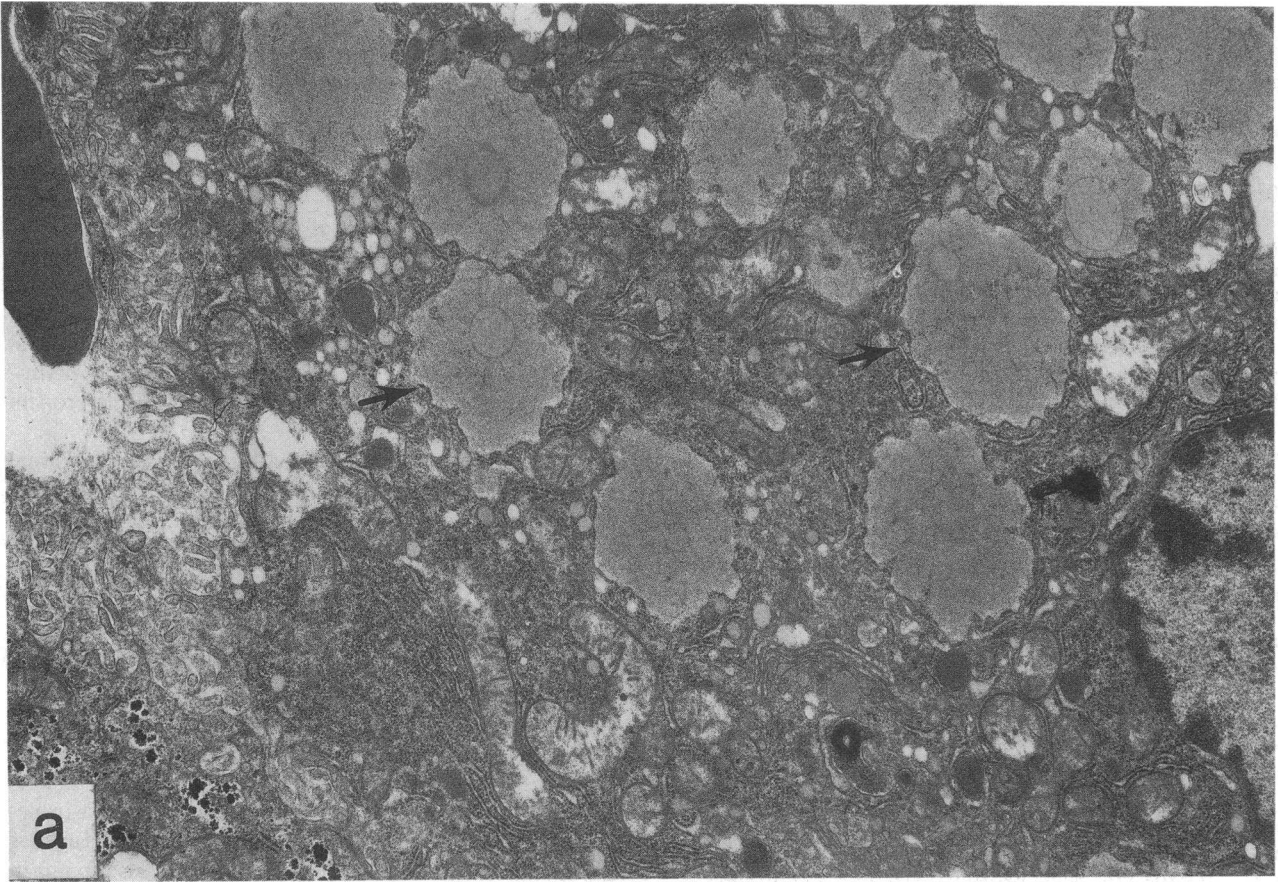
**Nonhepatic tissues.** Abundant staining was seen in the renal medulla in all mice (Fig. 2 A) with AAT specifically localized by electron microscopy within the RER in the epithelium of the proximal portion of the thin limb of the loop of Henle (Fig. 1 B). Ultrastructural immunostaining with gold-labeled antibody demonstrated that AAT was present exclusively in the RER (Fig. 1 B, inset) and not in lysosomal or other vesicles. Focal staining was also seen within cortical tubules. In the lungs, AAT was demonstrated in histiocytes, some interstitial cells, and chondrocytes of the bronchi (Fig. 2 B).

Abundant staining was seen within the gastrointestinal tract. Nonparietal cells of the gastric mucosa in both the fundus and antral regions stained positively (Fig. 2 C). Variable staining was seen in the Paneth and goblet cells of the proximal and distal small intestine (Fig. 2 D). More constant but less intense staining was seen in the perinuclear region of small intestinal crypt epithelial cells (Figs. 2 D and 1 C). Immunoelectron microscopy confirmed the presence of AAT within the RER of these cells (Fig. 1 C, inset). No gold particles could be seen elsewhere in the cells. Cells of probable neuroendocrine function were also stained by the immunoperoxidase technique.

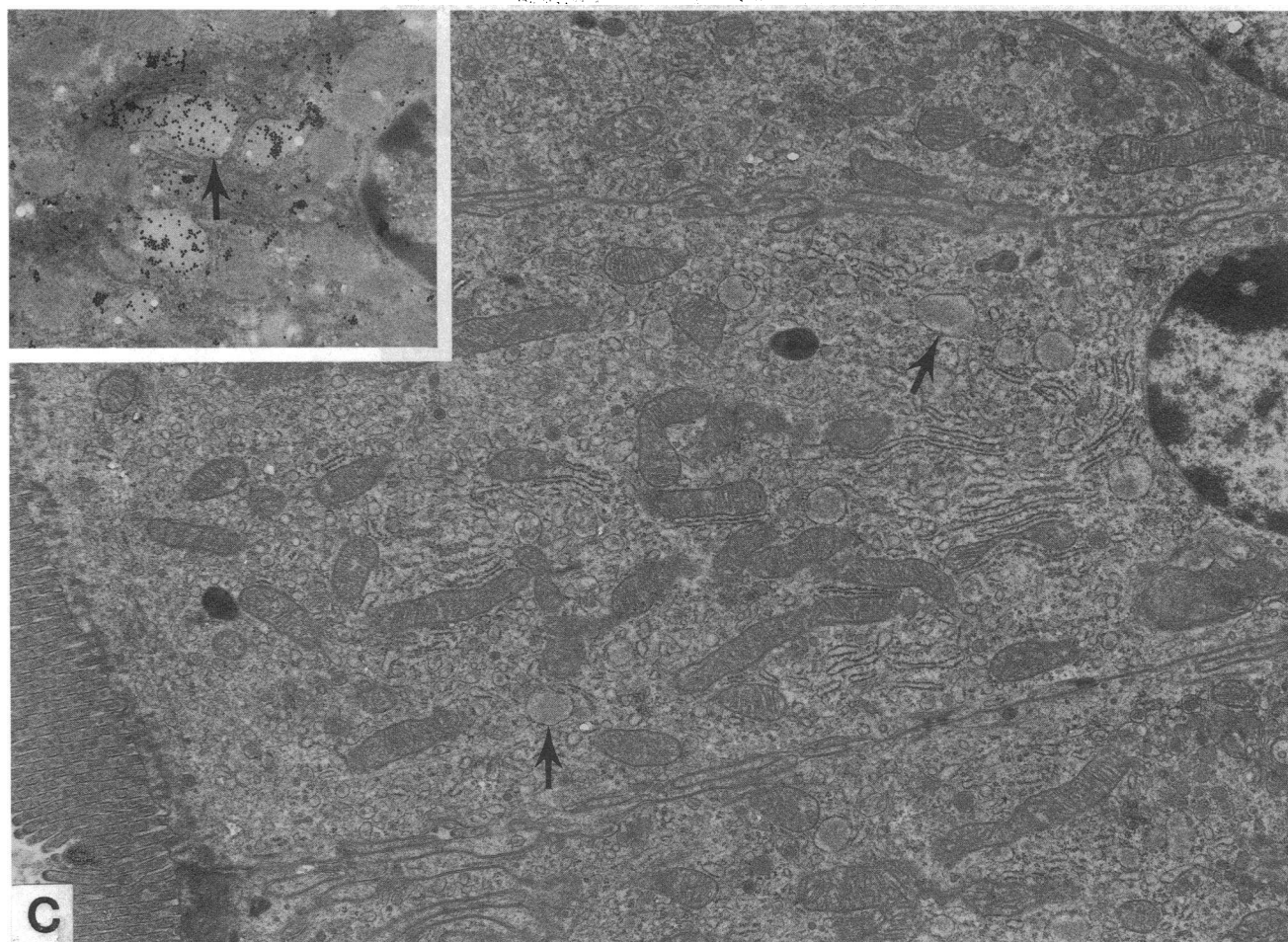
Less abundant but unequivocal staining was seen in peripheral cells of the islets of Langerhans within the pancreas (Fig. 2 E) and in rare acinar cells. Staining was also found in neurons of the central nervous system (CNS) (Fig. 2 F). In some animals, staining was also seen in the Sertoli cells of the testes, in the zona glomerulosa of the adrenal glands (Fig. 2 G), and in the sebaceous glands of the skin (Fig. 2 H). The remainder of the tissues examined failed to show AAT staining in epithelial or parenchymal cells. In tissues where macrophages were present, however, these cells stained positively.

### *Human AAT gene is expressed in corresponding tissues in transgenic mice*

To verify that intracellular AAT in the multiple transgenic mouse organs listed above resulted from de novo synthesis, S<sub>1</sub> nuclease analysis of human AAT mRNA was performed. Human species-specific mRNA corresponding to a 700-nucleotide fragment using S<sub>1</sub> nuclease analysis, was found in mouse liver, kidney, stomach, proximal and distal small intestine, pancreas, and adrenal glands (Fig. 3). This corresponded to immunoperoxidase staining of epithelial or parenchymal cells in these organs. Hybridization was also seen with total RNA from the brain. The protected band was < 700 nucleotides, however, possibly indicating posttranscriptional modification of the mRNA (Sifers, R. N., data not shown). Hybridization was present in total RNA from the lung, female reproductive organs (not shown), testes, spleen, thymus, and colon (Fig. 3). These findings correspond to the immunoperoxidase staining of AAT within bronchial chondrocytes and in cells of monocytic origin, but not in the major parenchymal cells of these organs. In addition to hepatocytes and monocytes, a number of other specific cell types thus appear to express the human AAT gene. Further studies, including in situ detection of AAT mRNA, are in progress to confirm de novo synthesis in particular cells.







**Figure 1.** Electron microscopy of tissues from transgenic mice with 100 copies of the human AAT gene. (A) Hepatocyte ( $\times 31,500$ ). (B) A renal tubular epithelial cell ( $\times 9,500$ ); *inset*, immunocytochemistry ( $\times 13,000$ ). (C) A small intestinal epithelial cell ( $\times 12,300$ ); *inset*, immunocytochemistry ( $\times 21,000$ ). In all micrographs, distended

loops of the RER may be seen containing human AAT (arrows). The insets in B and C show colloidal gold particles affixed to antibody localized exclusively to the endoplasmic reticulum contents. No lysosomal or vesicular particles were found.

#### *Detection of AAT in human organs*

AAT was found by immunohistochemistry in human pancreatic islets and in scattered cells of pancreatic acini and ducts. Human kidneys stained positively in the thin limb of the loop of Henle and some cortical renal tubules. AAT was seen in multiple cells of the gastric mucosa (Fig. 4 A), the goblet cells of the human small intestine (Fig. 4 B), and in some neurons of the human CNS (Fig. 4 C). Macrophages or histiocytes within numerous organs stained positively for AAT, as did epithelial cells lining the hair follicles (not shown). Any AAT present in human liver, adrenals, bronchial cartilage, or testes was below the limit of detection by the immunoperoxidase method used.

#### **Discussion**

ATT is the major antiprotease in human extracellular fluids, with specificity against a number of serine proteases. The relative inhibitory capacity of AAT against proteolytic enzymes may be summarized as leukocyte elastase > chymotrypsin > cathepsin G > anionic trypsin > cationic trypsin > plasmin

> thrombin (1). It is also known to inhibit urinary and pancreatic tissue kallikreins, renin, urokinase, acrosin, and skin and synovial collagenase (29). Due to the relative association rates for the protease-antiprotease complexes and the clinical finding of emphysema in a large number of AAT-deficient patients, leukocyte elastase inhibition in the lung has been thought to be the main function of AAT in humans (1). If de novo synthesis in a variety of cell types could be established, it would suggest other previously unrecognized functions of this antiprotease.

In this paper we report on tissue expression of AAT in transgenic mice and man. These mice have received the normal (PiM) human structural gene of AAT along with 2.0 kb of its 5' flanking region. The length of the flanking region is apparently adequate to include the promoter, the enhancer, and tissue-specific *cis*-acting elements. Integration of multiple copies of the gene into the host DNA has led to higher levels of expression than normally occur in humans. This enhanced synthesis of AAT facilitates its detection in specific cell types and permits further study. Immunoperoxidase techniques thus have been used to demonstrate AAT within specific cell types



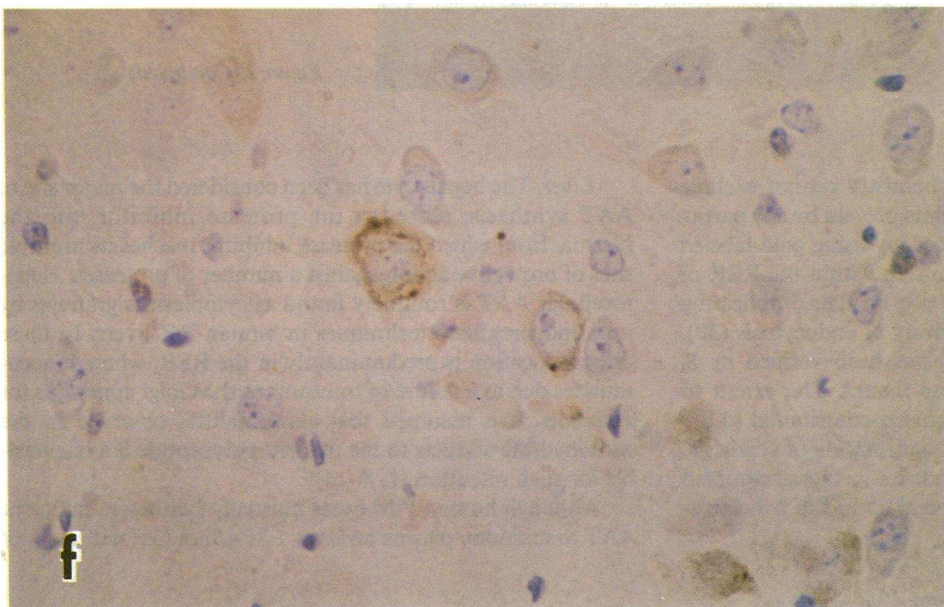
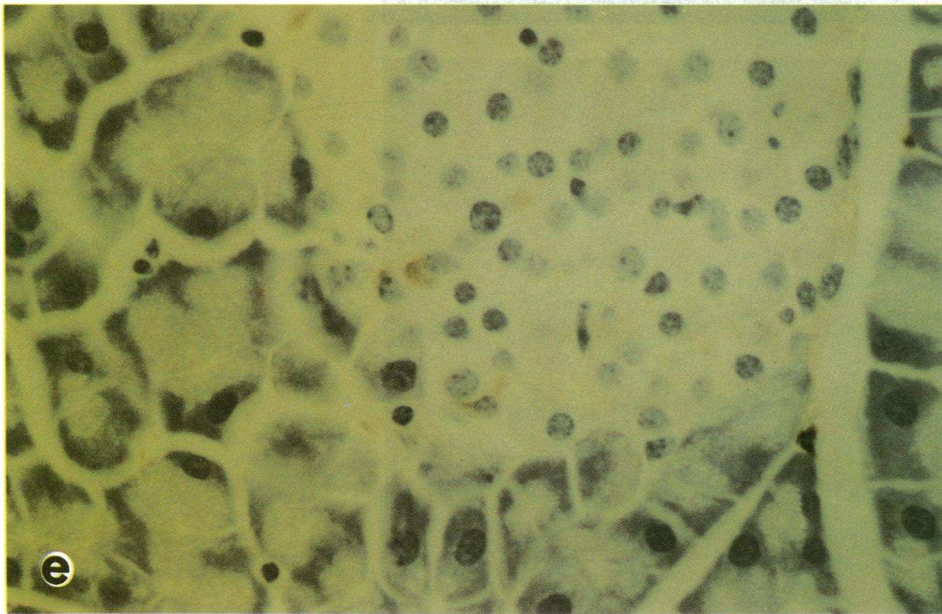
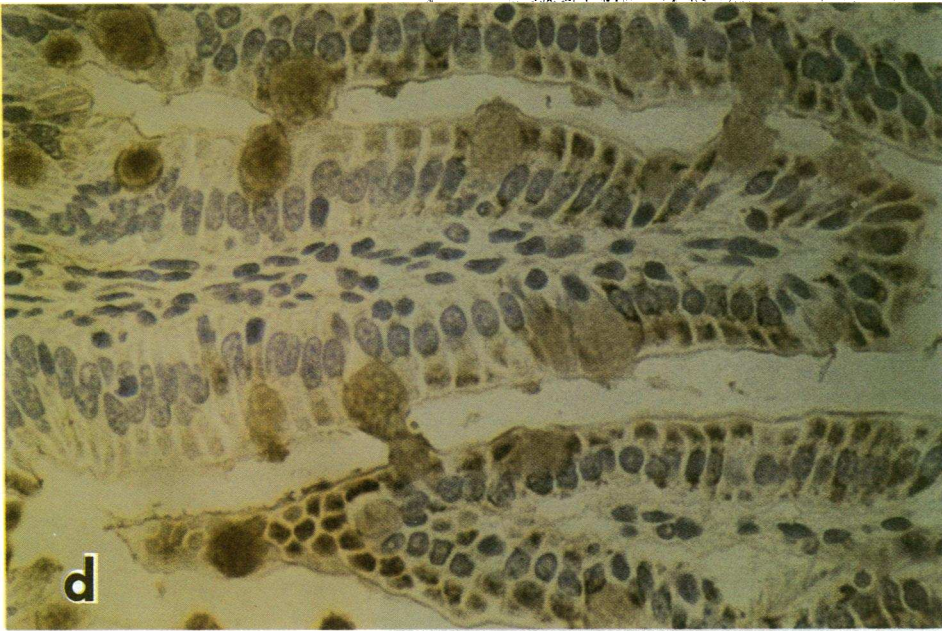


Figure 2 (Continued)



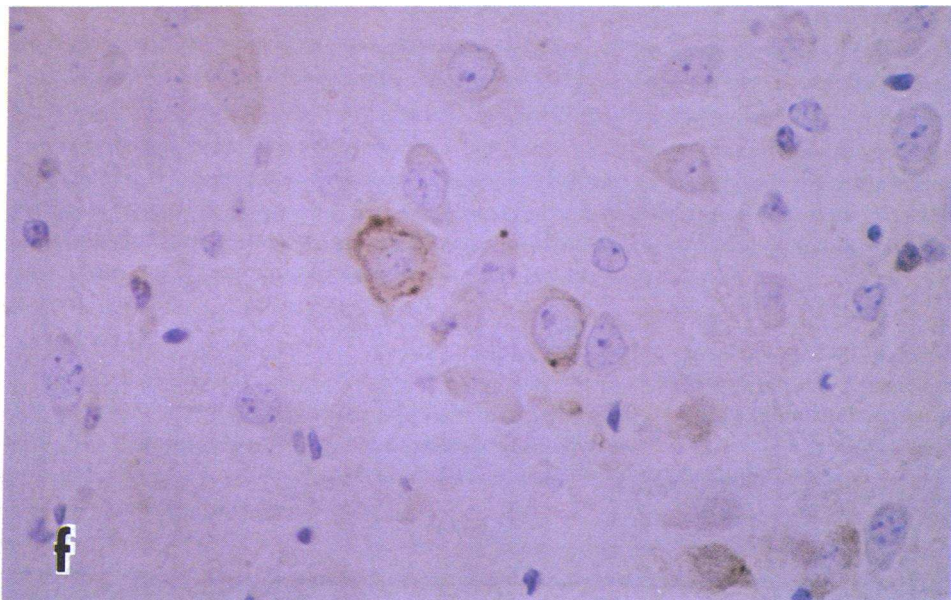
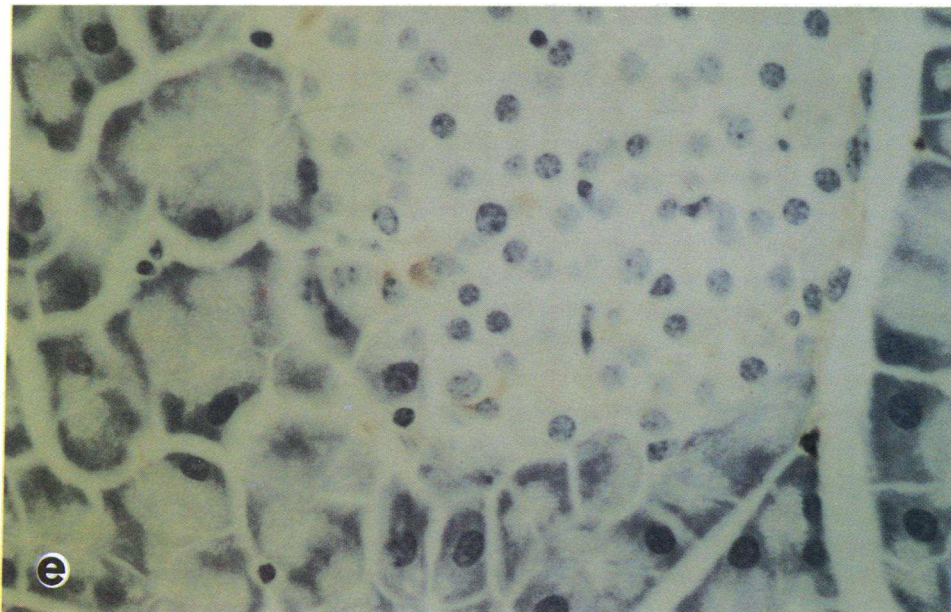
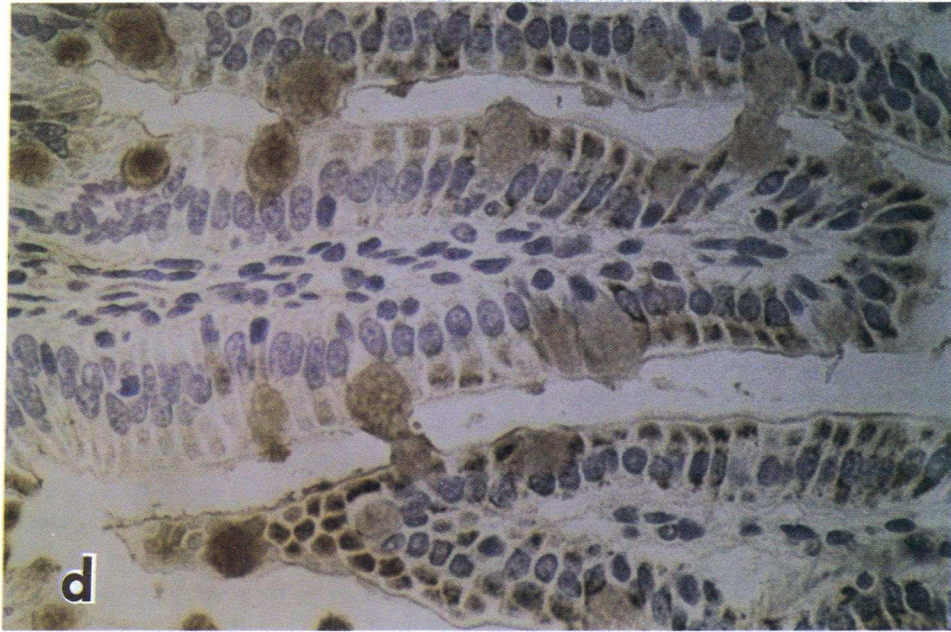


Figure 2 (Continued)



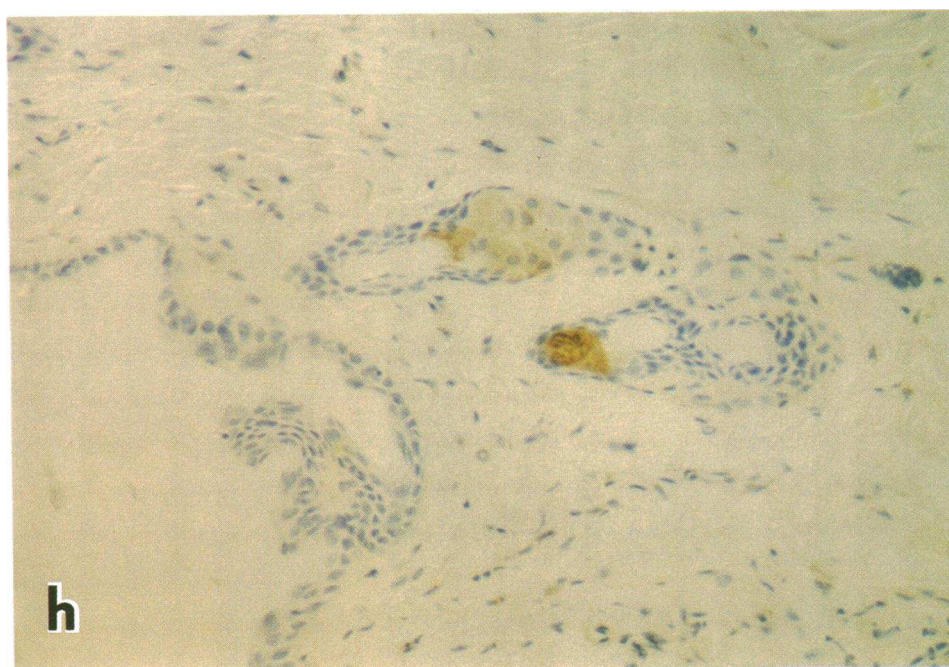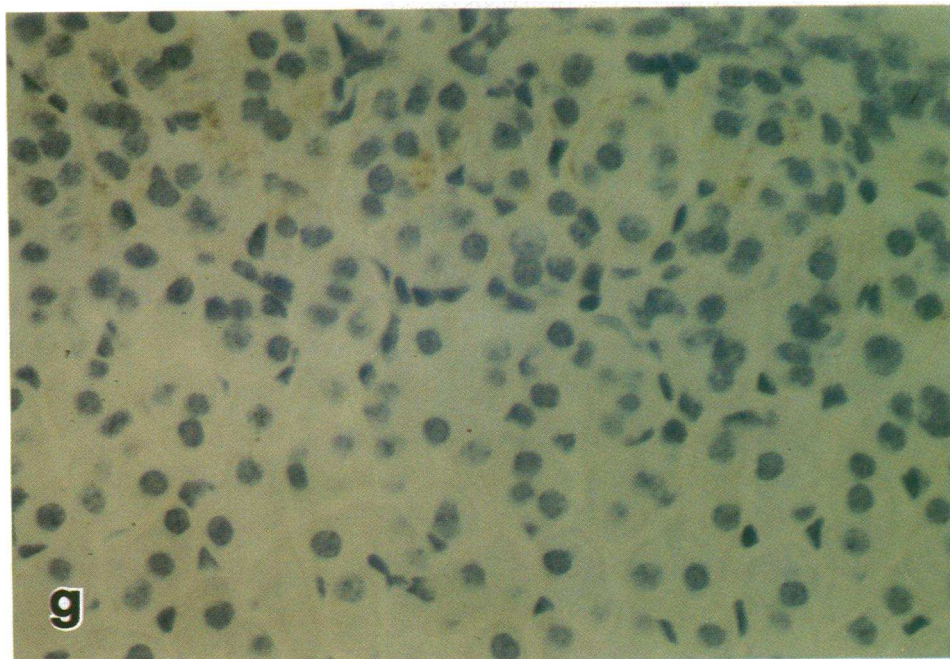


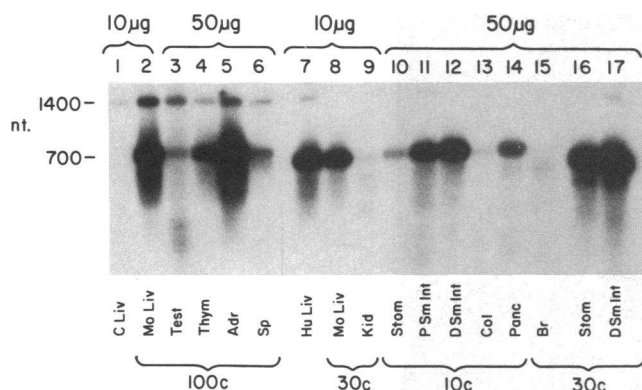
Figure 2 (Continued)

in numerous tissues. Immunohistochemistry cannot exclude the possibility of endocytosis of a plasma protein by any particular cell, but immunoelectron microscopy using gold-labeled antibodies has shown the nascent protein within the RER of specific cell types. At present there are no data implicating involvement of the RER in the pathway of endocytosis (30). De novo synthesis of human AAT has been verified by  $S_1$  nuclease analysis of RNA from these tissues. The extent to which mRNA from resident macrophages contributed to the total detected is unknown. Ultimate confirmation of synthesis, as opposed to endocytosis and protease-antiprotease complex formation in these locations, will depend on in situ hybridization for mRNA, which is in progress.

**Liver.** The hepatocyte has been considered the major site of AAT synthesis, secreting the protease inhibitor into the plasma, from which the protease inhibitor reaches its multiple sites of protective action against a number of proteases. Hepatocellular AAT is routinely found as cytoplasmic granules by immunoperoxidase techniques in human PiZ livers. In these cells its location is predominantly in the RER, where it accumulates due to a failure of transport to the Golgi apparatus for secretion. It is assumed that abnormalities observed in the carbohydrate adducts to the nascent polypeptide are responsible for such retention (1, 8, 14).

Although human PiM livers normally synthesize sufficient AAT to maintain plasma levels at 1.35 g/liter (31) with a  $t_{1/2}$  of





**Figure 3.** Demonstration of human AAT mRNA in tissues from transgenic mice. The  $S_1$  nuclease protection analysis was performed on 10 or 50  $\mu$ g of total RNA from tissues. The bands at 700 nucleotides indicate the presence of human AAT mRNA; the 1,400-nucleotide band is residual probe. Lane 1, nontransgenic (control) mouse liver; lane 7, human liver; all other lanes show transgenic mouse tissue RNA. Lane 2, liver; lane 3, testes; lane 4, thymus; lane 5, adrenals; lane 6, spleen; lane 8, liver; lane 9, kidney; lane 10, stomach; lane 11, proximal small intestine; lane 12, distal small intestine; lane 13, colon; lane 14, pancreas; lane 15, brain; lane 16, stomach; and lane 17, distal small intestine. Lanes 2–6 are from mice with 100 gene copies. Lanes 10–14 are from mice with 10 gene copies and remaining lanes are from mice with 30 gene copies per cell. The band from the brain in lane 15 has < 700 nucleotides, possibly because of posttranscriptional modification.

6 d (32); intracellular levels are normally below the limits of detection by immunoperoxidase staining. Negative staining thus should not be equated with lack of synthesis in any cell type studied. In subjects with phenotype PiM who are in extreme acute phase situations with high plasma AAT levels, or in some persons with cirrhosis, globular inclusions have also been seen (33). Transgenic mice with high gene copy numbers per cell have enhanced synthesis of AAT, with plasma levels exceeding those normally seen in humans (12). It was therefore not surprising to find globular inclusions in the hepatocytes of such mice. The localization of AAT in the mice was predominantly in pericentral hepatocytes, contradicting an earlier report of periportal distribution of endogenous AAT in normal CBA/J mice (34). The number of AAT-positive cells was correlated with gene copy number and plasma AAT levels. The difference in AAT distribution between the human PiZ livers and these mouse livers may be related to differences in metabolism across the lobule in the two species. In humans it is known that periportal hepatocytes are more actively involved in the synthesis and secretion of export proteins, whereas pericentral hepatocytes contain higher levels of detoxifying enzymes (35). Mice metabolize numerous drugs much more rapidly than man or rats (36). Distributional differences thus may depend on slight functional differences between the two species. Alternatively, centrilobular staining may reflect a lower efficiency of protein secretion from the centrilobular cells.

**Lung.** AAT is normally present in extracellular fluids in the lung (1). It is also synthesized by alveolar macrophages (10, 11). The relative importance of the contributions from these two sites in preventing emphysema is not yet clear. As expected, AAT was seen in the interstitial cells and alveolar macrophages of transgenic mouse lungs. One animal with chronic

pneumonia had abundant staining in inflammatory cells. AAT was also found in bronchial chondrocytes, which had not been observed previously. Aside from its antiproteolytic effects, exogenous AAT has been shown to decrease the abnormally high lymphocyte response to PHA in AAT-deficient subjects (37), suggesting an immunoregulatory role for the normal protein. The relevance of these findings to clinical lung disease in PiZ humans remains to be evaluated.

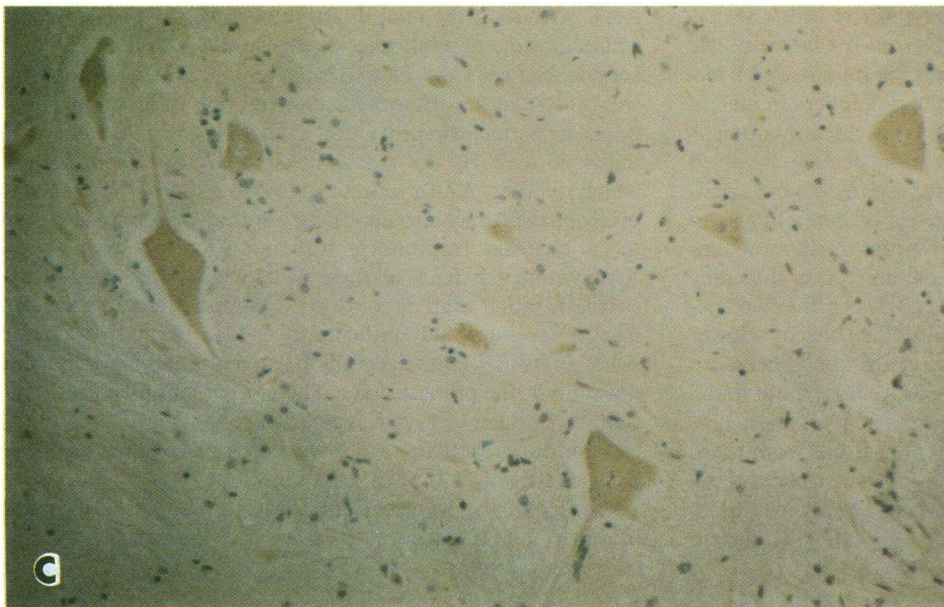
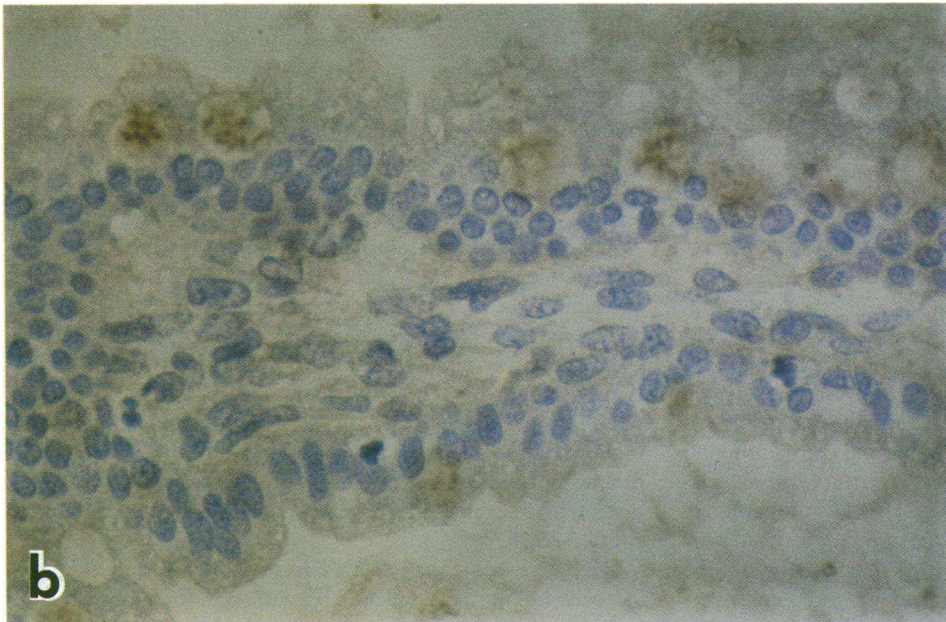
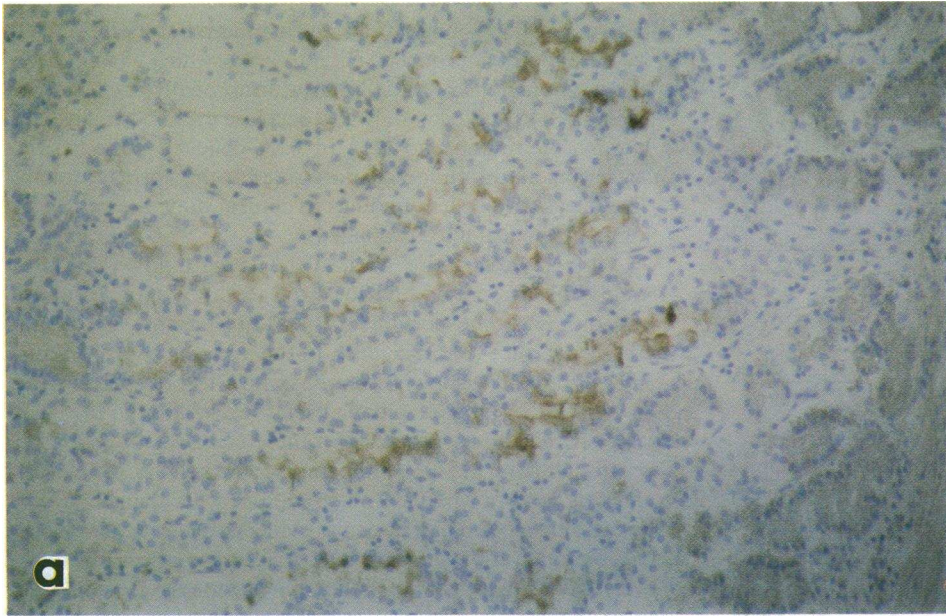
**Kidney.** Presence of AAT in the human kidney has previously been reported and localized to the proximal tubules and the ascending portion of the loop of Henle (8). In the transgenic mice AAT was seen in the same locations. Immunoelectron microscopy has demonstrated the presence of AAT in the RER of tubular epithelial cells; localization to the RER suggests that it is synthesized in these cells. As no gold label was found over the Golgi apparatus, whether the AAT is secreted is not known. That no structures other than RER cisternae were labeled is regarded as evidence against endocytosis of the protein from the plasma (30). It was not possible, however, to control for the possibility that plasma AAT complexed to an endogenous enzyme was being identified by immunocytochemistry. AAT is known to be a weak inhibitor of urinary tissue kallikrein and a stronger inhibitor of asialokallikrein (38). It is also a moderately effective inhibitor of urokinase (29). A protease inhibitor thus may be synthesized and secreted locally to protect the urinary tract against attack by endogenous and exogenous proteases.

**Gastrointestinal tract.** AAT was found within the gastrointestinal tract of the transgenic mice. Its presence in human gastric and small intestinal mucosa as demonstrated immunocytochemically has been reported previously (3–8). Tahara et al. found AAT in normal gastric mucosa in cells that did not produce gastrin or somatostatin and were not parietal cells (4). Others reported large amounts of AAT in gastric neuroendocrine tumors with the histologic pattern of carcinoid tumors, but these neuroendocrine tumors did not appear to secrete 5-hydroxyindolacetic acid, gastrin, or serotonin (3). The exact function of the gastric AAT-containing cells in our transgenic mice remains uncertain. The parietal cells do not appear to contain AAT.

Geboes et al. (5) noted AAT in the small intestinal epithelial cells but not in goblet or Paneth cells of human tissue. Kelsey et al. (39) have recently noted the expression of human AAT mRNA in the fetal intestine of transgenic mice. In the small intestine of adult mice in this study, AAT was found in some goblet cells and Paneth cells. Staining of lower intensity was present in the absorptive epithelial cells of the small intestine. The  $S_1$  nuclease protection assay clearly indicates biosynthesis of AAT by the small intestine, but does not specify which cell type. AAT synthesized in one cell type (i.e., resident macrophages) may also appear in another cell type secondary to endocytosis. Immunoelectron microscopy demonstrated AAT within the RER of these cells, which strongly suggests synthesis rather than endocytosis. Mucus adhering to the surface of the intestinal epithelial layer also stained darkly for AAT. Intestinal epithelial cells from nontransgenic mice did not stain in the present study. These observations suggest that staining in these cell types is not due to nonspecific glycoprotein immunoreactivity. AAT was also seen within probable neuroendocrine cells of the small intestine.

Synthesis of a protease inhibitor in secretory cells of the gut may be essential to protect the epithelium from attack by pan-





*Figure 4.* Immunoperoxidase staining of AAT in human tissue sections from (A) gastric mucosa ( $\times 100$ ), (B) small intestinal mucosa ( $\times 400$ ), and (C) neural tissue ( $\times 400$ ).



creatic proteases. Similarly, although the enteropancreatic circulation of pancreatic enzymes remains controversial, AAT in absorptive cells could protect them and other tissues from proteolytic digestion. AAT-containing cells have been reported absent in human celiac disease (5, 7). This may have some importance in the pathogenesis of villus atrophy in that condition (5). Other authors have found no increase of AAT deficiency phenotypes in 103 children (40) or 18 adults with celiac disease (41). The absence of AAT-containing cells in this disease thus may be secondary to the general atrophy or destruction of these cells.

Demonstration of AAT in simple or complex form (42) in human stool or gastric secretions from patients with Menetrier's disease (43), protein-losing gastroenteropathy (44, 45), and inflammatory bowel disease (46) have been interpreted to indicate exudation of plasma proteins in this condition. Awareness of de novo synthesis in mucosal cells of the gastrointestinal tract may alter this interpretation. The high fecal AAT levels found in children with celiac disease (45) might indicate rapid cell turnover and destruction within the gastrointestinal tract. Further studies may reveal the importance of this protein as a defense against peptic ulcer disease (19), and improve understanding of the protease-antiprotease balance in the gastrointestinal tract.

**Pancreas.** AAT is found in the pancreatic islets of Langerhans. It is also seen in rare acinar cells. Human studies have shown AAT in islet endocrine cells which do not produce any known pancreatic hormone (2, 47), but de novo synthesis has not been demonstrated. Cases of islet cell hyperplasia (48) and islet cell tumor in human PiZ subjects may be related to these findings. Exocrine pancreatic disease has also been associated with AAT deficiency (20, 49).

**Other tissues.** Human sperm have previously been shown to contain AAT (8). The importance of proteolysis for penetration of cervical mucus and the zona pellucida has been well documented. An endogenous protective factor in sperm thus might inhibit proteolytic attack before fertilization.

AAT was also present in the sebaceous glands in the skin of transgenic mice, and was seen in human hair follicles in this study. These findings may be related to the unusual but dramatic occurrence of panniculitis in PiZ human subjects (21).

AAT appears to be present in neuroendocrine cells of the gastrointestinal tract and pancreas. It is also found within specific neurons in the brain and in the adrenal cortex. These findings are also in agreement with earlier immunochemical data concerning humans (50). The function of the AAT in these locations has not been determined.

**Conclusion.** Transgenic mice bearing multiple copies of the normal human PiM AAT gene have been studied. These mice contain the human gene product in a multitude of specific cell types within the liver, kidney, gastrointestinal tract, pancreas, brain, adrenal glands, and testes. These findings correspond to previous and present studies of the distribution of AAT in human tissues. In this animal model system, it has also been possible to demonstrate de novo protein synthesis by the S<sub>1</sub> nuclease protection assay for human AAT mRNA. By means of immunoelectron microscopy using gold-labeled antibodies to alpha<sub>1</sub>-antitrypsin, localization of the protein to the RER of intestinal and renal tubular epithelial cells has been observed. This strongly suggests synthesis rather than endocytosis by those cells. These mice with greatly enhanced expression of the human gene should facilitate further studies on the impor-

tance of the protease-antiprotease balance and its relationship to human disease.

## Acknowledgments

The authors wish to express their gratitude to Mrs. Billie Smith for expert immunohistochemical preparations and to Ms. Linda Rehm for valuable assistance in ultrastructural immunocytochemistry.

This work was partially supported by National Institutes of Health (NIH) grants HL-27509 and HL-37188 to Dr. Woo, who is also an investigator of the Howard Hughes Medical Institute. Dr. Carlson was supported by NIH training grant AM-07479. Dr. Sifers is the recipient of NIH postdoctoral fellowship HL-07343.

## References

1. Carrell, R. W., J.-O. Jeppsson, C.-B. Laurell, S. O. Bennan, M. C. Owen, L. Vaughan, and D. R. Boswell. 1982. Structure and variation of human alpha-1-antitrypsin. *Nature (Lond.)* 298:329-334.
2. Ray, M. B., V. J. Desmet, and W. Gepts. 1977. Alpha-1-antitrypsin immunoreactivity in islet cells of adult human pancreas. *Cell Tissue Res.* 185:63-68.
3. Ray, M. B., K. Gebos, F. Callea, and V. J. Desmet. 1982. Alpha-1-antitrypsin immunoreactivity in gastric carcinoid. *Histopathology* 6:289-297.
4. Tahara, E., H. Ito, K. Taniyama, H. Yokozaki, and J. Hata. 1984. Alpha-1-antitrypsin, alpha-1-antichymotrypsin, and alpha-2-macroglobulin in human gastric carcinomas: a retrospective immunohistochemical study. *Hum. Pathol.* 15:957-964.
5. Geboes, K., M. B. Ray, P. Rutgeerts, F. Callea, V. J. Desmet, and G. Vantrappen. 1982. Morphological identification of alpha-1-antitrypsin in the human cell intestine. *Histopathology (Oxf.)* 6:55-60.
6. Kittas, C., K. Aroni, A. Matani, and C. S. Papadimitriou. 1982. Immunocytochemical demonstration of alpha-1-antitrypsin and alpha-1-antichymotrypsin in human gastrointestinal tract. *Hepato-gastroenterology* 29:275-277.
7. Nielsen, K. 1984. Coeliac disease: alpha-1-antitrypsin contents in jejunal mucosa before and after gluten-free diet. *Histopathology (Oxf.)* 8:759-764.
8. Callea, F. 1983. Immunohistochemical study on alpha-1-antitrypsin. PhD thesis. Katholieke Universiteit te Leuven, Leuven, Belgium. 153 pp.
9. Carlson J., and J. Stenflo. 1982. The biosynthesis of rat alpha-1-antitrypsin. *J. Biol. Chem.* 257:12987-12994.
10. Perlmutter, D. H., F. S. Cole, P. Kilbridge, T. H. Rossing, and H. R. Colten. 1985. Expression of the alpha-1-proteinase inhibitor gene in human monocytes and macrophages. *Proc. Natl. Acad. Sci. USA* 82:795-799.
11. Mornex, J. F., A. Chytii-Weir, M. Courtney, J. P. LeCocq, and R. G. Crystal. 1986. Expression of the alpha-1-antitrypsin gene in mononuclear phagocytes of normal and alpha-1-antitrypsin deficient individuals. *J. Clin. Invest.* 77:1952-1961.
12. Sifers, R. N., J. A. Carlson, S. M. Clift, F. J. DeMayo, D. W. Bullock, and S. L. C. Woo. 1987. Tissue specific expression of the human alpha-1-antitrypsin gene in transgenic mice. *Nucleic Acids Res.* 15:1459-1475.
13. Laurell, C. B., and S. Eriksson. 1963. The electrophoretic alpha-1-globulin pattern of serum in alpha-1-antitrypsin deficiency. *Scand. J. Clin. Lab. Invest.* 15:132-140.
14. Sharp, H. L., R. A. Bridges, W. Krivit, and E. F. Freier. 1969. Cirrhosis associated with alpha-1-antitrypsin deficiency: a previously unrecognized inherited disorder. *J. Lab. Clin. Med.* 73:934-939.
15. Eriksson, S., J. Carlson, and R. Velez. 1986. Increased risk for cirrhosis and hepatoma in homozygous alpha-1-antitrypsin deficiency. *N. Engl. J. Med.* 314:736-739.
16. Orell, S. R., and P. Mazodier. 1966. Pathological findings in alpha-1-antitrypsin deficiency. In *Pulmonary Emphysema and Proteolysis*. C. Mittman, editor. Academic Press, New York. 69-81.

17. Miller, F., and M. Kuschner. 1969. Alpha-1-antitrypsin deficiency, emphysema, necrotizing angitis and glomerulonephritis. *Am. J. Med.* 46:615-619.
18. Moroz, S. P., E. Cutz, J. W. Balfe, and A. Sass-Kortsak. 1976. Membranoproliferative glomerulonephritis in childhood cirrhosis associated with alpha-1-antitrypsin deficiency. *Pediatrics.* 57:232-238.
19. Andre, F., C. Andre, R. Lambert, and F. Descos. 1974. Prevalence of alpha-1-antitrypsin deficiency in patients with gastric or duodenal ulcer. *Biomedicine.* 21:222-224.
20. Novis, B. H., G. O. Young, S. Bank, and I. N. Marks. 1975. Chronic pancreatitis and alpha-1-antitrypsin. *Lancet.* ii:748-749.
21. Viraben, R., P. Massip, B. Dicostranzo, and C. Mathieu. 1986. Necrotic panniculitis with alpha-1-antitrypsin deficiency. *J. Am. Acad. Dermatol.* 14:684-687.
22. Gianazza, E., and P. Arnaud. 1982. A general method for fractionation of plasma proteins. *Biochem. J.* 201:129-136.
23. Burnette, W. N. 1981. "Western blotting": electrophoretic transfer of proteins from sodium dodecyl sulfate-polyacrylamide gels to unmodified nitrocellulose and radiographic detection with antibody and radioiodinated protein A. *Anal. Biochem.* 112:195-203.
24. Taylor, C. R. 1978. Immunoperoxidase technique. practical and theoretical aspects. *Arch. Pathol. Lab. Med.* 102:113-121.
25. Newman, G. R., B. Jasani, and E. D. Williams. 1983. A simple post-embedding system for the rapid demonstration of tissue antigens under the electron microscope. *Histochem. J.* 15:543-555.
26. Slot, J. W., and H. J. Geuze. 1985. A new method of preparing gold probes for multiple-labeling cytochemistry. *Eur. J. Cell Biol.* 38:87-93.
27. Horisberger, M. 1981. Colloidal gold: a cytochemical marker for light and fluorescent microscopy and for transmission and scanning electron microscopy. *Scanning Electron Microsc.* II:9-31.
28. Chirgwin, J. M., A. E. Przybyla, R. J. MacDonald, and W. J. Rutter. 1979. Preparation of biologically active ribonucleic acid from sources enriched in ribonuclease. *Biochemistry.* 18:5294-5299.
29. Heidtmann, H., and J. Travis. 1986. Human alpha-1-proteinase inhibitor. In *Proteinase Inhibitors*. A. J. Barrett and G. Salvesen, editors. Elsevier/North Holland, Amsterdam. 441-456.
30. Wileman, T., C. Harding, and P. Stahl. 1985. Receptor mediated endocytosis. *Biochem. J.* 232:1-14.
31. Jeppsson, J. O., C. B. Laurell, and M. K. Fagerhol. 1978. Properties of isolated human alpha-1-antitrypsins of Pi types M, S and Z. *Eur. J. Biochem.* 83:143-153.
32. Laurell, C. B., B. Nosslin, and J. O. Jeppsson. 1977. Catabolic rate of alpha-1-antitrypsin of Pi type M and Z in man. *Clin. Sci. Mol. Med.* 52:457-461.
33. Carlson, J., S. Eriksson, and I. Hagerstrand. 1981. Intra- and extracellular alpha-1-antitrypsin in liver disease with special reference to Pi phenotype. *J. Clin. Pathol. (Lond.).* 34:1020-1025.
34. Gauldie, J., L. Lamontagne, P. Horsewood, and E. Jenkins. 1980. Immunohistochemical localization of alpha-1-antitrypsin in normal mouse liver and pancreas. *Am. J. Pathol.* 101:723-736.
35. Jones, A. L., and D. L. Schmucker. 1977. Current concepts of liver structure as related to function. *Gastroenterology.* 73:833-851.
36. Kaplan, H. M., N. R. Brewer, and W. H. Blair. 1983. Physiology. In *The Mouse in Biomedical Research*. III. Normative Biology, Immunology and Husbandry. H. L. Foster, J. D. Small, and J. G. Fox, editors. Academic Press, New York. 259-260.
37. Breit, S. N., D. Wakefield, J. P. Robinson, E. Luckhurst, P. Clark, and R. Penny. 1985. The role of alpha-1-antitrypsin deficiency in the pathogenesis of immune disorders. *Clin. Immunol. Immunopathol.* 35:363-380.
38. Hirano, K., Y. Okumura, S. Hayakawa, T. Adachi, and M. Sigiura. 1984. Inhibition of human tissue kallikrein by alpha-1-proteinase inhibitor. *Hoppe-Seyler's Z. Physiol. Chem.* 365:27-32.
39. Kelsey, G. D., S. Povey, A. E. Bygrave, and R. H. Lovell-Badge. 1987. Species- and tissue-specific expression of human alpha-1-antitrypsin in transgenic mice. *Genes and Development.* 1:161-171.
40. Klasen, E. C., I. Polanco, I. Biemond, C. Vazquez, and A. S. Pena. Alpha-1-antitrypsin and coeliac disease in Spain. *Gut.* 21:948-950.
41. Vegnente, A., P. Toscano, V. Nuzzo, G. Ambrogio, and R. Sollazzo. 1984. Serum levels and phenotypes of alpha-1-antitrypsin in coeliac disease. *Minerva Pediatr.* 36:831-834.
42. Buffone, G. J., and R. J. Shulman. 1985. Characterization and evaluation of immunochemical methods for the measurement of fecal alpha-1-antitrypsin. *Am. J. Clin. Pathol.* 83:326-330.
43. Reinhart, W. H., K. Weigand, M. Kappeler, H. Roesler, and F. Halter. 1983. Comparison of gastrointestinal loss of alpha-1-antitrypsin and chromium 51-albumin in Menetrier's disease and the influence of ranitidine. *Digestion.* 26:192-196.
44. Florent, Ch., N. Vidon, B. Flourie, A. Carmantrand, A. Zerbani, M. Maurel, and J. J. Bernier. 1986. Gastric clearance of alpha-1-antitrypsin under cimetidine perfusion: new test to detect protein-losing gastropathy? *Dig. Dis. Sci.* 31:12-15.
45. Thomas, D. W., F. R. Sinatra, and R. J. Merritt. 1981. Random fecal alpha-1-antitrypsin concentration in children with gastrointestinal disease. *Gastroenterology.* 80:776-782.
46. Grill, B., A. C. Hillemeier, and J. D. Gryboski. 1984. Fecal alpha-1-antitrypsin clearance in patients with inflammatory bowel disease. *J. Pediatr. Gastroenterol. Nutr.* 3:56-61.
47. Ray, M. B., and R. Zumwalt. 1986. Identification of alpha-1-proteinase inhibitor-containing cell in pancreatic islets. *Cell Tissue Res.* 243:677-680.
48. Ray, M. B., and R. Zumwalt. 1986. Islet-cell hyperplasia in genetic deficiency of alpha-1-proteinase inhibitor. *Am. J. Clin. Pathol.* 85:681-687.
49. Callea F., P. Goddeeris, M. B. Ray, K. Geboes, J. Bekaert, and V. J. Desmet. 1983. Presence of alpha-1-antitrypsin in pancreatic carcinoma. Report of four cases in association with hepatic storage of the protease inhibitor. *Appl. Pathol.* 1:290-300.
50. Dziegielewska, K. M., N. R. Saunders, E. J. Schejter, H. Zakut, D. Zevin-Sonkin, R. Zisling, and H. Sorez. 1986. Synthesis of plasma proteins in fetal, adult, and neoplastic human brain tissue. *Dev. Biol.* 115:93-104.