

## **In vivo interaction of antibodies with cell surface antigens. A mechanism responsible for in situ formation of immune deposits in the zona pellucida of rabbit oocytes.**

S Matsuo, ... , J R Brentjens, G Andres

*J Clin Invest.* 1985;**75**(4):1369-1380. <https://doi.org/10.1172/JCI111838>.

### Research Article

It was the aim of this study to test the hypothesis that the interaction of antibodies with antigens expressed on the plasma membrane of cells surrounded by a basement membrane or a basement membrane-like structure results in in situ formation of immune deposits. Ovary was chosen for the experiments because we found that a well-characterized protein, angiotensin-converting enzyme (ACE), is expressed in a diffuse pattern on the plasma membrane of mature oocytes. To investigate the events following the in vivo interaction of oolemma-ACE with its antibody, rabbits were injected with goat anti-rabbit ACE gamma-globulin or with Fab fragments of goat anti-rabbit ACE IgG in an ear vein for a maximum of 4 d; they were followed for up to 20 d thereafter. Ovary tissue was studied by immunofluorescence, and immunoelectron, light, and transmission electron microscopy. The results of this study document two new findings: First, that ACE is expressed on the oolemma of rabbit oocytes. Second, that the in vivo interaction of divalent antibodies to this cell surface antigen induces formation of granular immune deposits in the adjacent zona pellucida through a mechanism of "patching" and "shedding" of immune complexes, similar to that occurring in in vitro systems characterized by interaction of plasma membrane receptors with soluble ligands. This mechanism might have importance in the pathogenesis of Heymann glomerulonephritis and [...]

**Find the latest version:**

<https://jci.me/111838/pdf>



# In Vivo Interaction of Antibodies with Cell Surface Antigens

## A Mechanism Responsible for In Situ Formation of Immune Deposits in the Zona Pellucida of Rabbit Oocytes

Seiichi Matsuo, Peter R. B. Caldwell, Jan R. Brentjens, and Giuseppe Andres

Departments of Pathology, Microbiology and Medicine, School of Medicine, State University of New York at Buffalo, New York, 14214; Renal Research Laboratory, Buffalo General Hospital, Buffalo, New York 14203; Department of Medicine, College of Physicians and Surgeons, Columbia University, New York 10032

### Abstract

It was the aim of this study to test the hypothesis that the interaction of antibodies with antigens expressed on the plasma membrane of cells surrounded by a basement membrane or a basement membrane-like structure results in in situ formation of immune deposits. Ovary was chosen for the experiments because we found that a well-characterized protein, angiotensin-converting enzyme (ACE), is expressed in a diffuse pattern on the plasma membrane of mature oocytes.

To investigate the events following the in vivo interaction of oolemma-ACE with its antibody, rabbits were injected with goat anti-rabbit ACE  $\gamma$ -globulin or with Fab fragments of goat anti-rabbit ACE IgG in an ear vein for a maximum of 4 d; they were followed for up to 20 d thereafter. Ovary tissue was studied by immunofluorescence, and immunoelectron, light, and transmission electron microscopy.

The results of this study document two new findings: First, that ACE is expressed on the oolemma of rabbit oocytes. Second, that the in vivo interaction of divalent antibodies to this cell surface antigen induces formation of granular immune deposits in the adjacent zona pellucida through a mechanism of "patching" and "shedding" of immune complexes, similar to that occurring in in vitro systems characterized by interaction of plasma membrane receptors with soluble ligands. This mechanism might have importance in the pathogenesis of Heymann glomerulonephritis and of other immunological diseases involving antigens expressed on the plasma membrane of cells.

### Introduction

The first evidence that tissue injury may occur as a consequence of in situ formation of antigen-antibody complexes was provided by the study of the Arthus reaction (1). In recent years, other observations have shown that free circulating antibodies reactive with tissue antigens induce immune complex formation and injury in the thyroid (2, 3), testis (4), and in the kidney, affecting tubules (5, 6) or glomeruli (7, 8). In experimental diseases, such as in thyroiditis induced by passive transfer of anti-thyroglobulin antibodies (2, 3), in autoimmune orchitis

occurring after vasectomy (4), and in tubulointerstitial nephritis of rabbits receiving multiple renal allografts (5) or immunized with homologous renal tissue (6), the immune reaction probably involves circulating antibodies reacting with "sequestered" or cytoplasmic antigens leaking out of epithelial cells (6). However, in other models, for instance in Heymann glomerulonephritis induced in rats (7, 8, 9, 10) or mice (11) by passive transfer of antibodies and in tubulointerstitial nephritis of rats immunized with Tamm-Horsfall protein (12), circulating antibodies react with antigens expressed on the plasma membrane of glomerular (13) or tubular (14) epithelial cells. The sequence of events in this in situ immune complex formation and aggregation has not been fully elucidated.

Relevant in this regard might be a recent observation showing that antibodies reacting in vivo with angiotensin-converting enzyme (ACE),<sup>1</sup> an antigen expressed on the plasma membrane of endothelial cells, cause antigenic modulation similar to that observed in other systems where plasma membrane receptors interact with soluble ligands. Antibody-cell surface antigen interaction in rabbits injected with anti-ACE antibodies includes a rapid redistribution of ACE, fixation of complement, and in surviving rabbits, disappearance of ACE from lung endothelial cells. It was proposed that this phenomenon might be relevant to the pathogenesis of injury occurring in other organs where divalent antibodies react with antigens expressed on the plasma membrane of cells adjacent to or surrounded by a basement membrane or a basement membrane-like structure (15). Shedding of immune complexes into a polysaccharide milieu should provide suitable conditions for in situ aggregation of immune complexes (16, 17).

Our observation that the plasma membrane (oolemma) of the mature oocytes, a cell surrounded by a thick basement membrane-like structure (zona pellucida), contains ACE afforded us the opportunity to examine the reaction of antibodies with this membrane antigen. The results obtained show that the interaction of divalent antibodies with ACE induces a rapid redistribution of ACE on the oolemma and shedding of ACE-antibody complexes into the perivitelline space with local formation of immune deposits. The morphologic and immunocytochemical aspects of in situ immune complex formation in the oocytes and the relevance of these events to the pathogenesis of Heymann glomerulonephritis are discussed.

### Methods

**Animals.** Female New Zealand white rabbits (Beckens Farms, Sanborn, NY), each weighing 2–2.5 kg, were used. They were allowed free

Address reprint requests to Dr. Andres, Department of Pathology SUNY/AB, 204 Farber Hall, Health Sciences Center, Buffalo, NY 14214.

Received for publication 31 July 1984 and in revised form 27 November 1984.

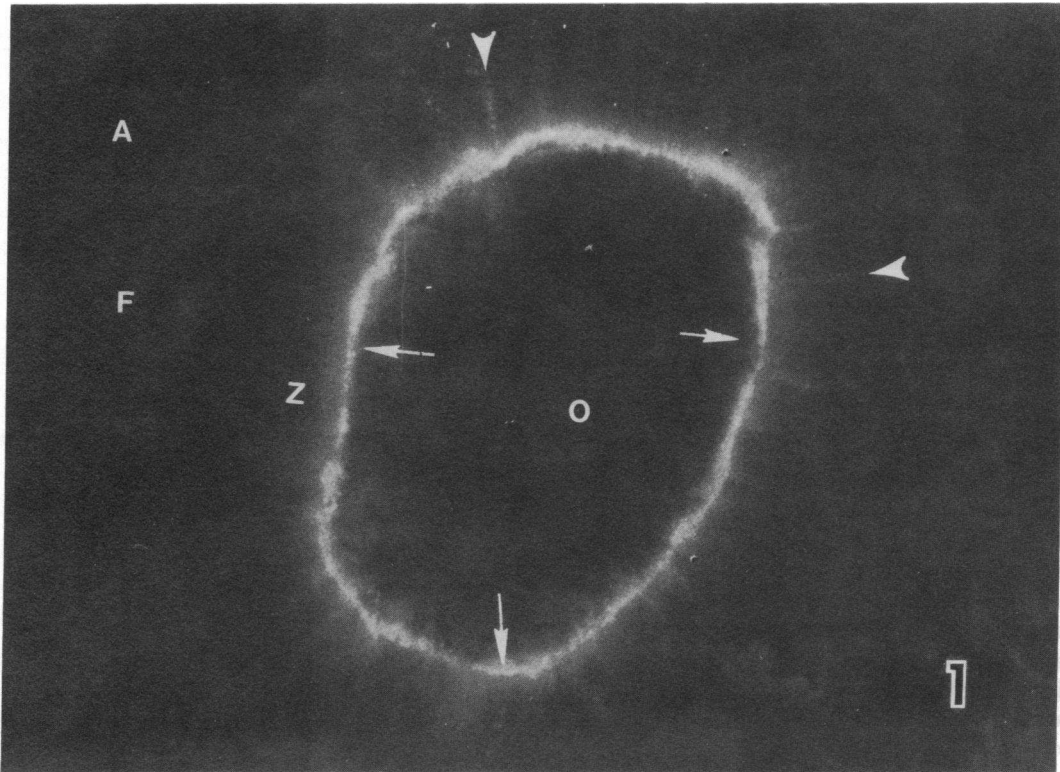
J. Clin. Invest.

© The American Society for Clinical Investigation, Inc.

0021-9738/85/04/1369/12 \$1.00

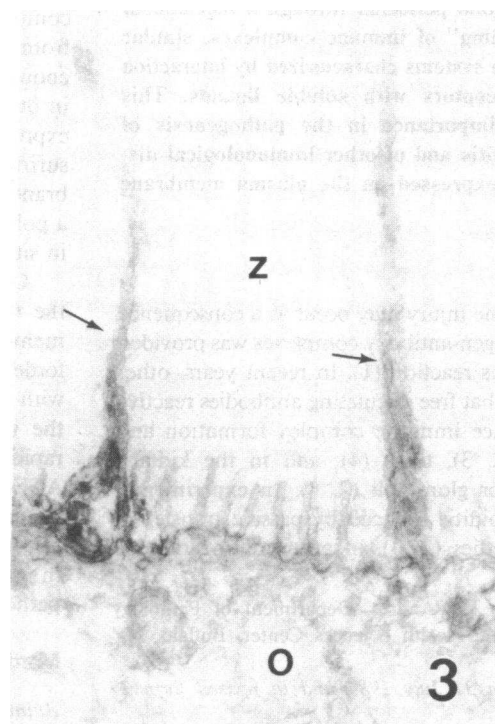
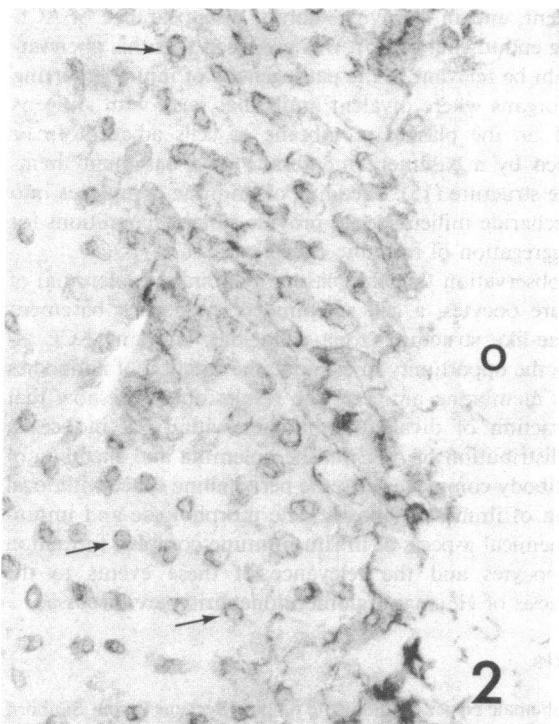
Volume 75, April 1985, 1369–1380

1. *Abbreviations used in this paper:* ACE, angiotensin-converting enzyme; FITC, fluorescein isothiocyanate; Gt, goat; HRP, horseradish peroxidase; IF, immunofluorescence; Rb, rabbit.



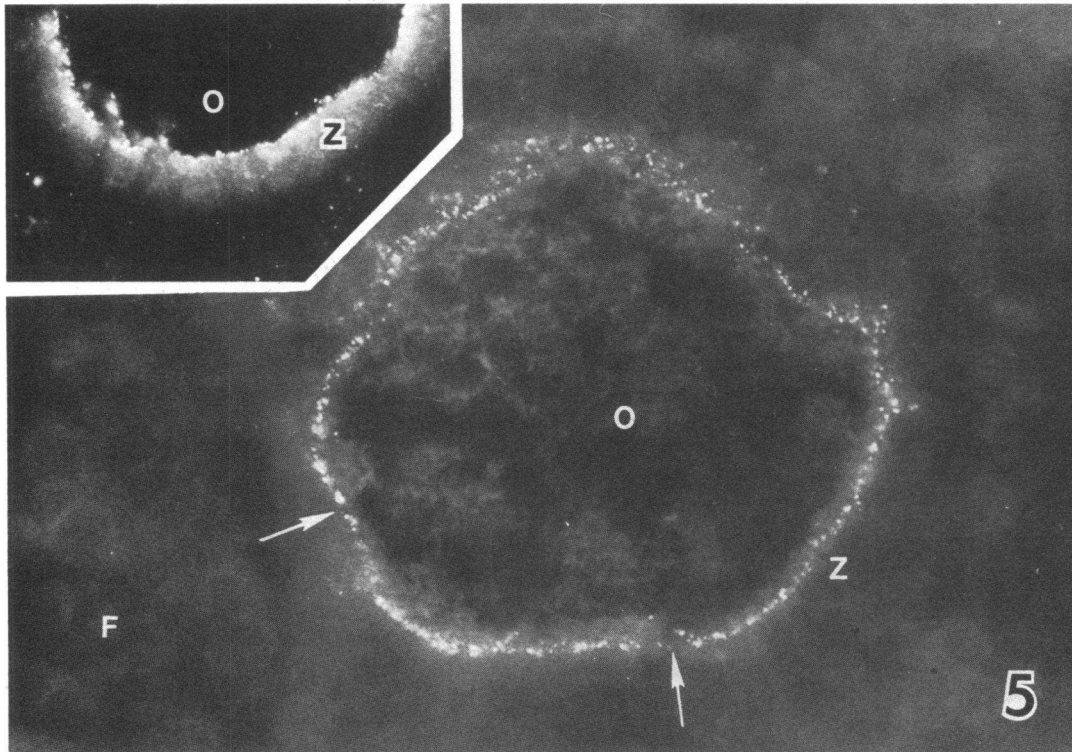
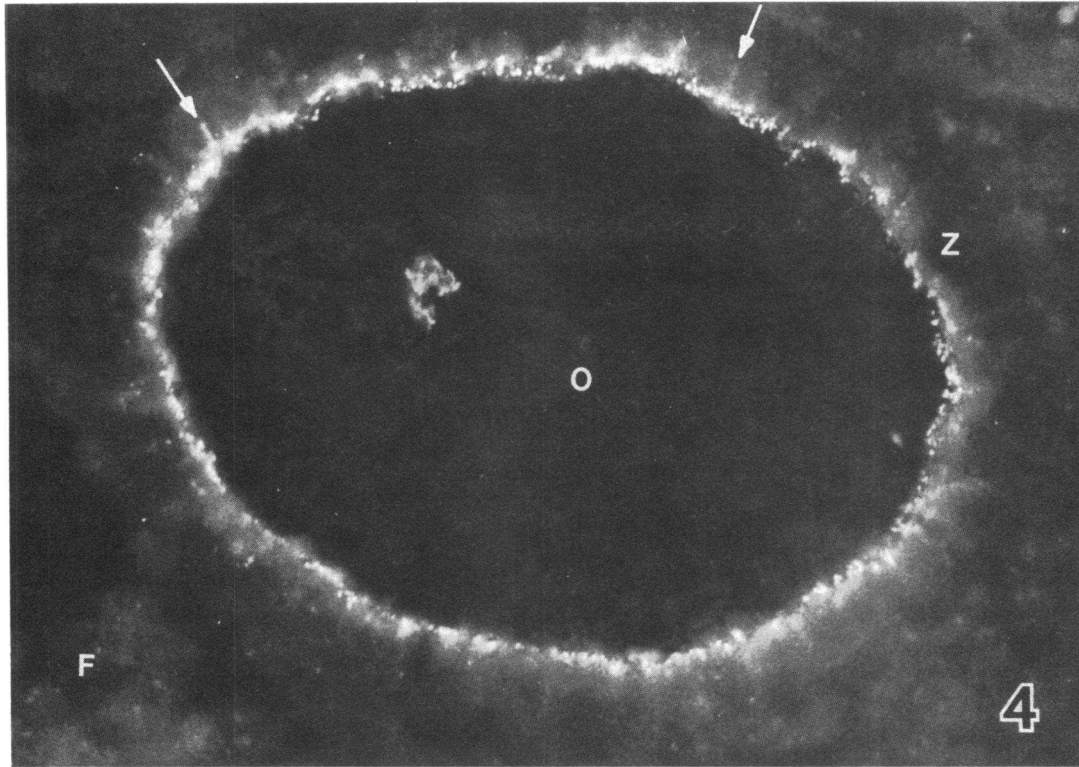
**Figure 1.** Antral follicle of a normal rabbit ovary. Section stained with FITC-conjugated Gt anti-RbACE  $\gamma$ -globulin. ACE is localized in the oolemma (arrows) and the radial processes of follicular cells

(arrow heads). O, oocyte; Z, zona pellucida; F, follicular cells; A, antrum.  $\times 800$ .



**Figures 2 and 3.** Electron micrographs showing the results of experiments performed by the immunoperoxidase technique for the localization of ACE in mature oocytes of a normal rabbit. Fig. 2 is an oblique section of the oolemma showing the reaction product local-

ized along the plasma membrane of the microvilli (arrows). Fig. 3 is a cross-section of part of an oocyte, showing the reaction product in the microvilli of the oocyte and in the long processes of follicular cells (arrows). O, oocyte; Z, zona pellucida.  $\times 35,000$ .



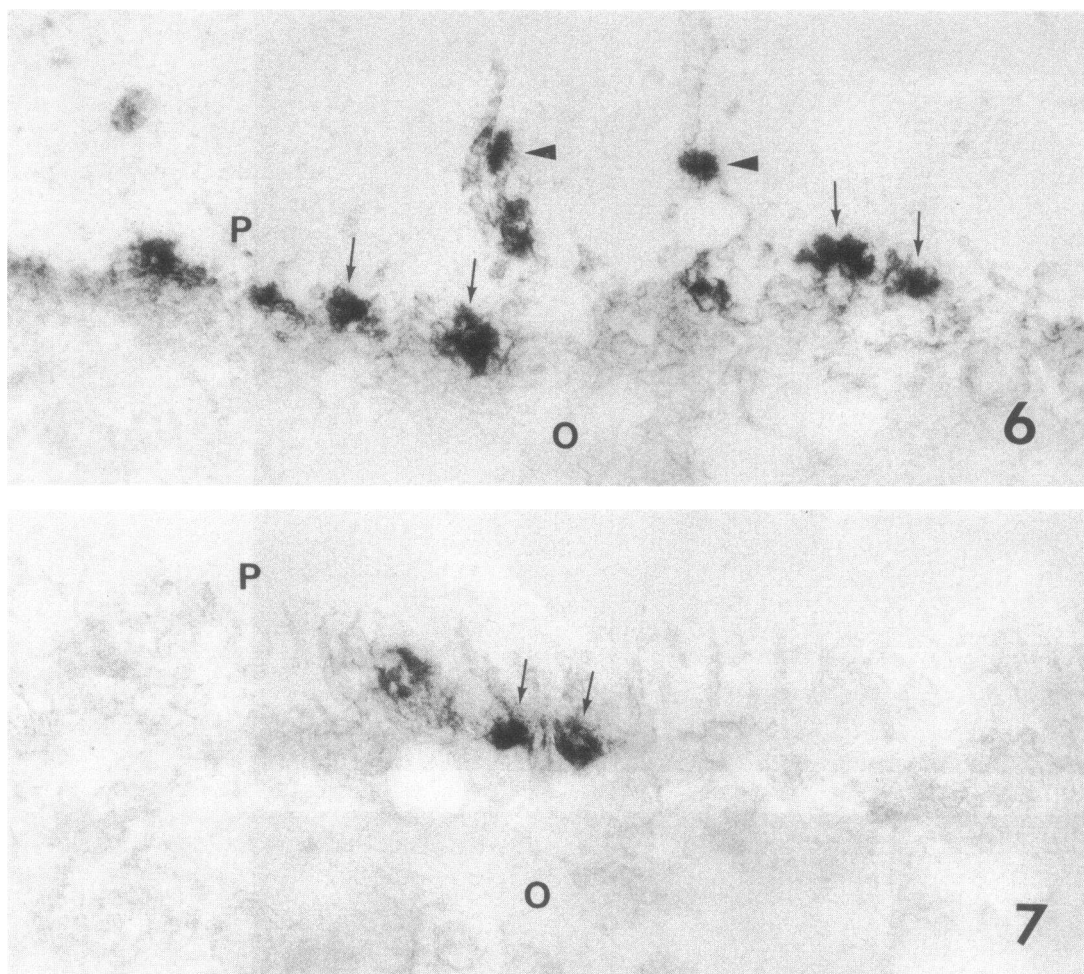
Figures 4 and 5. IF photographs showing granular deposits of Gt IgG (Fig. 4), ACE (Fig. 5), and Rb C3 (Fig. 5, inset) at the interface of the oolemma and the zona pellucida after 4 d of intravenous injection of Gt anti-RbACE  $\gamma$ -globulin. The arrows in Fig. 4 indicate

radial processes of follicular cells. Note that Rb C3 is distributed throughout the zona pellucida and that ACE is not detectable in the segments of oolemma between the deposits (arrows). O, oocyte; Z, zona pellucida; F, follicular cells.  $\times 800$ .

access to water and Purina rabbit pellets (Ralston Purina, Inc., St. Louis, MO).

*Goat anti-rabbit ACE (Gt anti-RbACE) antibody preparations.* Rabbit pulmonary ACE was purified as previously described (18, 19).

Antibodies to RbACE were raised in goats by immunization with the purified enzyme in Freund's adjuvant (19). In all experiments, the same pool of Gt anti-RbACE  $\gamma$ -globulin isolated by ammonium sulfate precipitation was used. Isolation of IgG from immune or normal Gt



Figures 6 and 7. Electron micrographs illustrating the results of studies performed by the immunoperoxidase technique of oocytes of a rabbit after 3 d of intravenous injections of Gt anti-RbACE  $\gamma$ -globulin. Fig. 6 shows granular deposits of Gt IgG and fusion of microvilli (arrows) at the interface of the oolemma and the perivitell-

line space (P). Some deposits are present along the processes of follicular cells (arrow heads). Fig. 7 shows segmental, granular deposits of ACE (arrows). ACE is not detectable in the microvilli adjacent to the deposits. O, oocyte.  $\times 40,000$ .

$\gamma$ -globulin was achieved by fractionation by DEAE-cellulose chromatography (19). The preparation of Fab fragments of IgG has been previously described (15, 19). Specificity of the antibodies was demonstrated by radioimmunoassay, by anticatalytic activity, and by the fact that the antibodies formed only a single precipitin arc when tested by immunoelectrophoretic analysis against solubilized rabbit lung extracts, which was identical to that against purified ACE (19).

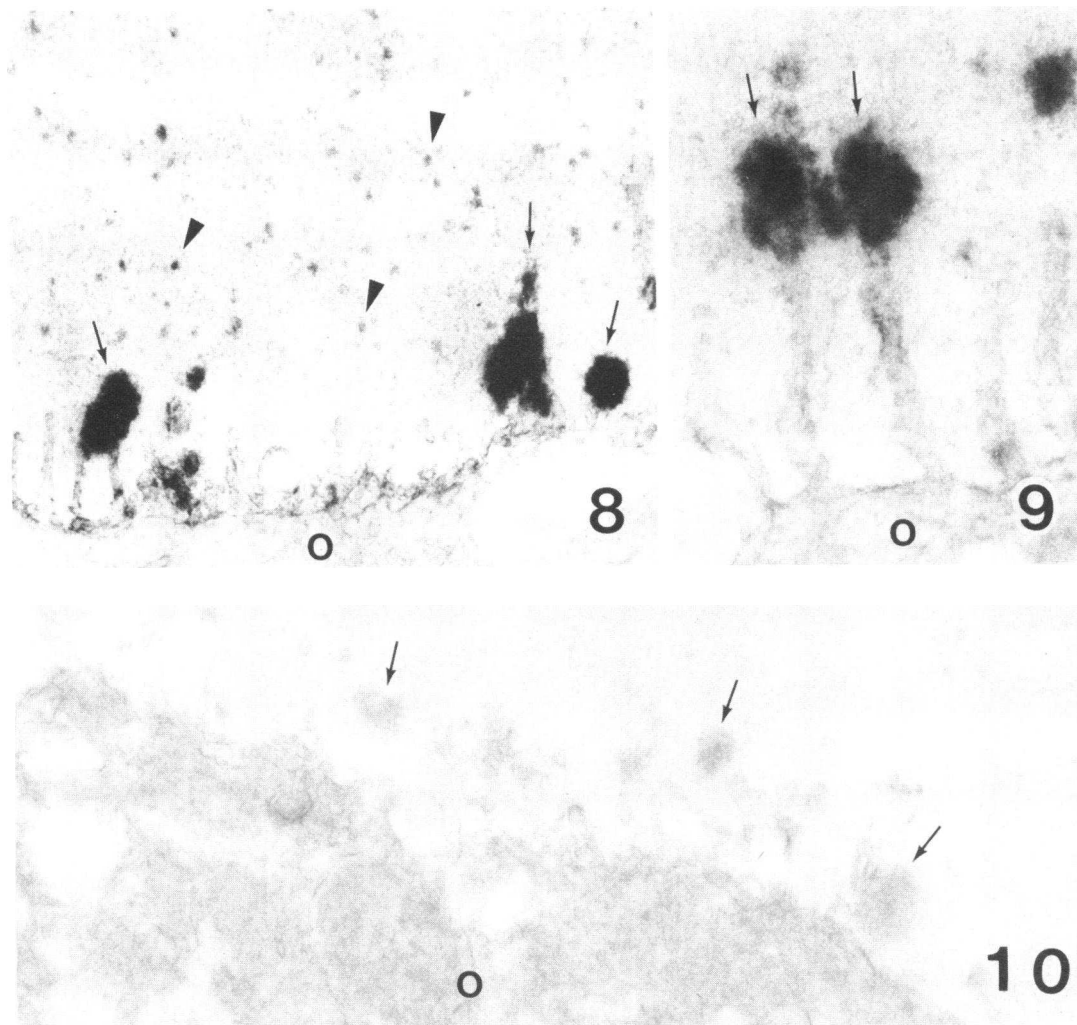
**Design of experiments.** In the first experiment, rabbits were injected for a maximum of 4 d with either Gt anti-RbACE  $\gamma$ -globulin or normal Gt  $\gamma$ -globulin. The doses were on day 1, 8 mg; on day 2, 23 mg; on day 3, 29 mg; and on day 4, 19 mg/kg body wt. The daily doses were administered over an 8-h period via an ear vein in a total volume of 12 ml. Ovary tissue of 4 rabbits injected with Gt anti-RbACE  $\gamma$ -globulin was studied on day 1, of 5 rabbits on day 3 or 4, of 1 rabbit on day 12, and of 6 rabbits on day 24. Ovary tissue of 2 rabbits injected with normal Gt  $\gamma$ -globulin was studied on day 1, of 3 rabbits on day 3 or 4, and of 4 rabbits on day 24. Ovaries were obtained by unilateral oophorectomy or at sacrifice.

For the second experiment, one rabbit received Fab fragments of Gt anti-RbACE IgG via an ear vein for 3 d while another rabbit received Fab fragments of normal Gt IgG for 3 d. The doses were on day 1, 5 mg; on day 2, 14 mg; and on day 3, 2 mg/kg body wt. A third rabbit was similarly treated with Gt anti-RbACE IgG, and a fourth with normal Gt IgG. The doses of IgG were on day 1, 8 mg;

on day 2, 23 mg; and on day 3, 3 mg/kg body wt. The total daily volume injected was 4 ml. All animals were sacrificed on day 3 and ovaries were obtained for immunopathologic studies.

In the third procedure, after cannulation of the ovarian artery under anesthesia, the right ovary of eight rabbits was perfused in situ for 5 min with 3 ml of Hanks' balanced salt solution (HBSS). This was followed by a perfusion for 15 min with 3 ml of HBSS containing 36 mg of Gt anti-RbACE  $\gamma$ -globulin in 3 rabbits, 36 mg of normal Gt  $\gamma$ -globulin in 3 rabbits, 18 mg of Fab fragments of Gt anti-RbACE IgG in 1 rabbit, and 18 mg of Fab fragments of normal Gt IgG in the eighth rabbit. After an additional 3-min perfusion with HBSS, the ovaries were removed and processed for immunopathologic studies.

**Immunofluorescence (IF) microscopy.** Direct IF tests on ovary tissue were performed according to methods described previously (20). Fluorescein isothiocyanate (FITC)-conjugated antisera to Gt IgG, Rb IgG, and Rb C3 were purchased from Cappel Laboratories (Cochranville, PA). They were found to be monospecific by immunoelectrophoresis as well as by immunodiffusion. Gt anti-RbACE  $\gamma$ -globulin was conjugated with FITC by a standard method (21). For the presence of ACE in ovaries of untreated rabbits, direct as well as indirect IF tests were used. The sections for IF microscopy were mounted in a medium containing *p*-phenylenediamine (22). They were examined with a Leitz Ortholux microscope (E. Leitz, Inc., Rockleigh, NJ) equipped with epifluorescence optics and appropriate filters.



Figures 8, 9, and 10. Electron micrographs illustrating the results of studies performed by the immunoperoxidase technique of oocytes of rabbits after 4 d of intravenous injections of Gt anti-RbACE  $\gamma$ -globulin. In Figs. 8 and 9, the deposits of Gt IgG (arrows) are at the level of the microvilli or at their tips. Note that Gt IgG is localized in round profiles (arrow heads) present in the perivitelline space. Fig. 10

illustrates the results of a control experiment. The ovary tissue was treated with normal rabbit serum instead of with Rb anti-Gt IgG antibodies. The electron dense deposits (arrows) present in the perivitelline space do not contain reaction product. O, oocyte. Fig. 8,  $\times 40,000$ ; Fig. 9,  $\times 50,000$ ; and Fig. 10,  $\times 40,000$ .

**Immunoelectron microscopy.** For the demonstration of Gt IgG and ACE in ovary tissue a modification of an earlier published protocol was used (23). Fragments of ovary tissue were fixed in a periodate-lysine-paraformaldehyde mixture (24) for 6 h at 4°C, followed by washing with several changes in phosphate-buffered saline (PBS) containing 4% sucrose for 60 h at 4°C. The last change of 1 h was in PBS containing 4% sucrose and 7% glycerol. The tissue was then embedded in OCT (Lab-Tek Products, Miles Laboratories, Naperville, IL) and frozen in liquid nitrogen. 8  $\mu$ m thick sections obtained with a cryostat were mounted on egg albumin-coated slides, dried at room temperature, and treated with PBS containing 0.05% sodium borohydride for 40 min at 4°C.

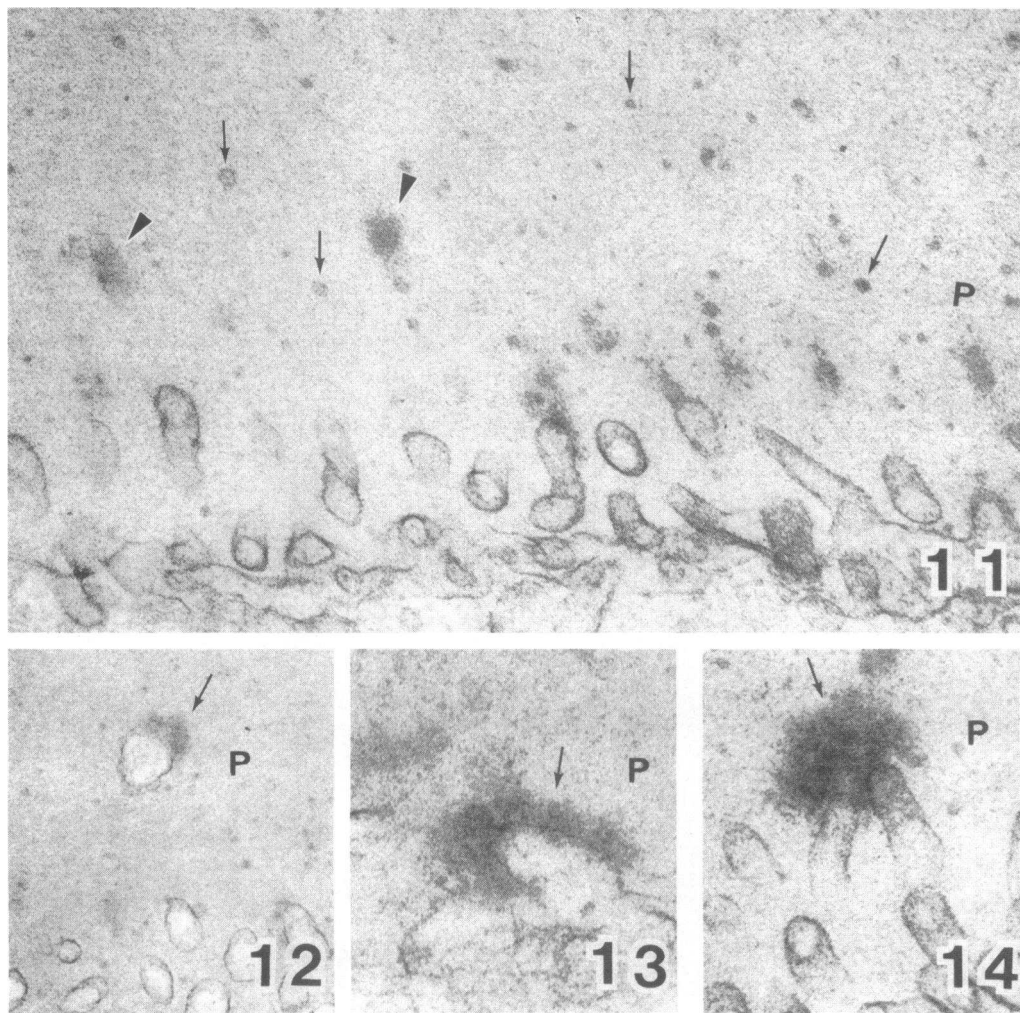
For detection of Gt IgG, the sections were first incubated for 30 min with normal rabbit serum diluted 1:20 in PBS, then with affinity purified Rb anti-Gt IgG antibodies (Cappel Laboratories) at a dilution of 1:4 for 1 h at room temperature, and then with horseradish peroxidase (HRP)-Gt anti-HRP immune complexes (Cappel Laboratories) at a dilution of 1:15 for 1 h at room temperature. For control, sections were incubated with normal rabbit serum diluted 1:40 instead of with Rb anti-Gt IgG antibodies.

For the demonstration of ACE, sections were first incubated with normal goat serum at a dilution of 1:20 for 30 min, then with HRP-conjugated (25) Gt anti-RbACE  $\gamma$ -globulin at a dilution of 1:10 for 2 h at room temperature. Control sections were treated with HRP-conjugated normal Gt  $\gamma$ -globulin.

After postfixation in 2.5% glutaraldehyde for 30 min at 4°C, all sections were incubated in 0.05 M Tris-HCl buffer, pH 7.6, containing 0.027% diaminobenzidine hydrochloride (Sigma Chemical Co., St. Louis, MO) for 10 min at room temperature. After addition of H<sub>2</sub>O<sub>2</sub> (final concentration, 0.005%), the sections were incubated for another 2.5–5 min (26). They were then treated with 1% osmium tetroxide, dehydrated, and "flat embedded" in Epon 812-Araldite (Polyscience, Inc., Warrington, PA). Thin sections were studied by electron microscopy without additional staining.

**Histological studies.** Fragments of ovary were fixed in 10% buffered formalin and embedded in paraffin. Sections cut at 3  $\mu$ m were stained with hematoxylin-eosin and periodic acid Schiff reagent. In addition, 1  $\mu$ m thick sections of Epon 812-Araldite embedded tissue stained with toluidine blue were also examined by light microscopy.

For routine electron microscopy, ovary tissue was fixed in a mixture



Figures 11, 12, 13, and 14. Electron micrographs showing oocytes of rabbits after 4 d of intravenous injection of Gt anti-RbACE  $\gamma$ -globulin. In Fig. 11, several round profiles (arrows) and areas of increased density (arrow heads) are present in the perivitelline space

(P). Figs. 12, 13, and 14 show electron dense deposits (arrows) contiguous to the plasma membrane of the microvilli. Note the morphological similarity of the deposits seen in Fig. 14 and those in Figs. 8 and 9. Figs. 11 and 12,  $\times 40,000$ ; Figs. 13 and 14,  $\times 55,000$ .

of paraformaldehyde and glutaraldehyde (27), postfixed in 1% osmium tetroxide, and embedded in Epon 812-Araldite. Thin sections stained with uranyl acetate and lead citrate were examined with a JEOL 100S electron microscope.

## Results

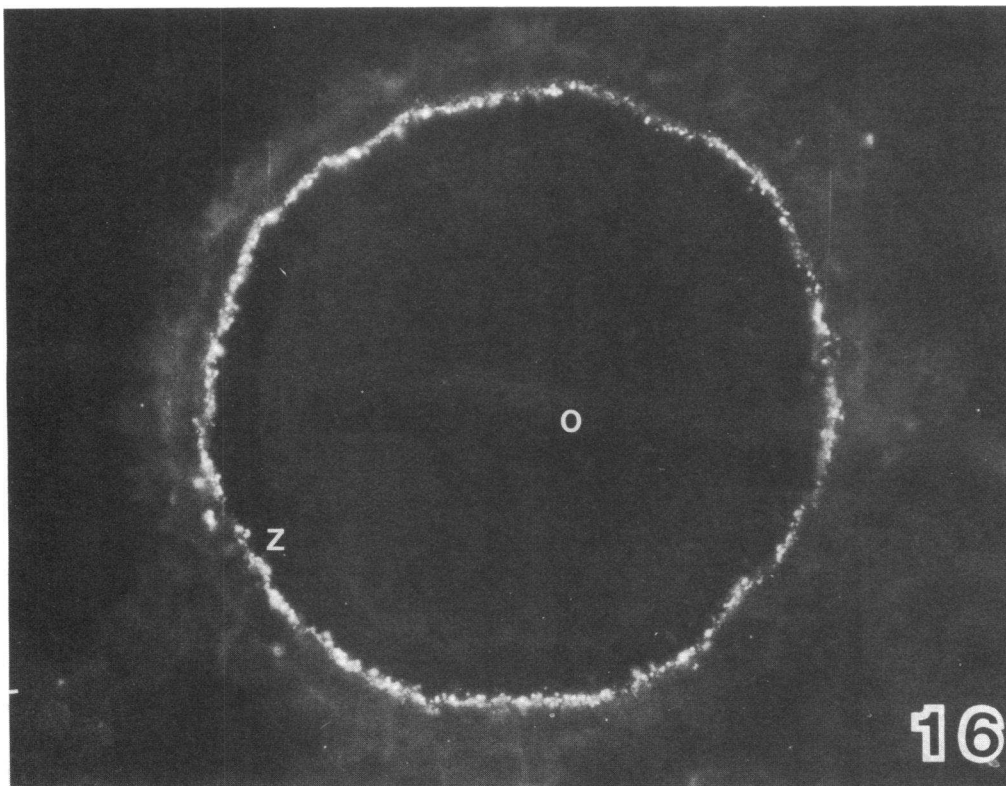
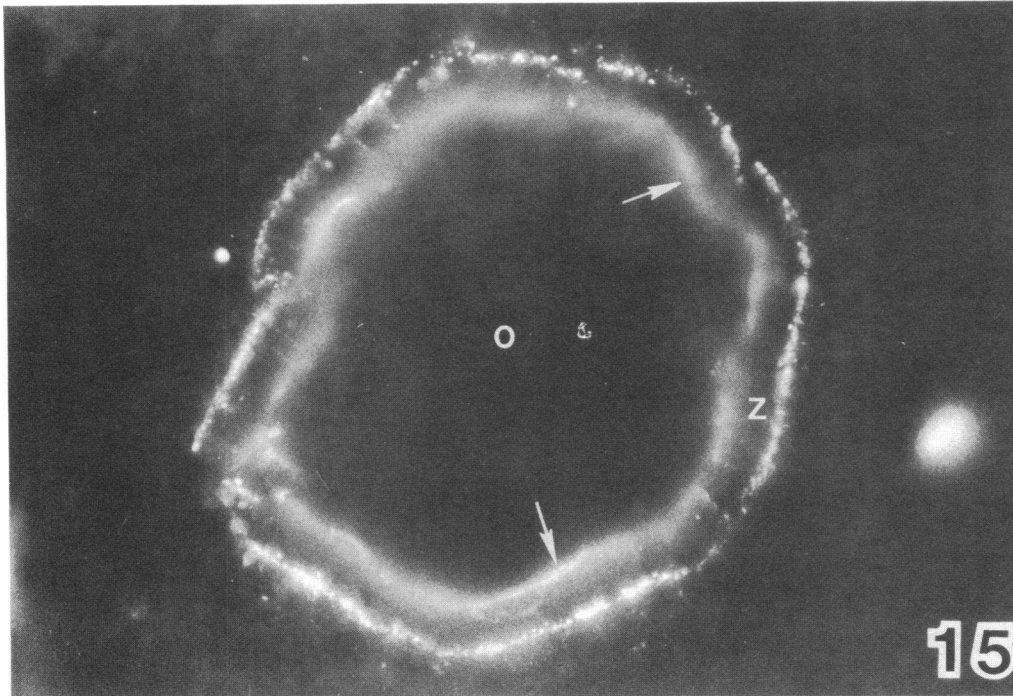
*In vitro reactivity of Gt anti-RbACE antibodies with rabbit ovary.* Direct as well as indirect IF microscopy tests for localization of ACE showed the presence of this enzyme in a diffuse pattern on the surface of oocytes. In addition, ACE was observed in the zona pellucida in radiating lines perpendicular to the oocyte (Fig. 1). ACE was most prominent in antral follicles. Immunoelectron microscopy revealed ACE in a linear pattern along the oolemma and the plasma membrane of the radial processes of the follicular cells (Figs. 2 and 3).

*Ovaries of rabbits injected for 1 d with Gt anti-RbACE  $\gamma$ -globulin.* In the ovaries of these rabbits no binding of Gt IgG was found. The distribution of ACE was similar to that observed in untreated rabbits. As in untreated rabbits, Rb IgG and C3 were detected diffusely in the zona pellucida. Morphologically, the follicles were unremarkable.

*Ovaries of rabbits injected for 3 or 4 d with Gt anti-RbACE  $\gamma$ -globulin.* Granular deposits containing ACE, Gt IgG, and Rb C3, but not Rb IgG, were found at the base and along the microvilli of the oocytes. The majority of the immune deposits were in contact with the oolemma. Segments of oolemma between the granular deposits were devoid of ACE (Figs. 4–10). Occasional immune deposits were also seen on the surface of the radial processes of the follicular cells (Fig. 6). By immunoelectron microscopy, Gt IgG, but not ACE, was also detected in small round profiles present mostly in the inner part of the zona pellucida (Figs. 8 and 9).

Whereas in light microscopy no structural abnormalities were seen, in transmission electron microscopy electron dense deposits corresponding to the immune deposits could be identified in most but not in all of the animals. The microvilli of the oocytes sometimes appeared interconnected and fused by these deposits. The round profiles described above were also noted (Figs. 11–14).

*Ovaries of rabbits studied 12 or 24 d after the beginning of the injections of Gt anti-RbACE  $\gamma$ -globulin for 4 d.* The immune deposits, initially observed at the interface of the oolemma



Figures 15 and 16. IF micrographs showing granular immune deposits in the oocytes of rabbits studied 24 d after the beginning of intravenous injections of Gt anti-RbACE  $\gamma$ -globulin. In Fig. 15, granular deposits of ACE are seen in the external part of the zona

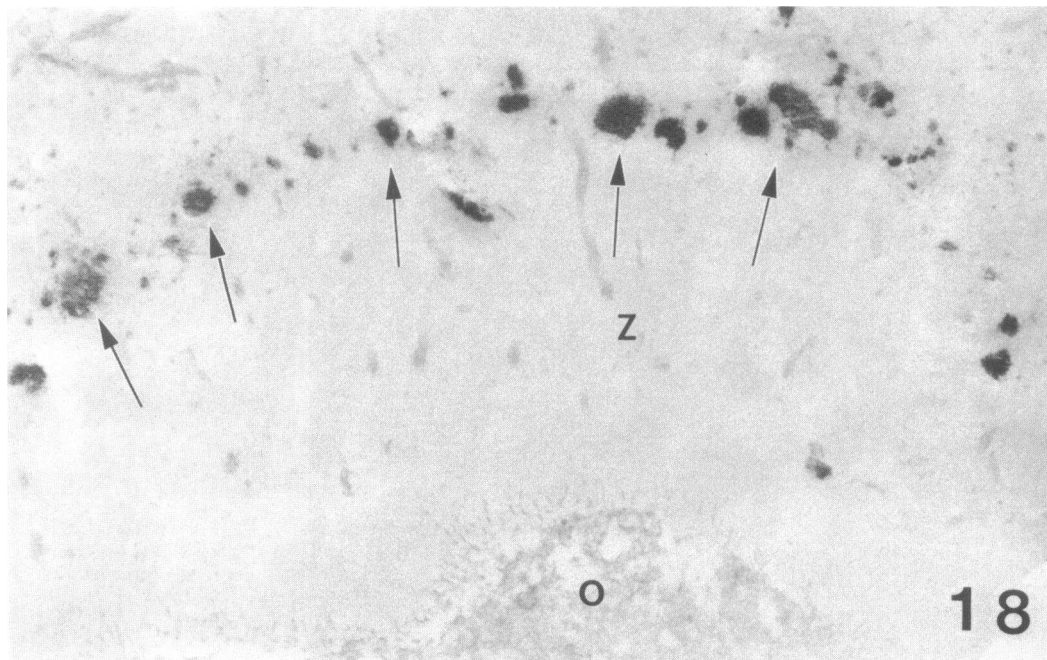
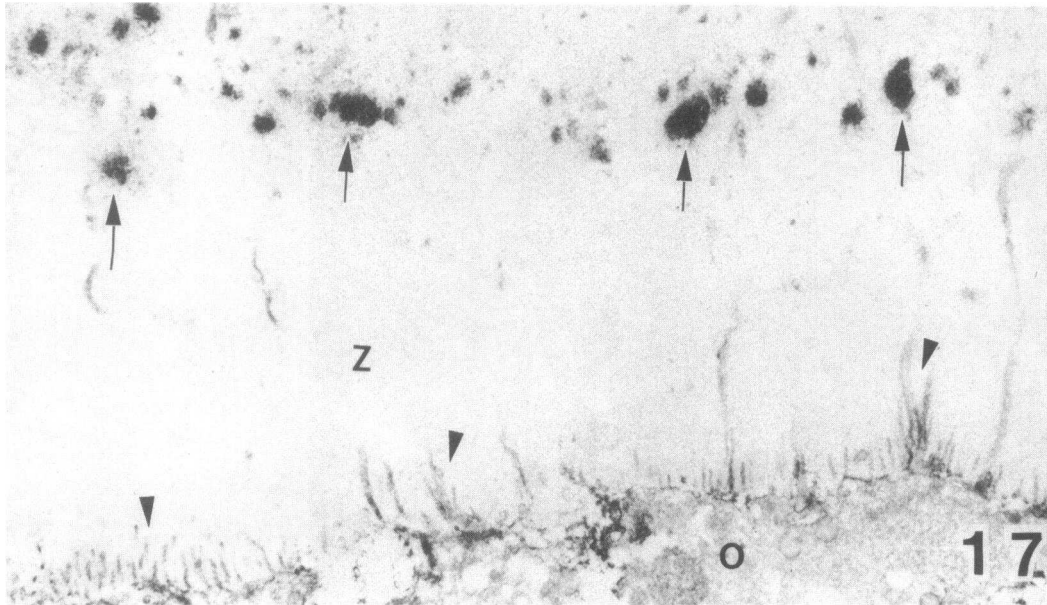
pellucida (Z). Diffuse deposits of ACE are also present at the level of the oolemma (arrows). Fig. 16 shows granular deposits of Gt IgG in the external part of the zona pellucida (Z). O, oocyte.  $\times 800$ .

and the zona pellucida, progressively moved to the periphery of the zona pellucida (Figs. 15–19). The deposits had grown in size and contained in addition to ACE (Fig. 15), Gt IgG (Fig. 16), and Rb C3, also Rb IgG. ACE was expressed once again in a diffuse linear pattern along the plasma membrane

of the oocytes and the radial processes of the follicular cells (Figs. 15 and 17).

In transmission electron microscopy, electron dense deposits corresponded to the immune deposits (Figs. 19 and 20). Small round profiles were seen dispersed throughout the zona pelu-





Figures 17 and 18. Electron micrographs showing results of immunoperoxidase studies of rabbit oocytes 24 d after the beginning of intravenous injection of Gt anti-RbACE  $\gamma$ -globulin. Fig. 17 shows that ACE is contained in granular deposits (arrows) on the external

part of the zona pellucida (Z). ACE is also present in the microvilli of the oolemma and in the processes of the follicular cells (arrow heads). Fig. 18 shows granular deposits of Gt IgG (arrows) in the external part of the zona pellucida (Z). O, oocyte.  $\times 40,000$ .

cida (Fig. 21). Occasionally they could be seen attached to the plasma membrane of the microvilli of the oocytes (Fig. 21, inset). Furthermore, similar profiles seemed to be present in some of the electron dense deposits (Fig. 20).

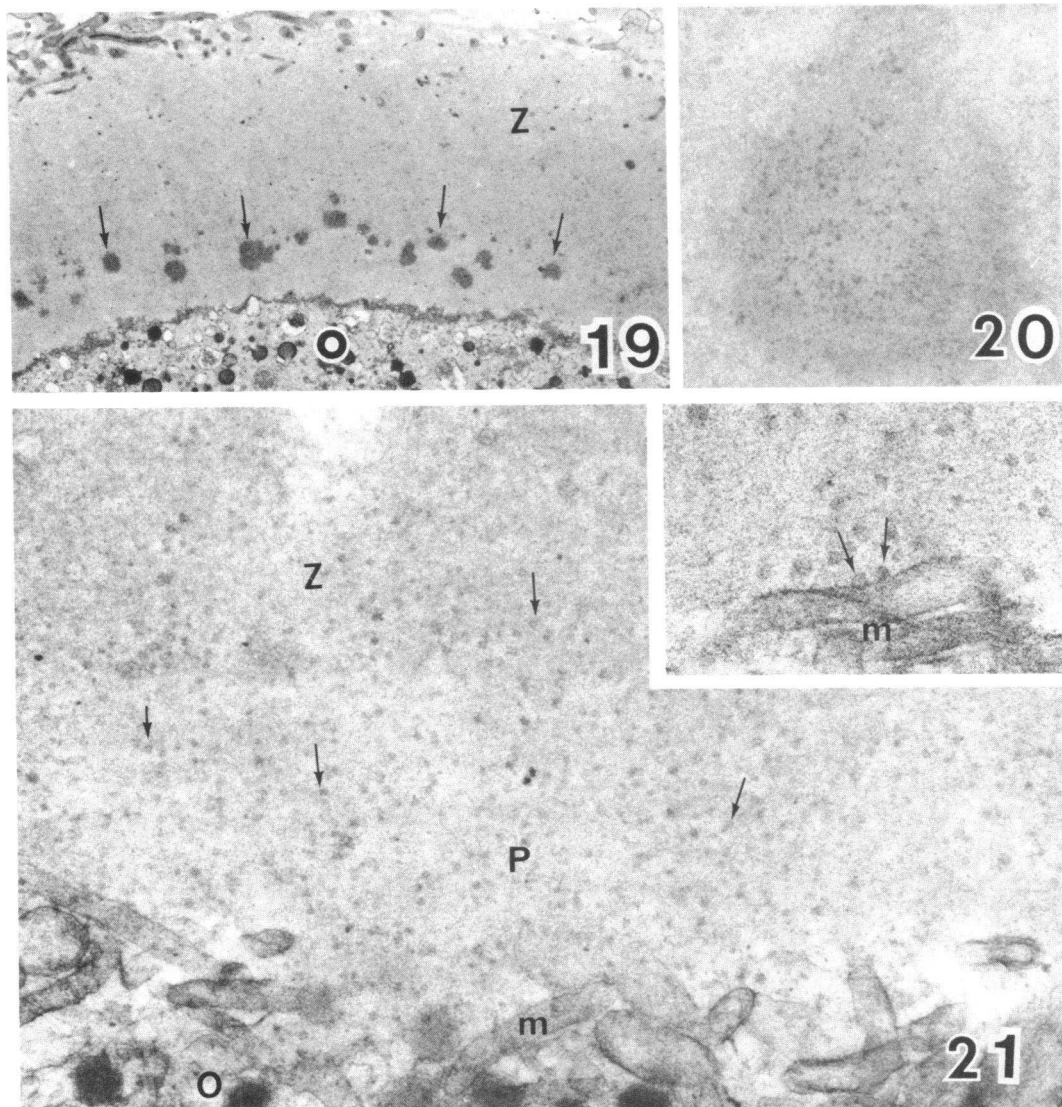
*Ovaries of rabbits injected for 3 or 4 d with normal goat  $\gamma$ -globulin.* The ovaries of rabbits studied up to 24 d after the beginning of normal Gt  $\gamma$ -globulin injections did not differ in any respect from those of untreated animals.

*Experiments involving Fab fragments of Gt anti-RbACE IgG.* Fab fragments of Gt anti-RbACE IgG injected for 3 d bound in a faint diffuse pattern to the oolemma. There was no detectable binding of Rb C3 and the distribution of ACE

did not change. In contrast, granular immune deposits of ACE, Gt IgG, and Rb C3 were observed along the oolemma when Gt anti-RbACE IgG was used. Injected Fab fragments of normal Gt IgG or intact normal Gt IgG did not localize in the ovary.

*Experiments of perfusion of isolated ovaries.* When ovaries were perfused in situ with Gt anti-RbACE  $\gamma$ -globulin, minimal granular deposits of ACE and goat IgG were seen by IF microscopy at the level of the oolemma. Similar deposits were not observed when the ovaries were perfused with the other three immune or nonimmune preparations.

The results of the studies performed in rabbits injected



Figures 19, 20, and 21. Electron micrographs of rabbit oocytes studied 12 or 24 d after the beginning of intravenous injections of Gt anti-RbACE  $\gamma$ -globulin. In Fig. 19, foreign electron dense deposits (arrows) are present in the inner part of the zona pellucida (Z) at day 12. Fig. 20 shows one of these foreign deposits containing compo-

nents of different electron density. Fig. 21 shows numerous round profiles (arrows) in the perivitelline space (P) at day 24. The inset shows two round profiles (arrows) attached to the plasma membrane of the microvilli. O, oocytes; m, microvilli of the oolemma. Fig. 19,  $\times 17,000$ ; Fig. 20,  $\times 35,000$ ; Fig. 21,  $\times 40,000$ ; inset,  $\times 55,000$ .

intravenously with Gt anti-RbACE antibodies are schematically illustrated in Fig. 22.

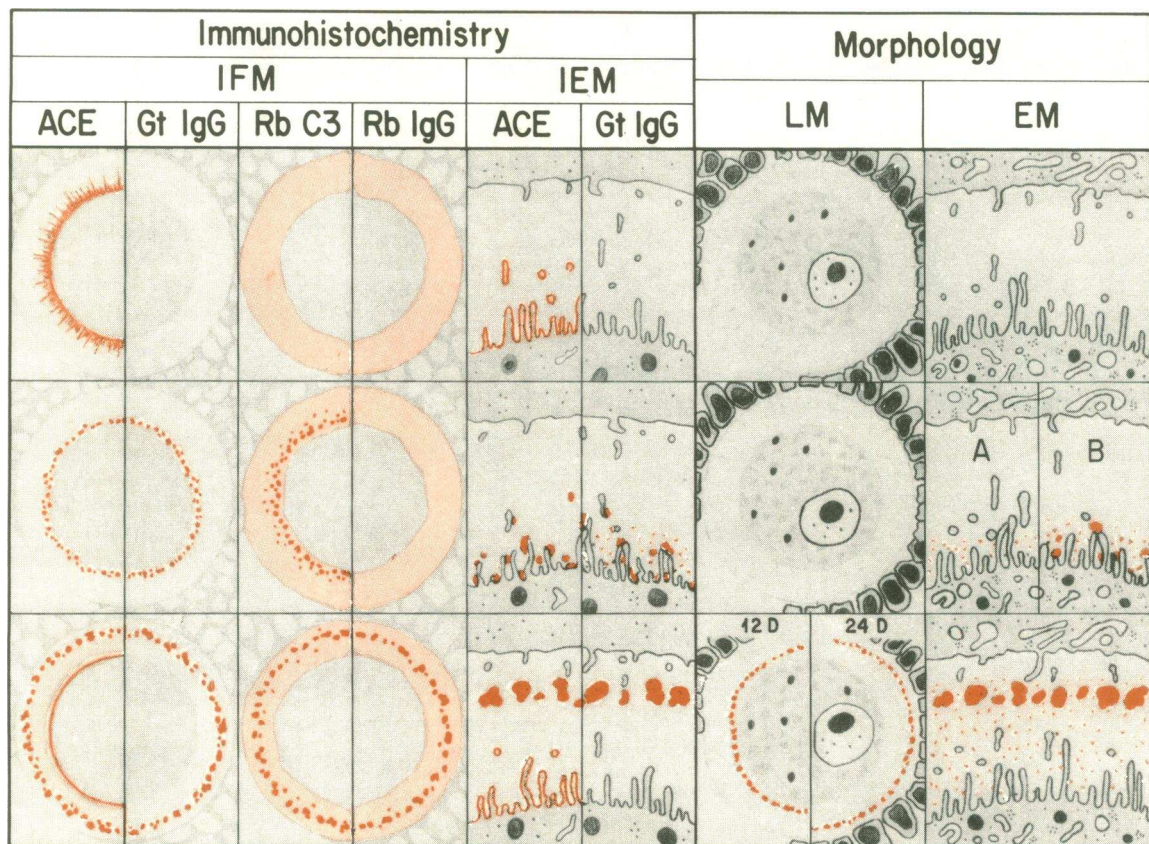
## Discussion

The aim of the present study was to explore the effect of *in vivo* interaction of antibody with an antigen expressed on the plasma membrane of cells adjacent to or surrounded by a basement membrane or a basement membrane-like structure and to evaluate the role of antigen redistribution in this structural milieu. This study is feasible in the oocyte because ACE is expressed on the oolemma in various stages of oocyte development but, especially, on the oolemma of mature antral follicles.

The interpretation that the interaction of divalent antibodies with ACE expressed on the oolemma induces immune complex formation and aggregation in the perivitelline space through patching and shedding of immune complexes is based on two

lines of evidence: First, in normal rabbits, ACE is distributed in the oolemma in a diffuse pattern. After binding of Gt anti-RbACE antibody to the oolemma, a redistribution of ACE occurs resulting in formation of granular aggregates of ACE separated by areas of oolemma devoid of this antigen. Because the granular deposits also contain Gt IgG and Rb C3, they are presumably formed by immune complexes. Second, under the same experimental conditions, the monovalent Fab fragments of Gt anti-RbACE IgG bind to the oolemma in a diffuse pattern without inducing antigen redistribution. These data indicate the ACE molecules, as transmembrane receptors, react with divalent ligands to undergo a structural change. This, in turn, may activate the oocyte's contractile elements resulting in patching and shedding of the immune complexes from the oolemma, as has been shown in the B lymphocyte (28, 29).

The polysaccharide milieu of the zona pellucida, a basement membrane-like structure, offers an ideal substrate for formation of immune aggregates because soluble immune complexes



22

Figure 22. This drawing schematically depicts the events following the interaction of Gt anti-RbACE antibodies with ACE present on the oolemma of the rabbit. The antibodies were injected via an ear vein for a maximum of 4 d. Ovaries were studied by IF microscopy (IFM), immunoelectron microscopy (IEM), light microscopy (LM), and electron microscopy (EM). The relevant observations are indicated in red.

On day 1, no antibodies reached the oolemma, presumably because most of the injected antibodies bound to ACE on the surface of lung endothelial cells. Thus, the findings on day 1 were similar to those seen in ovaries of untreated rabbits. ACE was present in a diffuse pattern along the oolemma and in the processes of the follicular cells. Gt IgG was not detectable. Small amounts of Rb C3 and Rb IgG were diffusely localized in the zona pellucida. The morphology of the oocyte and of the zona pellucida was normal.

preferentially precipitate within basement membrane-like structures as a consequence of "steric exclusion," which decreases their solubility in a manner directly proportional to the size of the immune complexes and to the concentration and total number of polysaccharides (16, 17). The absence of dense deposits detectable by transmission electron microscopy in the zona pellucida of some rabbits injected intravenously with Gt anti-RbACE  $\gamma$ -globulin, and the much smaller immune deposits seen exclusively by IF microscopy in isolated ovaries perfused with Gt anti-RbACE  $\gamma$ -globulin may be explained by lack of sufficient cross-linking in the initial stage of oophoritis (30), by the brevity of the perfusion experiments, and by the superior sensitivity of IF as compared with transmission electron microscopy (9).

In the present experiments, the immune complexes are initially formed at the level of the oolemma. By way of

contrast, the oophoritis induced by circulating immune complexes in rabbits with experimentally-induced chronic serum sickness (31) or in mice with spontaneous lupus-like syndrome (32) is characterized by appearance of immune deposits in the external part of the zona pellucida. These deposits, resulting from entrapment of immune complexes migrating from the capillaries of the theca interna toward the oocytes, are seldom seen in the perivitelline space and never near the oolemma.

The formation of immune deposits in the perivitelline space is associated with the appearance of numerous round profiles at the level of the oolemma. Round profiles are also seen in the perivitelline space and, occasionally, in the electron dense deposits. These abnormal structures are not observed in rabbits (31) or mice (32) with oophoritis induced by circulating immune complexes. Thus, they appear to be the consequence of the interaction of antibody with the oolemma. By immu-

noelectron microscopy, the round profiles appear to contain mainly Gt IgG. However, the round profiles might also contain components of the oolemma, including ACE covered by antibodies, and these components might contribute to the formation of the immune deposits. If this latter interpretation is confirmed, the appearance of the round profiles and their shedding into the perivitelline space might be the morphologic equivalent of the external stripping of plasma membrane antigens that occurs in vitro when cells are incubated with divalent ligands under capping conditions (28, 29).

The migration of immune deposits from the oolemma toward the outer part of the zona pellucida indicates that in situ formation of immune complexes is a dynamic process. The centrifugal migration of the immune deposits may be due to a passive transport resulting from the turnover of the zona pellucida. The relative role of the oocyte and granulosa cells in the formation of the zona pellucida has been debated for several decades (for review, see reference 33). However, recent studies by Zamboni and Upadhyay (34) on ectopic germ cells in the Anlage of the adrenal cortex have firmly established that at least some components of the zona pellucida are synthesized by the oocyte. This demonstration supports the hypothesis that immune complexes formed at the level of the oolemma move peripherally because of the turnover of the zona, a turnover that may be accelerated by the inflammatory process (35).

The discovery that ACE is localized on the oolemma of mature follicles poses a question concerning the role of ACE in this structure. Although ACE's main effect is in regulating blood pressure homeostasis, a regulatory effect on the osmotic pressure of other body fluids is probable (36). In this regard, it should be noted that during the last stage of maturation, the liquor folliculi is secreted at rapid rate and the intrafollicular pressure increases (37). ACE, which is found in larger amount in the oolemma of mature follicles, might contribute to the pressure changes (38) required for ovulation.

In situ immune complex formation is an established cause of tissue injury in several organs (39). In passive Heymann glomerulonephritis, a disease that mimics certain morphological aspects of human membranous glomerulonephritis, the immune deposits seen in the subepithelial part of the glomerular capillary wall are formed by autologous (9, 40) or heterologous (7, 8, 10) antibodies that react with an antigen mainly localized in the plasma membrane and in the coated pits of glomerular visceral epithelial cells (13). The morphological similarities between Heymann glomerulonephritis and the oophoritis induced by antibodies reactive with the oolemma lend credibility to the hypothesis that patching and shedding of immune complexes may have a role in the pathogenesis of Heymann glomerulonephritis, as well as in the pathogenesis of inflammatory lesions induced by interaction of antibodies with antigens expressed on the plasma membranes of cells adjacent to basement membrane in other organs.

### Acknowledgments

We thank Dr. Luciano Zamboni for his helpful criticism and advice, Ms. Lourdes T. Fernandez, Mrs. Mary Houlston, Mrs. Irene Pawlowski, and Mrs. Catherine Schwegler for technical support, Mr. Bruce Luders for printing the figures, Mr. Neal Niesen for expert microsurgery, and Mrs. Marilyn Fitzsimmons for typing the manuscript.

This study was supported by grant AI-10334 of the National Institute of Allergy and Infectious Diseases, National Institutes of

Health, and by grants from the American Heart Association, the Joe and Emily Lowe Foundation, and the Dana Foundation.

### References

1. Cochrane, C. G., and W. O. Weigle. 1958. The cutaneous reaction to soluble antigen-antibody complexes. A comparison with the Arthus phenomenon. *J. Exp. Med.* 108:591-604.
2. Kåresen, R., and T. Godal. 1969. Induction of thyroiditis in guinea pigs by intravenous injection of rabbit anti-guinea pig thyroglobulin serum. *Immunology.* 17:863-874.
3. Clagett, J. A., C. B. Wilson, and W. O. Weigle. 1974. Interstitial immune complex thyroiditis in mice. The role of autoantibody to thyroglobulin. *J. Exp. Med.* 140:1439-1456.
4. Bigazzi, P. L., L. L. Kosuda, K. C. Hsu, and G. A. Andres. 1976. Immune complex orchitis in vasectomized rabbits. *J. Exp. Med.* 143:382-404.
5. Klassen, J., and F. Milgrom. 1969. Autoimmune concomitants of renal allografts. *Transplant. Proc.* 1:605-608.
6. Klassen, J., F. Milgrom, and R. T. McCluskey. 1977. Studies of the antigens involved in an immunologic renal tubular lesion in rabbits. *Am. J. Pathol.* 88:135-144.
7. Van Damme, B. J. C., G. J. Fleuren, W. W. Bakker, R. L. Vernier, and P. J. Hoedemaeker. 1978. Experimental glomerulonephritis in the rat induced by antibodies directed against tubular antigen. IV. Fixed glomerular antigens in the pathogenesis of heterologous immune complex glomerulonephritis. *Lab. Invest.* 38:502-510.
8. Couser, W. G., D. R. Steinmuller, M. M. Stilmant, D. J. Salant, and L. M. Lowenstein. 1978. Experimental glomerulonephritis in the isolated perfused rat kidney. *J. Clin. Invest.* 62:1275-1287.
9. Sugisaki, T., J. Klassen, G. A. Andres, F. Milgrom, and R. T. McCluskey. 1973. Passive transfer of Heymann nephritis with serum. *Kidney Int.* 3:66-73.
10. Barabas, A. Z., and R. Lannigan. 1974. Induction of autologous immune complex glomerulonephritis in the rat by intravenous injection of heterologous anti-rat kidney tubular antibody. I. Production of chronic progressive immune complex glomerulonephritis. *Brit. J. Exp. Pathol.* 55:47-55.
11. Assmann, K. J. M., M. M. Tiggelder, W. P. J. Lange, T. M. Tadema, and R. A. P. Koene. 1983. Membranous glomerulonephritis in the mouse. *Kidney Int.* 24:303-312.
12. Hoyer, J. R. 1980. Tubulointerstitial immune complex nephritis in rats immunized with Tamm-Horsfall protein. *Kidney Int.* 17:284-292.
13. Kerjaschki, D., and M. G. Farquhar. 1983. Immunocytochemical localization of the Heymann nephritis antigen (gp 330) in glomerular epithelial cells of normal Lewis rats. *J. Exp. Med.* 157:667-686.
14. Hoyer, J. R., S. P. Sisson, and R. L. Vernier. 1979. Tamm-Horsfall glycoprotein: ultrastructural immunoperoxidase localization in rat kidney. *Lab. Invest.* 41:168-173.
15. Barba, L. M., P. R. B. Caldwell, G. H. Downie, G. Camussi, J. R. Brentjens, and G. Andres. 1983. Lung injury mediated by antibodies to endothelium. I. In the rabbit a repeated interaction of heterologous anti-angiotensin converting enzyme antibodies with alveolar endothelium results in resistance to immune injury through antigenic modulation. *J. Exp. Med.* 158:2141-2158.
16. Laurent, T. C. 1966. Solubility of proteins in the presence of polysaccharides. *Fed. Proc.* 25:1127-1133.
17. Hellsing, K. 1968. On the solubility of antigen-antibody complexes in the presence of dextran and some glycosaminoglycans from connective tissue. *Acta Univ. Ups. Abstr. Uppsala Diss. Sci.* 58:7-16.
18. Soffer, R. L., R. Reza, and P. R. B. Caldwell. 1974. Angiotensin converting enzyme from rabbit pulmonary particles. *Proc. Natl. Acad. Sci. USA.* 71:1720-1724.
19. Caldwell, P. R. B., J. H. Wigger, L. T. Fernandez, R. M. D'Alisa, D. Tse-Eng, V. P. Butler, Jr., and I. Gigli. 1981. Lung injury induced by antibody fragments to angiotensin converting enzyme. *Am. J. Pathol.* 105:54-63.

20. Andres, G. A., L. Accinni, S. M. Beiser, C. L. Christian, G. A. Cinotti, B. F. Erlanger, K. C. Hsu, and B. C. Seegal. 1970. Localization of fluorescein-labeled antinucleoside antibodies in glomeruli of patients with active systemic lupus erythematosus nephritis. *J. Clin. Invest.* 49: 2106-2118.
21. Wood, B. T., S. H. Thompson, and G. Goldstein. 1965. Fluorescent antibody staining. III. Preparation of fluorescein-isothiocyanate-labeled antibodies. *J. Immunol.* 95:225-229.
22. Platt, J. L., and A. F. Michael. 1983. Retardation of fading and enhancement of intensity of immunofluorescence by *p*-phenylenediamine. *J. Histochem. Cytochem.* 31:840-842.
23. Mynderse, L. A., J. R. Hassell, H. K. Kleinman, G. R. Martin, and A. Martinez-Hernandez. 1983. Loss of heparan sulfate proteoglycan from glomerular basement membrane of nephrotic rats. *Lab. Invest.* 48:292-302.
24. McLean, I. W., and P. K. Nakane. 1974. Periodate-lysine-paraphormaldehyde fixative. A new fixative for immunoelectron microscopy. *J. Histochem. Cytochem.* 22:1077-1083.
25. Nakane, P. K., and A. Karwaoi. 1974. Peroxidase-labeled antibody: a new method of conjugation. *J. Histochem. Cytochem.* 22: 1084-1091.
26. Courtoy, P. J., D. Hunt Picton, and M. G. Farquhar. 1983. Resolution and limitations of the immunoperoxidase procedure in the localization of extracellular matrix antigens. *J. Histochem. Cytochem.* 31:945-951.
27. Karnovsky, M. J. 1965. Formaldehyde-glutaraldehyde fixative of high osmolality for use in electron microscopy. *J. Cell. Biol.* 27: 137A.
28. Braun, J., and E. R. Unanue. 1980. B lymphocyte biology studied with anti-IgG antibodies. *Immunol. Rev.* 52:3-28.
29. Schreiner, G. F., and E. R. Unanue. 1977. Capping and the lymphocyte: models for membrane reorganization. *J. Immunol.* 119: 1549-1551.
30. Mannik, M., L. Y. C. Agodoa, and K. A. David. 1983. Rearrangement of immune complexes in glomeruli leads to persistence and development of electron-dense deposits. *J. Exp. Med.* 157:1516-1528.
31. Albin, B., E. Ossi, C. Neuland, B. Noble, and G. Andres. 1979. Deposition of immune complexes in the ovarian follicle of rabbits with experimental chronic serum sickness. *Lab. Invest.* 41:446-454.
32. Accinni, L., B. Albin, G. Andres, and F. J. Dixon. 1980. Deposition of immune complexes in ovarian follicles of mice with lupus-like syndrome. *Am. J. Pathol.* 99:589-602.
33. Kan, Y. H. 1974. Development of the zona pellucida in the rat oocyte. *Am. J. Anat.* 139:535-566.
34. Zamboni, L., and S. Upadhyay. 1983. Germ cell differentiation in mouse adrenal glands. *J. Exp. Zool.* 228:173-193.
35. Pierce, B. G. 1970. Epithelial basement membrane: origin, development and role in disease. In *Chemistry and Molecular Biology of the Intercellular Matrix*, Vol. 1. E. A. Balazs, editor. Academic Press, New York. 471-506.
36. Soffer, R. L. 1981. Angiotensin converting enzyme. In *Biochemical Regulation of Blood Pressure*. Wiley-Interscience, New York. 123-164.
37. Blandau, R. J. 1955. Ovulation in the living albino rat. *Fert. Steril.* 6:391-404.
38. Mariscal, R. N. 1974. In *Coelenterate Biology*. L. Muscatine and H. M. Lenhoff, editors. Academic Press, New York. 129-132.
39. Couser, W. G., and D. J. Salant. 1980. In situ immune complex formation and glomerular injury. *Kidney Int.* 17:1-13.
40. Neale, J. T., W. G. Couser, D. J. Salant, L. M. Lowenstein, and C. B. Wilson. 1982. Specific uptake of Heymann's nephritic kidney eluate by rat kidney. *Lab. Invest.* 46:450-453.