

Delineation of four cell types comprising the giant cell tumor of bone. Expression of Ia and monocyte-macrophage lineage antigens.

G R Burmester, ... , G Steiner, H A Sissons

J Clin Invest. 1983;71(6):1633-1648. <https://doi.org/10.1172/JCI110919>.

Research Article

Giant cell tumors of bone dissociated by collagenase digestion were found to be composed of four different cell types defined by morphology, growth in culture, and pattern of staining with monoclonal antibodies. Giant cells comprised an average of 0.8% of the cells recovered, with the remainder consisting of small stromal cells. Of the giant cells, 20-57% expressed Ia antigens, while all lacked IgG Fc receptors and five differentiation antigens associated with mature members of the monocyte-macrophage lineage (M phi S-1, M phi P-9, M phi P-15, M phi S-39, and 63d3). One antigen, M phi U-50, found on early monocytoïd forms was expressed on Ia+ giant cells. 6-36% of the remaining stromal tumor cells formed a second subpopulation that assumed either a rounded or elongated shape in culture. These cells bore Ia antigens, IgG Fc receptors, and five antigens of the monocyte-macrophage lineage usually found on blood monocytes. However, these cells differed from monocytes or macrophages in that the antigen M phi R-17 generally found on tissue macrophages was absent, and the M phi U-50 antigen present on more primitive cells was well expressed. A very limited endocytic capacity was demonstrable. A third population of up to 24% of the tumor cells was defined by the presence of intense staining for Ia antigens but the absence of antigens of mature [...]

Find the latest version:

<https://jci.me/110919/pdf>



Delineation of Four Cell Types Comprising the Giant Cell Tumor of Bone

EXPRESSION OF Ia AND MONOCYTE-MACROPHAGE LINEAGE ANTIGENS

G. R. BURMESTER, R. J. WINCHESTER, A. DIMITRIU-BONA, M. KLEIN, G. STEINER, and H. A. SISSONS, *Erwin S. and Rose F. Wolfson Laboratory of Cellular Mechanisms of Disease and the Department of Laboratories, The Hospital for Joint Diseases Orthopaedic Institute, Mount Sinai School of Medicine, New York 10003*

ABSTRACT Giant cell tumors of bone dissociated by collagenase digestion were found to be composed of four different cell types defined by morphology, growth in culture, and pattern of staining with monoclonal antibodies. Giant cells comprised an average of 0.8% of the cells recovered, with the remainder consisting of small stromal cells. Of the giant cells, 20–57% expressed Ia antigens, while all lacked IgG Fc receptors and five differentiation antigens associated with mature members of the monocyte-macrophage lineage (M ϕ S-1, M ϕ P-9, M ϕ P-15, M ϕ S-39, and 63d3). One antigen, M ϕ U-50, found on early monocytoid forms was expressed on Ia+ giant cells. 6–36% of the remaining stromal tumor cells formed a second subpopulation that assumed either a rounded or elongated shape in culture. These cells bore Ia antigens, IgG Fc receptors, and five antigens of the monocyte-macrophage lineage usually found on blood monocytes. However, these cells differed from monocytes or macrophages in that the antigen M ϕ R-17 generally found on tissue macrophages was absent, and the M ϕ U-50 antigen present on more primitive cells was well expressed. A very limited endocytic capacity was demonstrable. A third population of up to 24% of the tumor cells was defined by the presence of intense staining for Ia antigens but the absence of antigens of mature monocytes. A proportion of these cells expressed M ϕ U-50 and a minority had IgG Fc receptors. The two Ia(+) populations of stromal cells were not identifiable after 2 wk of culture, nor did tumor cells

selected for the presence of Ia antigens proliferate in culture. A fourth population of cells lacked Ia and monocyte lineage antigens, but showed pronounced intracellular staining for acid phosphatase. These cells had a distinctive plump epitheloid to fibroblastoid morphology and were readily established in long-term culture where they gave rise to large multinuclear Ia(-) cells containing acid phosphatase. The possibility is discussed that the cell types of these tumors relate to various stages in the development of osteoclasts from precursors in the mononuclear phagocyte lineage.

INTRODUCTION

The unusual morphological features of the giant cell tumor of bone have made it the subject of numerous studies since its classic description by Jaffe et al. (1). The tumor is characterized by large multinucleated cells distributed amongst numerous distinctive stromal cells that are smaller and morphologically uniform. The giant cells contain relatively large amounts of acid phosphatase and other hydrolytic enzymes (2). Recently, smaller amounts of acid phosphatase have been identified in the stromal cells (3). The similarity of the giant cell to an osteoclast both in morphology and enzyme content has given rise to the conjecture that the cell is a neoplastic variant of an osteoclast, and the tumor is sometimes termed an "osteoclastoma" (2, 4, 5). However, other theories viewed the giant cell either as a reactive cell similar to the macrophage-related giant cell or to a normal osteoclast, or alternatively as derived from the stromal cell, while the stromal cell itself was considered to be the primary tumoral ele-

Received for publication 8 November 1982 and in revised form 23 February 1983.

ment (2, 3, 6). The general nature of the tumoral cells and their relationship to normal cells remains relatively obscure and information on the more specific types of cell markers in the giant cell tumor is lacking.

Recently, a number of monoclonal antibodies have been described that detect surface antigens exclusively or predominantly expressed on the mononuclear phagocyte lineage (7-9). The use of these reagents provides a specific means of identifying cells related to or derived from the mononuclear phagocyte lineage. The Ia or DR antigens that are encoded by genes in the major histocompatibility complex are primarily expressed on cells of bone marrow origin such as monocytes, B lymphocytes, and progenitors of the granulocyte and erythrocyte lineages. Ia antigens are uncommonly found on normal cells outside of the bone marrow lineage such as endothelial cells but are strongly expressed on certain tumor cells of nonhematopoietic origin (10).

The purpose of the present investigation was to initiate the analysis of the cell surface phenotype of both the stromal cells and the giant cells using antibodies to Ia/DR and monocyte differentiation antigens. Aspects of the biology of the tumor were investigated with emphasis on the nature of different stromal cell populations, their relationship to the giant cells, and possible analogies with normal cell lineages.

METHODS

Patient population. Five patients with giant cell tumors of bone were studied. The diagnosis was made according to criteria previously described (1, 11, 12). The tumor tissue was obtained during surgery and was in excess of that required for diagnosis. The tissue samples from patient 1, 2, 3, and 4 were obtained at primary surgery, and in patient 5 from a recurrent tumor.

Processing of tissue. The cell isolation procedure was modified from one described in greater detail elsewhere (13). Tumor tissue was dissected free, finely minced in medium RPMI 1640 and mixed with 20 vol of medium RPMI 1640 containing 1 mg/ml collagenase (Sigma Chemical Co., St. Louis, MO) and 0.15 mg/ml deoxyribonuclease (Sigma Chemical Co.). After constant stirring for 60 min at 37°C in a small spinner flask, the cell suspension was filtered through a nylon sieve with a pore size of 250 μ m (Tetko, Inc., Elmsford, NY). Subsequently, the cell suspension was purified by centrifugation upon a Ficoll-Hypaque density gradient. Cells were harvested from the interface, washed three times in phosphate-buffered saline (PBS) and stored in medium RPMI 1640 supplemented with 10% fetal calf serum until used.

Cell culture. Cell cultures were initiated on small round coverslips (Bellco Glass, Inc., Vineland, NJ) in 24-well culture plates (Linbro Chemical Co., Hamden, CT) in medium RPMI 1640 supplemented with 10% fetal calf serum at a cell concentration of 0.2×10^6 cells/ml. After reaching confluency, the cells were split 1:3. Cells were stained on coverslips at time intervals indicated below.

Histochemistry and cytochemistry. Specimens were fixed in 10% neutral-buffered formalin. The fixed tissues were either embedded in paraffin for routine sectioning or de-

hydrated in a series of increasing methanol concentrations for embedding in methyl methacrylate according to the method of TeVelde et al. (14). Sections (15) were cut at 5 μ m thickness and stained for acid phosphatase (16) or alkaline phosphatase (17). The presence of lysozyme or Factor VIII-related antigen was detected by an immunoperoxidase method (17).

The coverslips or cytocentrifuge preparations of sorted cells were fixed in Baker's formalin for 1 h, rinsed with distilled water, and placed in PBS. The acid phosphatase, alkaline phosphatase, and lysozyme stains were performed as described for the fixed sections with the exception that the incubation periods with substrate were carried out for 15, 30, and 60 min whereas in fixed sections 30 min was the standard incubation time used. Staining for Factor VIII-related antigen was performed using the technique referred to above. The specimens were examined and photographed in a Zeiss Photomicroscope III (Carl Zeiss, Inc., New York).

Determination of the relative cell size. The relative cell size of suspended cells was determined by using the forward light scatter analysis on a fluorescence-activated cell sorter (FACS IV, Becton, Dickinson & Co., Mountainview, CA) (18). Peripheral blood lymphocyte and monocyte preparations separated as previously described (13) served as reference standards to compare cell sizes.

Identification of cell surface antigens. The following monoclonal reagents were used at saturating concentrations for surface antigen identification in indirect immunofluorescence. The anti-Ia monoclonal antibody 22c6 was obtained from an immunization with peripheral blood B cells (19). The antibodies reacting with antigens on cells of monocyte-macrophage lineage were obtained by immunization with peripheral blood monocytes (reagents M ϕ P-9, M ϕ P-15, M ϕ S-39, and M ϕ R-17), pleural fluid macrophages (M ϕ S-1), and the primitive monocytoid cell line M ϕ U-50) as described in greater detail elsewhere (9, 20, 21). The antimonocyte monoclonal antibody 63d3 was kindly provided by Dr. J. D. Capra, University of Texas, Southwestern Medical School, Dallas, TX. (7). The specificities of the antibodies directed to the mononuclear phagocyte lineage are summarized in Table I. The monoclonal antibody T3 reacting with >95% of peripheral blood T cells (22) was purchased from the Ortho Pharmaceutical Co., Raritan, N.J. F(ab')₂ fragments of the rabbit anti-Ia serum 962 were conjugated with fluorescein isothiocyanate. This reagent was characterized previously (23). An F(ab')₂ preparation of the immunoglobulin fraction was conjugated with fluorescein isothiocyanate and absorbed with T lymphoblastoid cell lines. The anti-human surface immunoglobulin reagents consisted of a mixture of F(ab')₂ reagents separately specific for mu or delta determinants (23). IgG Fc receptors were detected by indirect immunofluorescence using 1-5 μ g of purified aggregated human IgG in the first stage per 100,000 cells and F(ab')₂ fragments of goat anti-human IgG Fc in the second stage (24).

Immunofluorescence. The above described monoclonal reagents were used in indirect immunofluorescence with an F(ab')₂ preparation of rabbit anti-whole IgG fraction of mouse ascites fluid that was conjugated with tetramethyl rhodamine isothiocyanate (19). Double staining was performed by adding the rabbit anti-mouse Ig reagent and the fluorescein-tagged hetero anti-Ia reagent at the same time (19). Slides were examined using incident illumination in a fluorescence microscope (E. Leitz, Wetzlar, West Germany). The evaluation of positively stained cells was performed by counting \sim 200 cells. The numbers of positive cells were expressed as percentages of the total cell preparation. Quantitative cytofluorometry was performed on the FACS IV

TABLE I
*Reactivity of Monoclonal Reagents Directed to Cells of the Mononuclear Phagocyte
 Lineage on Various Cell Populations*

Cell populations	MφP-9	MφS-1	MφS-39	63d3	MφP-15	MφR-17	MφU-50
Peripheral blood monocytes	84	83	87	84	70	33	0
Fluid macrophages*	78	80	85	83	79	86	0
Tissue macrophages†	90	95	94	92	91	89	0
Granulocytes	(25)‡	(20)	(36)	(32)	0	0	0
Peripheral blood lymphocytes	0	0	0	0	0	0	0
U937 monoblastoid cell line	0	0	0	0	0	0	100
HL 60 cell line	0	0	0	0	0	0	0

* Obtained from pleural or peritoneal exudates.

† Obtained from the synovial tissues from patients with osteoarthritis.

‡ Very dim staining, primarily detectable by fluorescence-activated cell sorter analysis.

^{||} 0 signifies indistinguishable from control.

(Becton, Dickinson & Co.) as previously described using antibodies conjugated with fluorescein isothiocyanate (13). The enumerations were performed under the following conditions: fluorescence gain 1×0.5 , photomultiplier tube 590 V and 300 mW laser output. Higher gains were used to ascertain if dimly stained populations were present.

Cultured cells were stained on coverslips modifying a method previously described (25). Coverslips were taken out of the 24-well culture plate, and cells were reacted with 75 μ l of culture supernatants containing monoclonal antibodies, in a moist chamber at room temperature for 30 min. Subsequently, the coverslips were washed four times in Hanks' balanced salt solution (HBSS) and an appropriate dilution of the developing rabbit anti-mouse antiserum conjugated with rhodamine was added. After 20 min the coverslips were washed three times in HBSS, and after a final wash in PBS containing 0.2% sodium azide, the coverslips were mounted upside down on slides in 100% glycerol. After staining, the number of positive cells was immediately evaluated as described above. If evaluation was delayed, a parallel sample was fixed with 1% formalin added to the last wash. In a series of experiments, cells from patient 4 were incubated with 1.1- μ m diam latex particles (Dow Chemical USA, S. Plainfield, NJ) as described (23) in fresh cell suspensions and after 18 and 36 h of tissue culture, stained as described above, and the percentages of phagocytic cells (>5 particles ingested) in positively and negatively stained cell populations were determined.

Fluorescence-activated cell sorting. In experiments designed to separate cells expressing Ia antigens or the monocyte antigen detected by reagent MφS-1, 5×10^6 cells were labeled with 40–50 μ g of monoclonal antibody supernate (22c6 or MφS-1, respectively) and developed with 40 μ l of the fluorescein-labeled rabbit anti-mouse IgG reagent (1.5 mg/ml). Cells from patient 4 were separated on the FACS IV using a 70- μ m nozzle orifice under sterile conditions into the antigen-positive or antigen-negative populations (13). Postsort viability was 95%. Verification of the sort by examination of aliquots of both samples revealed >98% purity of each sample. Cells were subsequently cultured and stained as described above.

RESULTS

Cells eluted from giant cell tumors display a heterogeneous morphology. Immediately after collage-

nase digestion, 0.7–0.9% of the cells were uniformly round, possessed from 3 to 90 nuclei and were filled with great numbers of small granules (Fig. 1 A). Some of these giant cells had thin translucent protrusions of the cell membrane. The remaining nongiant stromal cells were frequently round in form with either very large phase dense vacuoles (Fig. 2 A) or numerous small granules (Fig. 2 C), or alternatively had a characteristic elongated shape with numerous irregular protrusions (Fig. 3 A, C). In all samples the proportion of lymphocytes was <1% as judged by morphologic criteria and determined by a monoclonal antibody detecting all T lymphocytes (T3), as well as by staining for surface immunoglobulin.

The forward light scatter histograms illustrated in Fig. 4 of the cells eluted from the giant cell tumor of patient 2 show a broad distribution of relative cell size with decreasing numbers of cells in the higher channel numbers. 31% of cells show a relative size in the range of blood lymphocytes, 38% have a size within the range of blood monocytes, and an average of 31% of eluted cells exceeded the size of the largest monocytes. Generally, similar apparent size distributions were observed for each tumor preparation.

Culture morphology. Appearance of new large multinucleated cells. Sufficient material was available from the tumors obtained from patient 2 and 4 to initiate long-term cultures. After 72 h of culture, 99% of cells were firmly adherent to glass coverslips. 10% of cells had the morphology of round spreading macrophages (Fig. 5 A, C). 13% of cells had a spindle-like elongated appearance (not illustrated). The remaining cells grew as large, plump epitheloid cells with one or two processes that sometimes were very elongated similar to the cells illustrated in the right of Fig. 6 A. 1% of cells had the morphology of very large giant cells with at least 80 nuclei (Fig. 1 B). After

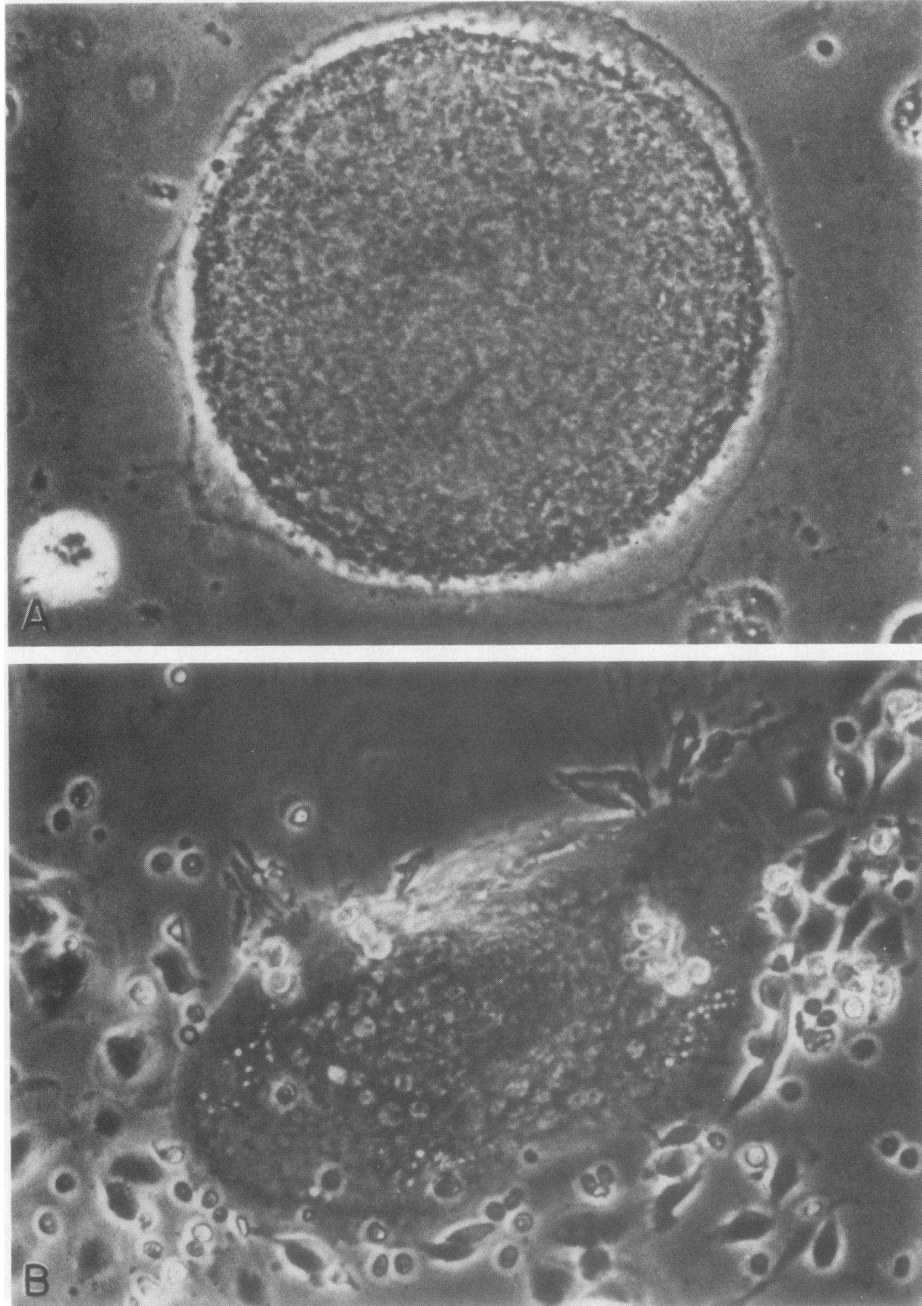


FIGURE 1 Giant cells in suspension and culture. (A) Phase-contrast micrograph of a freshly isolated giant cell demonstrating the translucent zone beneath the membrane and the presence of cytoplasmic granules ($\times 600$). (B) Adherent giant cell after 1 wk of culture without passage displaying numerous nuclei ($\times 250$).

72 h of culture the number of the spindlelike cells and the round spreading cells rapidly decreased.

After the first passage at 7 d using trypsinization the original giant cells were no longer detectable. After 21 d, the vast majority of the residual cells consisted

of plump epitheloid/fibroblastoid cells (Fig. 6 A). Upon confluency these cells closely attached to each other, and often it was impossible to discriminate between cell borders (6 B). After 3 wk of culture large multinucleated cells (0.5% of cells) with up to 12 or

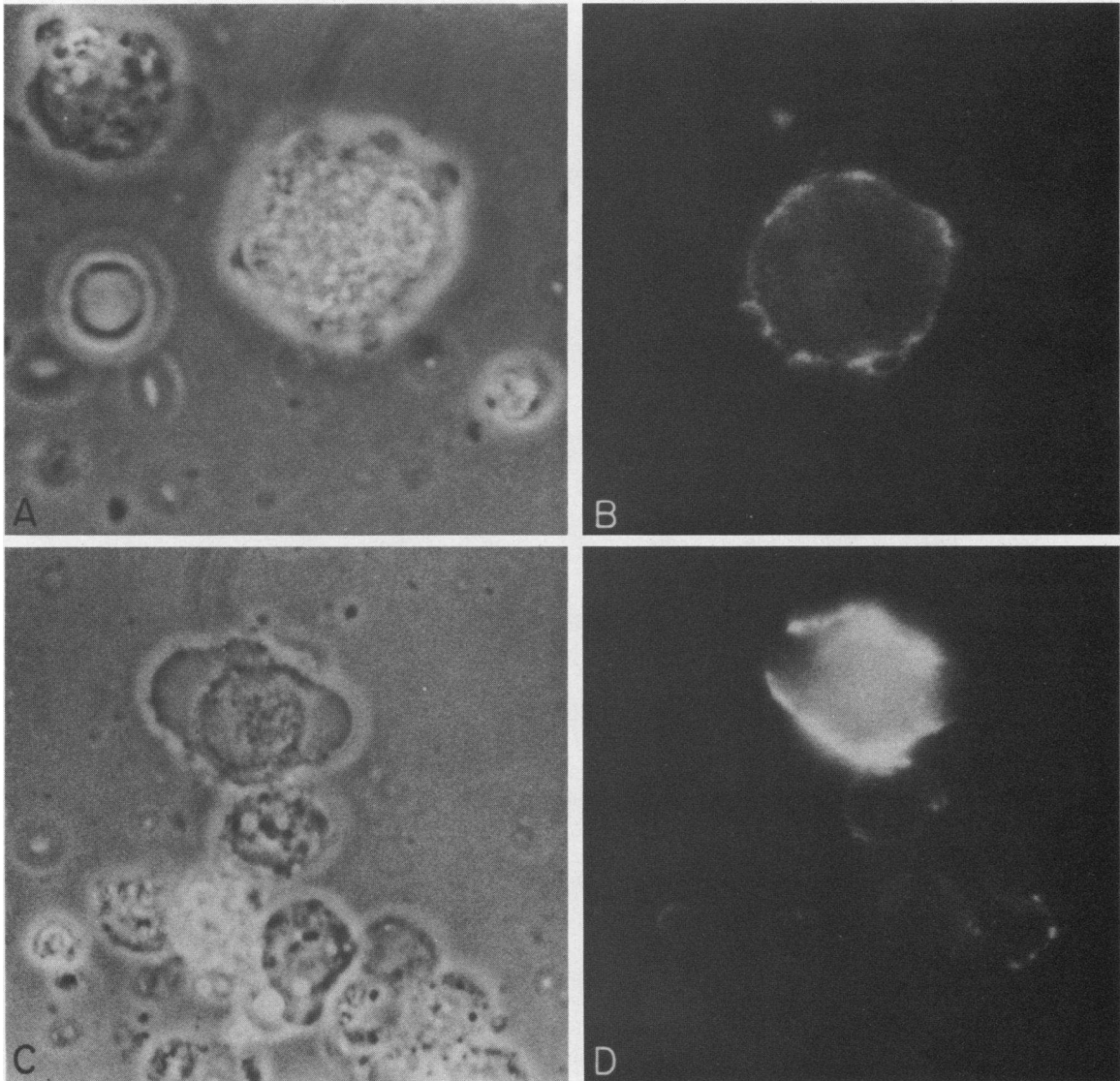


FIGURE 2 Two types of Ia positive stromal cells ($\times 2400$). (A) Phase-contrast micrograph of a stromal cell (center) filled with numerous large vacuoles. (B) Fluorescent micrograph demonstrating the expression of Ia antigens. Ia(+) cells with this morphology have monocyte-macrophage antigens detected by double-label experiments that are not illustrated. (C) Stromal cell with thin cell protrusions (upper part of picture). (D) Intense expression of Ia antigens. Cells with this morphology did not bear monocyte macrophage antigens determined by a double label experiment that is not illustrated.

more nuclei appeared. Characteristically, the nuclei of these cells were surrounded by a hem of abundant small granules, and the very thin cytoplasm extended several micrometers onto the surface of the coverslip (Fig. 6 C).

Histochemical and cytochemical characteristics of stromal cells and giant cells. In the tissue sections, all giant cells and an average of 68% of stromal cells

stained intensely for acid phosphatase. 6% of stromal cells showed staining for alkaline phosphatase, and 15% for lysozyme. After 21 d of culture >99% of mononuclear and multinucleated cells gave a positive reaction for acid phosphatase (Fig. 7). Staining for lysozyme and alkaline phosphatase was detectable in <1% of these cultured cells. Factor VIII-related antigen was demonstrated in <2% of newly dissociated

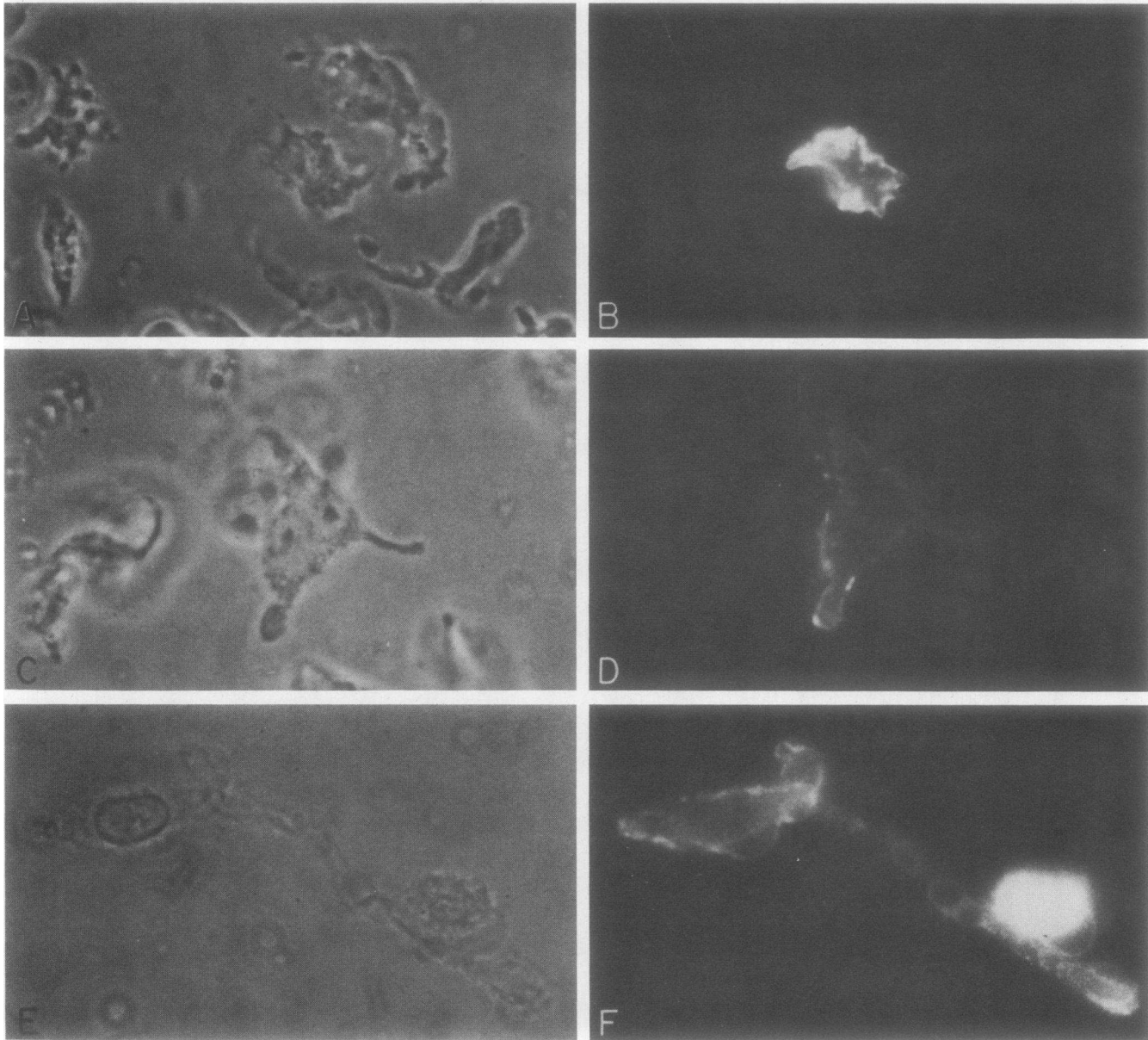


FIGURE 3 Stromal cells with irregular or spindle-like morphology ($\times 1,800$). (A) Suspension of stromal cells with bizarre irregular shape and prominent nucleoli. (B) Intense staining for Ia antigens on a stromal cell. (C) (D) Binucleate stromal cell in suspension with distinct prominent nucleoli that express Ia antigens. (E) (F) Adherent culture showing an Ia positive elongated stromal cell and a round spreading macrophage-like cell. All cells seen in Fig. 3 bearing Ia antigens did not express monocyte-macrophage antigens except for the round cell in Fig. 3 (E), (F) as revealed by double-label experiments.

cells. It was detected on $<1\%$ of cells cultured for >72 h. In tissue sections only the vascular endothelium of the tumor's vessels was positively stained.

Expression of Ia antigens but lack of monocyte-macrophage differentiation antigens on giant cells. Table II demonstrates that Ia antigens were present

on 20–57% of giant cells freshly eluted from the tumor tissue while Fc receptors and antigens characteristic of the mature members of the mononuclear phagocyte lineage were not detectable. The giant cells ingested only occasional latex particles. The Ia staining was dim to moderate in intensity. There were no morphological

TABLE II
Expression of Ia and Monocyte-Macrophage Antigens on Stromal Cells and Identification of Ia Antigens on Giant Cells

Patient	Stromal cells			Giant cells		
	Monoclonal anti-Ia reagent	Monoclonal antibodies with monocyte-macrophage specificity		Monoclonal anti-Ia reagent	Monoclonal antibodies with monocyte-macrophage specificity	
	22c6	MφS-1	MφP-9	22c6	MφS-1	MφP-9
1	49*	36	ND	25	0	ND
2	43	32	28	25	0	0
3	30	6	6	24	0	0
4	26	16	19	57	0	0
5	10	9	9	20	0	0

* Percent positive cells. ND, not done.

differences discernible between Ia(+) and Ia(-) giant cells. Double-label experiments performed on patients 2 and 4 revealed that MφU-50 reagent stained all of the giant cells that bore Ia antigens. In short-term cultures of up to 1 wk the giant cells maintained the expression of Ia antigens while the monocyte-macrophage antigens remained undetectable.

Definition of a subpopulation of stromal cells characterized by monocyte-macrophage differentiation

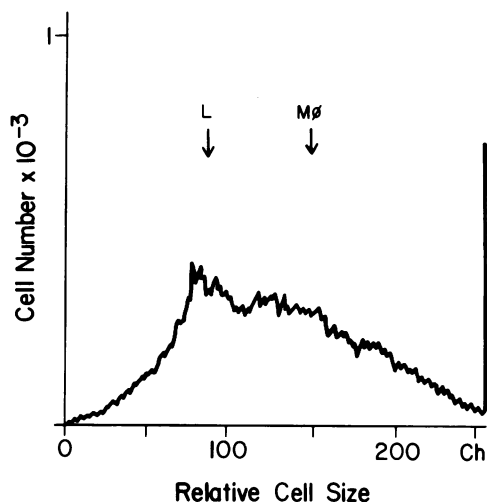


FIGURE 4 Distribution histogram of relative cell size determined by narrow angle forward light scatter analysis using a fluorescence-activated cell sorter. The cell preparation from patient 2 shows a broad distribution of cells of different sizes. The arrows denote corresponding average cell sizes for lymphocytes (L) or blood monocytes (Mo) demonstrating that 31% of cells gave a light scatter similar to blood lymphocytes, 38% had a size within the range of blood monocytes, while 31% of cells exceed the size of the largest monocytes.

antigens and Ia antigens. The reagents MφS-1 and MφP-9, which define antigens found on nearly all blood monocytes and tissue macrophages (9), intensely stained from 6–36% of the freshly isolated stromal cells. Similar results were obtained with the reagents MφS-39 and 63d3. 9–22% of stromal cells showed intense staining with the monoclonal antibody MφP-15. Fc receptors for IgG were detectable on 20% of freshly isolated or cultured cells. An antigen detected by monoclonal reagent MφR-17 that is characteristic of fibroblasts, fluid and tissue macrophages, and weakly expressed on a minority of blood monocytes (13) was detectable on <1% of the stromal cells.

Double-label experiments designed for the purpose of determining whether the cells expressing the monocyte-macrophage antigens also bore the Ia antigens revealed that an average of 98% of cells bearing monocyte antigens also expressed the Ia antigens (Fig. 8). Table III contains the results of double-label experiments using a combination of a fluorescein-labeled hetero anti-Ia reagent and the monoclonal antibody MφS-1 used with a rhodamine labeled second stage reagent. From 6–36%, mean 20%, of stromal cells bore both Ia and MφS-1 antigens. In double-label experiments an average of 65% of the cells bearing MφS-39 had the MφU-50 antigen and all of the MφS-39+ cells expressed Fc receptors.

Fig. 9 illustrates a representative profile of the binding of the antimonocyte reagent MφP-9 to cells eluted from the giant cell tumor of patient 2 utilizing flow cytometry. 28% of cells show positive staining, with the peak staining intensity of the positive cells in channel 58 and extending to all higher channel numbers. The distribution profiles of the other monocyte antigens were similar to that obtained with reagent MφP-9 and are not illustrated. In fresh cell suspension, <1% of MφP-9+ cells were strongly phagocytic after 18 h

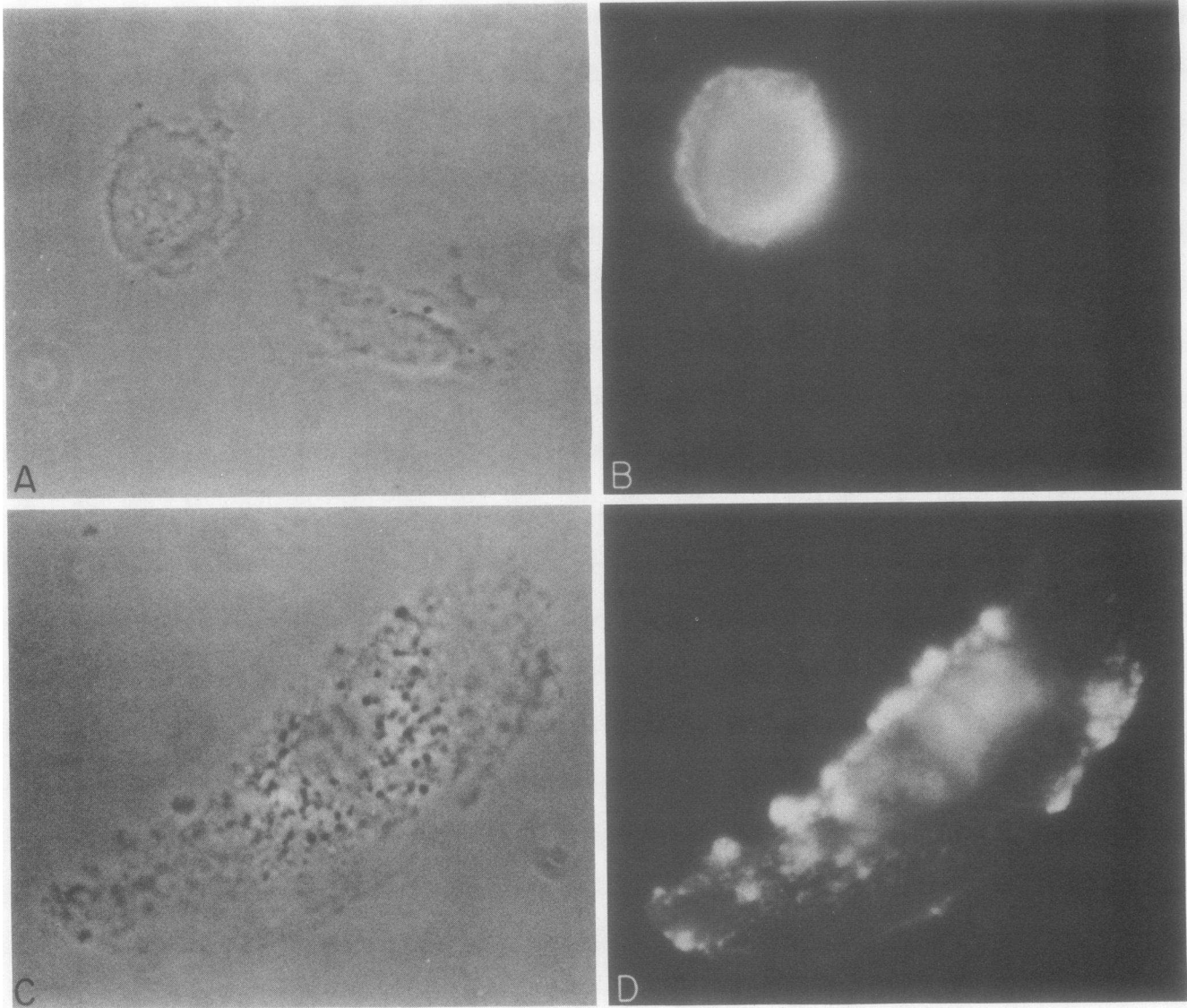


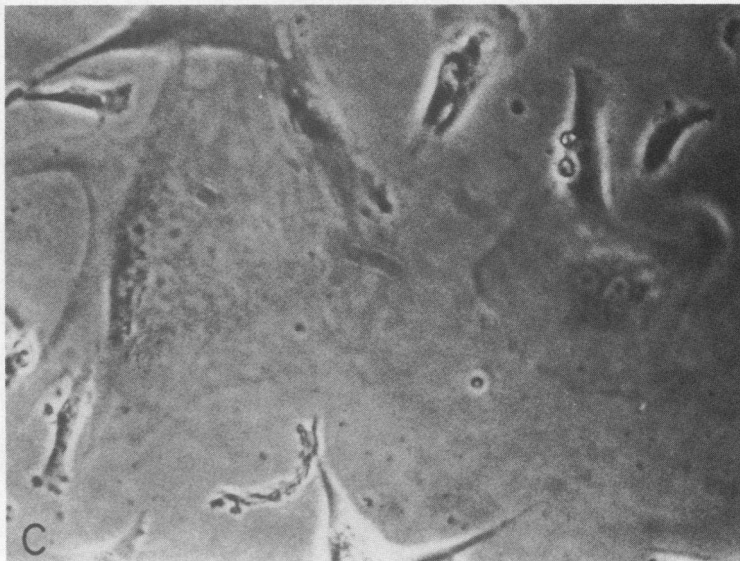
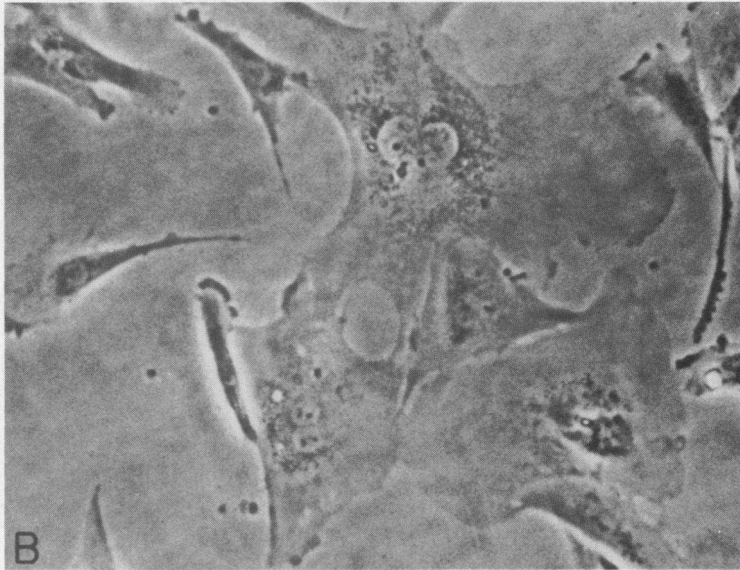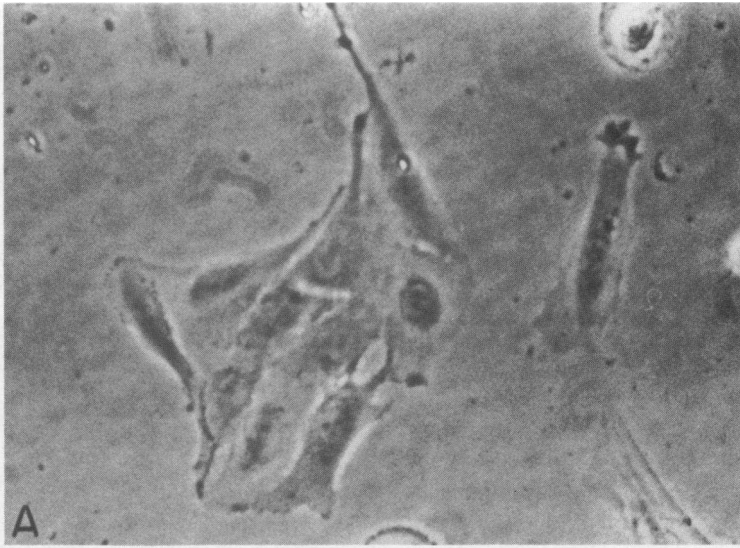
FIGURE 5 Round-spreading macrophagelike cells in culture stained on coverslips ($\times 2,400$). (A) Phase-contrast micrograph of a round monocyte-like cell (upper left part of picture). (B) Intense staining for the monocyte-antigen detected by reagent M ϕ S-1. (C) Larger more elongated cells filled with numerous phase dense granules. (D) Intense expression of the M ϕ S-1 antigen characteristically concentrated on cell protrusions.

of culture, 52% demonstrated moderate phagocytosis ($\sim 5-10$ particles/cell).

After 72 h of culture an average of 17% of cells bore monocyte-macrophage markers as determined by re-

agents M ϕ P-9 and M ϕ S-1. 70% of these cells had the typical spreading morphology of adherent monocytes (Fig. 5) while 30% had an elongated spindlelike appearance. The number of cells positive for monocyte-

FIGURE 6 Development of large multinucleated cells in culture ($\times 750$). (A) Close attachment of mononuclear stromal cells upon confluence in culture. Cell borders became indistinct suggesting a loss of contact inhibition and fusion of mononuclear stromal cells. (B) Two large binucleate stromal cells. The nuclei are characteristically surrounded by a hem of numerous granules. (C) Very large multinucleated cell (upper left) on day 21 of culture. Cells with this phenotype had extremely thin cytoplasm that extended several micrometers onto the coverslip.



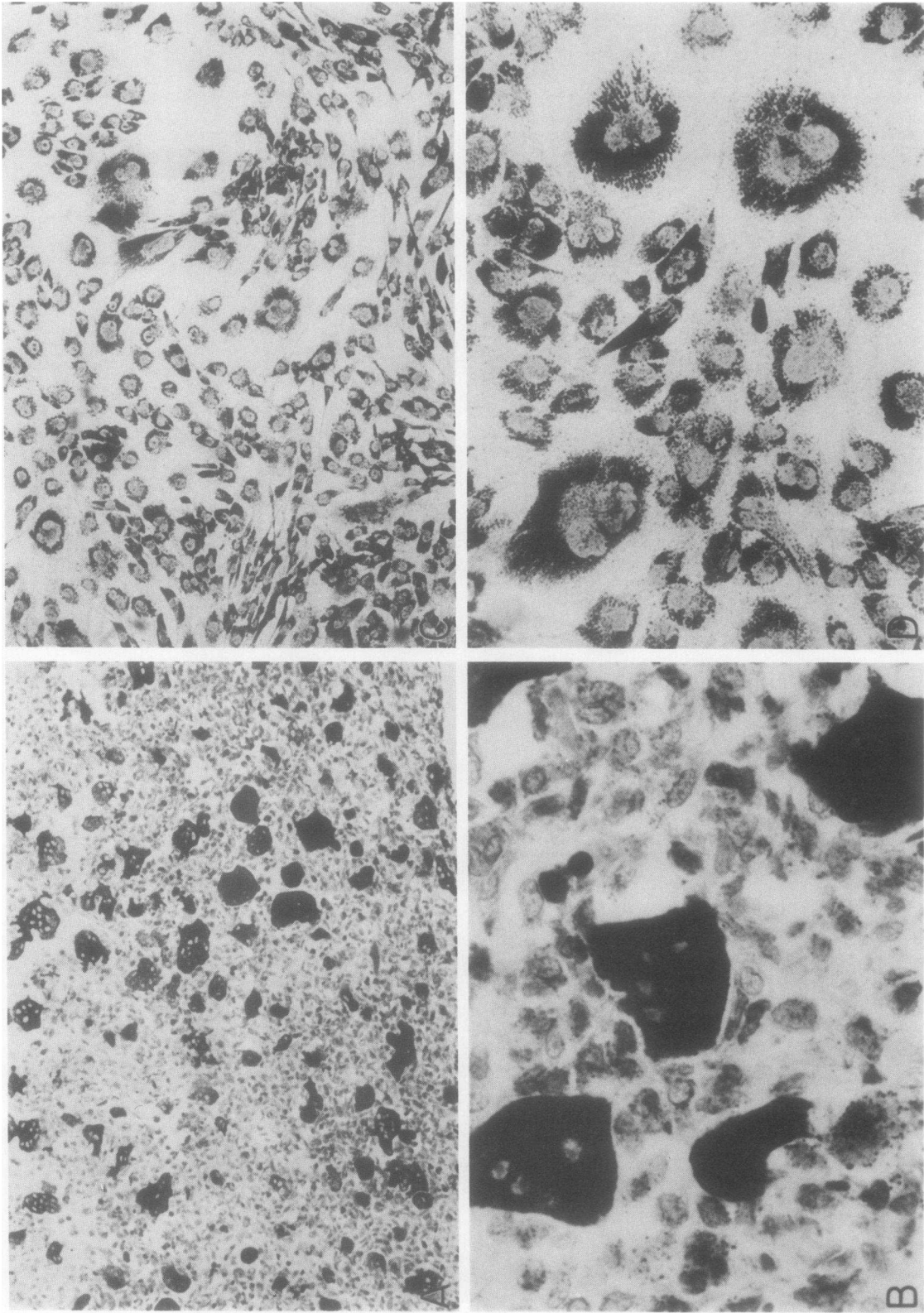


FIGURE 7 Comparison of the staining for acid phosphatase in fresh sections and tissue culture. (A) (B) Fresh section of a giant cell tumor showing intense staining for acid phosphatase in the stromal cells after 30 min of substrate incubation (A, X300; B, X1,200). (C) (D) Corresponding magnifications of cells cultured for 21 d demonstrating very intense staining after only 15 min of substrate incubation in both the mononuclear as well as the multinucleated cells.

TABLE III
Double-Label Experiments Reveal Three Populations of Stromal Cells and Two Populations of Giant Cells Based on the Expression of Ia and Nuclear Phagocyte Monocyte Lineage Antigens

Tumor	Stromal cells			Giant cells	
	Ia+Mo+*	Ia*Mo ⁻	Ia ⁻ Mo ⁻	Ia*(Mo ⁻)	Ia ⁻ (Mo ⁻)
1	36	13	51	25	75
2	32	11	57	25	75
3	6	24	70	24	76
4	16	10	74	57	43
5	9	1	91	20	80
Mean±SD	20±14	12±8	69±16	30±15	70±15

* Ia⁺ cells were identified by reagent 962 (fluorescein) and Mo + (rhodamine) cells by reagent Mo S-1.

macrophage antigens rapidly decreased in culture and they were virtually undetectable after 14 d.

To decide whether the monocyte antigen positive cells had lost the expression of these antigens with further growth in culture, or actually lacked the capacity to proliferate, the tumor cells obtained from patient 4 were separated into MφP-9 monocyte differentiation antigen positive and antigen negative subpopulations utilizing fluorescence-activated cell sorting. An F(ab')₂ fragment of the antibody directly labeled with fluorescein was used. Over a period of 21 d no proliferation of the cells bearing the MφP-9 antigen was observed. 57% of MφP-9+ cells freshly selected by the fluorescence-activated cell sorter demonstrated weak staining for acid phosphatase, while the population lacking the MφP-9 had 94% that stained more strongly for acid phosphatase.

In preliminary experiments the possibility was explored that the enzymatic isolation procedure caused an alteration in the cell membrane antigens examined. Portions of tumor 1 and 2 were dissociated by teasing and passing through a stainless steel sieve. The percentage of Ia+ and MφP-9+ cells were not significantly different from values obtained with enzymatically dissociated preparations.

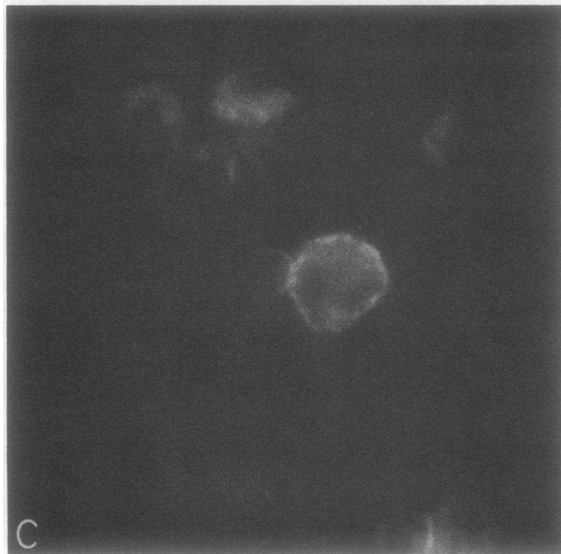
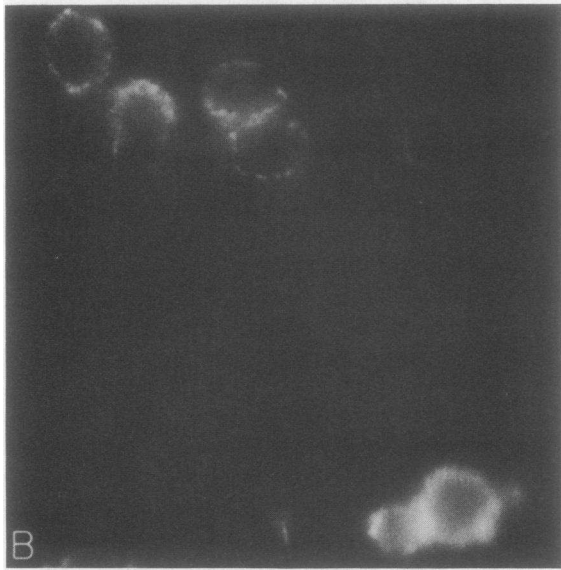
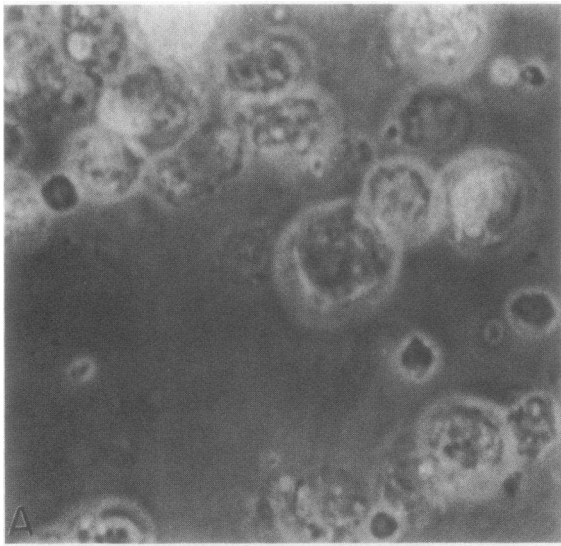
A second subpopulation of stromal cells express Ia antigens but lack monocyte-macrophage markers. In all patients, the number of Ia-positive stromal cells exceeded the number with mature monocyte-macrophage antigens (Tables II and III). From 1 to 24% of the total cell preparation (patient 3) belonged to the subpopulation of Ia antigen (+) mature monocyte antigen (-) cells. In culture these cells were typically spindle-shaped with prominent nucleoli (Fig.3). MφU-50 was identified on approximately one-third of the cells in this subset in patients 2 and 4 using double-

label techniques. Similarly, Fc receptors were identified on one-fifth of the cells in this population.

Fig. 9 illustrates the profile of the binding of the anti-Ia antibody of 22c6 to cells from patient 2. 43% of cells showed positive staining. The intensity of Ia antigen staining by antibody 22c6 was considerably greater than the expression of the monocyte antigen MφP-9 (Fig. 9). Analysis of the light scatter distribution of cells bearing Ia antigens by gating revealed that many of these cells had a large cell size and were found in the channels 200-256.

After 72 h of culture the proportion of cells bearing the Ia antigens without mature monocyte antigens was essentially unchanged, but after 14 d of culture were no longer detectable. When positively selected by fluorescence-activated cell sorting the Ia(+) Mo(-) cells did not show proliferation in culture. Of the freshly sorted Ia positive stromal cells, (patient 4) 56% possessed weak acid phosphatase activity. The Ia(-) population, in contrast, stained much more strongly for the presence of this enzyme. Less than 1% of fresh Ia(+), but monocyte-antigen(-) (MφP-9) cells were phagocytic.

A major third subpopulation of stromal cells that possesses abundant acid phosphatase and proliferates in culture but does not bear monocyte-macrophage or Ia antigens. An average of 69% of stromal cells lacked the expression of Ia and mature monocyte-macrophage antigens (Table III). Less than 1% of these cells ingested latex particles. The primary positive characteristics of these cells were both the intense staining for acid phosphatase and a distinct morphology in culture. This population showed a marked proliferative capacity in culture with cells intermediate in morphology between epitheloid and fibroblastoid cells. 4-9% of the Ia(-) cells expressed the MφU-50



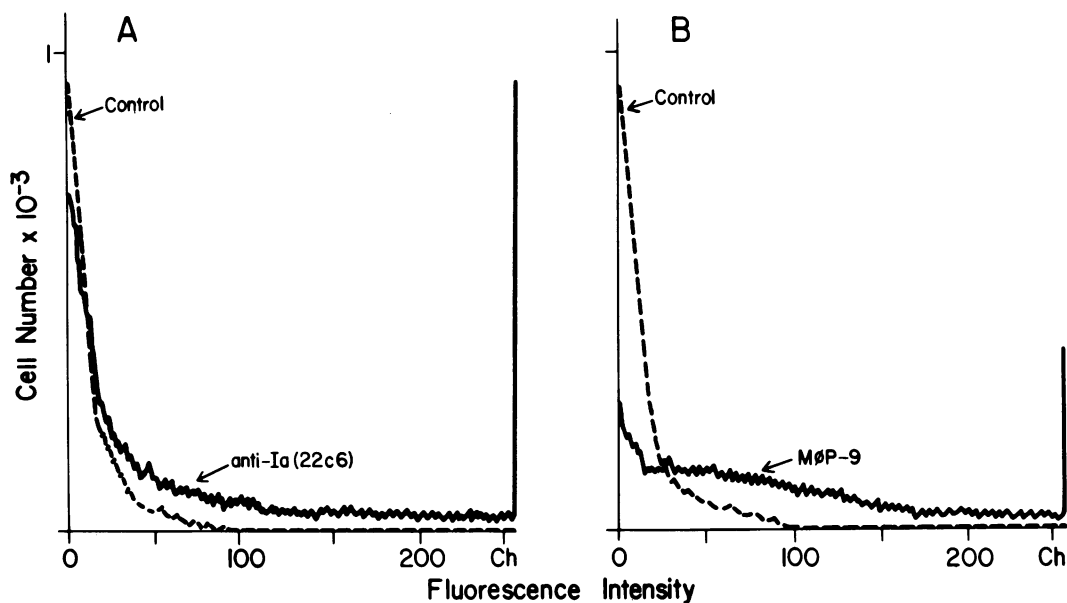


FIGURE 9 Distribution histograms of per cell fluorescence of freshly eluted cells from the tumor of patient 2. (A) Staining for Ia antigens using antibody 22c6. 43% of cells were positive. The distribution demonstrates a large number of intensely positive cells, with many cells displayed in the last channel. The dashed line represents control curve obtained by staining with monoclonal antinitrophenol antibody of the same isotype. (B) Staining for the monocyte-macrophage antigen detected by reagent M ϕ P-9 28% of cells are positive. The staining intensity was less than that of antibody 22c6.

antigenic determinants in association with Fc receptors. To determine if the Ia(-) stromal cells were able to give rise to the large multinucleated cells found in long-term cultures (Fig. 6) selection for the absence of Ia antigens was performed by fluorescence-activated cell sorting. Virtually all of the Ia(-) cells showed intense acid phosphatase activity. They proliferated rapidly, and after 3 wk of culture large multinucleated cells were detected that resembled those in cultures of unfractionated cells. No cells expressed Ia or monocyte-macrophage antigens, but all retained intense acid phosphatase activity.

DISCUSSION

This report provides evidence demonstrating the existence of four distinct cell types in the neoplastic tissues obtained from patients with giant cell tumors of bone (Table IV). The different patterns of genomic

expression distinguishing the cell types were revealed by monoclonal antibody analysis, relative amount of acid phosphatase, and proliferative capacity in culture. The morphologically distinctive giant cell, made up of two otherwise identical subtypes distinguishable by the presence or absence of Ia antigens, is the first cell type. Surface differentiation antigens of mature members of the mononuclear phagocyte lineage were not found on any giant cells. The stromal cells comprise the remaining cell types. A second cell type expressed multiple monocyte-macrophage as well as Ia antigens suggesting the possibility of a relationship to cells of the mononuclear phagocyte lineage. Of considerable interest, this cell differed from typical members of the mononuclear phagocytic lineage by its very limited phagocytic capacity, the presence of an antigen associated with early monocytoïd forms, and the absence of an antigen usually found on tissue macrophages. The phenotype of a third cell type was characterized

FIGURE 8 Double-label analysis of stromal cells ($\times 2,000$). (A) (B) Staining for the monocyte-macrophage antigen M ϕ S-1 tagged with rhodamine reveals a large number of positive cells, however, the cell in the center of the micrograph does not express this antigen. (C) Staining for Ia antigens using the hetero-reagent 962 tagged with fluorescein. All cells expressing M ϕ S-1 also bear Ia antigens, in addition, the cell in the center, negative for M ϕ S-1 expresses Ia antigens.

TABLE IV
Cells Eluted from Giant Cell Tumors Can be Grouped into Five Populations

Property	Stromal cells			Giant cells	
	M-type	I-type	P-type	Ia+	Ia-
Ia antigens	++++	++++	-	++++	-
M ϕ antigens	++++	-	-	-	-
Phagocytosis	-	-	-	-	-
Fc receptor	++	++	-	-	-
M ϕ U-50	+++	+++	+	++++	-
Acid phosphatase	+++ (Weak)	+++ (Weak)	++++ (Strong)	++++ (Strong)	++++ (Strong)
Growth in culture	No	No	Yes	No	No
Culture morphology	Round or elongated	Spindle like	Epitheloid/ fibroblastoid	Round	Round

(-) not detectable; (+) present but identified on <10% of cells; (++) identified on up to 50% of cells; (+++) identified on up to 75% of cells; (++++) identified on nearly 100% of cells.

by the intense expression of Ia antigens and no detectable antigens characteristic of mature monocytes or macrophages. A fourth cell type bore neither Ia nor mature monocyte-macrophage antigens and included all the nongiant cells with pronounced acid phosphatase activity. Only this cell type proliferated in culture.

The second cell type had a novel phenotype and was of considerable interest. Characterized by the intense expression of both Ia antigens, IgG Fc receptors and five antigens of the mononuclear phagocyte lineage, it was distinguished from blood monocytes and macrophages by the absence of the antigen M ϕ R-17 (9), poor phagocytic capacity, and the presence on most cells of an antigenic determinant, M ϕ U-50, characteristic of immature monocytoïd cells. For convenience, these cells that account for up to 36% of the tumor will be referred to as "M type" (Table IV). Compared with blood monocytes, the amount of Ia and the five mature monocyte-related antigens per cell was significantly enhanced and resembled the levels found in activated monocytes or tissue macrophages.¹ The M type cell is presumably identifiable with the subset of stromal cells that show certain ultrastructural characteristics of macrophages described by Asparisi (26). In cultures, the M type cells were found either as elongated spindlelike forms, or with a rounded spreading shape resembling the type I phagocytic synovial lining cell (9, 25). No evidence was obtained indicating that M type cells proliferate in culture even when greatly enriched preparations of these cells were cultured after positive selection by fluorescence-activated cell sorting based on the expression of a mono-

cyte lineage antigen. This finding is consistent with the properties of differentiated mononuclear phagocytes. However, the limited property of phagocytosis is difficult to reconcile with the conventional concept of a mononuclear phagocyte. The presence of the M ϕ U-50 antigen provided some further evidence of both the interrelationship and the unusual position of this cell type with respect to the mononuclear phagocyte lineage. The possibility that the phenotype of the cell has been altered by the method of isolation is a very remote one because extensive experience with this isolation procedure on synovial tissues and in control experiments on blood monocytes has not produced any evidence either of diminished M ϕ R-17 antigen expression or loss of phagocytosis (13). Furthermore, mechanical dissociation of two tumors gave no significant differences in the frequency of Ia+ or M ϕ P-9+ cells. Taken together, these initial data suggest the hypothesis that the M type cell is derived from a hematopoietic progenitor that is related to the progenitor of the mononuclear phagocyte lineage but that the M cell type represents a cell in a pathway of subsequent developments distinct from that of monocytes or macrophages. One possibility is that this cell could represent one element in the lineage leading to osteoclasts.

The third cell type comprising 1-24% of the stromal cells was characterized by the strikingly intense expression of Ia antigens, and a low frequency of cells with IgG Fc receptors (Table IV). Phagocytosis and antigens of mature members of the mononuclear phagocyte lineage were not detectable. These cells have a characteristic spindlelike or irregular morphology with very large nucleoli that distinguishes them from other cell types. This morphology was most clearly seen after culture. For convenience these cells will be referred to as "I type." The cell surface phenotype of this cell type, Ia antigen(+) mature mono-

¹ Dimitriu-Bona, A., R. J. Winchester, P. Merryman, and G. R. Burmester. Manuscript submitted for publication.

cyte-antigen(-), is similar to that of the subtype of Ia positive giant cells. The presence of M ϕ U-50 on certain of these stromal cells supported this parallel. No cells of this phenotype were found in long-term cultures and selection for Ia+ cells by fluorescence-activated cell sorting resulted in nonproliferating cultures. The possibility was considered that endothelial cells might account for this population, since endothelial cells have a phenotype resembling the I type cell. However, the proportion of I type cells did not correlate with the vascularity of the tumor and staining for Factor VIII-associated antigens was not detectable on >98% of the freshly isolated or cultured cells of the tumor.

The fourth cell type recognized in this study bore neither Ia nor monocyte antigens and in each tumor was the most frequent cell population. This cell type had an abundance of acid phosphatase both in fresh cells and after culture. Designated "P type," they were the only ones that exhibited proliferation in culture, making them more likely to be the fundamental tumor cell population to the extent that in vitro behavior reflects the biology of the tumor. Since giant cell tumors are generally benign neoplasms characterized by local infiltration and limited metastatic capabilities, this significant proliferative capacity also raises the question of what event or cell type inhibits their in vivo growth capacity.

The nature of the giant cells characteristic of this tumor has long been a matter of considerable interest. The alternative designation "osteoclastoma" for this tumor reflects the opinion of several investigators that these cells are a neoplastic variant of osteoclasts. This view is supported by the general morphology of these cells and the presence of high levels of acid hydrolases in them (2). The giant cells, however, differ from normal osteoclasts in that they do not directly participate in the resorption of bone (27) and manifest ultrastructural differences including a distinctive cell surface fine structure and the lack of the ectoplasmic layer (3).

The possibility that the giant cells might be reactive rather than neoplastic in origin is suggested by the finding in some inflammatory conditions of giant cells generally similar to those of the tumor derived from small mononuclear precursors (2, 28, 29). The multinucleate giant cells found in synovial tissues of patients with rheumatoid arthritis are characterized by intense expression of Ia and monocyte-macrophage antigens as well as IgG Fc receptors and phagocytosis (13). However, the absence of the mature monocyte macrophage markers on the giant cells of giant cell tumors provides evidence against the idea of this type of direct relationship to cells of the monocyte series.

The consistent finding of four distinct cell types in one tumor suggests two alternative hypotheses: that either each cell type is linked to the others by differ-

entiation events or that the tumor contains several cell populations reacting to the presence of one neoplastic cell type. The contrasting characteristics of the four cell types and in particular the distinctive phenotype of the M type cell could lend support to the concept that the tumor is an admixture of extraneous cell types. However, the absence of evident infiltrating lymphocytes, monocytes, or macrophages, and the uniform occurrence of the four cell types in all tumors favors the view that the cell types are interrelated. There is a reasonable likelihood that the giant cells are derived from P type cell precursors. This is based on the presence in both P type and giant cells of acid hydrolase, the absence of monocyte lineage antigens, IgG Fc receptors, and phagocytosis, and the finding of giant cells in cultures that initially contained only P type cells. Since giant cells arise from mononuclear precursors either by cell fusion or nuclear multiplication without cell division (30, 31), the finding that some fresh giant cells show intensively Ia positive caplike protrusions over a peripheral nucleus provides possible evidence in support of fusion from I cells. This possibility is supported by the presence of the M ϕ U-50 determinants on some cells of both populations.

In view of the growing evidence that the osteoclast is related to the mononuclear phagocyte series (32) and the classic concept of the giant cell tumor as a neoplastic form of an osteoclast, the unusual antigenic phenotype of the M cell could provide the unifying link between all cell types of the tumor, normal osteoclast differentiation, and the monocyte-macrophage lineage. In this view certain stages in the lineage of normal osteoclasts should be analogous to cell types in the giant cell tumor, and the tumor may prove to be of use in studies of the biology of osteoclast formation. Confirmation of these hypotheses will require further detailed studies including the use of monoclonal antibodies raised against each of the tumoral cell types of this curious tumor.

ACKNOWLEDGMENTS

The authors wish to express thanks to Dr. M. Lewis for providing the tissue samples, to Ms. K. J. Olsen for skillful technical assistance, to Mr. K. Kelley for performing analysis on the fluorescence-activated cell sorter and to Mrs. R. Berger and Ms. N. L. Rodriguez for their excellent secretarial assistance.

This study was supported by U.S. Public Health Service grant CA 20107 and AI 19411, an Arthritis Foundation Clinical Research Center award, and the Milton Petrie Arthritis Endowment. Dr. Burmester is a Postdoctoral Fellow of the Deutsche Forschungsgemeinschaft, grant Bu 445/1.

REFERENCES

1. Jaffe, H. L., L. Lichtenstein, and R. B. Portis. 1940. Giant cell tumor of bone. Its pathologic appearance, grading, supposed variants, and treatment. *Arch. Pathol.* 30: 993-1002.

2. Schajowicz, J. 1961. Giant cell tumors of bone. *J. Bone Joint Surg.* 43-A: 1-29.
3. Sanerkin, N. G., and G. M. Jeffree. 1980. Cytology of Bone Tumors. John Wright & Sons Ltd., Bristol, U.K. 96-99.
4. Schajowicz, Fritz. 1981. Giant cell tumor (osteoclastoma). In Tumors and Tumor-like Lesions of Bone and Joint. Springer-Verlag, New York. 205-239.
5. Johnston, J. 1977. Giant cell tumor of bone. The role of the giant cell in orthopedic pathology. *Orthop. Clin. North Am.* 8: 751-770.
6. Aegerter, E., and J. A. Kirpatrick, Jr. 1975. Orthopedic Diseases: Physiology, Pathology, Radiology. 4th edition. W. B. Saunders Company, Philadelphia. 607-620.
7. Ugolini, V., G. Nunez, R. G. Smith, P. Stastny, and J. D. Capra. 1980. Initial characterization of monoclonal antibodies against human monocytes. *Proc. Natl. Acad. Sci. USA.* 77: 6764-6768.
8. Todd, R. F., and S. F. Schlossman. 1982. Analysis of antigenic determinants on human monocytes and macrophages. *Blood.* 59: 775-786.
9. Dimitriu-Bona, A., G. R. Burmester, S. J. Waters, and R. J. Winchester. 1983. Human monocyte-macrophage differentiation antigens. *J. Immunol.* 130: 145-162.
10. Winchester, R. J., and H. G. Kunkel. 1979. The human Ia system. *Adv. Immunol.* 28: 221-292.
11. Steiner, G. C., L. Goch, and H. D. Dorfman. 1972. Ultrastructure of giant cell tumors of bone. *Hum. Pathol.* 3: 569-586.
12. Schajowicz, F., L. V. Ackerman, and H. A. Sissons. 1972. Histological typing of bone tumors. International histological classification of tumors, No. 6. World Health Organization, Geneva.
13. Burmester, G. R., A. Dimitriu-Bona, S. J. Waters, and R. J. Winchester. 1983. Identification of three major synovial lining cell populations by monoclonal antibodies directed to Ia antigens and antigens associated with monocytes/macrophages and fibroblasts. *Scand. J. Immunol.* 17: 69-82.
14. TeVelde, J., R. Burkhardt, K. Kleiverda, L. Leenheers-Binendijk, and W. Sommerfield. 1977. Methyl methacrylate as an embedding media in histopathology. *Histopathology.* 1: 319-330.
15. Spyker, H. J. D. 1978. A procedure for obtaining thin sections of undecalcified bone biopsies embedded in methyl methacrylate. *Microsc. Acta.* 81: 17-26.
16. Gomori, G. 1941. Distribution of acid phosphatase in tissues under normal and pathological conditions. *Arch. Pathol.* 32: 189-199.
17. Taylor, C. R. 1978. Immunoperoxidase techniques. Practical and theoretical aspects. *Arch. Pathol. Lab. Med.* 102: 113-121.
18. Herzenberg, L. A., and L. A. Herzenberg. 1979. Analysis and separation using the fluorescence-activated cell sorter (FACS). In Handbook of Experimental Immunology. D. M. Weir, editor. Blackwell Scientific Publications. 22: 1-22.21.
19. Burmester, G. R., D. T. Y. Yu, A. M. Irani, H. G. Kunkel, and R. J. Winchester. 1981. Ia+ T cells in synovial fluid and tissues of patients with rheumatoid arthritis. *Arthritis Rheum.* 24: 1370-1376.
20. Dimitriu-Bona, A., K. Kelley, and R. Winchester. 1982. Differentiation antigens on human monocytes and monocyte-like U937 cells as defined by monoclonal antibodies. *Fed. Proc.* 41: 368a. (Abstr.)
21. Dimitriu-Bona, A., R. J. Winchester, I. Szer, M. Reilly, V. Najfeld, and J. Cuttner. 1982. Expression of early or mature monocyte-related antigens on certain acute myeloid leukemias (AML) before and after culture. *Clin. Res.* 30: 512a. (Abstr.)
22. Reinherz, E. L., P. C. Kung, G. Goldstein, and S. F. Schlossman. 1979. A monoclonal antibody with selective reactivity with functionally mature thymocytes and all peripheral human T cells. *J. Immunol.* 123: 1312-1317.
23. Winchester, R. J., C. Y. Wang, J. Halper, and T. Hoffman. 1976. Studies with B cell allo- and heteroantisera: parallel reactivity and special properties. *Scand. J. Immunol.* 5: 745-757.
24. Winchester, R. J., T. Hoffman, M. Ferrarini, G. D. Ross, and H. G. Kunkel. 1979. Comparison of various tests for Fc receptors on different human lymphocyte subpopulations. *Clin. Exp. Immunol.* 37: 126-133.
25. Winchester, R. J., and G. R. Burmester. 1981. Demonstration of Ia antigens on certain dendritic cells and on a novel elongate cell found in human synovial tissues. *Scand. J. Immunol.* 14: 441-446.
26. Asparisi, T. 1978. Giant cell tumor of bone. Electron microscopic and histochemical investigations. *Acta. Orthop. Scand.* (Suppl 173): 7-35.
27. Glimcher, M. J., S. Sakamoto, M. Sakamoto, J. Kenzora, A. Tashjian Jr., and P. Goldhaber. 1977. Stimulation of bone resorption in tissue culture by giant cell tumours. *Orthop. Trans.* 1: 233.
28. Galindo, B. 1972. Antigen-mediated fusion of specifically sensitized rabbit alveolar macrophages. *Infect. Immun.* 5: 583-591.
29. Postlethwaite, A. E., B. K. Jackson, E. H. Beachey, and A. H. Kang. 1982. Formation of multinucleated giant cells from human monocyte precursors. Mediation by a soluble protein from antigen- and mitogen-stimulated lymphocytes. *J. Exp. Med.* 155: 168-178.
30. Byers, V. S., A. S. Levine, J. O. Johnston, and A. J. Hackett. 1975. Quantitative immunofluorescence studies of the tumor antigen-bearing cell in giant cell tumor of bone and osteogenic sarcoma. *Cancer Res.* 35: 2520-2531.
31. Gallardo, H., F. S. Lustig, and F. Schajowicz. 1970. Growth and maintenance of human giant cell bone tumors (osteoclastomas) in continuous culture. *Oncology.* 24: 146-159.
32. Burger, E. H., J. W. M. van der Meer, J. S. van de Gevel, J. C. Gribnan, C. W. Thesingh, and R. van Furth. 1982. In vitro recruitment of osteoclasts from mononuclear phagocytes. In Proceedings of the 9th International Reticuloendothelial System Conference. Abstract 47.