

Persistent Testicular Δ^5 -Isomerase- 3β -Hydroxysteroid Dehydrogenase (Δ^5 - 3β -HSD) Deficiency in the Δ^5 - 3β -HSD Form of Congenital Adrenal Hyperplasia

GEORGE SCHNEIDER, MYRON GENEL, ALFRED M. BONGIOVANNI,
ALLEN S. GOLDMAN, and ROBERT L. ROSENFIELD

From the Departments of Pediatrics and Medicine, Yale University School of Medicine, New Haven, Connecticut 06510, the Children's Hospital of Philadelphia and the Department of Pediatrics, University of Pennsylvania School of Medicine, Philadelphia, Pennsylvania 19104, and the Department of Pediatrics, University of Chicago, Pritzker School of Medicine, Chicago, Illinois 60637

ABSTRACT A partial testicular defect in testosterone secretion has been documented in a pubertal male with a congenital adrenal hyperplasia due to hereditary deficiency of the Δ^5 -isomerase- 3β -hydroxysteroid dehydrogenase enzyme complex (Δ^5 - 3β -HSD). Diagnosis of the enzymatic defect is based on the clinical picture of ambiguous genitalia and salt-losing crisis in infancy, together with high urinary Δ^5 -pregnenetriol and plasma dehydroepiandrosterone when the patient was taken off replacement corticoid treatment. No hormonal response to ACTH or salt deprivation was demonstrable. In addition, in vivo studies revealed a partial enzymatic defect in the testis. Although plasma testosterone was low-normal (250 ng/100 ml), plasma Δ^5 -androstenediol was markedly elevated and rose to a greater extent than testosterone after human chorionic gonadotropin administration. In vitro testicular incubation studies suggested a testicular Δ^5 - 3β -HSD enzyme defect with less Δ^4 products formed from Δ^5 precursors than in a control testis. Histochemical studies of the testis were also consistent with this defect. Testicular biopsy revealed spermatogenic arrest, generally diminished Leydig cells, but with focal areas of Leydig cell hyperplasia as well as benign Leydig cell nodules within the spermatic cord. In vivo studies of steroid metabolism suggested intact peripheral or hepatic Δ^5 - 3β -HSD activity. These studies imply that Δ^5 - 3β -HSD activity differs in the gonad, adrenal, and peripheral organs. These findings are compatible with the concept that the enzyme complex consists of subunits and/or that enzymes in these organs are under different genetic control.

genetic arrest, generally diminished Leydig cells, but with focal areas of Leydig cell hyperplasia as well as benign Leydig cell nodules within the spermatic cord. In vivo studies of steroid metabolism suggested intact peripheral or hepatic Δ^5 - 3β -HSD activity. These studies imply that Δ^5 - 3β -HSD activity differs in the gonad, adrenal, and peripheral organs. These findings are compatible with the concept that the enzyme complex consists of subunits and/or that enzymes in these organs are under different genetic control.

INTRODUCTION

The first description of the Δ^5 -isomerase- 3β -hydroxysteroid dehydrogenase (Δ^5 - 3β -HSD)¹ deficiency form of congenital adrenal hyperplasia was made by Bongiovanni in 1962 (1). The first direct demonstration of the enzymatic defect in both the adrenals and testes of a 6-wk-old male with the disease was reported in 1964 (2). Since then, a number of other cases have been described, including two achieving spontaneous puberty (3, 4), both males with hypospadias, gynecomastia, and appropriate secondary sexual development. In one, however, a normal testosterone response to human chorionic gonadotropin (HCG) stimulation at

An abstract of a portion of this work has appeared in *Pediatr. Res.* 7: 332/104. 1973.

Dr. Schneider was a trainee in endocrinology supported by U. S. Public Health Service Grant T01-AM05015 and his present address is the Veterans' Administration Hospital, East Orange, N. J. 07019. Drs. Goldman and Rosenfield are recipients of Research Career Development Awards HD-13-268 and HD-70-152, respectively, from the United States Public Health Service.

Received for publication 29 October 1973 and in revised form 6 December 1974.

¹Abbreviations used in this paper: Δ^5 - 3β -HSD, Δ^5 -isomerase- 3β -hydroxysteroid dehydrogenase enzyme complex; DHA, dehydroepiandrosterone; DHAS, dehydroepiandrosterone sulfate; DOCA, desoxycorticosterone acetate; FSH, follicle-stimulating hormone; HCG, human chorionic gonadotropin; IRP, International Reference Preparation, LH, luteinizing hormone.

age 13 suggested postnatal normalization of testosterone secretion and reserve (3).

We have investigated another pubertal boy with clinical evidence of Δ^5 - 3β -HSD deficiency. Studies of his pituitary-Leydig cell axis in vivo and of testicular biosynthesis in vitro indicate that, although this enzyme defect seems complete in the adrenal, it is partial in the testes. In contrast, peripheral enzyme activity appears to be intact.

METHODS

Plasma cortisol², androstenedione, dehydroepiandrosterone (DHA), dehydroepiandrosterone sulfate (DHAS), Δ^5 -androstenediol, and testosterone were measured by competitive protein binding (5-9). Plasma estradiol, estrone, luteinizing hormone (LH), and follicle-stimulating hormone (FSH) were measured by radioimmunoassay (10-12). The second International Reference Preparation (IRP) of human menopausal gonadotropin was used for dose interpolation in both LH and FSH assays. 1 mIU of LH activity of the second IRP is equivalent to 3.9 ng of LER 907, a pituitary gonadotropin preparation, and 1 mIU of FSH activity is equivalent to 30.0 ng of LER 907. Plasma renin activity was performed by bioassay by the method of Skinner (13). Urine hydroxycorticoids were measured by a modification of the method of Porter and Silber (14). Urinary 17-ketosteroids were measured by a modification of the Zimmermann method (15). Urinary aldosterone was measured by the double isotope derivative technique (16). Urinary pregnanetriol, 11-ketopregnanetriol, 17-hydroxypregnanolone, and Δ^5 -pregnenetriol were measured by gas-liquid chromatography (17). Urinary gonadotropins were measured by bioassay³ (18).

In vitro testicular incubations were performed on both a biopsy specimen from the patient and from a control, a 67-yr-old white male with cancer of the prostate, who had been treated with estrogens before orchiectomy. The testes were minced on ice with an iris scissors, and then duplicate 60-mg portions were incubated in 1.0 ml of Krebs-Ringer phosphate buffer, pH 7.4, containing 120 mg glucose/

100 ml and either 4.0 μ g, 0.67 μ Ci [¹⁴C]pregnenolone (sp act 52.8 mCi/mM)⁴ or 0.98 μ g, 0.2 μ Ci [¹⁴C]DHA (sp act 58.8 mCi/mM)⁴. A high mass per tissue quantity of substrate was deliberately chosen to negate any pool size differences. The incubations were carried out for 1 h at 37°C under 95% O₂/5% CO₂ and terminated by the addition of 4 ml of methanol. The flasks were stored at -20°C until purification of steroid metabolites. The incubation products were identified as previously described (19, 20).

In addition, an in vitro microincubation of 3 mg of the biopsy specimen of the patient was also performed by our previously published micro method (21). The tissue was incubated for 1 hr at 37°C in 20 μ l phosphate buffer, pH 7.4, containing 2.45 μ g, 0.5 μ Ci [¹⁴C]DHA (sp. act. 58.8 mCi/mM)⁴ in 1 μ l dimethylsulfoxide, 145 nM NAD, 18 nM NADP, 66 nM glucose-6-phosphate, and 0.4 U. glucose-6-phosphate dehydrogenase. The reaction was terminated with 250 μ l (1/1: vol/vol) ethanol-acetone. The labeled products were separated by a partition system on thin-layer chromatography, with propylene glycol as stationary phase and carbon-tetrachloride-cyclohexane (90/10: vol/vol) as mobile phase. Label peaks were also identified by radio-gas liquid chromatography with 3% OV-210⁵ and by recrystallization to constant specific activity, as previously described (21).

Histochemistry. Activity of Δ^5 - 3β -HSD was determined as previously described (22) in the testis of this patient and in a control testis obtained at gonadectomy from a 12-yr-old patient with incomplete testicular feminization.

Case summary. M.D., a 15-yr-old white male, was previously described as a case of the salt-losing 21-hydroxylase form of congenital adrenal hyperplasia (23). A third-degree hypospadias with a bifid scrotum was noted at birth. At 10 wk he required admission to the Yale-New Haven Hospital for therapy of severe dehydration associated with projectile vomiting. Serum sodium was 114 meq/liter, potassium 9.6 meq/liter, and chloride 85 meq/liter. Buccal smear was chromatin negative, and intravenous pyelogram and bone age were normal. 17-ketosteroid excretion was 19.7 mg/24 hr. Fractionation of the 17-ketosteroids revealed DHA to be 3.3 mg/24 hr, androsterone 6.0 mg/24 h, etiocholanolone 2.4 mg/24 h, 11-oxy-17-ketosteroids 4.0 mg/24 h, and pregnanetriol 4.0 mg/24 h, all elevated. Neither pregnanediol nor 11-ketopregnanetriol, usually increased in the 21-hydroxylase form of congenital adrenal hyperplasia (24), were detected, and Δ^5 -pregnenetriol was not measured. Family history was negative for consanguinity, congenital adrenal hyperplasia, ambiguous genitalia, salt-losing states, and sudden death in infancy. The only sibling was a normal female. The diagnosis of salt-losing congenital adrenal hyperplasia with male pseudohermaphroditism was made, and he responded to saline, desoxycorticosterone acetate (DOCA), and cortisone therapy clinically and with decreased 17-ketosteroid and pregnanetriol excretion.

He was maintained on varying doses of hydrocortisone, depending on 17-ketosteroid excretion and growth, and with DOCA pellets for 4-yr, after which 9 α -fluorohydrocortisone was substituted. 10 urological procedures were performed in his first decade to correct the hypospadias. Puberty began at age 10 yr, and gynecomastia at 11. Over the next 18 mo, the gynecomastia, pubic hair, and acne increased, and axillary hair developed. Bilateral mastectomy was performed with a tissue diagnosis of ductal hyperplasia.

During the next 10 mo pubic and axillary hair increased, and his testes increased in size from 3 \times 3 cm to 6 \times 4 cm,

² The following compounds and their trivial names and abbreviations are used in this paper: 11 β , 17,21-trihydroxypregn-4-ene-3,20 dione (cortisol); androst-4-ene-3,17 dione (androstenedione); 3 β -hydroxyandrost-5-en-17-one (dehydroepiandrosterone, DHA); androst-5-en-17-one-3 β -yl sulfate (dehydroepiandrosterone sulfate, DHAS); androst-5-en-3 β , 17 β -diol (Δ^5 -androstenediol); estra-1,3,5,(10)-triene-3, 17 β -diol (estradiol); 3-hydroxy-estra-1,3,5 (10)-triene-17-one (estrone); 11 β ,21-dihydroxy-18-oxy-18-one-3,20-dione (aldosterone); 5 β -pregnane-3 α ,17 α ,20 α -triol (pregnanetriol); 3 α ,17 α ,20 α -trihydroxy-5 β -pregnan-11-one (11-ketopregnanetriol); 3 α ,17 α -dihydroxy-5 β -pregnan-20-one (17-hydroxypregnanolone); preg-5-ene-3 β ,17 α ,20 α -triol (Δ^5 -pregnenetriol); 17 β -hydroxyandrost-4-en-3-one (testosterone); 9 α -fluoro-16 α -methyl-11 β ,17 α ,21-trihydroxypregn-1,4-diene-3,20 dione (dexamethasone); 3 α -hydroxy-5 α -androstan-17-one (androsterone); 3 α -hydroxy-5 β -androstan-17-one (etiocholanolone); 17 β -hydroxy-5 α -androstan-3-one (dihydrotestosterone); 3 β -hydroxypregn-5-en-20-one (pregnenolone); 3 β ,17 α -dihydroxy-pregn-5-en-20-one (17 α -hydroxypregnenolone); 17 α -hydroxypregn-4-ene-3,20 dione (17-hydroxyprogesterone); 5 β -pregnane-3 α ,20 α -diol (pregnanediol).

³ Bio-Science Laboratories, Van Nuys, Calif.

⁴ New England Nuclear, Boston, Mass.

⁵ Supelco, Inc., Bellefonte, Pa.

TABLE I
Response to HCG Stimulation under Dexamethasone Suppression*

Study days	Normal values	1	2	3	4	5	6	7
Dexamethasone (2 mg every 6 h)		x	x	x	x	x	x	x
9 α -Fluorohydrocortisone (0.1 mg/day)		x	x	x	x	x	x	x
HCG (2,000 U i.m. every 12 hr)				x	x	x	x	
Plasma†								
Cortisol, $\mu\text{g}/100\text{ ml}$	5–20			2				
Androstenedione, $\text{ng}/100\text{ ml}$	70–160			39				86
DHA $\text{ng}/100\text{ ml}$	220–800			227				293
DHAS, $\mu\text{g}/100\text{ ml}$	115–265			92				157
Δ^5 -Androstenediol, $\text{ng}/100\text{ ml}$	80–170			285				712
Testosterone, $\text{ng}/100\text{ ml}$	240–1,000			250		210		475
Estrone, pg/ml	<50			10		10		14
Estradiol, pg/ml	<50			9		84		28
LH, mIU/ml	10–20	10	9	11				
FSH, mIU/ml	10–20	13	13	11				

* Study commenced 7 days after substitution of 1 mg/day dexamethasone (0.5–0.25–0.25 mg every 8 h) for routine suppressive therapy with 35 mg/day hydrocortisone (15 mg–10 mg–10 mg).

† All plasma was obtained at 8 a.m. before instituting changes indicated in the study protocol.

becoming nodular and hard in consistency. Three small 0.5–1.0-cm nodules became palpable in the left spermatic cord. His 17-ketosteroids were 19.0–22.5 mg/24 h. Plasma testosterone was 400 ng/100 ml (normal adult, 240–1,000 ng/ml). When hydrocortisone replacement was increased from 20 to 35 mg/24 h, the right testis shrank to 5 × 2.5 cm, but the left did not change.

Physical examination at age 14 yr and 7 mo revealed a well-developed pubertal boy with acne. Height was 158 cm (height age = 13 yr). Bilateral subareolar mastectomy scars were hyperpigmented with slight keloid formation. There was a moderate amount of pubic and axillary hair but little beard development. The penis was 6 cm in length with a first-degree hypospadias, the result of multiple surgical procedures. The right testis was 5 × 2.5 cm and was normal in consistency, whereas the left testis was 6 × 3 cm and was firm and nodular. The left spermatic cord contained three to four hard 0.5-cm nodules. The scrotum was rugated. The prostate was not palpable on rectal examination.

Clinical studies. The patient was admitted to the Yale Children's Clinical Research Center after he and his parents were informed of the nature, purpose, and possible risks of the studies, and voluntary consent to participate was obtained. 1 wk before admission, replacement therapy was changed from 35 mg of hydrocortisone in divided doses to dexamethasone, 1 mg/day (0.5–0.25–0.25 mg). Biopsy of the left testis was performed, and one of the nodules in the left spermatic cord was removed under general anesthesia with parenteral dexamethasone and DOCA coverage. After uneventful recovery, the dexamethasone dose was increased to 8 mg/day (2 mg every 6 h) to assure complete suppression of ACTH secretion. 2 days later response to administration of HCG was studied according to the protocol depicted in Table I. Response of the renin-aldosterone system to acute salt deprivation was then studied after a return to 1 mg/day replacement dexamethasone dose for 48 h. Mineralocorticoid therapy with 9 α -fluorohydrocortisone was discontinued, and dietary sodium was restricted to 1 g/day. 24-h urines were collected on the 2nd and 3rd days of this

regimen for aldosterone and electrolyte determinations. Blood was obtained for plasma renin activity, both supine and after 4 h of exercise on the 3rd day.

At a later date, adrenal function was evaluated according to the protocol in Table II. The patient was taken off 9 α -fluorohydrocortisone and hydrocortisone and given 50 mg i.m. of long-acting desoxycorticosterone pivalate. After 21 days off oral therapy, urine was collected for pregnanetriol, 11-ketopregnanetriol, 17-hydroxypregnanolone, Δ^5 -pregnenetriol, 17-ketosteroids, and 17-hydroxycorticoids. Blood was also obtained for various steroid determinations. In addition, blood for LH and FSH was obtained every 10 min for 3 h during the morning. The patient was then given ACTH gel, 25 U every 12 h for 3 days with concurrent blood and urine collections. After this he was again treated with 8 mg/day of dexamethasone for 9 days.

At a later date, while continued on his usual maintenance therapy of 35 mg of hydrocortisone and 0.05 mg of 9 α -fluorohydrocortisone, the patient received oral 17 α -hydroxypregnenolone, 1 mg/kg body weight, in a dilute alcohol solution. 24-h urine collections were obtained for 2 days before, during, and 2 days after the day of administration of the steroid for determination of Δ^5 -pregnenetriol and pregnanetriol. Blood for LH and FSH determinations was again obtained every 10 min for 3 h during the morning during maintenance therapy.

RESULTS

Testicular pathology. The predominant histologic picture was of an immature testis inconsistent with the patient's state of advanced pubertal development. Seminiferous tubules showed spermatogenic arrest with predominantly Sertoli cell lining. For the most part, Leydig cells appeared prominent though relatively diminished in number, although occasional areas of focal Leydig cell hyperplasia were noted. The nodule removed from the left spermatic cord demonstrated be-

TABLE II
Response to ACTH and High Dose Dexamethasone Suppression in Untreated State*

Study days	Normal values	1	2	3	4	5	6	7	8	9	10	11	12	13	14
Dexamethasone (2 mg every 6 h)							x	x	x	x	x	x	x	x	x
ACTH (25 U i.m. every 12 h)				x	x	x									
Plasma‡															
Cortisol, $\mu\text{g}/100\text{ ml}$	5-20	3	3				2								2
Androstenedione, $\text{ng}/100\text{ ml}$	70-160	93	119				119								15
DHA, $\text{ng}/100\text{ ml}$	220-800	1,416	1,665				1,736								118
DHAS, $\mu\text{g}/100\text{ ml}$	115-265	227	172				265								55
Δ^5 -Androstenediol, $\text{ng}/100\text{ ml}$	80-170	436	449				397								99
Testosterone, $\text{ng}/100\text{ ml}$	240-1,000	471	450				365								184
Estrone, pg/ml	<50	28					29								8
Estradiol, pg/ml	<50	36					33								5
LH, mIU/ml	10-20	10.3					9.7								25.6
FSH, mIU/ml	10-20	10.7					9.3								20.7
Urine‡															
17-hydroxycorticoids, mg/day	3-10	0.1			0.1	0.1									
17-ketosteroids, mg/day	5-15	13.5			9.2	3.2									
Pregnanetriol, mg/day	0.8-3.1	8.4			5.2	8.0									
Δ^5 -Pregnenetriol, mg/day	0.1-0.4	7.4			4.7	7.2									

* Study commenced 21 days after cessation of hydrocortisone and 9 α -fluorohydrocortisone therapy and administration of 50 mg desoxycorticosterone pivalate i.m.

‡ All plasma was obtained at 8 a.m. before instituting changes indicated in the study protocol. Urine collections began at 8 a.m. on the day designated, concluding at 8 a.m. the following day.

nign Leydig cell hyperplasia, although crystalloids of Reinke were not observed.

Response to HCG stimulation (Table I). After 2 days of high-dose dexamethasone suppression, plasma Δ^5 -androstenediol was elevated, whereas plasma testosterone was low normal and plasma androstenedione, DHA, and DHAS were low. After 4 days of 4,000 U of i.m. HCG, plasma Δ^5 -androstenediol more than doubled to 712 ng/100 ml, whereas plasma testosterone rose less than twofold to 475 ng/100 ml. Plasma estradiol was low but was stimulated by HCG. Estrone remained low both before and after HCG.

Mineralocorticoids. While on ordinary replacement therapy, aldosterone excretion was only 1.7 $\mu\text{g}/\text{day}$ (normal = 5-20 $\mu\text{g}/\text{day}$). During the period of sodium restriction, while off 9 α -fluorohydrocortisone therapy, urinary aldosterone failed to rise (1.3 and 0.7 $\mu\text{g}/\text{day}$), despite a significant rise in plasma renin activity from 2.3 ng of angiotensin I generated/ml/h to 4.8 supine and 9.4 after exercise. Urinary Na during this period rose to 250 meq/liter from previous values of 130 and 158 meq/liter. Serum Na did not change significantly, but serum K rose from 4.3 to 5.3 meq/liter, and the blood-urea nitrogen rose from 14 to 23 mg/100 ml. This aspect of the study was terminated after 72 h because of clinical signs of mild dehydration.

Adrenal studies (Table II). When the patient was taken off hydrocortisone for 3 wk, his urinary Δ^5 -pregnenetriol excretion was 7.42 mg/day (normal 0.1-0.4 mg/day for adults) and urinary pregnanetriol was 8.42 mg/day (normal 0.8-3.1 mg/day for adults). Total

17-ketosteroids were 13.5 mg/day, and 17-hydroxycorticoids were 0.1 mg/day. Neither 11-ketopregnanetriol nor 17-hydroxypregnanolone, two compounds usually seen in 21-hydroxylase deficiency, were found. On the 2nd day of ACTH gel, the patient's urinary volume fell from 1,926 cm^3 to 850 cm^3 , and Δ^5 -pregnenetriol excretion was 4.73 mg/day while pregnanetriol excretion was 5.17 mg/day. On the 3rd day of ACTH gel, the urinary volume fell further to 620 cm^3 , while Δ^5 -pregnenetriol excretion was 7.24 mg and pregnanetriol excretion was 7.97 mg. The 17-ketosteroids also fell to 9.2 and 3.2 mg on the 2nd and 3rd days of ACTH, respectively. The 17-hydroxycorticoids were always 0.1 mg. The lack of a rise in urinary pregnanetriol and Δ^5 -pregnenetriol during ACTH probably reflects maximal adrenal stimulation by endogenous ACTH, while the drop in 17-ketosteroid excretion during this same time is most likely related to the drop in urine volume (25, 26), probably attributable to vasopressin contamination of ACTH preparations.

At that time when the patient was off hydrocortisone, plasma DHA was almost twice normal (1416 ng/ml), whereas DHAS was normal and androstenedione was low normal. Both Δ^5 -androstenediol and testosterone were significantly higher than at the beginning of the initial study, but the ratio of the two compounds remained approximately the same. In addition, plasma estrone and estradiol, although within normal limits, were significantly higher than when the patient was on glucocorticoid therapy. 3 days of ACTH stimulation led to a minimal rise in DHA, DHAS, and an-

drostenedione, a slight fall in testosterone and Δ^5 -androstenediol, and no change in estrone or estradiol, again probably reflecting maximal endogenous ACTH stimulation. Plasma cortisol was very low both before and after ACTH. After 9 days of high-dose dexamethasone, all androgens and estrogens fell significantly.

Gonadotropin secretion. Sequential plasma LH and FSH were always within normal limits during the two study periods on and off therapy, and there was no difference in either the LH or FSH levels during these two periods. Mean LH \pm SE off corticoid therapy was 13.35 \pm 2.85 mIU/ml, while on therapy it was 13.67 \pm 3.03 mIU/ml. Mean FSH \pm SE off therapy was 12.37 \pm 2.55 mIU/ml and 14.41 \pm 0.85 mIU/ml on therapy.

In addition, random plasma LH and FSH determinations obtained at various times during the study were always within normal limits, except for one occasion after 9 days of high-dose dexamethasone suppression (Table II). At this time, both plasma LH and FSH were slightly elevated, corresponding to a simultaneous decrease in the levels of plasma androgens and estrogens. Urinary gonadotropins, measured by bioassay, were slightly elevated (>48, >96 mouse uterine U/day on three of four 24-h collections), although simultaneous plasma LH and FSH levels were normal.

Metabolism of 17 α -hydroxypregnenolone (Fig. 1). As indicated, while continued on routine hydrocortisone replacement of 35 mg/day, base-line Δ^5 -pregnenetriol was undetectable and pregnanetriol was within normal limits, thus indicating adequate pituitary-adrenal suppression. After the administration of an oral load of the Δ^5 steroid, 17 α -hydroxypregnenolone, the patient excreted the major amount as pregnanetriol and only a minor amount as Δ^5 -pregnenetriol.

In vitro studies (Figs. 2 and 3). With pregnenolone and DHA as substrates, the patient's testis was able to make a small amount of testosterone, but this was only one-third that of the control. Although conversion to Δ^5 -androstenediol was not quantitated in the study depicted, a compound with the mobility of Δ^5 -androstenediol on both paper and thin-layer chromatography consistently had four times more 14 C counts in the patient's incubation, as compared to the control. With the micro method, the patient's testis formed similar amounts of testosterone (0.2% of substrate) and androstenedione (4.2% of substrate) as in the macro method. In addition, Δ^5 -androstenediol was the major metabolite formed from DHA by the patient's testis, representing 6.4% of the substrate with its identity confirmed by radio-gas-liquid chromatography and recrystallization to constant specific activity.

Histochemistry. Histochemical studies of the patient's testis demonstrated undetectable Leydig cell Δ^5 -

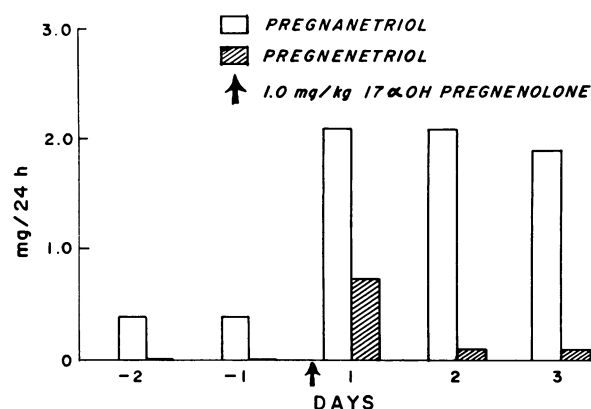


FIGURE 1 The excretion of pregnanetriol and pregnenetriol before and after the oral administration of 17 α -hydroxypregnenolone (1 mg/kg). -2 and -1 are the two control days before the steroid was administered.

3 β -HSD activity with DHA as the substrate. In contrast, intense staining for this enzyme was readily demonstrated in the Leydig cells from the control testis. Identical results were obtained in both testes with pregnenolone as the substrate.

DISCUSSION

Hereditary Δ^5 -3 β -HSD deficiency in males is characterized by adrenal insufficiency, pseudohermaphroditism, and marked salt-wasting, generally leading to death in early infancy (1, 27). However, long-term survival has been reported in a number of cases thought to represent partial deficiency states (3, 28-32). Recently, Finnish investigators have published studies obtained during the natural puberty (4) of their earlier reported case (31). As in the first-described pubertal male (3), their patient's adolescence was characterized by gynecomastia but otherwise showed normal secondary sexual development.

Our patient presented in the newborn period with a typical picture of complete adrenal insufficiency. Although he was originally reported as a case of 21-hydroxylase deficiency with salt-losing and hypospadias (23), the present studies clearly indicate an adrenal deficiency of the Δ^5 -3 β -HSD complex. After 3 wk off routine adrenal suppressive therapy, urinary Δ^5 -pregnenetriol, plasma DHA, and Δ^5 -androstenediol were grossly elevated, and corticoid excretion was low. Moreover, the urinary Δ^5 -pregnenetriol:pregnanetriol ratio was nearly 1(0.88), whereas this ratio ranges from 0 to 0.28 in patients with the more common 21-hydroxylase deficiency form of congenital adrenal hyperplasia (17). Absence of 11-ketopregnanetriol and 17-hydroxypregnanolone is another strong point against the diagnosis of a 21-hydroxylase deficiency. ACTH administration did not lead to the normal, appreciable

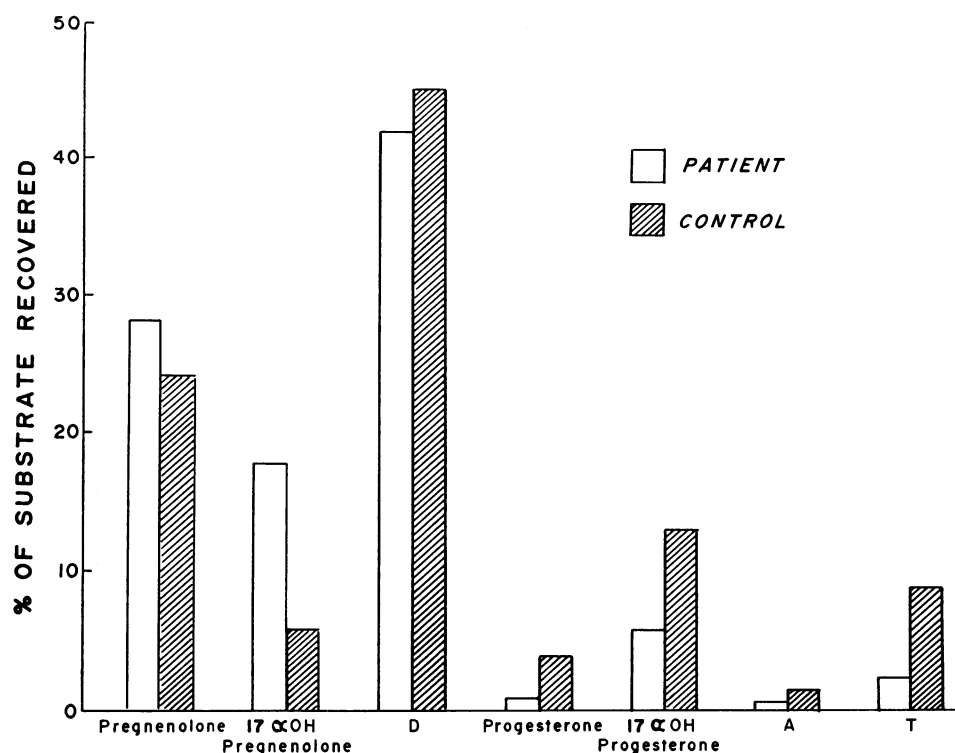


FIGURE 2 Testicular conversion of pregnenolone to various Δ^5 and Δ^4 products in vitro, expressed as percent recovery of original substrate. 60 mg of minced testis were incubated with 4.0 μ g, 0.67 μ Ci of [14 C]pregnenolone in 1.0 ml of Krebs-Ringer phosphate buffer, pH 7.4, containing 120 mg of glucose/100 ml for 1 h. D, dehydroepiandrosterone; A, androstenedione; T, testosterone.

increase in C_{21} or C_{19} steroids (33), consistent with already maximum endogenous ACTH stimulation typical of congenital adrenal hyperplasia. As in the neonatal

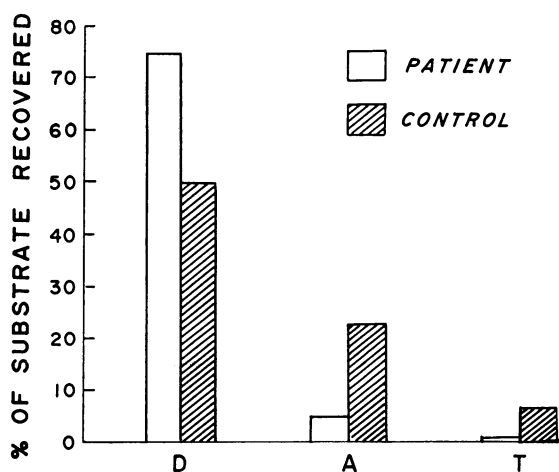


FIGURE 3 In vitro testicular recovery of androstenedione (A) and testosterone (T) after incubation of minced testis with 0.98 μ g, 0.2 μ Ci of [14 C]dehydroepiandrosterone (D). Conditions identical to Fig. 2.

period, glucocorticoids reversed the biochemical abnormality. Furthermore, aldosterone excretion was low and remained low when the mineralocorticoid therapy was discontinued, and dietary salt restriction led to negative sodium balance, a rise in serum potassium, and an appropriate increase in plasma renin, also consistent with adrenal Δ^5 -3 β -HSD deficiency.

Since testicular Δ^5 -3 β -HSD activity is necessary for production of testosterone, the main secretory product of the human testes, male pseudohermaphroditism in the syndrome has been ascribed to a coexisting deficiency of this enzyme complex (2). This concept has not been proven by studies of the Δ^4 pathway from progesterone via 17-hydroxyprogesterone and androstenedione to testosterone. However, the Δ^5 pathway from 17-hydroxypregnenolone and DHA via Δ^5 -androstenediol to testosterone now seems of major importance in man (34). Several steroids have been found to be secreted directly by the testes. In males approximately 40% of 17 α -hydroxypregnenolone secretion is of testicular origin (35), and DHA, though mainly secreted by the adrenal, has also been found in the spermatic vein effluent of man (36). Δ^5 -androstene-

diol is the second most abundant steroid in spermatic vein plasma; the ratio of testosterone to DHA is 37:1, compared to 4:1 for testosterone to Δ^5 -androstenediol (36). This latter ratio corresponds to that found in the peripheral plasma by Rosenfield and Otto (8) and confirmed by recent studies from two separate laboratories (37, 38). After HCG stimulation of similar dosage and duration as performed in our patient, this ratio was either maintained (37) or somewhat increased (38). Furthermore, the ratio was maintained in a variety of testicular disorders before and after HCG stimulation (38). Our own studies demonstrate a similar secretory pattern after HCG administration to children but also suggest even less Δ^5 androgen response with a resultant testosterone: Δ^5 -androstenediol ratio of 10:1 (39).

The *in vivo* data in our patient provide evidence that the testicular Δ^5 -3 β -HSD enzyme complex is also deficient. Although plasma testosterone is low normal, Δ^5 -androstenediol is elevated, and the plasma testosterone: Δ^5 -androstenediol ratio was 0.88 compared to a normal ratio of at least 4:1. After HCG, Δ^5 -androstenediol rises more than testosterone, so that the resultant testosterone: Δ^5 -androstenediol ratio is further reduced to 0.67. The increases in these steroids after HCG may be artificially low, since the base-line values were obtained after only 2 days of high-dose dexamethasone suppression. In view of the lower values later observed after 9 days of dexamethasone administration, the HCG stimulation very likely was begun at a time of incomplete adrenal suppression. Subsequent HCG testing after prolonged dexamethasone administration has supported this conclusion (39). These data are consistent with a partial block in testosterone synthesis and indicate that Δ^5 -androstenediol is a major secretory product of the testes in this patient. Since only 1–2% of Δ^5 -androstenediol is normally converted peripherally to testosterone (40), the majority of this patient's testosterone is most likely secreted by the testes, consistent with a partial rather than complete testicular Δ^5 -3 β -HSD block.

Deficiency of the testicular enzyme complex is further suggested by the absence of Δ^5 -3 β -HSD activity histochemically and by the *in vitro* studies. However, our data must be interpreted cautiously because of the lack of extensive control testes. With either pregnenolone or DHA as a substrate, the control testis consistently formed 3–10 more Δ^4 products than that of our patient. These differences may even be minimized, since the control testis was from a patient treated with estrogens, shown by both *in vivo* and *in vitro* studies to suppress Δ^5 -3 β -HSD enzyme activity (41–43). In addition, the micro method demonstrated that Δ^5 -androstenediol is the major product in the patient's testicular incuba-

tions. The ratio of Δ^5 -androstenediol:testosterone produced by incubation of our patient's testis with DHA was 32:1, whereas almost equal amounts of these two steroids are reported to be produced from DHA after incubation of normal human testes (34). Thus, *in vivo* and *in vitro* data in our patient are consistent with data obtained from rats in which Δ^5 -3 β -HSD activity has been experimentally inhibited by injecting the pregnant mother with a C_{19} substrate analog, cyanoketone (2 α -cyano-4,4-17 α -trimethyl-5-androstene-17 β -ol-3-one) on either the 16th or the 19th day of gestation (44). In this experimental situation, Δ^5 -androstenediol is the major product formed *in vitro* by the cyanoketone-inhibited testes (45) and is the major androgen in the circulation of the newborn males (46).

For the most part, plasma estrogens were normal and estradiol levels were increased by exogenous gonadotropins. These studies do not indicate, however, if estrogens are secreted directly by either the testes or the adrenals or are derived from peripheral metabolism of androgens. The intact nature of the pituitary-gonadal axis was further confirmed by the finding of normal levels of gonadotropins, except for the rise associated with the decline of plasma androgens and estrogens after 9 days of high-dose dexamethasone suppression. These findings indicate that this patient's gonadotropins were responsive to negative feedback by circulating sex steroids.

Including our patient, the oldest pubertal boys thus far described have developed gynecomastia (3, 4). This breast development could represent that seen in otherwise normal male adolescents, in whom steroid studies have not demonstrated a characteristic pattern (47). Alternatively, the gynecomastia may reflect fetal testosterone insufficiency, with failure of inhibition of the female breast anlage (3). Animal experiments where either androgen antagonist (cyproterone acetate) or a 3 β -HSD inhibitor was administered to fetal male rats support the latter concept, since these rats also developed breast hypertrophy (48, 49), which can be prevented by simultaneous testosterone treatment (49). Alternatively, Δ^5 -androstenediol itself, in view of its feminizing effect on vaginal mucosa (50), might promote breast development.

The testicular biopsy revealed spermatogenic arrest with primarily areas of diminished Leydig cells but with occasional focal Leydig cell hyperplasia. Although this may be considered appropriate for the patient's stage of puberty, the studies of Goldman (51) suggest it may be abnormal. In these latter studies of the cyanoketone-inhibited rat, persistent Δ^5 -3 β -HSD deficiency is produced in the progeny when the mother is injected with this C_{19} substrate analog on the 16th–19th day of gestation. If the mothers are treated on the 16th day,

testes of the male offspring fail to undergo enlargement at puberty, and the testes have a complete arrest of tubular development, with hypoplastic Leydig cells. When the mother is treated on the 19th day, the offspring's testes have tubular atrophy and hyperplastic Leydig cells. In both situations, enzyme activity in the testis is reduced, and hypospadias is present. The hypospadias can be partially prevented with *in utero* testosterone treatment, implying that testosterone deficiency is responsible for this defect (44). The histological features and absent histochemical Δ^5 -3 β -HSD activity seen in the testis of our patient represent changes similar to those found by Goldman in cyanoketone-treated male offspring rats and suggest that normal *in utero* testosterone production is necessary for normal testicular maturation and spermatogenesis.

The nodules noted in the testis and spermatic cord in this patient proved to represent Leydig cell hyperplasia. There is controversy in the literature as to whether these tumors in congenital adrenal hyperplasia are of adrenal or of testicular origin (52-56). However, prolonged ACTH stimulation appears to lead to the development of these tumors (57), and whatever the cell of origin, they have the capacity to make cortisol or other steroid precursors (55-57). Although testicular nodule tissue from our patient was not incubated, these nodules appear stimulated by ACTH, as evidenced by a decrease in size, at least in the right testis, with increased glucocorticoid therapy.

The pattern of simultaneous adrenal and testicular enzyme deficiency in this pubertal patient is similar to that of a neonate (2) but may differ from that of the pubertal boy studied by Parks, Bermudez, Anast, Bongiovanni, and New (3). Their patient had a normal testosterone level that rose ninefold after HCG, a brisk response suggesting that testosterone synthesis was intact at puberty. Parks et al. postulated that the enzyme complex was probably absent *in utero*, but activity developed with age and thus was present at puberty. However, as discussed earlier, Δ^5 -androstenediol is the major Δ^5 -C₁₉ androgen secreted by the testes, and was not measured in this pubertal male. Recently, opposite conclusions were reached from studies in another pubertal male (4), in whom a subnormal testosterone response to HCG and elevated spermatic and peripheral venous concentrations of Δ^5 -pregnenolone were demonstrated. The elevation of Δ^5 -androstenediol observed in our patient, as well as its disproportionate rise relative to testosterone after HCG stimulation, provides substantive evidence for a functional impairment in testosterone secretion. If the enzymatic defect in these three reported pubertal males is similar, testicular function clearly is less compromised than that of the adrenal glands. It is conceivable that the enzyme

complex may have a lower affinity for C₂₁ than C₁₉ steroids to account for the seeming differences in enzyme activity in the adrenal versus the testis. Our *in vitro* data are against this explanation. The possible explanation that the adrenal and testicular enzymes are under different genetic control seems unlikely, since adrenal insufficiency and pseudohermaphroditism indicate deficiency of adrenal and fetal testicular Δ^5 -3 β -HSD. Alternately, the enzyme complex may consist of isoenzymes, one subunit of which is mutant and comprises all of the adrenal activity, whereas testicular activity represents portions of normal as well as mutant subunits, as previously postulated (47).

In this patient, as in some others, urinary pregnanetriol, androsterone, and etiocholanolone are elevated (3, 30-32). The increase in these metabolites has been attributed to peripheral conversion of Δ^5 compounds to Δ^4 compounds by hepatic Δ^5 -3 β -HSD activity (3, 27). Bongiovanni, Eberlein, and Moshang (17) administered 17 α -hydroxypregnenolone orally to two normal subjects and found the excretion of more pregnanetriol than Δ^5 -pregnenetriol, suggesting an hepatic or other extra-adrenal site of conversion. Our patient handled oral 17 α -hydroxypregnenolone in a qualitatively similar manner as the two normal volunteers studied by Bongiovanni et al. These data would suggest that hepatic or other peripheral Δ^5 -3 β -HSD activity is intact in this patient and responsible for the increased excretion of Δ^4 steroid metabolites, although it could be argued that the methods used to assess peripheral Δ^5 -3 β -HSD activity might not be sufficiently sensitive to detect small differences in enzymatic activity. However, our data are consistent with conclusions deduced from gas-liquid chromatography and mass spectrometry analysis of bile secretions in one other patient with a Δ^5 -3 β -HSD defect (58). In addition, treatment with cyanoketone does not affect hepatic Δ^5 -3 β -HSD activity despite 90% inhibition of both the testicular and adrenal enzyme complexes (59). These findings, together with our patient's ability to metabolize orally administered 17 α -hydroxypregnenolone, suggests that the liver or other peripheral enzyme systems are either different or under different genetic control from that of the gonad and adrenal.

ACKNOWLEDGMENTS

The authors are grateful for the assistance and cooperation of the nursing and general staff of the Yale Children's Clinical Research Center. We are indebted to Dr. Martin Schiff, Jr., for performing the testicular biopsy, to Dr. Michael Kashgarian for assistance in interpretation of the histologic specimens, to Dr. Judith L. Vaitukaitis for performing the LH and FSH determinations, to Dr. Leon Speroff for determining plasma estrogens, and to Ms. Barbara Bahrs and Ms. Donna Arre for their excellent secretarial assistance in preparation of the manuscript. Dr. Patrick J. Mulrow pro-

vided encouragement and laboratory facilities throughout the course of this study.

Clinical studies were performed at the Yale Children's Clinical Research Center, supported by grant RR-125 from the General Clinical Research Centers Program, Division of Research Resources, National Institutes of Health. This research was supported by Training Grant AM-05015 and Research Grants HD-4683, HD-00371, and HD-06308 from the National Institutes of Health, United States Public Health Service, and by grants from the Rockefeller Foundation and the National Foundation—March of Dimes.

REFERENCES

- Bongiovanni, A. M. 1962. The adrenogenital syndrome with deficiency of 3β -hydroxysteroid dehydrogenase. *J. Clin. Invest.* **41**: 2086–2092.
- Goldman, A. S., A. M. Bongiovanni, W. C. Yakovac, and A. Prader. 1964. Study of Δ^5 - 3β -hydroxysteroid dehydrogenase in normal, hyperplastic, and neoplastic adrenal cortical tissue. *J. Clin. Endocrinol. Metab.* **24**: 894–909.
- Parks, G. A., J. A. Bermudez, C. S. Anast, A. M. Bongiovanni, and M. I. New. 1971. Pubertal boy with the 3β -hydroxysteroid dehydrogenase defect. *J. Clin. Endocrinol. Metab.* **33**: 269–278.
- Jänne, O., J. Perheentupa, L. Viinikka, and R. Vihko. 1974. Testicular endocrine function in a pubertal boy with 3β -hydroxysteroid dehydrogenase deficiency. *J. Clin. Endocrinol. Metab.* **39**: 206–209.
- Murphy, B. E. P. 1967. Some studies of the protein-binding of steroids and their application to the routine micro and ultramicro measurement of various steroids in body fluids by competitive protein-binding radioassay. *J. Clin. Endocrinol. Metab.* **27**: 973–990.
- Rosenfield, R. L. 1969. A competitive protein binding method for the measurement of plasma androstenedione. *Steroids*. **14**: 251–261.
- Rosenfield, R. L. 1971. A competitive protein binding method for the measurement of unconjugated and sulfate-conjugated dehydroepiandrosterone in peripheral plasma. *Steroids*. **17**: 689–696.
- Rosenfield, R. L., and P. Otto. 1972. Androstenediol levels in human peripheral plasma. *J. Clin. Endocrinol. Metab.* **35**: 818–822.
- Rosenfield, R. L., W. R. Eberlein, and A. M. Bongiovanni. 1969. Measurement of plasma testosterone by means of competitive protein binding analysis. *J. Clin. Endocrinol. Metab.* **29**: 854–859.
- Speroff, L., B. V. Caldwell, W. A. Brock, G. G. Anderson, and J. C. Hobbins. 1972. Hormone levels during prostaglandin $F_{2\alpha}$ infusions for therapeutic abortion. *J. Clin. Endocrinol. Metab.* **34**: 531–536.
- Odell, W. D., G. T. Ross, and P. L. Rayford. 1967. Radioimmunoassay for luteinizing hormone in human plasma or serum: physiological studies. *J. Clin. Invest.* **46**: 248–255.
- Cargille, C. M., G. T. Ross, and T. Yoshimi. 1969. Daily variations in plasma follicle stimulating hormone, luteinizing hormone and progesterone in the normal menstrual cycle. *J. Clin. Endocrinol. Metab.* **29**: 12–19.
- Skinner, S. L. 1967. Improved assay methods for renin "concentration" and "activity" in human plasma. Methods using selective penetration of renin substrate. *Circ. Res.* **20**: 391–402.
- Silber, R. H. 1963. Free and conjugated 17-hydroxycorticosteroids in urine. *Stand. Methods Clin. Chem.* **4**: 113–120.
- Chaney, A. L. 1958. 17-ketosteroids in urine. *Stand. Methods Clin. Chem.* **2**: 79–85.
- Kliman, B., and R. D. Peterson. 1960. Double isotope derivative assay of aldosterone in biological extracts. *J. Biol. Chem.* **235**: 1639–1648.
- Bongiovanni, A. M., W. R. Eberlein, and T. Moshang, Jr. 1971. Urinary excretion of pregnanetriol and Δ^5 -pregnenetriol in two forms of congenital adrenal hyperplasia. *J. Clin. Invest.* **50**: 2751–2754.
- Frank, R. T., and R. C. Berman. 1941. A twenty-four-hour pregnancy test. *Am. J. Obstet. Gynecol.* **42**: 492–496.
- Schneider, G., and C. W. Bardin. 1970. Defective testicular testosterone synthesis by the pseudohermaphrodite rat: an abnormality of 17 β -hydroxysteroid dehydrogenase. *Endocrinology*. **87**: 864–873.
- Greenwood, S. M., J. R. Goodman, G. Schneider, B. H. Forman, S. C. Kress, and A. F. Gelb. 1971. Choriocarcinoma in a man. The relationship of gynecomastia to chorionic somatomammotropin and estrogens. *Am. J. Med.* **51**: 416–422.
- Goldman, A. S. 1973. Rat fetal target organ Δ^5 - 3β -hydroxysteroid dehydrogenase. Effect of cyanoketone and cyproterone acetate. *Endocrinology*. **92**: 1043–1050.
- Goldman, A. S., M. K. Baker, and A. E. Stanek. 1972. Development of Δ^5 - 3β -HSD and glucose-6-phosphate dehydrogenase in testes, adrenals and ovaries of the rabbit fetus. *Proc. Soc. Exp. Biol. Med.* **140**: 1486–1492.
- Blodgett, F. M., R. H. Berki, and W. L. Herrmann. 1961. Hypospadias in a male infant with the adrenogenital syndrome. *J. Clin. Endocrinol. Metab.* **21**: 1087–1091.
- Bongiovanni, A. M., and A. W. Root. 1963. The adrenogenital syndrome. *N. Engl. J. Med.* **268**: 1283–1289, 1342–1351, 1391–1399.
- Guinet, P., M. Petigny, and R. Bethoux. 1949. Les 17-cétosteroides neutres. Valeur semeiologique de leur dosage dans les urines. *J. Med. Lyon.* **30**: 347–357.
- Neukomm, S., and A. Reymond. 1950. Excrétion des 17-cétostéroïdes chez l'homme normal. *Experientia (Basel)*. **6**: 62–63.
- Bongiovanni, A. M. 1972. Disorders of adrenogenital steroid biogenesis (the adrenogenital syndrome associated with congenital adrenal hyperplasia). In *The Metabolic Basis of Inherited Disease*. J. B. Stanbury, J. B. Wyngaarden, and D. S. Fredrickson, editors. McGraw-Hill Book Company, New York. 857–885.
- Hamilton, W., and M. G. Brush. 1964. Four clinical variants of congenital adrenal hyperplasia. *Arch. Dis. Child.* **39**: 66–72.
- Rivarola, M. A., J. M. Saez, and C. J. Migeon. 1967. Studies of androgens in patients with congenital adrenal hyperplasia. *J. Clin. Endocrinol. Metab.* **27**: 624–630.
- Zachmann, M., J. A. Völlmin, G. Mürset, H.-Ch. Curtius, and A. Prader. 1970. Unusual type of congenital adrenal hyperplasia probably due to a deficiency of 3β -hydroxysteroid dehydrogenase. Case report of a surviving girl and steroid studies. *J. Clin. Endocrinol. Metab.* **30**: 719–726.
- Jänne, O., J. Perheentupa, and R. Vihko. 1970. Plasma and urinary steroids in an eight-year-old boy with 3β -hydroxysteroid dehydrogenase deficiency. *J. Clin. Endocrinol. Metab.* **31**: 162–165.

32. Kenny, F. M., J. W. Reynolds, and O. C. Green. 1971. Partial 3β -hydroxysteroid dehydrogenase (3β -HSD) deficiency in a family with congenital adrenal hyperplasia: evidence for increasing 3β -HSD activity with age. *Pediatrics*. **48**: 756-765.
33. Rosenfield, R. L., B. J. Grossman, and N. Ozoa. 1971. Plasma 17-ketosteroids and testosterone in prepubertal children before and after ACTH administration. *J. Clin. Endocrinol. Metab.* **33**: 249-253.
34. Yanaihara, T., and P. Troen. 1972. Studies of the human testis. II. A study of androstenediol and its monosulfate in human testes *in vitro*. *J. Clin. Endocrinol. Metab.* **34**: 793-800.
35. Strott, C. A., J. A. Bermudez, and M. B. Lipsett. 1970. Blood levels and production rate of 17-hydroxypregnenolone in man. *J. Clin. Invest.* **49**: 1999-2007.
36. Laatikainen, T., E. A. Laitinen, and R. Vihko. 1971. Secretion of free and sulfate-conjugated neutral steroids by the human testis. Effect of administration of human chorionic gonadotropin. *J. Clin. Endocrinol. Metab.* **32**: 59-64.
37. Demish, K., W. Magnet, M. Neubauer, and K. Schöfling. 1973. Studies about unconjugated androstenediol in human peripheral plasma. *J. Clin. Endocrinol. Metab.* **37**: 129-134.
38. Ruder, H. J., D. L. Loriaux, R. J. Sherins, and M. B. Lipsett. 1974. Leydig cell function in men with disorders of spermatogenesis. *J. Clin. Endocrinol. Metab.* **38**: 244-247.
39. Rosenfield, R. L., A. A. Barmach de Niepomniszcze, F. M. Kenny, and M. Genel. 1974. The response to gonadotropin (HCG) administration in boys with and without Δ^5 - 3β -hydroxysteroid dehydrogenase deficiency. *J. Clin. Endocrinol. Metab.* **39**: 370-374.
40. Kirschner, M. A., S. Sinhamahapatra, I. R. Zucker, L. Loriaux, and E. Nieschlag. 1973. The production, origin and role of dehydroepiandrosterone and Δ^5 -androstenediol as androgen prehormones in hirsute women. *J. Clin. Endocrinol. Metab.* **37**: 183-189.
41. Bongiovanni, A. M., W. R. Eberlein, A. S. Goldman, and M. New. 1967. Disorders of adrenal steroid biogenesis. *Recent Prog. Horm. Res.* **23**: 375-449.
42. Sobrinho, L. G., N. G. Kase, and J. A. Grunt. 1971. Changes in adrenocortical function of patients with gonadal dysgenesis after treatment with estrogen. *J. Clin. Endocrinol. Metab.* **33**: 110-114.
43. Yanaihara, T., and P. Troen. 1972. Studies of the human testis. III. Effect of estrogen on testosterone formation in human testis *in vitro*. *J. Clin. Endocrinol. Metab.* **34**: 968-973.
44. Goldman, A. S., A. M. Bongiovanni, and W. C. Yakovac. 1966. Production of congenital adrenal hyperplasia, hypospadias and clitoral hypertrophy (adrenogenital syndrome) in rats by inactivation of 3β -hydroxysteroid dehydrogenase. *Proc. Soc. Exp. Biol. Med.* **121**: 757-766.
45. Block, E., M. Lew, and M. Klein. 1971. Studies on the inhibition of fetal androgen formation. Inhibition of testosterone synthesis in rat and rabbit fetal testes with observations on reproductive tract development. *Endocrinology*. **89**: 16-31.
46. Goldman, A. S. 1972. Inhibition of 3β -hydroxy- Δ^5 -steroid dehydrogenase. *Gynecol. Invest.* **2**: 213-238.
47. Rosenfield, R. L. 1971. Role of androgens in growth and development of the fetus, child and adolescent. *Adv. Pediatr.* **19**: 171-213.
48. Neumann, F., and W. Elger. 1966. The effect of the anti-androgen 1,2 α -methylene-6-chloro- Δ^4 , Δ^6 -pregnadiene-17 α -O1-3,20-dione-17 α -acetate (cyproterone acetate) on the development of the mammary glands of male foetal rats. *J. Endocrinol.* **36**: 347-352.
49. Neumann, F., and A. S. Goldman. 1970. Prevention of mammary gland defects in experimental congenital adrenal hyperplasia due to inhibition of 3β -hydroxysteroid dehydrogenase in rats. *Endocrinology*. **86**: 1169-1171.
50. Shao, T.-C., E. Castaneda, R. L. Rosenfield, and S. Liao. 1975. Selective retention and formation of a 3β , 17 β -dihydroxy-androst-5-ene-protein complex in cell nuclei of the rat vagina. *J. Biol. Chem.* In press.
51. Goldman, A. S. 1967. Experimental congenital adrenocortical hyperplasia: persistent postnatal deficiency in activity of 3β -hydroxysteroid dehydrogenase produced *in utero*. *J. Clin. Endocrinol. Metab.* **27**: 1041-1049.
52. Dahl, E. V., and R. C. Bahn. 1962. Aberrant adrenal cortical tissue near the testis in human infants. *Am. J. Pathol.* **40**: 587-598.
53. Nelson, A. A. 1939. Accessory adrenal cortical tissue. *Arch. Pathol.* **27**: 955-965.
54. Shanklin, D. R., A. P. Richardson, Jr., and G. Rothstein. 1963. Testicular hilar nodules in adrenogenital syndrome. *Am. J. Dis. Child.* **106**: 243-250.
55. Savard, K., R. I. Dorfman, B. Baggett, L. L. Fielding, L. L. Engel, H. T. McPherson, L. M. Lister, D. S. Johnson, E. C. Hamblen, and F. L. Engel. 1960. Clinical, morphological and biochemical studies of a virilizing tumor in the testis. *J. Clin. Invest.* **39**: 534-553.
56. Fisher, J. N., D. B. Vilee, and H. Jockin. 1971. Testicular tumors in congenital adrenal hyperplasia (CAH). *Clin. Res.* **19**: 372. (Abstr.)
57. Fore, W. W., T. Bledsoe, D. M. Weber, R. Akers, and R. T. Brooks, Jr. 1972. Cortisol production by testicular tumors in adrenogenital syndrome. *Arch. Intern. Med.* **130**: 59-63.
58. Laatikainen, T., J. Perheentupa, R. Vihko, I. Makino, and J. Sjövall. 1972. Bile acids and hormonal steroids in bile of a boy with 3β -hydroxysteroid dehydrogenase deficiency. *J. Steroid. Biochem.* **3**: 715-719.
59. Björkhem, I., J.-Å. Gustafsson, and S. A. Gustafsson. 1970. Metabolism of steroids in germfree and conventional rats treated with a 3β -hydroxy- Δ^5 -oxidoreductase inhibitor. *Eur. J. Biochem.* **16**: 557-566.