

Reduction of Experimental Myocardial Infarct Size by Corticosteroid Administration

Peter Libby, ... , Burton E. Sobel, Eugene Braunwald

J Clin Invest. 1973;52(3):599-607. <https://doi.org/10.1172/JCI107221>.

Research Article

The influence of the administration of pharmacologic doses of hydrocortisone on the extent and severity of acute myocardial ischemic injury and on subsequent necrosis after acute coronary occlusion was investigated in 28 dogs. In order to study acute myocardial injury, repeated epicardial electrocardiograms were recorded from 10 to 15 sites on the anterior surface of the left ventricle. Average ST segment elevation (ST) and the number of sites in which ST segment elevation exceeded 2 mV (NST), indices of the magnitude and extent of myocardial injury, respectively, were analyzed at 30 and 60 min after coronary occlusion. In the control group ST and NST did not change significantly in this time interval while in the treated group, which received 50 mg/kg hydrocortisone just after the 30 min recording, ST fell from 3.5 ± 0.8 to 1.1 ± 0.4 mV ($P < 0.01$) and NST was reduced from 6.7 ± 1.1 to 1.4 ± 0.8 ($P < 0.01$). In order to study the influence of hydrocortisone on necrosis, epicardial ST segment elevation 15 min after coronary occlusion was compared to myocardial creatine phosphokinase activity (CPK) and histologic appearance 24 h later in each site. In a control group (14 dogs) a relationship was established between ST segment elevation at 15 min (in millivolts) and CPK activity (in international units per milligram of protein) 24 h later: $\log \text{CPK} = -0.0611\text{ST} + 1.26$ (N [...])

Find the latest version:

<https://jci.me/107221/pdf>



Reduction of Experimental Myocardial Infarct Size by Corticosteroid Administration

PETER LIBBY, PETER R. MAROKO, COLIN M. BLOOR, BURTON E. SOBEL, and EUGENE BRAUNWALD

From the Departments of Medicine and Pathology, University of California, San Diego, School of Medicine La Jolla, California, 92037 and the Departments of Medicine, Harvard Medical School and Peter Bent Brigham Hospital, Boston, Massachusetts 02115

ABSTRACT The influence of the administration of pharmacologic doses of hydrocortisone on the extent and severity of acute myocardial ischemic injury and on subsequent necrosis after acute coronary occlusion was investigated in 28 dogs. In order to study acute myocardial injury, repeated epicardial electrocardiograms were recorded from 10 to 15 sites on the anterior surface of the left ventricle. Average ST segment elevation (\overline{ST}) and the number of sites in which ST segment elevation exceeded 2 mV (NST), indices of the magnitude and extent of myocardial injury, respectively, were analyzed at 30 and 60 min after coronary occlusion. In the control group \overline{ST} and NST did not change significantly in this time interval while in the treated group, which received 50 mg/kg hydrocortisone just after the 30 min recording, \overline{ST} fell from 3.5 ± 0.8 to 1.1 ± 0.4 mV ($P < 0.01$) and NST was reduced from 6.7 ± 1.1 to 1.4 ± 0.8 ($P < 0.01$). In order to study the influence of hydrocortisone on necrosis, epicardial ST segment elevation 15 min after coronary occlusion was compared to myocardial creatine phosphokinase activity (CPK) and histologic appearance 24 h later in each site. In a control group (14 dogs) a relationship was established between ST segment elevation at 15 min (in millivolts) and CPK activity (in international units per milligram of protein) 24 h later: $\log \text{CPK} = -0.0611\overline{ST} + 1.26$ ($N = 102$ specimens, $r = -0.79$). In the treated groups, hydrocortisone (50 mg/kg i.v.) was given either at 30 min after occlusion (seven dogs) or at 6 h after occlusion (six dogs). Both groups received supplementary doses of hydrocortisone (25 mg/kg) 12 h after occlusion. The two treated groups exhibited less CPK depression than that expected

from ST segment elevation at each site, with slopes of the regression lines which were significantly less steep: $\log \text{CPK} = -0.0288\overline{ST} + 1.26$ ($N = 48$, $r = -0.71$) and $\log \text{CPK} = -0.0321\overline{ST} + 1.31$ ($N = 48$, $r = -0.76$) in the $\frac{1}{2}$ h and 6 h groups, respectively. Histologically, sites with ST segment elevations of less than 2 mV at 15 min after occlusion exhibited normal appearance 24 h later. Sites with ST segment elevations (> 2 mV) in the control group showed histologic changes compatible with early myocardial infarction in 96% of specimens, while this occurred only in 61% and 63% of specimens, respectively, in the treated groups, showing that over one third of the sites were protected from undergoing necrosis due to the intervening hydrocortisone treatment. Thus pharmacological doses of hydrocortisone prevent myocardial cells from progressing to ischemic necrosis even when administration is initiated 6 h after coronary occlusion.

INTRODUCTION

Recent investigations in our laboratory have begun to delineate factors determining the extent and severity of myocardial ischemic injury and subsequent necrosis after acute coronary occlusion. The possibility of modification of infarct size has been demonstrated both in experimental animals and in patients, and it has been observed that interventions which either decrease myocardial requirements or increase oxygen supply reduce the extent and severity of myocardial ischemic injury and subsequent necrosis, while those which augment oxygen demands or decrease oxygen supply increase myocardial damage (1-3). In addition, it has been demonstrated that interventions which may exert metabolic effects, such as glucose-insulin-potassium, act to protect ischemic myocardium from necrosis (4). The possibility that

A preliminary report of this investigation appeared in *Clin. Res.* 1972, 20: 207.

Received for publication 22 June 1972 and in revised form 30 October 1972.

corticosteroid administration may have a beneficial effect on infarct size has been investigated by a number of workers, but the results have been conflicting (5-7). Since the newly developed methods for assessing myocardial ischemic injury are more sensitive and reliable than those previously available, we have undertaken to evaluate the effects of pharmacologic doses of corticosteroids on experimental infarcts.

METHODS

The study was divided into two parts: (a) the examination of the effects of hydrocortisone administered during the 1st h after occlusion on the electrocardiographic signs of ischemic injury, and (b) their effects on enzymatic and histologic signs of necrosis and infarction 24 h later in animals receiving the steroid $\frac{1}{2}$ and 6 h after coronary occlusion. The basic techniques utilized in this investigation have been described in detail (1-4).

The studies were carried out in 28 mongrel dogs of both sexes weighing from 18 to 27 kg, anesthetized with sodium thiamylal (25 mg/kg) with respiration maintained mechanically through a cuffed endotracheal tube. Aortic pressure was monitored through a catheter inserted through the left common carotid artery using a Statham P23Db strain gauge (Statham Instruments, Inc., Oxnard, Calif.). The left jugular vein was catheterized and used as a route of administration of fluids and drugs. The thorax was entered through the fifth left intercostal space and the heart suspended in a pericardial cradle, so that the anterior aspect of the left ventricle was well exposed. The left anterior descending coronary artery or its apical branch was dissected free so that it could be occluded when desired. 10-14 sites on the anterior surface of the left ventricle were selected arbitrarily at the outset of each experiment for recording of unipolar epicardial electrocardiograms so that some were clearly within the area supplied by the artery to be occluded and others were located in regions whose perfusion would not be affected by the coronary ligation and thus could serve as internal controls. The epicardial electrocardiograms were recorded in anatomically recognizable sites, such as branching of arteries or intersection of arteries and veins. The technical details were described previously (1).

The extent and severity of acute myocardial ischemic injury was determined by analysis of the ST segments in epicardial electrocardiographic maps obtained from these sites before and at intervals after occlusion. The number of sites with abnormal ST segments (elevations of more than 2 mV) was taken as an index of the extent of ischemic injury (NST)¹ and the average of the sum of ST segment elevation at all sites (\overline{ST}) was used as an index of the severity of ischemic injury. Sites which had ST segment depression were considered as having zero ST segment elevation since in this model, creatine phosphokinase activity (CPK) and histology of these sites has been found to be normal 24 h after occlusion. The animals were divided into two groups, a control group (14 dogs) and a treated group (14 dogs). In seven dogs from the control group and in seven treated dogs the effect of corticosteroid

¹Abbreviations used in this paper: CPK, creatine phosphokinase activity; NST, number of sites in which ST segment elevation exceeded 2 mV; \overline{ST} , average ST segment elevation.

administration on acute ischemic injury was determined by recording epicardial electrocardiographic maps just before, and 15, 30, and 60 min after coronary artery ligation. The dogs in the treated group received hydrocortisone hemisuccinate (50 mg/kg) intravenously as a bolus just after the 30 min postocclusion map. The effect of this treatment was evaluated by comparing the changes in average NST and \overline{ST} in the control and treatment groups at 30 and 60 min after occlusion.

The effect of corticosteroid administration on the development of myocardial infarcts after coronary occlusion was studied by measurement of myocardial CPK and by histologic examination of tissue obtained post mortem 24 h after occlusion in all 14 control dogs and 13 of the treated group. After the final electrocardiographic map, the chest was closed anatomically and drained by a chest tube to constant underwater suction. The animals were then allowed to recover but were maintained under sedation with small additional doses of sodium thiamylal. All animals received 40 cc/kg per 24 h of normal saline by intravenous drip. Aortic pressure and lead aVF of the electrocardiogram were constantly monitored using a Brush oscillographic recorder (Brush Instruments, Div. Clevite Corp., Cleveland, Ohio). The 13 treated animals were divided into two subgroups: seven dogs received 50 mg/kg hydrocortisone 30 min after occlusion and the other six dogs received the same dose 6 h after coronary occlusion. An additional dose of hydrocortisone (25 mg/kg) was administered intravenously to both groups 12 h after occlusion.

24 h after occlusion all animals were reanesthetized with sodium thiamylal, reintubated, and again placed on the respirator. The chest was reopened, the heart excised and transmural specimens for CPK analysis were rapidly obtained from the same sites at which epicardial electrocardiograms had been recorded 24 h previously. The biopsies were taken with a stainless steel cannula and the specimens obtained were roughly of the same diameter as the cotton wick electrode (7 mm) and weighed approximately 0.5 g. They were placed in iced homogenizing medium and prepared for assay of CPK activity as previously described (1). This biochemical determination was carried out by a technician unaware of the origin of the specimen. Transmural tissue samples, for histological and histochemical analysis, from sites immediately adjacent to the site of biopsy for CPK were taken with a scalpel, fixed in absolute ethanol, and stained with hematoxylin-eosin and Best's carmine stain.

The effects of interventions on the development of signs of myocardial infarction were analyzed exactly as described previously (1, 3, 4). The relationships between ST segment elevation 15 min after occlusion (i.e., before any treatment), and myocardial CPK activity and histologic appearance of the specimens obtained 24 h later from the same sites in the control group was compared to those observed in the treated group. Myocardial CPK specific activity was determined in the 31,000 g supernatant fraction of the tissue homogenate at 30°C by the back reaction technique of Rosalki (8). Protein was determined by the Biuret reaction and activity was expressed in international units (micro-moles substrate converted per minute) per milligram protein. The results of duplicate determination of CPK agreed within 3% (1).

Histopathologic examination was carried out by a pathologist who was unaware of the origin of the coded sections. The hematoxylin-eosin-stained sections were graded for the presence or absence of early signs of ischemic necrosis such as more intense eosinophilic staining, nuclear changes, loss

of cross-striations, and inflammatory cell infiltration. Results were analyzed by comparing epicardial ST segment elevation at each site 15 min after occlusion (i.e., before any drug administration) with the histologic appearance of the tissue obtained from the same epicardial site 24 h later.

The possibility that hydrocortisone could affect CPK activity or the synthesis of CPK was investigated by incubating dog heart CPK purified according to Noda, Kuby, and Lardy (9) and slices of dog heart with 1 mg/ml of hydrocortisone at 37°C for 8 h in duplicate experiments. Any influence of hydrocortisone on the CPK assay was examined by including it at an appropriate concentration in the assay mixture of a CPK standard (Worthington Biochemical Corp., Freehold, N. J.). There was no alteration in CPK activity due to hydrocortisone addition in any of the above experiments.

RESULTS

Effect of hydrocortisone on acute myocardial ischemic injury. In the six animals in the control group in which ST segment maps were obtained 30 and 60 min after occlusion there was no significant spontaneous decrease in the indices of the extent and severity of acute myocardial ischemic injury. In this group, \overline{ST} was 3.0 ± 1.2 mV (SEM) at 30 min and 2.9 ± 1.4 mV at 1 h after occlusion (NS), while NST changed from 5.0 ± 1.5 to 4.2 ± 1.5 sites (NS). In contrast, in the group which received hydrocortisone (50 mg/kg i.v.) just after the 30 min map, a substantial decrease in both the extent and severity of myocardial ischemic injury was observed; \overline{ST} decreased from 3.5 ± 0.8 at 30 min to 1.1 ± 0.4 mV at 60 min ($P < 0.01$), while NST fell from 6.7 ± 1.1 to 1.4 ± 0.8 ($P < 0.01$) (Fig. 1). Thus, the administration of hydrocortisone 30 min after coronary artery occlusion decreases electrocardiographic signs of acute ischemic injury to the myocardium. The effects could not be compared 24 h postocclusion due to the presence of pericarditis and of multifocal ventricular tachyarrhythmias which occurred in some dogs at this time.

Effect of hydrocortisone on myocardial CPK activity. The relationship between epicardial ST segment elevation 15 min after coronary occlusion and myocardial CPK activity in the same sites 24 h later was determined in dogs from the control group. Sites outside the ischemic area always had normal ST segments (ST elevation ≤ 2 mV) and showed normal CPK activity 24 h later (18.8 ± 4.1 IU/mg prot. [average \pm SD]); while sites within the ischemic area (i.e., sites exhibiting ST segment elevation > 2 mV) always had decreased CPK activity (Fig. 2). In 102 specimens from the 14 control dogs, CPK activity 24 h after occlusion was found to be exponentially and inversely related to the degree of ST segment elevation recorded 15 min after occlusion from the same site. The regression equation of the line representing this relationship is $\log \text{CPK (in IU/mg prot.)} = -0.0611\overline{ST}$ (in millivolts) + 1.26 ($r = -0.79$, Fig. 3).

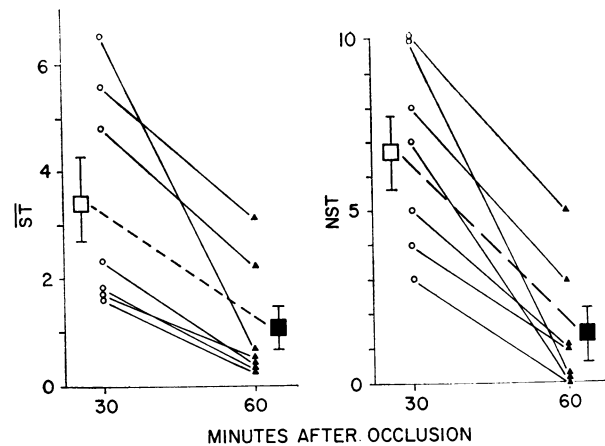
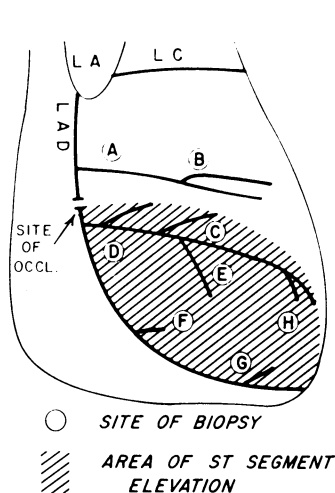


FIGURE 1 The effects of hydrocortisone on average ST segment elevation (\overline{ST} , left panel) and on the number of sites with abnormally elevated ST segments (NST, right panel). Every line represents one animal. Open symbols are the \overline{ST} and NST value 30 min after occlusion (just before hydrocortisone administration), solid symbols are the values 30 min later, i.e., 60 min after occlusion. Mean and standard errors are denoted by the squares connected by dotted lines.

In the group treated with hydrocortisone, sites with normal ST segments at 15 min also showed normal CPK activity 24 h later. Sites which exhibited ST segment elevations 15 min after occlusion showed less CPK depression than expected and several exhibited CPK values within the normal range. Fig. 4 is an example from a dog which received hydrocortisone 6 h postocclusion in which CPK activity was much less depressed than that expected from the height of the ST segment at 15 min. The slope of the regression line was significantly lower in the two treated groups than in the control group. In the animals which received hydrocortisone 30 min after occlusion, the regression equation was $\log \text{CPK} = -0.0288\overline{ST} + 1.26$ ($r = -0.71$, Fig. 3). This indicates that for any given level of ST segment elevation there was less CPK depletion than predicted from the control group. In the 6 dogs (48 biopsies) in which treatment started 6 h after occlusion there was also less CPK depression than that expected from epicardial ST segment elevation 15 min after occlusion: $\log \text{CPK} = -0.0321\overline{ST} + 1.31$ ($r = -0.76$, Fig. 3). Thus, hydrocortisone treatment exerts a protective effect on the myocardium even when started 6 h after occlusion, as estimated by the decreased degree of CPK depression.

Effect of hydrocortisone on histologic appearance. In the control group, 27 out of 28, i.e., 96% of the sites with normal ST segments (0-2 mV elevation) 15 min after occlusion showed normal histologic appearance 24 h later (Fig. 5, panel 1; Table I). Also 51 of 53, i.e., 96% of the sites from control animals which had abnormal



SITE	ST SEGMENT ELEVATION (mV)	CPK (IU/mg prot)	HISTOLOGY
A	0	20.7	NORMAL
B	0	20.8	NORMAL
C	7	6.5	ABNORMAL
D	8	6.3	ABNORMAL
E	6	8.5	ABNORMAL
F	7	6.8	ABNORMAL
G	5	8.8	ABNORMAL
H	5	8.4	ABNORMAL

FIGURE 2 Relationship between ST segment elevation 15 min after occlusion and CPK and histology 24 h later in an experiment in the control group. Left panel: a diagrammatic representation of the anterior surface of the heart with its arteries (LA, left atrial appendage; LAD, left anterior descending coronary artery). The shaded area represents the area of ST segment elevation after occlusion. The circles represent sites from which biopsies were taken. Right panel: comparison between ST segment elevation 15 min after occlusion and CPK and histologic analysis 24 h later in the same sites.

ST segments (> 2 mV elevation) 15 min after occlusion showed pathologic changes consistent with early myocardial ischemic necrosis 24 h later (Fig. 5, panel 2; Table I). In contrast, in the dogs which received hydrocortisone 30 min after occlusion 15 of 41, i.e., 37% of sites with abnormal ST segment elevations exhibited

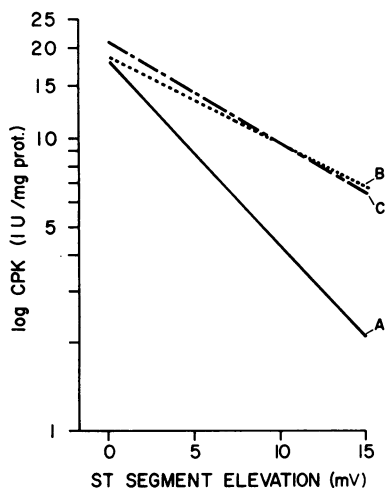


FIGURE 3 Relationship between ST segment elevation 15 min after occlusion and log CPK values from specimens obtained in the same sites 24 h later. Line A: occlusion alone: $\log \text{CPK} = -0.0611\text{ST} + 1.26$ ($r = -0.79$, 14 dogs, 102 biopsies). Line B: hydrocortisone 30 min after occlusion: $\log \text{CPK} = -0.0288\text{ST} + 1.26$, $r = -0.71$, 7 dogs, 56 biopsies). Line C: hydrocortisone 6 h after occlusion: $\log \text{CPK} = -0.0321\text{ST} + 1.31$ ($r = -0.76$, 6 dogs, 48 biopsies).

normal histologic appearance 24 h later (Fig. 5, panel 3; Table I). All 15 out of 15 sites with normal ST segments showed normal histology (Table I). The results of Best's carmine staining for glycogen granules were similar to those of hematoxylin-eosin staining. Whenever a section from a site was classified as pathological, Best's carmine-stained sections from the same site showed depletion of glycogen granules. Sites from the hydrocortisone-treated group which had abnormal electrocardiograms but which had preservation of normal histologic appearance also showed preserved glycogen stores. Thus, in the control group, 96% of sites with normal ST segments (0-2 mV) 15 min after occlusion showed preservation of glycogen granules 24 h later. On the other hand, 96% of sites with abnormal ST segments (> 2 mV) at 15 min after occlusion showed depletion of glycogen granules 24 h later. In the hydrocortisone-treated group 100% of sites with normal ST segment elevation showed preserved glycogen granules and in sites with ST segment elevation 37% of sites showed preserved glycogen granules.

In the dogs which were treated with hydrocortisone 6 h after occlusion, all 15 out of 15 sites with normal ST segments (elevation 0-2 mV) at 15 min, showed normal histology 24 h later (Table I). Sites with abnormal ST segment elevations 15 min after occlusion exhibited normal histology in 14 of 41 instances or 39%. (Fig. 4, Table I).

Other effects of hydrocortisone administration. Hydrocortisone exhibited no observable effects on the de-

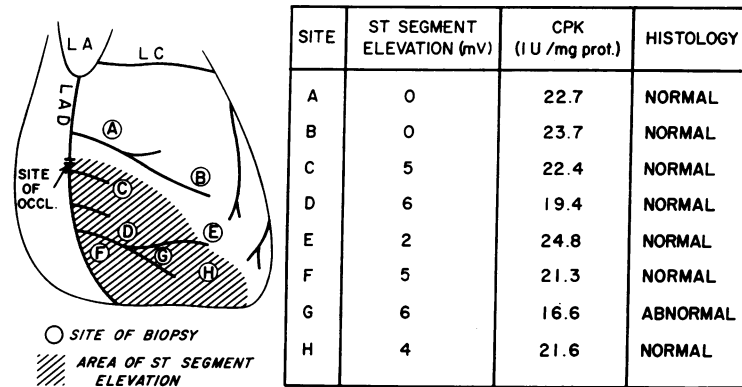


FIGURE 4 Example of an experiment from the group receiving hydrocortisone 6 h after occlusion. Left panel: diagrammatic representation of the heart. The shaded area represents the area of ST segment elevation 15 min after infarction, circles represent the sites where biopsies were taken. Right panel: comparison between ST segment elevation 15 min after coronary occlusion and CPK activity and histologic changes 24 h later. Note sites C-F and H, which had elevated ST segments 15 min after occlusion but which showed normal CPK activity and preserved histology 24 h later.


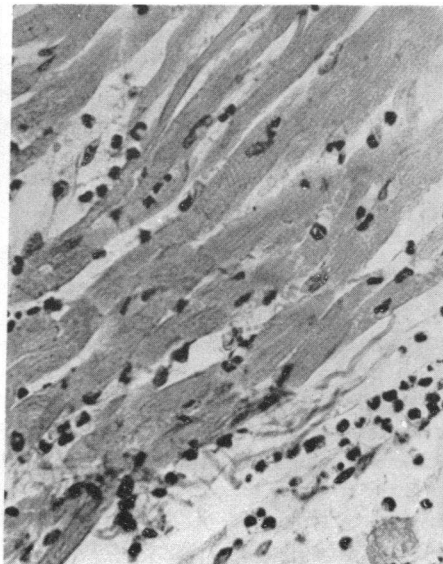



FIGURE 5 Left panel: histology from sites without ST segment elevation. Epicardial electrocardiogram (ECG) 15 min after occlusion and hematoxylin-eosin-stained sections obtained from the same sites 24 h later. Note the normal myocardial structure. Middle panel: histology from a site with ST segment elevation from the control group. Epicardial ECG 15 min after occlusion and hematoxylin-eosin stain from the same sites 24 h later. Note the abnormalities described in the text. Right panel: histology from a site with ST segment elevation of the same magnitude as that in the middle column, in a dog from the group treated with hydrocortisone. Epicardial ECG 15 min after occlusion. Note the preservation of normal myocardial histologic appearance.

TABLE I
Comparison of Electrocardiographic and Histologic Changes

ST segment elevation*	Normal (0-2 mV)			Abnormal (>2 mV)			
	Histology‡	No. specimens/ No. animals	Normal specimens	Abnormal specimens	No. specimens/ No. animals	Normal specimens	Abnormal specimens
			%	%		%	%
1 Control group		28/8	96	4	53/8	3	96
2 Hydrocortisone group		30/14	100	0	82/14	38	62
2a Hydrocortisone at 30 min§		15/7	100	0	41/7	37	63
2b Hydrocortisone at 6 hr¶		15/7	100	0	41/7	39	61

* ST segment elevation 15 min after a simple coronary occlusion, i.e., before hydrocortisone administration.

‡ Histologic findings 24 hr after coronary occlusion.

§ Hydrocortisone treatment started 30 min after coronary occlusion.

|| Hydrocortisone treatment started 6 hr after coronary occlusion.

¶ Significantly greater than group 1 ($P < 0.005$).

velopment of the ventricular tachyarrhythmias commonly seen in dogs after coronary ligation. There was also no statistical difference between the control and hydrocortisone-treated groups in mean arterial pressure at 6, 12, and 24 h after coronary occlusion. After the bolus intravenous injections of hydrocortisone a transient arterial hypotension was observed in all dogs. When 50 mg/kg was injected at 30 min and 6 h after occlusion there was a fall of 45 ± 5 mm Hg from the initial mean arterial pressure of 111 ± 10 mm Hg. The arterial pressure returned to preinjection levels after an average of 170 ± 30 s. When a dose of 25 mg/kg was injected 12 h after occlusion, mean arterial pressure fell 36 ± 5 mm Hg from an average of 116 ± 8 mm Hg, and returned to previous levels after 110 ± 4 s.

DISCUSSION

With the advent of effective intensive coronary care, primary arrhythmias are usually effectively controlled in patients hospitalized with acute myocardial infarction, and cardiac pump failure manifested by cardiogenic shock and/or pulmonary edema has emerged as the leading cause of death (10). Since it is becoming apparent that development of cardiogenic shock depends on the quantity of left ventricular myocardium which is spared infarction (11-13), limitation of the amount of necrosis resulting from a given occlusive event should be a major objective of treatment (1-4). Accordingly, an effort to decrease infarct size after coronary occlusion is potentially of considerable clinical importance and led us to evaluate the possible effects of corticosteroid therapy. The model used in this study was employed only to answer the question of whether hydrocortisone influences infarct size after coronary occlusion and is not suitable for study of the hemodynamic effects of such changes in view of the small hemodynamic alterations

that occlusions at the midportion of the left anterior coronary artery produce in dogs.

The value of these agents in myocardial infarction has been controversial, Johnson, Scheinberg, Gerisch, and Saltzstein (5) showed a reduction in the area of infarcts experimentally produced in dogs treated with cortisone (1-2 mg/kg) intramuscularly each day for 2-3 wk after coronary ligation and noted evidence of increased intercoronary anastomoses. However, Opdyke, Lambert, Stoerk, Zanetti, Kuna (6) and Hepper, Pruitt, Donald, and Edwards (7) were unable to confirm these results. Similarly, several clinical investigations showed reduced mortality in patients with acute myocardial infarction treated with hydrocortisone (14-17), while other studies have not confirmed this observation (18).

The methods which we have developed for studying development of experimental myocardial infarcts are more sensitive and reliable than the measurement of gross infarct size used in previous investigations, which necessitated comparisons of groups of animals. The inherent difficulty of the latter approach has been well recognized by earlier investigators who noted that the size of an infarct does not correlate well with the site of occlusion (6, 19), and that there is considerable variation in the size of infarcts within a control series with a standard point of occlusion. This observation has been borne out by our own experience. Since production of standard experimental infarcts by coronary occlusion is not readily accomplished in the dog, it becomes difficult to demonstrate a statistically significant effect of treatment in this species. The method used in this study obviates this problem because the amount of eventual necrosis is predicted for each site of the myocardium to be sampled. When no treatment intervenes, ST segment elevation 15 min after occlusion reliably predicts myocardial CPK depletion and histologic, histochemical, and ultrastruc-

tural signs of myocardial necrosis observed 24 h later, as shown in previous studies (1, 3, 4) as well as in the control group of dogs employed in this investigation. It is notable that epicardial ST segment elevation 15 min after occlusion also predicts gross anatomic infarct size 1 wk after occlusion (20).

In the dogs which received hydrocortisone, the damage observed biochemically (i.e., myocardial CPK depression) and histologically 24 h after occlusion, was much less than that expected from the initial ST segment map and it is therefore concluded that hydrocortisone protects portions of the ischemic myocardium from undergoing necrosis. The possibility that hydrocortisone might induce an increased synthesis of CPK was explored in experiments in which tissue slices of the myocardium were incubated with and without hydrocortisone; their CPK activities were comparable, providing no evidence for such synthesis. Also, sites with no ST segment elevation showed no differences in CPK activity in the control and the hydrocortisone-treated groups. The possibility that hydrocortisone would prevent the loss of CPK from the cells or its entrance to the blood was also considered. While not excluded, it is unlikely in view of the normal histologic appearance and the conservation of glycogen granules in hydrocortisone-treated animals.

Hydrocortisone is also known to decrease the inflammatory cell infiltration, one of the histologic criteria for determining the presence of infarction, but whenever the histologic appearance was considered normal it was judged also on the presence of muscular cross-striation, the absence of karyolysis or karyorrhexis and the presence of glycogen granules.

Hydrocortisone acts not only when given 30 min after occlusion but also when administered for the first time 6 h after occlusion. This observation has important practical implications. It suggests that therapy might still be effective when started as late as a number of hours after the onset of occlusion, at a time when the patient may already be admitted to a hospital and his condition recognized. This observation is of theoretical importance as well, because it suggests that some myocardial injury is reversible even after 6 h of coronary occlusion. Irreversible damage after coronary occlusion is known to occur in some cells within the first 45 min (21-23) and it has been shown to take place as early as 21 min after occlusion (24). The proportion of reversible and irreversible damage to myocardial cells after several hours of ischemia is difficult to determine, but some investigators believe that after 1-2 h, most of the cells are irreversibly injured (25). However, using the methods currently available it was possible to show that enzymatic and histologic evidence of myocardial damage can be decreased substantially 3 h after occlusion by the simultane-

ous administration of propranolol and glucose-insulin-potassium (4) and by coronary artery reperfusion (3, 20). The present investigation extends this observation to show that an intervention (i.e., hydrocortisone administration) can partially protect the myocardium from ischemic necrosis, even when given as late as 6 h after occlusion. This finding is consistent with the observation that electrocardiographic signs of ischemic injury decrease when propranolol is administered up to 6 h after occlusion (2).

The electrocardiographic observations made during the 1st h of these experiments demonstrate that hydrocortisone treatment decreases the extent and severity of acute ischemic injury after coronary occlusion and they are therefore in agreement with earlier results (26). This decrease in the electrocardiographic signs of injury makes it feasible to monitor the effects of this drug atraumatically in patients by ST segment mapping using multiple unipolar precordial leads (2).

While this study did not attempt to elucidate the mechanism of action of hydrocortisone's protective effect, there are several possible explanations which warrant consideration. Lysosomes occur in myocardial cells (27-31) and it is possible that steroids protect the myocardium by their well-known stabilizing effect on lysosomal membranes (32-34). These organelles, which are disrupted by acidotic conditions in hypoxic cells, release acid hydrolases which may contribute to early irreversibility of cell damage. There is evidence that a significant proportion of myocardial lysosomal hydrolytic activity shifts from particulate to unbound tissue fractions within the first few hours of ischemia (35, 36). If these data are applicable to our experimental model, then the protective effect of hydrocortisone administered 30 min after occlusion could be explained by decreased autolysis. In the group which received the drug 6 h after occlusion, stabilization of the phagocytic vacuoles of infiltrating inflammatory cells might reduce their heterolytic activity through a similar mechanism.

There are isolated reports of other effects of corticosteroids which might also contribute to the protection of myocardium from ischemic damage in acute myocardial infarction. For example, corticosteroids have been reported to decrease oxygen consumption of isolated rat myocardium (37) and to shift the oxyhemoglobin dissociation curve to the right (38). On the other hand, the decrease in myocardial necrosis observed in this study could not be attributed to hydrocortisone's antiarrhythmic properties (39-41), since no reduction in the late tachyarrhythmias which develop in the dog after coronary occlusion were observed in this investigation. Previous experiments showed that all positive inotropic interventions which have been examined in the non-failing heart increased the extent of ischemic injury

and subsequent necrosis after coronary occlusion (1, 2). Therefore, it is extremely unlikely that the positive inotropic effect ascribed to large doses of corticosteroids (42, 43) could provide an explanation for their beneficial action on infarct size observed in these experiments. On the other hand, the beneficial effect of corticosteroids in the treatment of cardiogenic shock (44-46) may be at least partially attributable to a reduction in ischemic injury. The observation that positive inotropic interventions decrease myocardial damage in the failing canine heart (47) suggests that hydrocortisone's positive inotropic effect in cardiogenic shock may contribute to a reduction in myocardial damage.

Corticosteroids have other effects which should be considered when their administration in the context of acute myocardial infarction is considered. The transient hypotension observed in the present experiments may be explained by the known vasodilatory action of steroids (43, 45, 48, 49). However, it is noteworthy that in studies of corticosteroid administration to patients with acute myocardial infarction, no deleterious hemodynamic effects have been reported (15-18). Corticosteroids are also known to alter the healing and granulation of surgically induced wounds (50-52). However, in acute myocardial infarction hydrocortisone (2-10 mg/kg per day) did not affect healing from 2 to 60 days after acute experimental coronary occlusion (7, 53, 54) and although the doses used were less than those employed in the present study, the course of treatment was longer.

The present studies showing the reduction in experimental myocardial necrosis should be extrapolated to patients only with extreme caution for several reasons: (a) the obvious differences between this experimental model and the patient with acute coronary occlusion, (b) the lack of knowledge of the mechanisms of action of hydrocortisone in reducing infarct size in this experimental model, and (c) the lack of information concerning the influence, if any, of hydrocortisone on the healing phase of acute myocardial infarctions. Nevertheless, the reduction in infarct size noted in these experiments does provide leads worthy of further investigation with a view to future clinical trial.

ACKNOWLEDGMENTS

This work was supported in part by U. S. Public Health Service Contracts PH-43-68-1332 and National Institutes of Health-NHLI 722949 and a grant from the John A. Hartford Foundation, Inc.

REFERENCES

1. Maroko, P. R., J. K. Kjekshus, B. E. Sobel, T. Watanabe, J. W. Covell, J. Ross, Jr., and E. Braunwald. 1971. Factors influencing infarct size following experimental coronary artery occlusion. *Circulation*. **43**: 67.
2. Maroko, P. R., P. Libby, J. W. Covell, B. E. Sobel, J. Ross, Jr., and E. Braunwald. 1972. Precordial ST segment elevation mapping: an atraumatic method for assessing alterations in the extent of myocardial ischemic injury. The effects of pharmacologic and hemodynamic interventions. *Am. J. Cardiol.* **29**: 223.
3. Maroko, P. R., P. Libby, W. R. Ginks, C. M. Bloor, W. E. Shell, B. E. Sobel, and J. Ross, Jr. 1972. Coronary artery reperfusion I. Early effects on local myocardial function and the extent of myocardial necrosis. *J. Clin. Invest.* **51**: 2710.
4. Maroko, P. R., P. Libby, B. E. Sobel, C. M. Bloor, H. D. Sybers, W. E. Shell, J. W. Covell, and E. Braunwald. 1972. Effects of glucose-insulin-potassium infusion on myocardial infarction following experimental coronary artery occlusion. *Circulation*. **45**: 1160.
5. Johnson, A. S., S. R. Scheinberg, R. A. Gerisch, and H. C. Saltzstein. 1953. Effect of cortisone on the size of experimentally produced myocardial infarcts. *Circulation*. **7**: 224.
6. Opdyke, D. F., A. Lambert, H. C. Stoerk, M. E. Zanetti, and S. Kuna. 1953. Failure to reduce the size of experimentally produced myocardial infarcts by cortisone treatment. *Circulation*. **8**: 544.
7. Hepper, N. G., R. D. Pruitt, D. E. Donald, and J. E. Edwards. 1955. The effect of cortisone on experimentally produced infarcts. *Circulation*. **11**: 742.
8. Rosalki, S. B. 1967. An improved procedure for serum creatine phosphokinase determination. *J. Lab. Clin. Med.* **69**: 696.
9. Noda, L., S. Kuby, and H. Lardy. 1966. ATP-creatine transphosphorylase. In *Methods in Enzymology*. S. P. Colwick and N. O. Kaplan, editors. Academic Press, Inc. New York. 1st edition. **2**: 605.
10. Friedberg, C. K. 1969. General treatment of acute myocardial infarction. *Circulation*. **40**(Suppl. IV): 252.
11. Harnarayan, C., M. A. Bennet, B. L. Pentecost, and D. B. Brewer. 1970. Quantitative study of infarcted myocardium in cardiogenic shock. *Br. Heart J.* **32**: 728.
12. Page, D. L., J. B. Caulfield, J. A. Kastor, R. W. DeSanctis, and C. A. Sanders. 1971. Myocardial changes associated with cardiogenic shock. *N. Engl. J. Med.* **285**: 133.
13. Bresnahan, G. F., W. E. Shell, B. E. Sobel, and R. D. Yoder. 1972. Myocardial infarct size in man assessed by serial serum creatine phosphokinase (CPK) changes. *Am. J. Cardiol.* **29**: 255. (Abstr.)
14. Breu, W. 1951. Das Nebennierenrindenhormon in der Behandlung des frischen Myokardinfarktes. *Muenchen. Med. Wochenschr.* **93**: 666.
15. Gerisch, R. A., and L. Compeau. 1958. Treatment of acute myocardial infarction in man with cortisone. *Am. J. Cardiol.* **1**: 535.
16. Dall, J. L. C., and A. A. F. Peel. 1963. A trial of hydrocortisone in acute myocardial infarction. *Lancet*. **2**: 1097.
17. Barzilai, D., J. Plavnick, A. Hazani, R. Einath, N. Kleinhaus, and Y. Kanter. 1972. Use of hydrocortisone in the treatment of myocardial infarction. *Chest*. **61**: 488.
18. Scientific Subcommittee of the Scottish Society of Physicians. 1964. Hydrocortisone in severe myocardial infarction. *Lancet*. **2**: 785.
19. Nachlas, M. M., and M. P. Siedband. 1967. The influence of diastolic augmentation on infarct size following coronary artery ligation. *J. Thorac. Cardiovasc. Surg.* **53**: 698.
20. Ginks, W. R., H. D. Sybers, P. R. Maroko, J. W. Covell, B. E. Sobel, and J. Ross, Jr. 1972. Coronary artery reperfusion II Reduction of myocardial infarct size at

- one week after coronary occlusion. *J. Clin. Invest.* **51**: 2717.
21. Savranoglu, N., R. J. Boucek, and G. G. Casten. 1959. The extent of reversibility of myocardial ischemia in dogs. *Am. Heart J.* **58**: 726.
 22. Yabuki, S., G. Blanco, and J. E. Imbriglia. 1969. Time studies of acute, reversible, coronary occlusions in dogs. *J. Thorac. Cardiovasc. Surg.* **38**: 40.
 23. Fischer, S. III, and W. S. Edwards. 1963. Tissue necrosis after temporary coronary artery occlusion. *Am. J. Surg.* **29**: 617.
 24. Jennings, R. B., H. M. Sommers, P. B. Herdson, and J. P. Kaltenbach. 1969. Ischemic injury of myocardium. *Ann. N. Y. Acad. Sci.* **156**: 61.
 25. Jennings, R. B. 1969. Symposium on the prehospital phase of acute myocardial infarction. Part III. Early phase of myocardial ischemic injury and infarction. *Am. J. Cardiol.* **24**: 753.
 26. Ebaid, M., Z. Caramelli, S. Mercurio Neto, M. I. R. Santos, J. Tranchesi, E. Barbato, F. Pileggi, and L. V. Décourt. 1965. The effects of large intravenous doses of hydrocortisone or hyaluronidase on the electrocardiographic pattern of acute myocardial infarction, a comparative clinical and experimental study. *Arch. Inst. Cardiol. Mex.* **35**: 1.
 27. Romeo, D., N. Stagni, G. L. Sottacasa, M. C. Pugliarello, B. De Bernard, and F. Vittur. 1966. Lysosomes in heart tissue. *Biochim. Biophys. Acta.* **130**: 64.
 28. Wheat, M. W. 1965. Ultrastructure autoradiography and lysosome studies in myocardium. *J. Mt. Sinai Hosp.* **32**: 107.
 29. Buchanan, W. E., and T. B. Schwartz. 1967. Lysosomal enzyme activity in heart and skeletal muscle of cortisone-treated rats. *Am. J. Physiol.* **212**: 732.
 30. Leighty, E. G., C. D. Stoner, M. M. Resselat, G. T. Passananti, and H. D. Sirak. 1967. Effects of acute asphyxia and deep hypothermia on the state of binding of lysosomal acid hydrolases in canine cardiac muscle. *Circ. Res.* **21**: 59.
 31. Ravens, K. G., and S. Gudbjarnason. 1969. Changes in the activities of lysosomal enzymes in infarcted canine heart muscle. *Circ. Res.* **24**: 851.
 32. Beaufay, H., E. van Campenhout, and C. de Duve. 1959. Tissue fractionation studies II. Influence of various hepatotoxic treatments on the state of some bound enzymes in rat tissues. *Biochem. J.* **73**: 617.
 33. Weissmann, G., and J. Dingle. 1961. Release of lysosomal protease by ultraviolet irradiation and inhibition by hydrocortisone. *Exp. Cell Res.* **25**: 207.
 34. Weissman, G., and L. Thomas. 1964. The effects of corticosteroids upon connective tissue and lysosomes. *Recent Prog. Hor. Res.* **20**: 215.
 35. Brachfeld, N. O. 1969. Maintenance of cell viability. *Circulation.* **40** (Suppl. IV): 202.
 36. Ricciutti, M., B. Scherlag, E. Stein, and A. Damato. 1968. Lysosome stability and coronary artery occlusion. *Clin. Res.* **16**: 245.
 37. Lacroix, E., and I. Leusen. 1958. The influence of cortisone on the oxygen consumption of myocard and diaphragm slices of the rat. *Arch. Int. Pharmacodyn. Ther.* **114**: 103.
 38. McConn, R., and L. R. M. Del Guericio. 1971. Respiratory function of blood in the acutely ill patient and the effect of steroids. *Ann. Surg.* **174**: 436.
 39. Friedberg, C. K., M. Kahn, J. Scheuer, S. Bleifer, and S. Dack. 1960. Adams-Stokes syndrome associated with chronic heart block. Treatment with Corticosteroids. *J. Am. Med. Assoc.* **172**: 1146.
 40. Dall, J. L. C., and J. Buchanan. 1962. Steroid therapy in heart-block following myocardial infarction. *Lancet.* **2**: 8.
 41. Dall, J. L. C. 1964. The effect of steroid therapy on normal and abnormal atrio-ventricular conduction. *Br. Heart J.* **26**: 537.
 42. Oskovi, M., and D. M. Aviado. 1969. Bronchopulmonary and cardiac effects of hydrocortisone. *Arch. Int. Pharmacodyn. Ther.* **179**: 314.
 43. Carter, J. W., and C. S. Thomas, Jr. 1970. The circulatory response to pharmacological levels of hydrocortisone. *J. Surg. Res.* **10**: 437.
 44. Griffith, G. C., W. B. Wallace, B. Cochran, Jr., W. E. Nerlich, and W. G. Frasher. 1954. The treatment of shock associated with myocardial infarction. *Circulation.* **9**: 527.
 45. Motsay, G. J., A. Alho, T. Jaeger, R. H. Dietzman, and R. C. Lillehei. 1970. Effects of corticosteroids on the circulation in shock: Experimental and clinical results. *Fed. Proc.* **29**: 1861.
 46. Schultz, L. S., R. H. Dietzman, G. J. Motsay, L. Romero, L. Beckman, and R. C. Lillehei. 1972. Clinical cardiogenic shock. Vasopressor vs. Corticoid therapy. *Ann. Intern. Med.* **78**: 867. (Abstr.)
 47. Watanabe, T., J. W. Covell, P. R. Maroko, E. Braunwald, and J. Ross, Jr. 1972. Effects of increased arterial pressure and positive inotropic agents on the severity of myocardial ischemia in the acutely depressed heart. *Am. J. Cardiol.* **30**: 371.
 48. Shambi, M. P., M. H. Weil, and U. N. Udhoji. 1965. Acute pharmacodynamic effects of glucocorticoids. Cardiac output and related hemodynamic changes in normal subjects and patients in shock. *Circulation.* **31**: 523.
 49. Wilson, R. F., and R. R. Fisher. 1968. The hemodynamic effects of massive steroids in clinical shock. *Surg. Gynecol. Obst.* **127**: 769.
 50. Ragen, C., and E. L. Howes. 1949. Effect of cortisone on production of granulation tissue in the rabbit. *Proc. Soc. Exp. Biol. Med.* **72**: 718.
 51. Green, J. P. 1965. Steroid therapy and wound healing in surgical patients. *Br. J. Surg.* **52**: 523.
 52. Hunt, T. K., H. P. Erlich, J. A. Garcia, and J. E. Dunphy. 1969. Effect of vitamin A on reversing the inhibitory effect of cortisone on healing of open wounds in animals and man. *Ann. Surg.* **170**: 633.
 53. Chapman, D. W., R. H. Skaggs, J. R. Thomas, and J. A. Greene. 1951. The effect of cortisone in experimental myocardial infarction. *Am. J. Med. Sci.* **223**: 41.
 54. Hoover, M. P., and G. W. Manning. 1954. The effects of cortisone and ACTH on artificially induced cardiac infarction in the dog. *Am. Heart J.* **47**: 343.