

Movement of the Feline Esophagus Associated with Respiration and Peristalsis. AN EVALUATION USING TANTALUM MARKERS

Wylie J. Dodds, ... , Donald Hodges, F. Frank Zboralske

J Clin Invest. 1973;52(1):1-13. <https://doi.org/10.1172/JCI107152>.

Research Article

The outer, lateral esophageal walls in the distal half of the esophagus in each of five cats were labeled with small tantalum wires. About 8 wk later, esophageal motion associated with respiration and peristalsis, induced by injecting barium boli (5 ml each) into the proximal esophagus, was recorded on cine and serial biplane roentgenograms while recording intraluminal esophageal pressures simultaneously by manometry. Esophageal motion was also evaluated without a manometric tube in place. The coordinates for each marker were digitized and a computer was used to plot marker position against time. During respiration, the markers passively made a shallow, 2-10 mm excursion on the longitudinal esophageal axis. This movement was synchronous with thoracic and diaphragmatic movement and changes in intraluminal esophageal pressure. Immediately after the onset of peristalsis, the markers made a pronounced oral movement of 10 mm or more above their mean respiratory position, as if to engulf the bolus. Markers in opposing esophageal walls approximated one another and commenced an aboral movement as the bolus tail, which was essentially co-incident with onset of the manometric pressure complex, passed the marker sites. The markers returned to their respective rest positions essentially coincident with passage of the pressure complex peak and then moved below their respective rest positions. The aboral excursion occurred predominantly after the bolus had emptied into the [...]

Find the latest version:

<https://jci.me/107152/pdf>



Movement of the Feline Esophagus Associated with Respiration and Peristalsis

AN EVALUATION USING TANTALUM MARKERS

WYLIE J. DODDS, EDWARD T. STEWART, DONALD HODGES, and
F. FRANK ZBORALSKE

From the Department of Radiology, Stanford University School of Medicine, Stanford, California 94305, the Department of Radiology, University of California, San Francisco Medical Center, San Francisco, California 94122, and the Department of Radiology, The Medical College of Wisconsin, Milwaukee, Wisconsin 53226

ABSTRACT The outer, lateral esophageal walls in the distal half of the esophagus in each of five cats were labeled with small tantalum wires. About 8 wk later, esophageal motion associated with respiration and peristalsis, induced by injecting barium boli (5 ml each) into the proximal esophagus, was recorded on cine and serial biplane roentgenograms while recording intraluminal esophageal pressures simultaneously by manometry. Esophageal motion was also evaluated without a manometric tube in place. The coordinates for each marker were digitized and a computer was used to plot marker position against time. During respiration, the markers passively made a shallow, 2–10 mm excursion on the longitudinal esophageal axis. This movement was synchronous with thoracic and diaphragmatic movement and changes in intraluminal esophageal pressure. Immediately after the onset of peristalsis, the markers made a pronounced oral movement of 10 mm or more above their mean respiratory position, as if to engulf the bolus. Markers in opposing esophageal walls approximated one another and commenced an aboral movement as the bolus tail, which was essentially coincident with onset of the manometric pressure complex, passed the marker sites. The markers returned to their respective rest positions essentially coincident with passage of the pressure complex peak and then moved below their respective rest positions. The aboral ex-

cursion occurred predominantly after the bolus had emptied into the stomach. The magnitude and duration of oral excursion was significantly greater for the distal than for the more proximal markers; conversely, the magnitude and duration of aboral excursion was greater for the proximal than for the more distal markers. During the peristaltic sequence, the labeled portion of the esophagus shortened from 26 to 46% of its resting length. No evidence of esophageal torque was shown. These findings suggest that both the longitudinal and circular esophageal musculature play an active and important role during peristaltic transport of a bolus through the esophagus.

INTRODUCTION

Although cinerentgenography and intraluminal manometry have provided much information about esophageal physiology, these methods do not adequately record esophageal motion. In this study, the feline esophagus was marked with small tantalum wires and the effects of respiration and peristalsis on esophageal wall motion were evaluated. In addition, esophageal motion was correlated with intraluminal esophageal pressure changes recorded simultaneously by intraluminal manometry.

METHODS

Five cats were studied. In each animal, three to nine tantalum wire markers (0.4×2.0 mm) were implanted in the outer walls of the distal one-half of the esophagus by a non-surgical technique (1). An attempt was made to place markers in opposing lateral esophageal walls within the

Abstracts of this work appeared in *Invest. Radiol.* 1970. 5: 273, and *Gastroenterology*. 1971. 60: 657.

Received for publication 23 February 1972 and in revised form 12 September 1972.

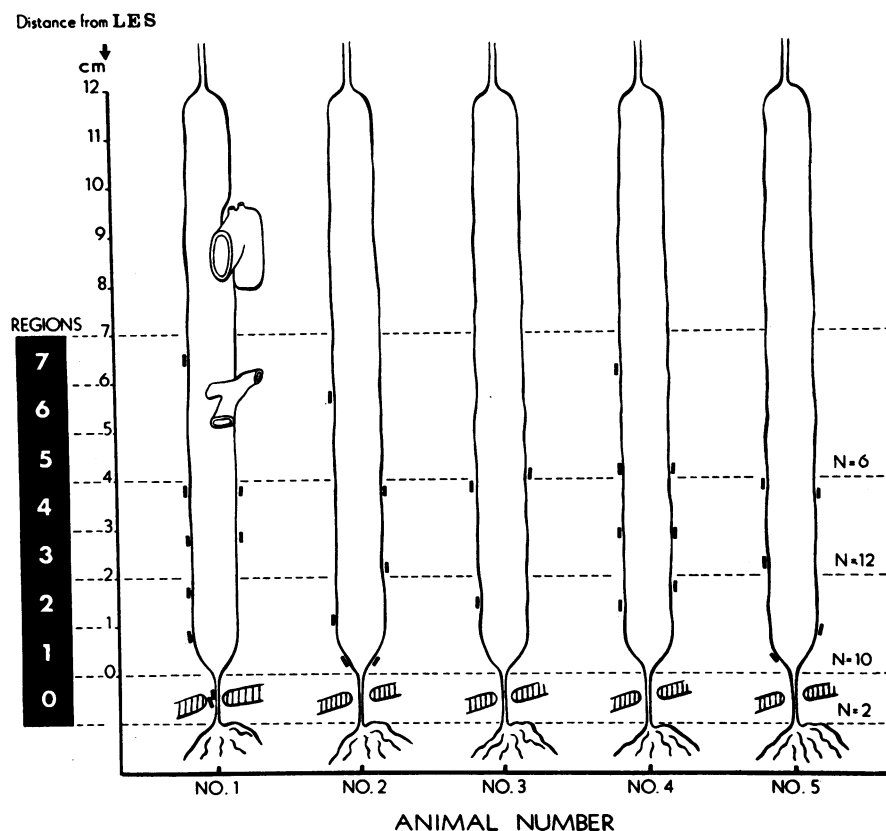


FIGURE 1 Regional distribution of esophageal markers in five cats. The markers were located in the distal one-half of the esophagus. The esophagi have been divided into imaginary regions, 1 cm in length, in order to permit pooling of data obtained from each animal. 6 markers were located in regions 5-7, 12 markers in region 3 and 4 and 10 markers in region 1 and 2. In one animal (no. 1), 2 markers were located in region 0, the LES segment.

same cross-sectional plane. The marking procedure does not cause important changes in esophageal histology or motility (2).

8 wk after marking, marker motion occurring during respiration and secondary peristalsis was recorded by single-plane cineroentgenography and biplane serial roentgenography. The animals, unmedicated, were restrained supine on a board and the jaws immobilized with a bite block. Secondary peristalsis was induced by injecting liquid barium (5 ml bolus) into the proximal esophagus. Primary peristalsis was not evaluated because swallows, when induced, were often repetitive.

To determine whether the animal moved during roentgen examination, the thoracic intraspinal ligament was marked percutaneously with tantalum wire. A cross wire, taped to the face of the image tube, served as a reference point (fiducial). Secondary peristaltic waves were recorded on 35-mm cineroentgenograms (75 kV, 200 mA, 14 fps, and 50 cm distance). To record the effects of respiration on marker motion, the barium bolus was not injected until 6-8 s after the beginning of the cinerecording. Cinerecording was continued until after peristalsis swept the barium bolus into the stomach, an additional 10-20 s. For the simultaneous biplane roentgen studies, two film changers were positioned at a 90° angle. The biplane studies were taken on

roll film¹ at two exposures/s for 27 s (80 kV, 200 mA, 0.1 s, and 50 cm).

Immediately after the initial cine- and biplane studies, a 4 lumen manometric tube was positioned in the esophagus so that the distal recording tip was 1-1.5 cm above the lower esophageal sphincter (LES).² In cats the LES segment (esophageal vestibule) measures 1-1.5 cm in length. The manometric tube was taped to the bite block. The four recording tips, spaced 3 cm apart, were identified by lead markers. The roentgenographic studies were repeated coincident with manometric recording.

The only change in the manometry method used in this study from that previously described (2) was a paper speed of 5 mm/s instead of 2.5 mm/s. An event marker was used to synchronize the roentgen sequences with the manometric tracing.

In all animals, four to six cineroentgenographic sequences, and in two animals, two serial biplane sequences were obtained during peristalsis both immediately before placement of the manometric tube and during intraluminal manometry.

¹ DuPont Cronex Hi-speed OH roll film, E. I. DuPont de Nemours & Co., Photo Products Div., Wilmington, Del.

² Abbreviations used in this paper: LES, lower esophageal sphincter; RL, mean resting length; RP, rest position.

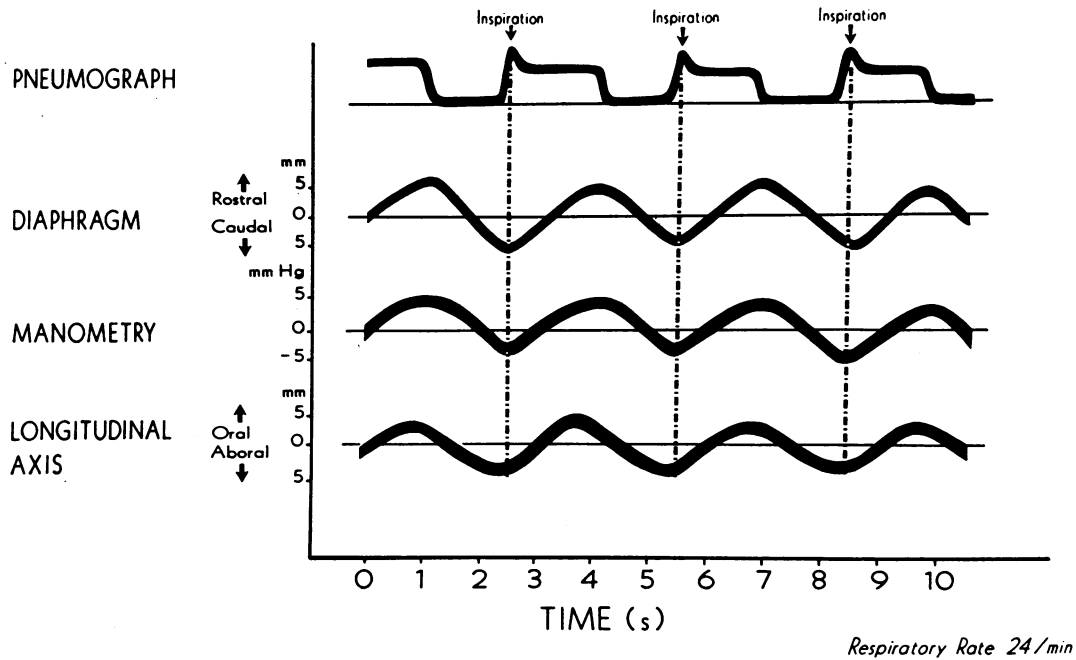


FIGURE 2 Esophageal motion associated with respiration (animal 4). The intraluminal manometric catheter tip and tantalum marker in the esophageal wall were located in region 4.

After the roentgenographic and manometric studies, the animals were sacrificed. At autopsy, most markers were shown to be firmly affixed within the outer, lateral esophageal wall. A few markers were located 1–2 mm away from the esophagus, but within the mediastinum. Roentgenograms of each esophageal specimen were taken to document marker position. The precise location of each marker was confirmed by removing the marker from its bed and sectioning through the marker site. Histologic examination demonstrated that

most markers had been located within the adventitia, adjacent to the muscularis externa; some markers were within the muscularis externa. Inflammatory changes around the marker beds were absent or minimal.

All roentgenographic studies were viewed, and sequences demonstrating quiet respiration, lack of animal movement, and secondary peristalsis were selected for measurement. From each animal, four cineradiographic sequences, two with and two without an indwelling manometric tube, were

Table I

MARKER MOVEMENT on the LONGITUDINAL ESOPHAGEAL AXIS DURING PERISTALSIS

REGIONS	A. MANOMETRIC TUBE IN PLACE				B. MANOMETRIC TUBE ABSENT			
	ORAL ↑		ABORAL ↓		ORAL ↑		ABORAL ↓	
	Magnitude (mm)	Duration (s)	Magnitude (mm)	Duration (s)	Magnitude (mm)	Duration (s)	Magnitude (mm)	Duration (s)
7								
6	108±17	64±24	72±15	12.5±2.2	60±25	34±12	70±17	153±4.9
5	N=12	N=12	N=10	N=4	N=12	N=12	N=12	N=4
4	108±3	87±18	52±29	83±0.5	79±30	59±1.4	53±2.9	123±2.4
3	N=24	N=24	N=21	N=3	N=24	N=24	N=24	N=3
2	130±3.2	109±1.3	15±1.7	–	99±2.3	88±1.4	11±1.1	–
1	N=20	N=20	N=10		N=20	N=15		
0	16.5±4.5	14.5±2.5	0±0	0±0	11.0±0	12.5±1.5	0±0	0±0
	N=4	N=4	N=2	N=2	N=4	N=4	N=4	N=4

* $\bar{x} \pm SD$.

† $P \leq 0.05$.

– Not measurable.

N = Number of measurements.

analyzed. The serial biplane roentgenograms obtained from the two animals so studied were also analyzed.

Marker movements recorded on the roentgen studies were measured by projecting the roentgen images on an Itek digitizer (Itek Corp., Rochester, N. Y.) and recording the coordinates for each marker on IBM punch cards (IBM Corp., White Plains, N. Y.). By measuring several sequences twice, the measurement error for marker coordinates was determined to be 0–1 mm. Coordinates were also obtained for the fiduciary, spinal marker, upper margin of the LES (point of the V configuration at the head of the barium column (3), tail of the barium bolus (point of the inverted V configuration at the tail of the barium column (3), and the distal two lead markers in the manometric

tube. Measurements were taken from every fourth cine-frame, corresponding to time intervals of 0.29 s. Measurements were taken from each roentgenogram (0.5-s intervals) in the serial biplane sequence. Data from the punch cards was fed into the Stanford Medical School ACME (Advanced Computer for medical research) computer which normalized, scaled, and plotted out graphs of marker movement. The 3 cm distance between markers in the manometric tube permitted assessment of magnification. Because the geometry was identical during sequences obtained without manometry, the same correction factors for magnification were used for studies performed without a manometric tube in place.

Marker motion on the longitudinal, coronal, and sagittal

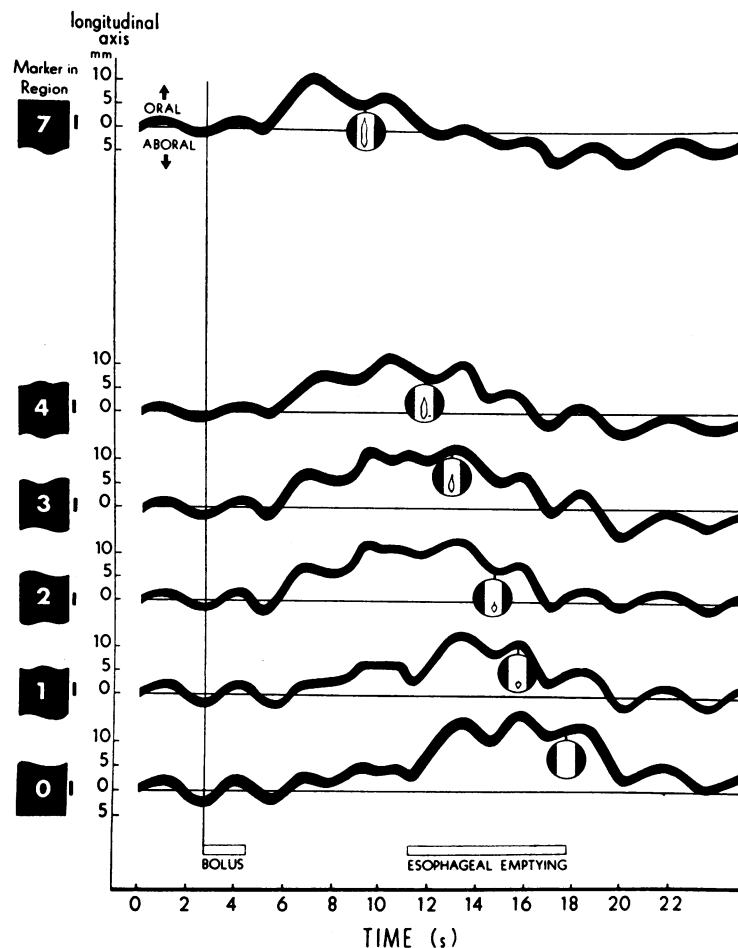


FIGURE 3 Marker movement on the longitudinal axis during peristalsis: manometric tube in place (animal 1). Tracings are shown for individual markers in regions 1, 4, and 7, respectively, and the LES. The circular inserts represent drawings of the cineroentgenographic appearance of the barium bolus as the tail of the bolus passed the respective markers. The lowest insert shows when esophageal emptying was complete. The onset of peristalsis was accompanied by nearly simultaneous, oral movement of markers located in regions 2–4, and 7. Oral excursion of markers in region 1 and the LES began about 6 s later. The markers commenced an aboral movement approximately coincident with passage of the barium bolus tail by the respective marker sites. Markers in regions 7, 4, and 3 made aboral excursions below their respective rest positions. The effects of respiration are seen superimposed on the oral-aboral peristaltic marker movements.

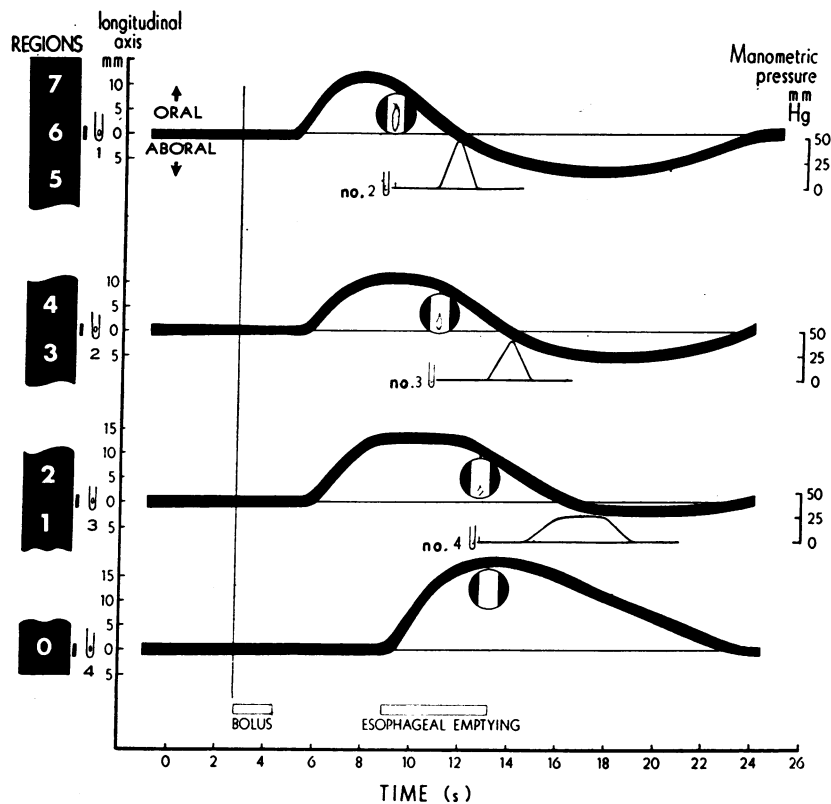


FIGURE 4 Marker movement on the longitudinal esophageal axis during peristalsis: manometric tube in place ("composite animal"). The curves for oral-aboral movements of markers in the esophageal body were drawn using mean values obtained by pooling data from all five animals. Selected cineframes show the barium bolus. Vestibular markers (region 0) were present in only one animal. The effects of respiration have been averaged out and are not shown. The base line (RP) represents mean marker position during the respiratory cycle. Although the aboral excursion was not completely recorded on most of the cine runs, measurements from the two serial roentgenogram studies indicate that the total duration of the peristaltic sequence is about 18 s. Passage of the barium bolus tail by the respective marker sites occurred when the markers were on the descending shoulder of their respective curves for oral excursion. The markers "fell" through their respective RP at the time the pressure peak of the pressure wave traversed the esophageal wall at the respective marker sites.

esophageal axes was plotted against time by the computer. The coronal and sagittal axis for a given marker are defined by intersection of the coronal and sagittal esophageal planes, respectively, with the cross-sectional plane of the marker. Longitudinal movement was plotted for each marker. Additionally, changes in distance between markers at different levels along the longitudinal axis were plotted against time. Movement of two opposing markers in the same cross-sectional plane along the coronal or sagittal axis was plotted by the same method. Also plotted against time was the sequential position of the barium bolus tail during its aboral travel. The event marks permitted correlation of the manometric pressure complexes with the computer plots.

To characterize the regional location of each marker along the esophagus, it was necessary to select a reference point. Although the esophagogastric junction in the cat is readily identified (4), esophageal shortening during resection prevents accurate measurement of the distance between a marker and the esophagogastric junction which exists dur-

ing life. The distal point of the barium column as seen on roentgenograms, a point which identifies the upper margin of the closed LES (3), was taken as the reference point. The distal "V" configuration of the barium column did not change in position and persisted 4-6 s until the LES opened. The regional location of each esophageal marker in each animal during life was characterized by measuring its distance from the upper margin of the LES (mean distance during a respiratory cycle), (Fig. 1). In animal no. 1, two markers located several millimeters below the "V" reference point were in the LES. At autopsy, these two markers measured 5 mm above the esophagogastric junction.

Measurements of marker movement on the longitudinal esophageal axis during respiration and peristalsis were made from the computer plots. The base line or rest position (RP) used for measurements was drawn through the mean marker position during quiet respiration. The mean resting length (RL) during quiet respiration between any two markers in different regions is defined as the distance be-

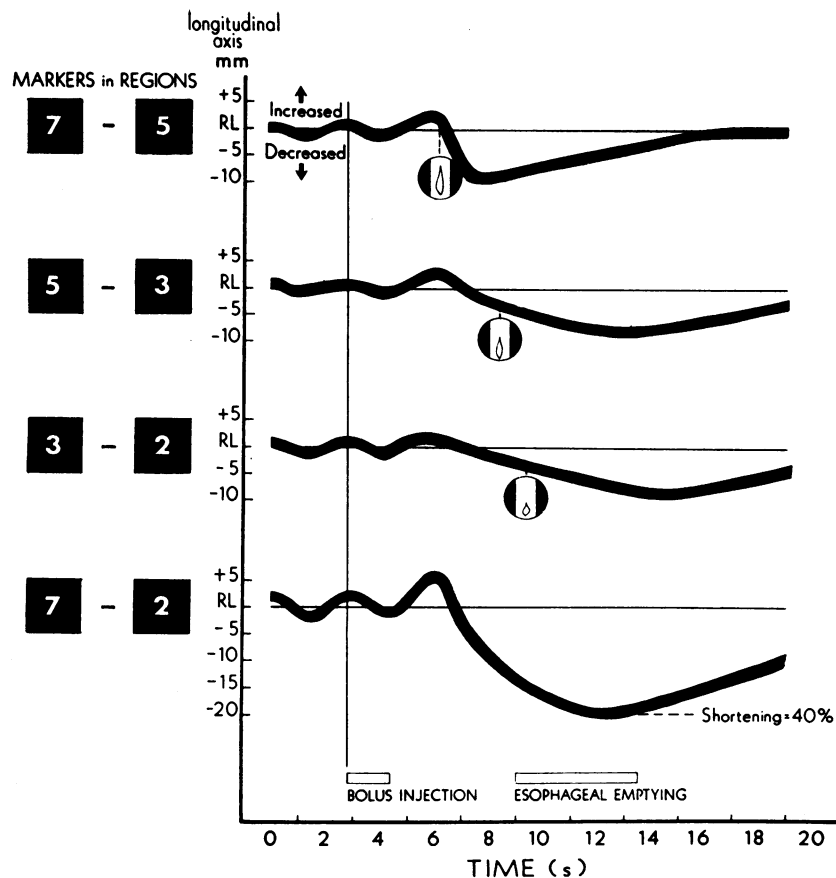


FIGURE 5 Movement of markers on the longitudinal axis relative to one another: manometric tube in place (animal 4). The distance between the respective markers increased 1-2 mm during inspiration. Immediately after the onset of peristalsis, the markers in regions 2-7 separated slightly and then approximated one another in an aboral sequence. The selected cineframes show the appearance of the barium bolus as the bolus tail passed the more proximal of the two markers from which each of the curves for marker separation and approximation were drawn. The markers in two different regions approximated one another predominantly after the tail of the barium bolus passed the more proximal marker. During peristalsis, the portion of esophagus spanning regions 2-7 shortened 40% of its RL.

tween their respective RP. Oral marker movement is defined as movement toward the mouth, and aboral marker movement as movement toward the stomach. Oral marker excursion includes oral movement of a marker above RP and its return to RP; similarly, aboral excursion includes aboral movement of a marker below RP and its return to RP. The magnitude of oral movement or excursion is defined as the maximal distance a marker moved above its RP during an oral excursion, and magnitude of aboral movement or excursion is defined as the maximal distance moved below its RP during an aboral excursion. Measurements of the magnitude of oral and aboral excursions occurring during peristalsis were made by averaging out the superimposed effects of respiration and measuring from the base line. The duration of oral and aboral peristaltic excursions, respectively, were also measured. Duration of aboral excursion was measured only from the biplane studies because the cinerecordings were generally not continued long enough to record the complete return of the markers to their RP.

Differences between values for marker movement were analyzed statistically using the paired Student *t* test (5). The 5% confidence level was used to identify values which differed significantly.

RESULTS

Respiration. During quiet respiration, the esophageal markers made a shallow, oscillatory, oral-aboral excursion along the longitudinal esophageal axis, synchronous with thoracic cage and diaphragmatic movement and changes in intraluminal esophageal pressure (Fig. 2). The total oral-aboral excursion ranged from 2 to 10 mm, varied with the depth of respiration, and was slightly greater for the distal than for the more proximal markers. Esophageal movement associated with respiration was not affected by the presence of an indwelling manometric tube.

Peristalsis. All markers located within the esophageal wall (adventitia or muscularis externa) made pronounced and characteristic movements during peristalsis. In contrast, markers located within the mediastinum, but 1–2 mm away from the esophagus, showed no appreciable movement during peristalsis.

Manometric tube in place. During injection of liquid barium into the proximal esophagus, the barium distributed throughout the esophageal body in a continuous column. The esophageal markers, which were located in the distal one-half of the esophageal body, began an oral movement, 0.5 s or more, after bolus injection was completed. In three animals, onset of oral movement for all markers occurred 0.5–1.0 s after completion of bolus injection. In two animals (nos. 1 and 2), the onset of oral movement in region 1 and regions 1–3, respectively, lagged 2.6–4.0 s behind that of the markers located more proximally. In animal no. 1, the two LES markers began their oral excursion 6 s after that of the markers located proximally (Fig. 3).

The bolus tail, formed by approximation of opposing esophageal walls during peristalsis, passed the respective marker sites as the markers either completed their maximal oral movement or had begun to return toward

their rest position. After passage of the bolus tail, each of the markers trailed the bolus tail and returned to its rest position. The markers in the esophageal body also made an aboral excursion which occurred either predominantly or entirely after the barium bolus had emptied into the stomach. The peristaltic movement sequence was complete when all of the markers returned to their respective RP.

The magnitude and duration of oral excursion were significantly greater ($P \leq 0.05$) for the distal than for the more proximal markers (Table I). Markers in regions 5–7 made an oral excursion 10.8 ± 1.7 mm in amplitude and 6.4 ± 2.4 s in duration, whereas markers in regions 1 and 2 made an oral excursion 13.0 ± 3.2 mm in amplitude and 10.9 ± 1.3 s in duration. Conversely, the magnitude of aboral excursion was significantly greater for the proximal than for the distal markers. Markers in regions 5–7 made an aboral excursion 7.2 ± 1.5 mm in amplitude compared with 1.5 ± 1.7 mm for markers in regions 1 and 2. The duration of aboral excursion was greater for the proximal than for the distal markers, but measurements were too few for meaningful statistical analysis. The LES markers, present in one animal, demonstrated greater magnitude and

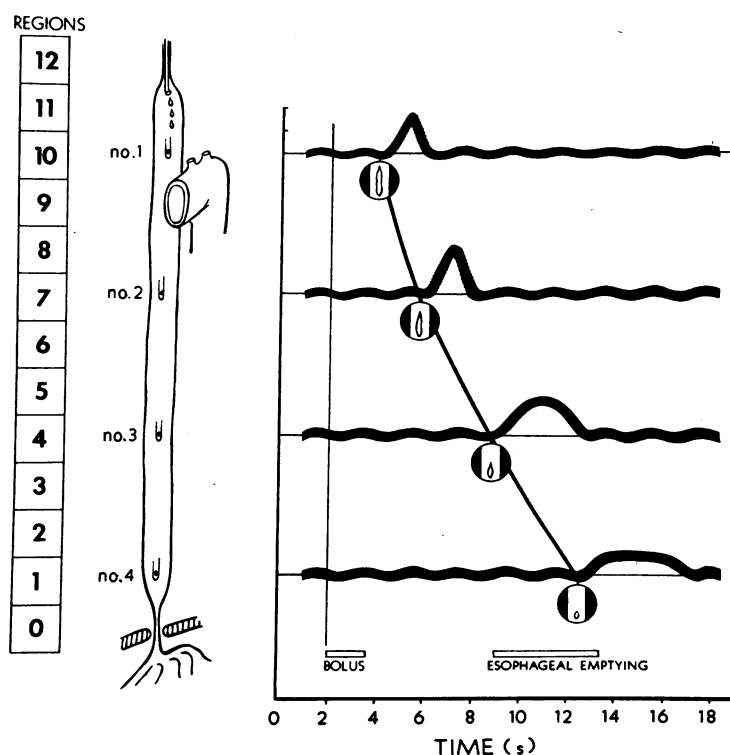


FIGURE 6 Relationship between bolus tail and manometric pressure complexes ("composite animal"). The bolus tail, shown on the selected cineframes, passed the respective manometric recording tips essentially coincident with the onset of the peristaltic pressure complex recorded for each tip.

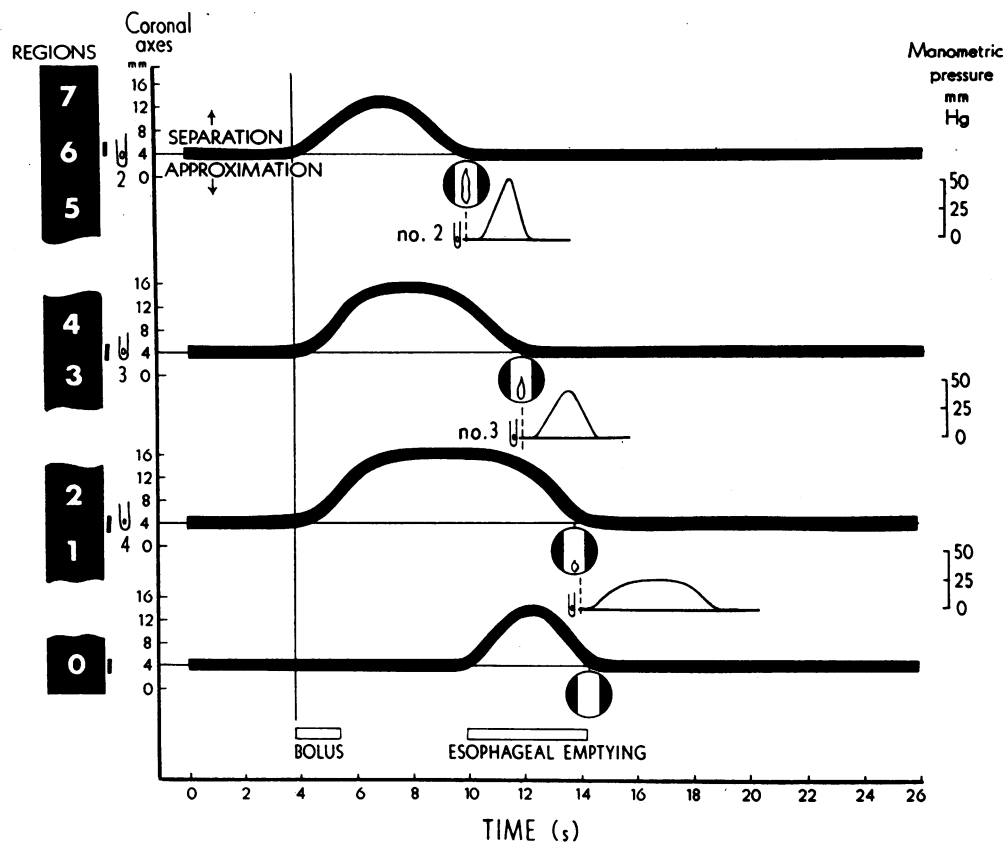


FIGURE 7 Marker movement along the coronal axis during peristalsis: manometric tube in place ("composite animal"). During injection of barium, markers on opposing esophageal walls separated. Markers in the different regions reapproximated one another in an aboral sequence nearly coincident with passage of the bolus tail. The cineframes, corresponding to reapproximation of the respective opposing esophageal markers, show the sequential appearance of the barium bolus.

duration of oral excursion than markers in the esophageal body. From the mean values of longitudinal marker motion during peristalsis, curves were drawn for regional esophageal movement for a "composite animal" (Fig. 4).

Movement of esophageal markers in different regions relative to each other along the longitudinal axis during a peristaltic sequence is shown in Fig. 5. During oral movement, the labeled portion of the esophagus stretched slightly. The distances between markers in regions 2-7 transiently became 2-4 mm greater than their respective RL. The distance between any two markers located in adjacent or nearly adjacent regions then decreased and became shortest as the more proximal marker returned toward its RP. Maximal approximation of markers in different regions occurred in an aborally oriented sequence (Fig. 5). During the peristaltic sequence, the marked portion of esophagus shortened $36.8 \pm 7.3\%$ of its RL (range 26-46%). During peristalsis, manometric tube movement was negligible (≤ 2 mm).

Correlation of esophageal peristaltic movement with manometry reveals that markers located at the same resting level as one of the manometric recording tips moved through or returned to their respective RP essentially coincident with passage of the pressure complex peak (Fig. 4). The markers passed through their respective RP 0.4 ± 0.9 s before the peristaltic pressure peak traversed the esophageal wall at the marker sites. The relationship between passage of the bolus tail and the pressure complexes cannot be determined from Fig. 4 because the markers, during their respective oral excursions, were located proximal to the level of the recording tips when the bolus tail passed each of the markers. A plot correlating position of the barium bolus tail and the manometric pressure tracings (Fig. 6) reveals that passage of the bolus tail at each of the recording tips is nearly coincident with onset of the manometric pressure complex. Passage of the bolus tail preceded pressure complex onset by 0.4 ± 0.6 s. The interval between passage of the bolus tail by (a) mark-

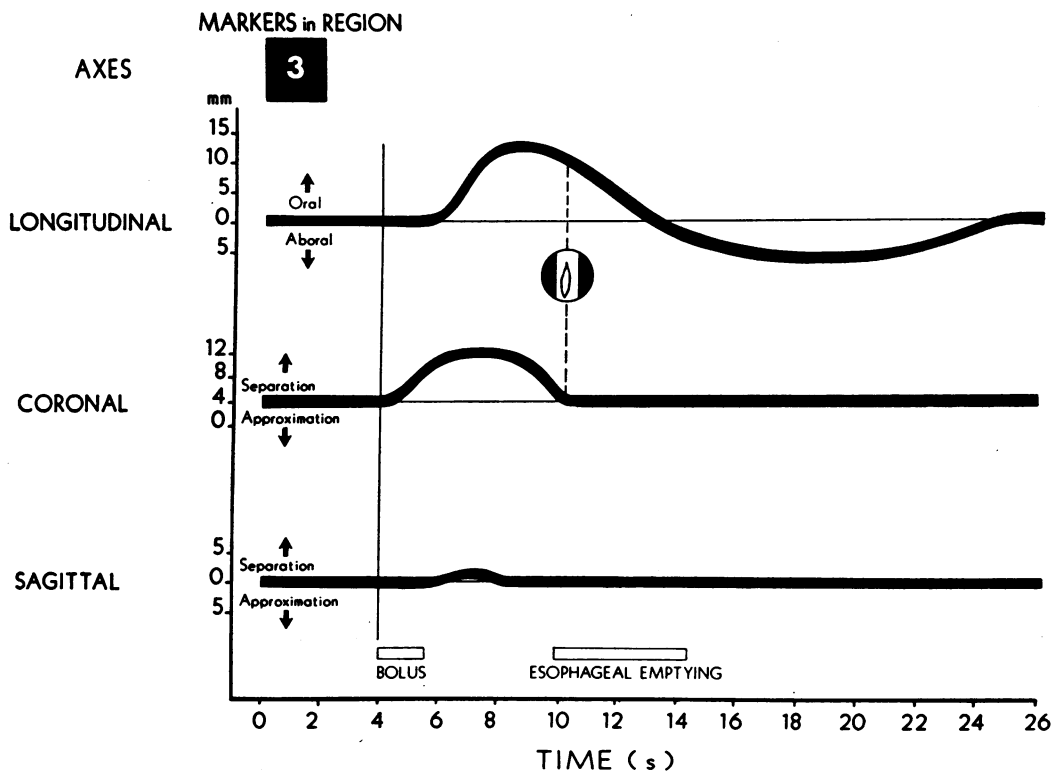


FIGURE 8 Relationship of the movement of markers in region 3 along the longitudinal, coronal and sagittal axes: manometric tube in place (animal 4). The curves for motion along the coronal sagittal axis represent changes in distance between two opposing markers in region 3. The longitudinal axis tracing represents motion of one of the markers; longitudinal movement for the other region 3 marker was virtually identical. The tail of the bolus passed the markers coincident with their reapproximation on the coronal axis (dotted line), but before they had completed their oral excursion along the longitudinal axis. Marker movement along the sagittal axis was negligible, indicating that significant esophageal torque did not occur.

ers during their oral peristaltic excursion, and (b) recording tips located at the same RP as the respective markers was 1.9 ± 0.9 s.

During resting conditions, opposing markers in outer walls of the nondistended esophagus were 3–4 mm apart. The esophageal walls separated during injection of barium. During the peristaltic sequence, maximal luminal diameter averaged about 9 mm for regions 5–7, 11 mm for regions 3 and 4 and 12 mm for regions 1 and 2 (Fig. 7). Opposing markers in different esophageal regions reapproximated one another in an aboral sequence which was nearly coincident with passage of the bolus tail.

Serial biplane studies demonstrated that marker motion on the longitudinal and coronal axis was of the same magnitude as that recorded on the cinerontgenograms. Measurements of marker movement and bolus tail position on the longitudinal axis were identical on both anterior-posterior and lateral projections. The lateral roentgenograms showed little or no marker move-

ment along the sagittal axis (Fig. 8), demonstrating that no significant esophageal torque occurred. Consequently, marker movement may be accurately depicted within the two dimensions of the coronal plane. When marker movement on the longitudinal axis was plotted against movement on the coronal axis, characteristic loops for marker motion during peristaltic transport of a liquid bolus were obtained for markers in different regions (Fig. 9A). Markers in regions 3–7 described "P" loops, whereas the distal markers in regions 1 and 2 described "D" loops. The entire sequence of esophageal movement during peristaltic transport of a barium bolus is summarized diagrammatically in Fig. 10.

Manometric tube absent. During peristalsis, the magnitude and duration of oral excursion for the distal markers were significantly greater than for the more proximal markers. Conversely, the magnitude of aboral movement was significantly greater for the proximal than for the distal markers (Table I). Esophageal torque was not in evidence.

In the absence of the manometric tube, the regional esophageal peristaltic movement during peristalsis was similar in pattern to that occurring when the manometric tube was in place (Fig. 9); however, some quantitative differences existed (Fig. 11). The magnitude and duration of oral excursion were significantly less in the absence of the tube than when the tube was in place. The duration of aboral excursion was greater with the tube absent, but the measurements were too few in number to permit meaningful statistical evaluation. The magnitude of aboral movement was not affected by presence or absence of the manometric tube. Esophageal shortening of the labeled portion of the esophagus during peristalsis, occurring with the tube absent, $34 \pm 4.2\%$, was comparable with that recorded when the tube was in place, $36 \pm 7.3\%$.

DISCUSSION

The results of this study characterize and quantitate feline esophageal motion associated with respiration and peristalsis. Previous studies utilizing metal markers to

study esophageal motion in experimental animals are limited to two independent investigators: Nauta (6) and Johnson (7-9). These investigators labeled the distal esophageal wall of dogs at thoracotomy. Esophageal movement was described, but not quantitated. Intraluminal manometry was not performed and the effects of the marking procedure on esophageal motility were not evaluated.

We believe that small metal markers positioned via the intraluminal transesophageal technique (1), adjacent to the muscularis externa, but within the esophageal adventitia, permit accurate assessment of esophageal wall movement. Under resting conditions, shallow, oscillatory marker motion along the longitudinal esophageal axis was synchronous with respiration. During peristaltic transport of a barium bolus, the esophageal markers described characteristic regional "P" or "D" loop movements. Mediastinal markers outside the esophagus did not move significantly during respiration or peristalsis.

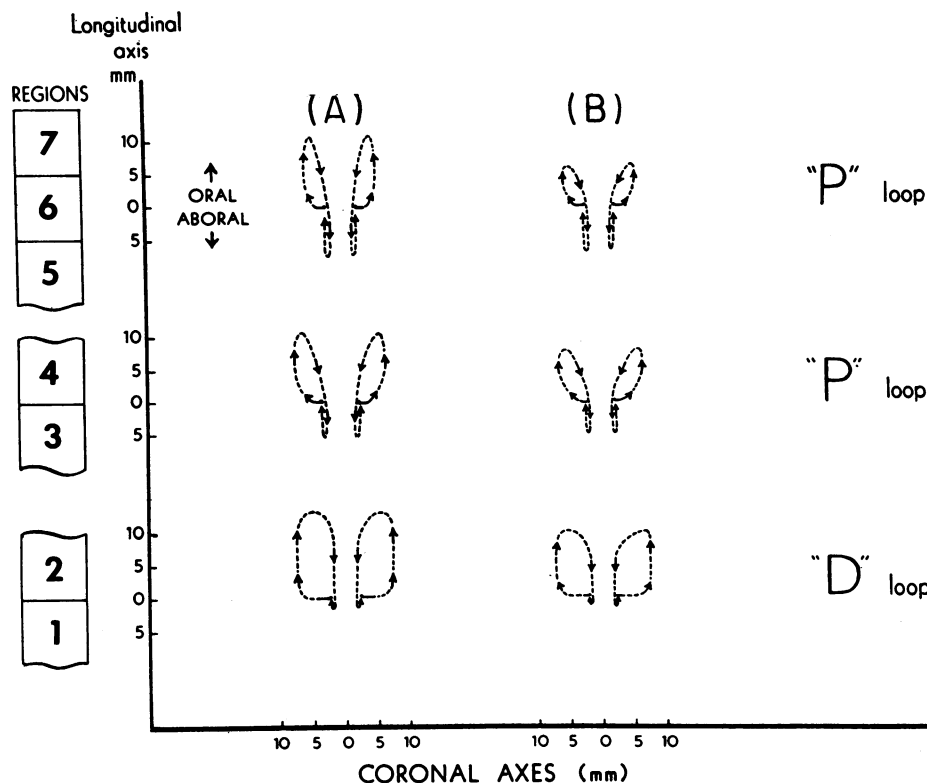


FIGURE 9 Marker movement in the coronal plane during esophageal transport of a liquid bolus ("composite animal"): (A) manometric tube in place and (B) manometric tube absent. Markers in regions 3-7 described characteristic "P" loops and markers in regions 1 and 2 "D" loops. Marker movement in the absence of a manometric tube was similar in pattern to that recorded with a tube in place, but oral movement was decreased in magnitude.

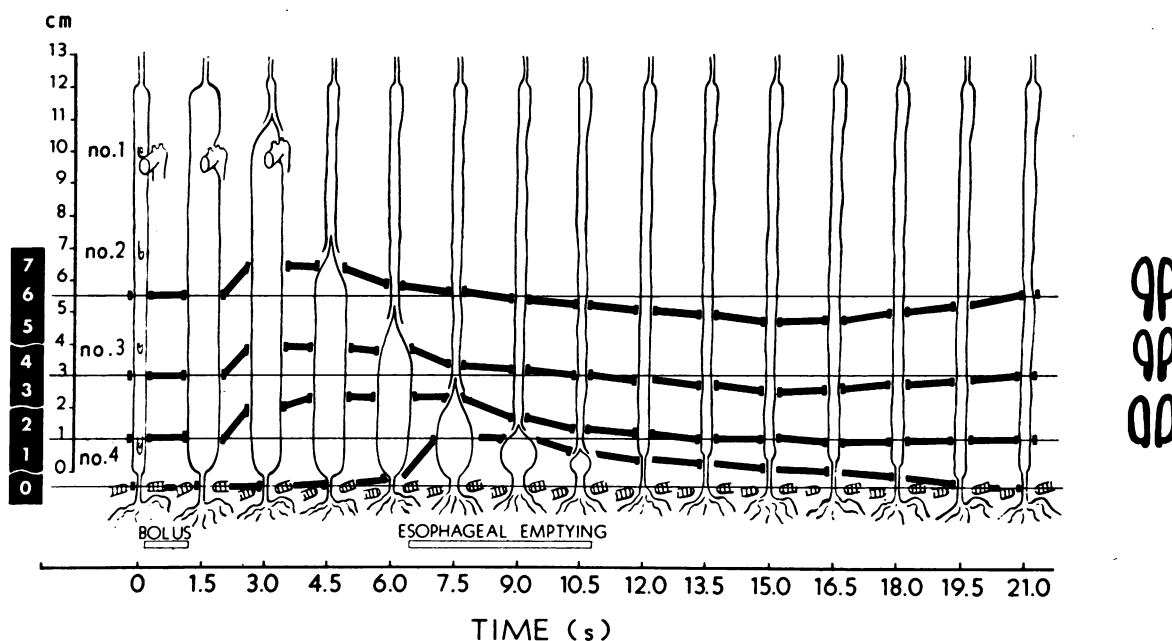


FIGURE 10 Esophageal movement during peristaltic transport of a liquid bolus: manometric tube in place ("composite animal"). During injection, a liquid bolus distributes the length of the esophagus causing nearly uniform distention. As a secondary peristaltic contraction wave forms in the upper esophagus, the markers make a pronounced oral movement. An inverted V configuration is imparted to the tail of the bolus by the circular contraction wave, and as the tail passes the respective marker sites, the markers commence an aboral movement. As the bolus is pushed ahead of the contraction wave, esophageal dilatation increases because the onset of bolus emptying into the stomach is not immediate. The bolus does not begin to empty into the stomach until the peristaltic contraction wave reaches the midportion of the esophagus, and emptying is not complete until the contraction wave reaches the cardia about 4.5 s later. Markers in the esophageal body trail the contraction wave and make an aboral excursion predominantly after esophageal emptying is complete. The entire sequence is about 18 s in duration. The characteristic loops for marker movements within the coronal plane are shown on the right. Markers in the LES segment (present in one animal) show pronounced oral movement during peristalsis.

The labeled portion of esophagus moved longitudinally (Fig. 3) and elongated and shortened (Fig. 7) in rhythm with thoracic cage movement and fluctuations of intraluminal esophageal pressure associated with respiration. This movement appears to be passive, caused by respiratory diaphragmatic movement. Little or no electrical activity is recorded from the esophageal musculature under resting conditions (10).

Esophageal movement during peristalsis is more dramatic (Fig. 4) and undoubtedly reflects active contraction of both the circular and longitudinal esophageal musculature. Aborally directed bursts of electrical activity occur in the feline esophageal musculature during peristalsis (10). The esophageal markers made characteristic and reproducible oral-aboral peristaltic movements, which were of much greater magnitude than marker movement associated with respiration. Passage of the barium bolus tail by each marker was essentially coincident with the onset of the manometric peristaltic

pressure complex recorded at the level of the marker. The entire peristaltic sequence of oral-aboral marker excursion was about 18 s in duration and the duration of oral and aboral excursions appear to be reciprocally related. During peristalsis, the labeled portion of the esophagus shortened from 26 to 46% of its RL.

In the past, the role of the circular musculature in esophageal peristalsis has been stressed, whereas the function of the longitudinal musculature has been, for the most part, neglected. A few workers (6, 9, 11, 12) have documented that significant esophageal shortening occurs during peristalsis, but their work has not received wide attention. Christensen and Lund (13), using a bath preparation, have studied the response of smooth muscle in the opossum esophagus after distention and electrical stimulation. Transient contraction of circular muscle (on response) occurred at the point of stimulation, whereas the longitudinal muscle contraction (duration response) occurred over a much longer segment, predominantly

below the point of stimulation, and remained contracted as long as the stimulus was applied. In the intact animal, the circular and longitudinal muscle act in concert, and their individual roles are difficult to separate. Although the marker method used in this study does not directly quantitate circular and longitudinal muscle activity, the study results do suggest that both types of muscle play important active roles during peristalsis. That circular approximation of the esophageal walls during peristalsis is caused predominantly by contraction of the circular musculature and longitudinal peristaltic movement primarily reflects activity of the longitudinal musculature seems likely. The aborally propagated wave of segmental, circular contraction is recorded manometrically as a pressure complex and seen roentgenographically as a stripping wave which imparts an inverted V configuration to the tail of a barium bolus. Longitudinal esophageal movement, however, is not well demonstrated by these methods. Esophageal labeling with metal markers suggests that during peristalsis, contraction of the longitudinal esophageal musculature: (a) occurs in an aborally oriented sequence, (b) results in significant esophageal shortening, and (c) causes the esophagus to make oral and aboral movements. The significant differences in magnitude and duration of oral movement and in the magnitude of aboral movement between the proximal and

distal markers are probably accounted for by the different lengths of esophagus above or below the respective markers, which are available for longitudinal shortening. Longitudinal muscle contraction would appear to account for the sustained, aborally directed, esophageal propulsive force (EPF) described by Winship and Zboralske (14) and to contribute to the caudally oriented esophageal "pull" described by Pope (15).

Similar to many systems which record physiologic events, the measuring system used in this study caused some alteration in the physiologic function under investigation. With a manometric tube in place, esophageal motion during peristalsis was similar in pattern, but had a greater magnitude and duration of oral excursion compared with that occurring when a tube was not present. Perhaps, during its oral peristaltic movement, the esophagus "shimmys" up the relatively fixed intraluminal tube. Additionally, a changing spatial relationship exists during peristalsis between manometric recording tips and points along the esophageal wall. Clearly, a manometric pressure complex does not represent the muscular motor activity occurring at a single point along the esophageal wall, but rather records activity from an esophageal segment as numerous points along the segment move longitudinally with respect to the recording tip. Thus, the manometric tracing for a given catheter tip represents

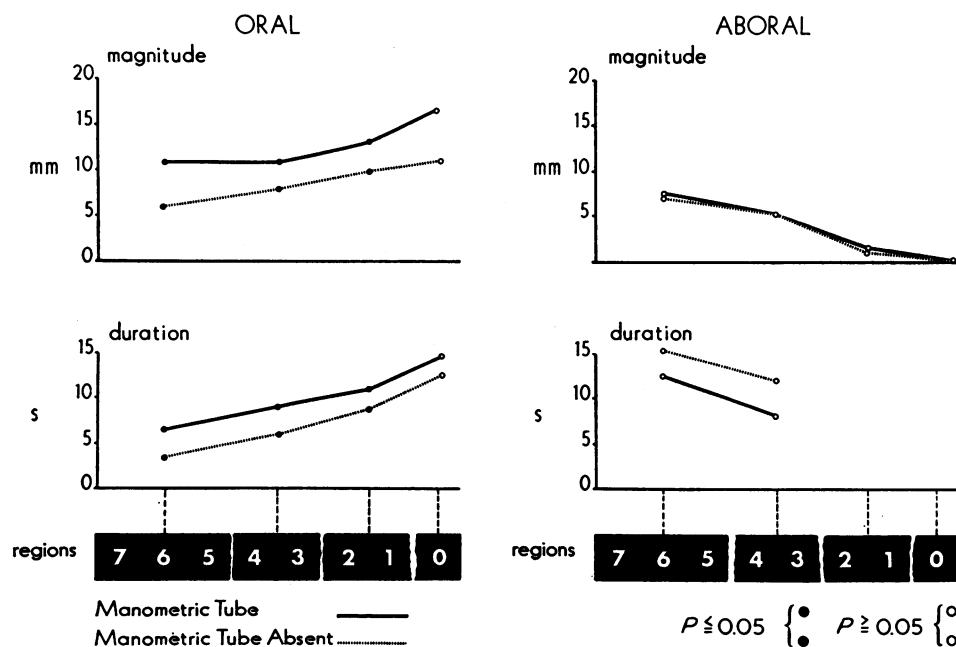


FIGURE 11 Magnitude and duration of oral and aboral marker excursion during peristalsis: manometric tube in place and manometric tube absent. The vertical paired solid dots are used to indicate significantly different values for regional marker excursion (magnitude or duration) recorded, respectively, with and without a manometric tube in place. Vertical open dots represent values which did not differ significantly.

pressure activity as "seen" from the relatively fixed recording tip. If the catheter tip were to track a single esophageal point during its peristaltic excursion, a pressure complex differing in form from that recorded by conventional manometry would probably be obtained.

The present study suggests that the esophageal bolus transport mechanism has several important components. Immediately after presentation of a bolus in the proximal esophagus, the gullet shortens and moves orally as if to engulf the bolus. Longitudinal esophageal shortening is believed to eliminate the abdominal esophageal segment and efface the vestibular muscosal plug (8). Because the esophagogastric junction and diaphragmatic hiatus were not labeled in the cats studied, we cannot determine whether the esophageal vestibule stretched or moved orally above the hiatus during peristalsis. Either or both of these events, however, might contribute to the mechanism of LES opening, thus enabling a bolus to enter the stomach. A well-recognized component of the bolus transport mechanism is the aborally directed peristaltic wave of circular contraction which serves to "push" a bolus toward the stomach. An equally important function of circular muscle contraction may be sealing of the esophageal lumen, thus preventing proximal escape of a bolus. With the lumen sealed, any shortening of longitudinal muscle which occurs below the site of circular muscular contraction would tend to "pull" a bolus toward the stomach.

ACKNOWLEDGMENTS

The authors express their appreciation to Dr. Leo T. McCarthy for evaluating the histology of esophageal sections.

This work was supported in part by grants GM 1707 and GM 1272 of the National Institute of General Medical Sciences, National Institutes of Health, U. S. Public Health Service, and by National Institutes of Health research grant No 1 RO1 AM 15540-1. This investigation was conducted in part while Dr. Dodds and Dr. Stewart were Academic Trainees in Diagnostic Radiology.

REFERENCES

1. Stewart, E. T., and W. J. Dodds. 1969. Marking the feline esophagus with small tantalum wires. An experimental technic. *Radiology*. **93**: 176.
2. Dodds, W. J., E. T. Stewart, L. J. McCarthy, and F. F. Zboralske. 1971. Esophageal labeling with small tantalum wires: effects on motility and histology. *Invest. Radiol.* **6**: 191.
3. Zboralske, F. F., and W. J. Dodds. 1969. Roentgenographic diagnosis of primary disorders of esophageal motility. *Radiol. Clin. North Am.* **7**: 147.
4. Bremner, C. G., R. G. Shorter, and F. H. Ellis, Jr. 1970. Anatomy of feline esophagus with special reference to its mucosal wall and phrenoesophageal membrane. *J. Surg. Res.* **10**: 327.
5. Snedecor, G. W., and W. G. Cochran. 1967. Statistical Methods. The Iowa State University Press, Ames, Iowa. 6th edition.
6. Nauta, J. 1956. The closing mechanism between the esophagus and the stomach. *Gastroenterologia*. **86**: 219.
7. Johnson, H. D. 1966. Active and passive opening of the cardia and its relation to the pathogenesis of hiatus hernia. *Gut*. **7**: 392.
8. Johnson, H. D., and J. W. Laws. 1966. The cardia in swallowing, eructation and vomiting. *Lancet*. **2**: 1268.
9. Johnson, H. D. 1968. The Cardia and Hiatus Hernia. Charles C. Thomas, Publisher, Springfield, Ill.
10. Hellemens, J., G. Vantrappen, P. Valembois, J. Janssens, and J. Vandenbroucke. 1968. Electrical activity of striated and smooth muscle of the esophagus. *Am. J. Dig. Dis.* **13**: 320.
11. Botha, G. S. M. 1962. The Gastro-Oesophageal Junction. Little, Brown and Co., Boston.
12. Torrance, H. B. 1958. Studies on the mechanism of gastroesophageal regurgitation. *J. R. Coll. Surg. Edinb.* **4**: 54.
13. Christensen, J., and G. F. Lund. 1969. Esophageal responses to distension and electrical stimulation. *J. Clin. Invest.* **48**: 408.
14. Winship, D. H., and F. F. Zboralske. 1967. The esophageal propulsive force: esophageal response to acute obstruction. *J. Clin. Invest.* **46**: 1391.
15. Pope, C. E., II. 1968. A comparison of "squeeze" and "pull" in the human esophagus. *Gastroenterology*. **54**: 1300. (Abstr.)