

Acute poststreptococcal glomerulonephritis: immune deposit disease.

A F Michael Jr, ... , R A Good, R L Vernier

J Clin Invest. 1966;[45\(2\)](#):237-248. <https://doi.org/10.1172/JCI105336>.

Research Article

Find the latest version:

<https://jci.me/105336/pdf>



Acute Poststreptococcal Glomerulonephritis: Immune Deposit Disease *

ALFRED F. MICHAEL, JR.,† KEITH N. DRUMMOND,‡ ROBERT A. GOOD,§ AND
ROBERT L. VERNIER || WITH THE TECHNICAL ASSISTANCE OF
AGNES M. OPSTAD AND JOYCE E. LOUNBERG

(From the Pediatric Research Laboratories of the Variety Club Heart Hospital and the
Department of Pediatrics, University of Minnesota, Minneapolis, Minn.)

The possible role of immunologic mechanisms in acute poststreptococcal glomerulonephritis was suggested in 1908 by Schick (2), who compared the delay in appearance of serum sickness after injection of heterologous serum to the latent period between scarlet fever and onset of acute glomerulonephritis. Evidence in support of this concept is the depression of serum complement during the early stages of the disease (3) and glomerular localization of immunoglobulin. Immunofluorescent studies have revealed either no glomerular deposition of γ -globulin (4) or a diffuse involvement of the capillary wall (5-9). Seegal, Andres, Hsu, and Zabriskie (10) demonstrated the presence of 7 S γ -globulin, β_{1C} -globulin, and streptococcal antigen in the glomeruli of most patients with this disease. By studies employing ferritin-labeled antibodies, these proteins could be demonstrated in the mesangium, between the endothelial cells, and within and adjacent to the basement membrane. Electron microscopic observations of

the kidney in acute glomerulonephritis have also revealed the presence of discrete electron dense masses adjacent to the epithelial surface of the glomerular basement membrane (11-18).

The purpose of this paper is to describe immunofluorescent and electron microscopic observations of the kidney in 16 children with acute poststreptococcal glomerulonephritis. This study demonstrates 1) the presence of discrete deposits of γ G- and β_{1C} -globulins along the glomerular basement membrane and its epithelial surface that are similar in size and location to the dense masses seen by both thin section microscopy and electron microscopy; 2) the characteristic and unique specificity of this lesion in acute poststreptococcal glomerulonephritis, its difference from other glomerular diseases, and the similarity to experimental antigen-antibody complex nephritis; and 3) the resolution of these deposits during recovery from the disease and their absence from the glomeruli 10 years after epidemic acute poststreptococcal glomerulonephritis.

Methods

Patients. The major portion of the study concerned sixteen children with acute poststreptococcal glomerulonephritis having the characteristic clinical course and renal histology as well as prior β -hemolytic streptococcal infections and elevated or rising antistreptococcal antibody titers. A total of 22 renal biopsies were performed on these patients by the method previously described (19) and at the times indicated in Table I. As part of a separate follow-up study (20) 10 years after well-documented acute poststreptococcal glomerulonephritis (Red Lake, Minnesota, epidemic of 1953), additional renal biopsies were performed on 14 children and studied by fluorescent microscopy.

Electron and fluorescent microscopic observations of the kidney were also made in one patient with lupus nephritis and one with Goodpasture's disease.

Histologic methods. Part of each biopsy was placed in 10% buffered formalin (pH 7.35) for standard paraffin

* Submitted for publication May 3, 1965; accepted November 4, 1965.

Aided by grants from the U. S. Public Health Service (AI-02168 and HE-05662), the American Heart Association, and the Cardiovascular Clinical Research Center (HE-06314).

Presented in part at the American Society for Clinical Investigation, Fifty-sixth Annual Meeting, May 4, 1964, Atlantic City, N. J. (1).

† Established Investigator, American Heart Association.

‡ Present address: Dept. of Pediatrics, McGill University, Montreal Children's Hospital, Montreal, Canada.

§ American Legion Memorial Heart Research Professor of Pediatrics and Microbiology.

Address requests for reprints to Dr. Robert A. Good, Dept. of Pediatrics, University of Minnesota Medical School, Minneapolis, Minn. 55455.

|| Established Investigator, American Heart Association.

Present address: Dept. of Pediatrics, Center for Health Sciences, University of California, Los Angeles, Calif.

embedding and sectioning and subsequently stained with hematoxylin-eosin, azocarmine, and periodic-acid Schiff. Light microscopy was carried out on 21 of the 22 biopsies. A total of 12 to 30 glomeruli were evaluated in 17 of the 21 biopsies; in each of the remaining specimens, five to six glomeruli were present.

Another portion of the biopsy specimen was immediately cut into cubes (0.5 mm³) under a drop of buffered (1%) osmic acid solution, dehydrated by standard techniques, and embedded in Vestopal-W¹ polyester resin. Sections 0.5 to 1.0 μ in thickness cut from these blocks were stained by either the Wright-Giemsa (21) or basic fuchsin method (22) and examined under oil immersion light microscopy. Very thin sections for electron microscopy were stained with either uranyl acetate (23) or lead citrate (24) and examined with either an RCA EMU-3D or a Phillips EMU-200 electron microscope at original magnifications of 2,500 to 75,000 times and enlarged photographically as desired.

Immunofluorescent methods (25-27) were carried out on renal biopsy tissue that had been frozen in isopentane in liquid nitrogen, fixed to a small cellulose sponge,² and sectioned in a Lipshaw cryostat. Fluorescent staining of unfixed tissue was carried out according to the method of Ortega and Mellors (28). In some instances an indirect technique was also employed. Inhibition of fluorescence was carried out by pretreating the section once or twice with unlabeled antiserum.

The sections were viewed in a Zeiss microscope with an HB-200 light source or a mercury lamp (GE-AHG) mounted in a Scopicon water-cooled unit. The ultra-violet activating and heat absorption filters were UG-1 and KG-1, respectively. The barrier filters consisted of OG-4 and a 2A Wratten (Kodak). Photographs were taken with an Exacta camera using Kodak Tri-X or high speed Ektachrome film. The intensity and amount of fluorescence were arbitrarily graded as negative, trace, 1+, 2+, and 3+. Six to 18 glomeruli were available for evaluation from each of the 22 biopsies.

Preparation of antisera. Antisera were prepared against the following antigens: 1) Human γ G-globulin was isolated by DEAE Sephadex A-50 chromatography;³ immunoelectrophoresis of this antigen against antihuman serum revealed a single precipitin line. 2) Human β_{1c} -globulin, a part of the third component of complement, was prepared from 400 ml of fresh human serum by the column chromatographic method of Müller-Eberhard, Nilsson, and Aronsson (29); the β_{1c} -globulin isolated formed one precipitin line with both antihuman serum and with known rabbit anti- β_{1c} -globulin serum.⁴ 3) Hu-

man fibrinogen was prepared from human Fraction I⁵ according to the method of Laki (30, 31). 4) Human fibrin was prepared from human fibrinogen; 25.0 mg of fibrinogen was diluted in isotonic saline to a final concentration of 5.0 mg per ml, and then 10.0 ml of 0.075 M sodium chloride in phosphate buffer (pH 6.1) and 0.5 ml of bovine thrombin were added. After standing for 1 hour, the clots were washed with distilled water, lyophilized, and suspended in particulate form in 0.15 M saline. Antisera were also prepared against 5) human albumin (Cohn Fraction V),⁶ 6) rabbit γ -globulin (Cohn Fraction II),⁷ and 7) heat-killed and ground-cell suspension of nephritogenic, type 1, group A, β -hemolytic streptococcus. 8) Extracellular products of the same streptococcus were prepared according to the method of Wannamaker (32) and concentrated by ammonium sulfate precipitation or by pervaporation.

Preparation of antibody. Antibody to these human antigens was prepared in rabbits. Immunizations were carried out with alum-precipitated human γ G-globulin and albumin, fibrin and β_{1c} -globulin incorporated in complete Freund's adjuvant,⁸ and a saline solution of fibrinogen. Alum-precipitated rabbit γ -globulin was injected into goats. The specificity of the antisera was shown by immunoelectrophoresis of the immunizing antigen and whole serum developed against the antisera. Antisera showing more than one major precipitin band were not used. A horse anti- γ M-globulin serum,⁹ employed in these studies, formed one major line on immunoelectrophoresis against normal serum; an additional faint line was also seen in the α_2 -globulin region.

Antisera to the various streptococcal preparations were obtained by immunizing rabbits three times weekly for a total of 2 months with 0.5 ml of antigen in solution or suspension. Antigen preparations were injected intravenously during the first month and subcutaneously during the second month of immunization. The development of antibodies to multiple antigens in these crude vaccine materials was demonstrated by the appearance of a number of lines of precipitation in a double-diffusion agar system.

The ammonium sulfate-precipitated globulins were dialyzed and then conjugated with fluorescein-isothiocyanate¹⁰ (33, 34) with 0.015 g per g of protein. The labeled antiserum was then passed through a column of Sephadex G-25 to remove the free fluorescein (35, 36). Antisera were stored as small portions at -22° C until used. Immediately before use, the antisera were ab-

¹ Martin Jaeger Co., Geneva, Switzerland.

² Onkosponge no. 1, obtained from Histomed, Paterson, N. J.

³ Some of the γ G-globulin used was obtained from Immunology, Inc., Lombard, Ill.

⁴ During the initial part of this investigation the rabbit anti- β_{1c} serum was kindly supplied by Dr. H. Müller-Eberhard, Scripps Clinic and Research Foundation, La Jolla, Calif.

⁵ Provided by the American Red Cross and Dr. Richard von Korff, Department of Biochemistry, University of Minnesota, Minneapolis, Minn.

⁶ Cutter's normal human serum albumin, Cutter Laboratories, Berkeley, Calif.

⁷ Rabbit γ -globulin (Fraction II), Nutritional Biochemical Corp., Cleveland, Ohio.

⁸ Difco Laboratories, Detroit, Mich.

⁹ Hyland Laboratories, Los Angeles, Calif.

¹⁰ Baltimore Biological Laboratories, Baltimore, Md.

TABLE I
Fluorescent and electron microscopic observations of the kidney in 16 patients with acute glomerulonephritis

Patient	Biopsy no.	Interval from onset to biopsy	Fluorescent microscopy					Electron microscopy		
			Nodular deposits demonstrated in glomerulus by fluorescent antibody technique*					Electron-dense deposits in glomerulus		
			γ G-globulin†	β 2c-globulin		Albumin	Fibrin	γ M-globulin	Basement membrane	Epithelial
		days		Direct‡	Indirect					
1	I	7	Trace	3+	3+	Negative			Many	Many
2	I	7	3+ (inh)	3+	3+	Negative		Negative	Many	Few
3	I	8	3+ (inh)	3+	3+	Negative	2+	Negative	Many	Few
4	I	8	Negative	3+	3+	Negative	Negative	Negative	Few	Many
5	I	13	2+ (inh)	3+	3+	Negative	1+	Negative	Irregularly thickened	Resolving
	II	193	Negative	Negative			Negative			
6	I	19	Trace (inh)	3+	3+				Irregularly thickened	Many
	II	184	Negative	Negative	Negative				Irregularly thickened	Rare
7	I	19	2+							
8	I	20	3+ (inh)		3+					
9	I	22	Negative	2+	3+					
10	I	23	3+ (inh)	2+	3+	Negative	Trace-focal	Negative		Few
	II	52	3+ (inh)	2+	3+		Negative	Negative	Many	Few resolving
	III	112	1+	Trace						
	IV	272	Trace-focal	Negative						
11	I	23	2+ (inh)	2+						
12	I	26	3+ (inh)	3+	3+	Negative	Negative	Negative	Thickened with deposits	Few
	II	198	1+ Focal and local (inh)	1+		Negative	Negative			
13	I	41	Negative	3+		Negative		Negative		
14	I	41	3+ (inh)	3+	3+	Negative	2+		Thickened with deposits	Rare
15	I	60	Negative	1+	2+	Negative	1+			
16	I	70	1+ Focal and local	2+	2+					

* Rabbit antisera to γ G-globulin, β 2c-globulin, albumin, and fibrin were labeled with fluorescein-isothiocyanate and used directly. In some instances an indirect technique was also used by overlaying the tissue with unlabeled rabbit anti- β 2c-globulin followed by fluorescein-labeled goat antirabbit γ -globulin; the labeled goat antirabbit γ -globulin control was negative in each instance. The fluorescence was inhibited by the prior application of unlabeled antiserum.

† inh = fluorescence inhibited by first overlaying tissue with unlabeled rabbit anti- γ G-globulin.

‡ The appearance of fluorescence with labeled anti- γ G-globulin and anti- β 2c-globulin was primarily discrete and nodular in all patients except 10, 12, and 14. In these patients fluorescence was seen in both a linear and nodular distribution along the basement membrane.

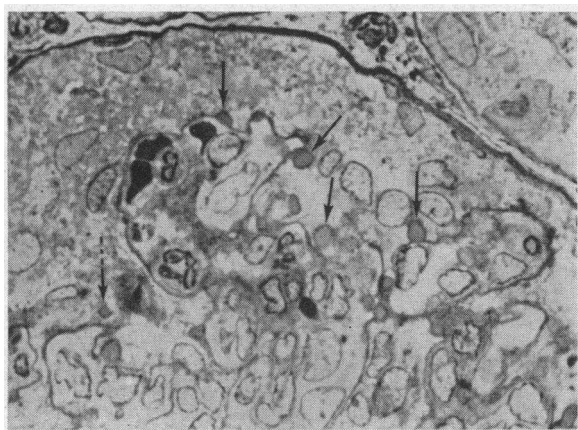

FIG. 1. THIN SECTION ($.5 \mu$) OF RENAL TISSUE OBTAINED FROM PATIENT 6, 19 DAYS AFTER ONSET OF ACUTE GLOMERULONEPHRITIS, SHOWING A SEGMENT OF THE GLOMERULUS. Discrete deposits are visible along the epithelial surface of the basement membrane (arrows) or appear to lie in the epithelium (dotted arrow). (Wright-Giemsa $\times 900$.)

sorbed twice with mouse liver powder.¹⁰ Labeled antisera having low fluorescein to protein ratios were used as recommended by Goldstein, Slizys, and Chase (37) and Frommhagen and Martins (38).

Results

I) Light microscopy

Light microscopy of standard $4\text{-}\mu$ sections in all patients showed findings characteristic of acute poststreptococcal glomerulonephritis: glomerular endothelial proliferation, decreased erythrocytes in the glomeruli, polymorphonuclear leukocyte infiltration, segmentation, and in some cases crescents.

Thin sections (Patients 1 to 4, 6, 10, 12). Although nodular masses seen along the basement membrane of glomerular capillaries of fluorescent and electron microscopy (see below) were not visible in routine $4\text{-}\mu$ sections because of thickness of the tissue, these masses could be resolved by light microscopy with thinner sections. Examination of sections of 0.5 to 1.0μ , cut from plastic blocks embedded for electron microscopy, disclosed nodular masses along the basement membranes (Figure 1). Variable numbers of these masses were seen in seven of seven cases (1 to 4, 6, 10, 12) studied by this technique. The masses stained somewhat differently from the membrane itself. With Wright-Giemsa stain, the masses were a deeper blue than the basement membrane proper.

With the basic fuchsin technique the nodules were pale red or pink, whereas the basement membrane proper was intensely red.

II) Fluorescent microscopy

A) *Acute glomerulonephritis.* The glomerular deposition of γ G- and β_{10} -globulins is summarized

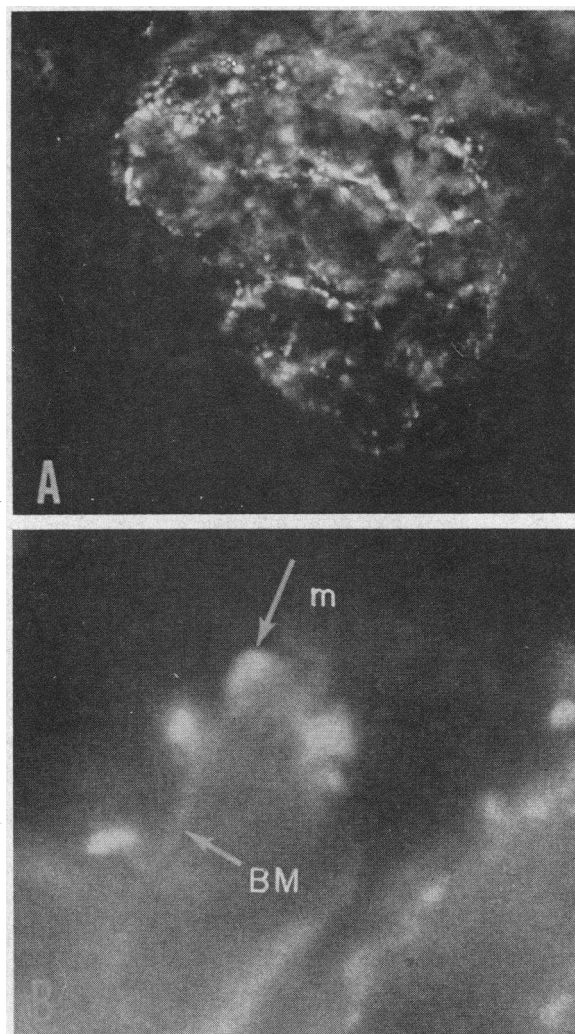


FIG. 2. RENAL BIOPSY OBTAINED FROM PATIENT 11, 23 DAYS AFTER ONSET. A) Discrete linear deposits of γ G-globulin are present throughout the glomerulus. A similar morphologic picture is seen when the tissue is stained with fluorescein-conjugated rabbit anti- β_{10} -globulin. (Fluorescent microscopy $\times 350$.) B) Small segment of a glomerular capillary loop showing immune masses (m) of γ G-globulin along the epithelial surface of the basement membrane (BM). The basement membrane stains weakly. The deposits in this photograph are 2 to 4μ in diameter. (Fluorescent microscopy $\times 2,200$.)

in Table I. In 12 of 16 patients, γ G-globulin was demonstrated in the glomeruli of the initial biopsy; β_{1C} -globulin was detected in glomeruli of all patients. Typically, the fluorescence was discrete and nodular, scattered diffusely throughout the glomeruli (Figure 2A); linear areas of basement membrane and mesangial fluorescence were also seen, especially in patients with more severe disease (Patients 10, 12, 14) or patients biopsied later in convalescence, but this morphologic distribution was less frequent. In glomeruli from some patients the fluorescent masses approached the size of erythrocytes and in some areas seemed to be fused with other masses in a local distribution sparing parts of the glomerulus. In tissue from other patients the nodules were smaller and gave a speckled appearance to the glomerulus at these magnifications. The deposits appear to follow the course of the glomerular capillary walls at higher magnification, and in glomeruli from some patients the immune desposits clearly were present on the epithelial surface of the glomerular basement membrane (Figure 2B). There was no evidence that the fluorescence represented nuclear, cytoplasmic, or cellular staining. Gamma G-globulin was not present on the glomeruli in Patients 4, 9, 13, and

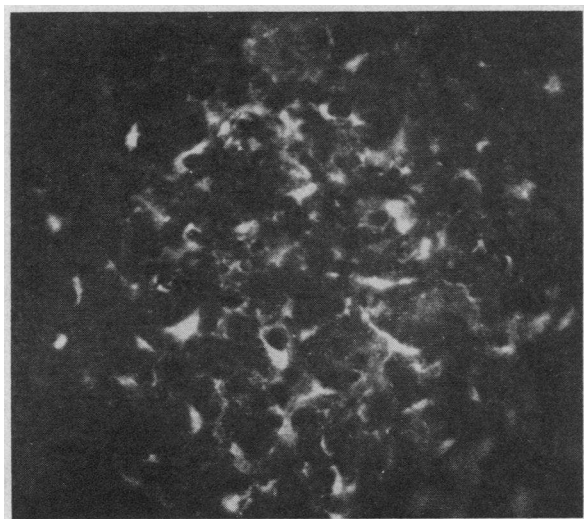


FIG. 3. RENAL TISSUE FROM PATIENT 3, 8 DAYS AFTER ONSET, STAINED WITH FLUORESCIN-LABELED RABBIT ANTI-HUMAN FIBRIN SERUM. The exact localization in the glomerulus cannot be determined although the fibrin is probably present within Bowman's space or along the basement membrane; it is not deposited in the nodular form seen with γ G- or β_{1C} -globulins (cf. Figure 2). (Fluorescent microscopy $\times 350$.)

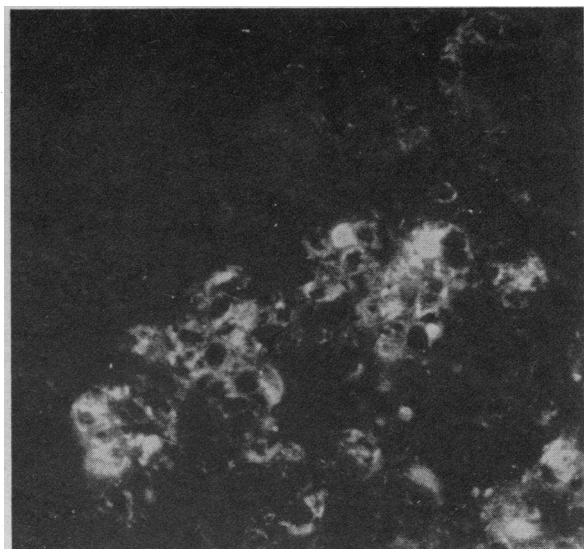


FIG. 4. TISSUE SHOWING A PORTION OF A GLOMERULUS OBTAINED FROM PATIENT 3, 8 DAYS AFTER ONSET OF ACUTE GLOMERULONEPHRITIS, STAINED WITH FLUORESCIN-CONJUGATED RABBIT ANTIBODY AGAINST A GROUND-CELL PREPARATION OF A NEPHRITOGENIC TYPE 1, GROUP A, β -HEMOLYTIC STREPTOCOCCUS. The discrete fluorescence cannot be anatomically localized with respect to the basement membrane, but appears to be present between cells or within the cytoplasm. (Fluorescent microscopy $\times 350$.)

15. In these patients considerable amounts of β_{1C} -globulin were observed as discrete nodules.

Beta $_{1C}$ -globulin was also demonstrated by an indirect technique in nine patients so studied, but when this method was used, the fluorescence was more linear in appearance than when the direct technique was used.

In Patient 10, the amounts of γ G- and β_{1C} -globulins were decreased at 112 days. At 272 days, only trace amounts of γ G-globulin were noted on the glomeruli in focal distribution, but no β_{1C} -globulin could be detected. The tissues from Patients 5 and 6, 193 and 184 days after onset, demonstrated neither β_{1C} - nor γ G-globulin. Slight local and focal deposition of both γ G and β_{1C} was observed in tissue obtained from Patient 12, 198 days after onset.

The specificity of the fluorescence was confirmed by inhibition of fluorescence with unlabeled anti-serum to γ G-globulin in 11 of 11 instances, by inhibition of fluorescence with antiserum to β_{1C} -globulin, and by negative fluorescence for human albumin in eight of eight preparations. No γ M-

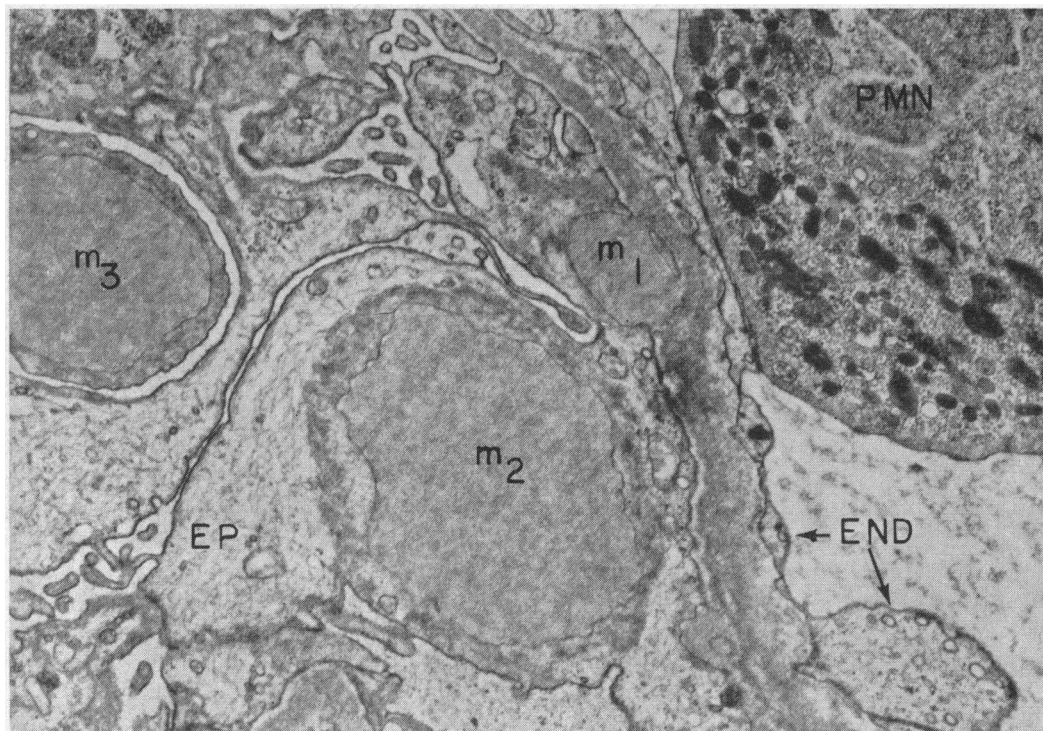


FIG. 5. ELECTRON MICROGRAPH OF A SMALL PORTION OF A GLOMERULUS FROM PATIENT 4, ILLUSTRATING THE FREQUENCY AND VARIABILITY OF FORM OF DENSE IMMUNE DEPOSITS. m_1 (m = electron dense masses) appears to be attached to the basement membrane, which is more dense than normal in the area of attachment. A polymorphonuclear leukocyte (PMN) is adjacent to the endothelium at this site. m_2 and m_3 appear to lie entirely within the epithelial cell although this is not proven. Note the dense halo of cytoplasmic material around m_2 . EP = epithelial cell; END = endothelial cell. ($\times 16,500$.)

globulin could be shown in the glomeruli of six patients so studied.

Fibrin was observed in the glomeruli of initial biopsy specimens from five of eight patients; however, the distribution of the fluorescence differed from the nodular distribution observed with γ G- or β_{1C} -globulins (Figure 3). The pattern of fibrin deposition was often ribbon-like as though it were present within Bowman's space, along the basement membrane, or within the capillary lumen.

In ten patients (No. 2 to 6, 10 to 12, 13, 15) the tissue was stained with fluorescein-conjugated globulin against two cellular preparations of a nephritogenic type 1, group A, β -hemolytic streptococcus: a heat-killed and a ground-cell suspension.¹¹ Definite discrete glomerular fluores-

cence was present in Patients 2 and 3 when either antiserum was used (Figure 4); this was inhibited by the prior application of unlabeled antisera. A trace of fluorescence was also seen in the glomeruli of Patient 4, but none was seen in the other patients. It was not possible to localize exactly the fluorescence with respect to the glomerular basement membrane, although no discrete nodules were seen. Fluorescein-conjugated globulin against the extracellular streptococcal products failed to show localization in Patients 2, 3, 4, 5, and 10; the remainder of the patients were not evaluated with this antiserum because of lack of tissue. Fluorescent antibody against the ground-cell preparation

¹¹ These studies were done in collaboration with Dr. Lewis W. Wannamaker under the sponsorship of the Commission on Streptococcal and Staphylococcal Diseases,

Armed Forces Epidemiological Board. The support of the offices of the Surgeon General, Department of the Army, Washington, D. C., and of the American Heart Association (Dr. Wannamaker, Career Investigator) in this collaborative effort is hereby acknowledged.

of type 1 streptococcus showed no glomerular staining in kidney tissue obtained from patients with the nephrotic syndrome (2), chronic glomerulonephritis (2), subacute glomerulonephritis (1), and diabetes mellitus (1), or in a normal individual (1).

B) Ten years after acute glomerulonephritis. Renal biopsies from 14 patients who had had acute poststreptococcal glomerulonephritis 10 years previously were examined for the presence of γ G- or β_{10} -globulins. All had normal renal function. The Addis counts in these patients were slightly abnormal, but the frequency of this abnormality was not significantly different from that of a control Indian population with no history of glomerulonephritis (20).

In 11 biopsies no glomerular deposition of γ G- or β_{10} -globulins was found; nine of these biopsies showed normal histology, but two showed mild focal and local glomerular abnormalities. In three biopsies, there was focal and local deposition of γ G- and β_{10} -globulins along the basement membrane of approximately one-half of the glomeruli; the deposition was restricted to small loci and represented a very small area of the glomerulus. Histologically, two of these biopsies also showed mild focal and local glomerular abnormalities, and one was normal. No immune complex type of deposition resembling that found during acute glomerulonephritis was seen.

III) Electron microscopy

Two to four glomeruli in each of 11 renal biopsy specimens from 9 of the 16 patients included in this report were studied by electron microscopy.

The ultrastructural changes within glomeruli of the patients fell roughly into two patterns, each related to the interval between onset of clinical disease and renal biopsy.

A) Electron microscopic findings in six renal biopsy specimens obtained 7 to 26 days after onset (Patients 1 to 4, 6, 12). The prominent abnormalities of ultrastructure in these biopsies included (Figures 5 and 6) 1) an increase in volume of low density cytoplasmic material of luminal endothelial cells (endothelial swelling); 2) an increased number of cells identified as either luminal endothelial cells (endothelial proliferation) or centrollobular cells (mesangial cells); 3) a striking in-

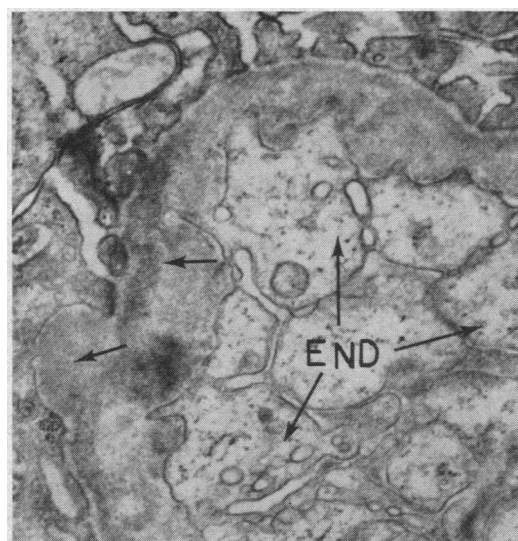


FIG. 6. TYPICAL EARLY CHANGES IN ENDOTHELIAL CELLS AND BASEMENT MEMBRANE IN PATIENT 3. The lumen of this capillary is obliterated by blebs of endothelium. Densely stained material (arrows) lies within the basement membrane and bulges outward toward the epithelium in one area. ($\times 25,700$.)

crease in the number of polymorphonuclear leukocytes within the glomerular capillary lumina usually adjacent to the dense deposits within the basement membrane or opposite nodules on the epithelial side of the basement membrane; 4) irregular circumscribed and linear areas of increased density within the basement membrane with occasional zones of thinning of the lamina densa or irregular scalloped thickening (these were especially prominent in Patients 2, 3, and 12); and 5) numerous dense, homogeneous, spherical deposits that projected from the epithelial side of the basement membrane. The smaller masses often indented the lamina densa of the basement membrane (Figure 5) and appeared to lie wholly within the basement membrane. These ovoid bodies were always more densely stained with lead citrate or uranyl acetate than the lamina densa. The larger masses were pedunculated and attached to the basement membrane by a narrow base that fused with the lamina densa. Other larger spheres often appeared to lie entirely within the epithelial cell although this is uncertain since serial sections would be needed to establish this point. Rarely, dense granular material could be observed within endothelial cytoplasmic vacuoles.

B) *Electron microscopic findings in five kidney biopsy specimens obtained 1 month or more after onset (biopsy 2 from Patients 5, 6, and 14 and biopsies 2 and 3 from Patient 10).* The electron microscopic findings in the group were similar to those described above except that the amount of

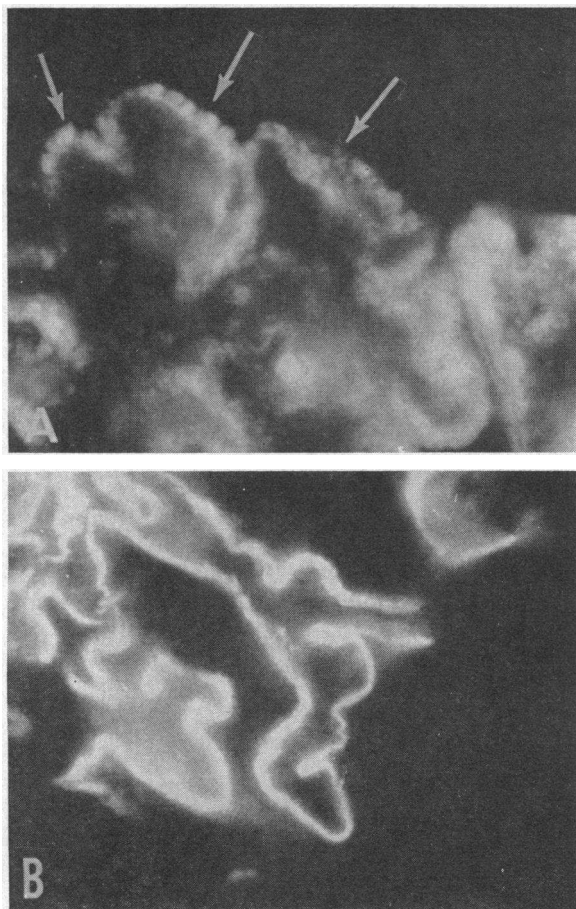


FIG. 7. A) TISSUE OBTAINED FROM A 15-YEAR-OLD MALE DURING THE COURSE OF SEVERE LUPUS NEPHRITIS. Fluorescent microscopy of a segment of a glomerulus reveals the presence of γ G-globulin along the glomerular basement membrane. Deposits are primarily along the epithelial side of the basement membrane (arrows), but are also present within it. Beta_{1c}-globulin was present in a similar distribution. Compare with electron microscopic appearance in Figure 8.

B) TISSUE OBTAINED FROM A 26-YEAR-OLD MAN WITH GOODPASTURE'S DISEASE. Gamma G-globulin is present within the glomerular basement membrane giving a diffuse linear pattern. No isolated or discrete extramembranous deposits are seen. Beta_{1c}-globulin was present in a similar distribution. Compare with electron microscopic appearance in Figure 8. (Fluorescent microscopy $\times 875$.)

dense material was decreased, and there were fewer deposits within the basement membrane. Nodular masses, where present, appeared to be within enlarged epithelial cells that contained numerous dilated cisternae and a decreased number of mitochondria and lysosomes. A dense granular layer of material approximately 200 Å in thickness surrounded the nodular deposits and appeared to blend into the epithelial cytoplasm. The basement membrane from later biopsy specimens showed focal areas of thickening alternating with areas of normal thickness and density. Glomeruli from two biopsy specimens (Patients 5 and 6), obtained 6 months after onset of the disease, demonstrated only an occasional nodular mass that appeared to be entirely within the epithelial cell; there was also an increase in membranous (stalk) material.

IV) *Comparison of the immunofluorescent and ultramicroscopic morphology of acute glomerulonephritis with other renal diseases*

A nodular deposition of γ G- and β_{1c} -globulins has also been seen in tissue from certain patients with chronic glomerulonephritis and systemic lupus erythematosus (SLE). In the latter disease large amounts of immune-complex deposits may be present within or beneath the glomerular basement membrane or projecting from its epithelial surface (Figure 7A). Electron microscopy of a similarly involved glomerulus from the same patient reveals numerous irregular dense masses within and projecting from the epithelial side of the basement membrane (Figure 8A). These masses are very different from the nodules described in acute glomerulonephritis in that the lesions observed in SLE are less compact, are rarely pedunculated, and have not been observed as nodules entirely within the visceral epithelium.

In other diffuse glomerular diseases such as certain types of chronic glomerulonephritis and Goodpasture's disease, no nodules or masses are seen by light or fluorescent microscopy. Figure 7B illustrates the fluorescent microscopic appearance of the glomerulus in a patient with Goodpasture's disease. The fine linear basement membrane fluorescence is due to γ -globulin deposition in the basement membrane, which is uniformly thickened and without nodules when viewed un-

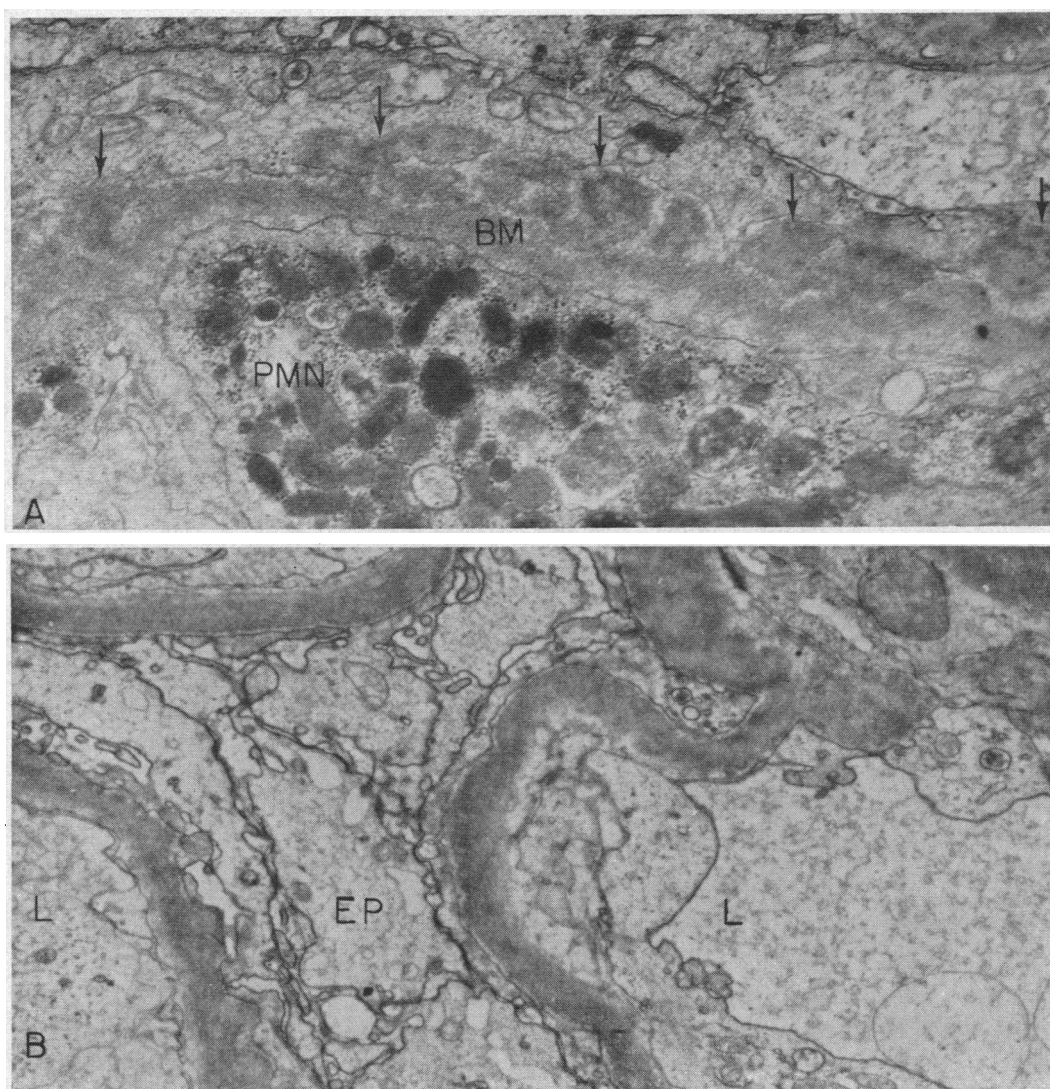


FIG. 8. SECTIONS OF TYPICAL GLOMERULAR CAPILLARIES FROM A) A PATIENT WITH SYSTEMIC LUPUS ERYTHEMATOSUS (SLE) AND B) A PATIENT WITH PULMONARY HEMORRHAGE AND GLOMERULONEPHRITIS (GOODPASTURE'S SYNDROME). Mottled density within the basement membrane and loosely packed nodular masses (arrows) on the epithelial side of the basement membrane are features of the ultrastructural pathology in SLE. Compare with Figure 7. In Goodpasture's syndrome the basement membrane is diffusely and rather uniformly infiltrated with electron dense material (γ -globulin). Compare with Figure 7. L = capillary lumen. (A, $\times 26,000$; B, $\times 18,000$.)

der the electron microscope (Figure 8B). This picture stands in sharp contrast to the morphologic appearance of the glomerulus in acute poststreptococcal glomerulonephritis.

Discussion

Strict criteria for the diagnosis of acute poststreptococcal glomerulonephritis in 16 of our patients included a characteristic clinical picture,

evidence of preceding streptococcal infection, and characteristic renal morphology. The salient finding was the presence of discrete nodular deposits of either β_{1c} - or γ G-globulin, or both, in the glomeruli of all 16 patients with acute disease and the correlation of this type of deposition with densities, similar in conformation and location, in electron microscopy and thin section microscopy of tissue from the same biopsies. These deposits are

characteristic of the disease. In a few patients with severe disease, a prominent diffuse linear basement membrane and mesangial fluorescence was also observed. During convalescence, the immune-complex deposits were either not present at all or in minimal quantity by fluorescence microscopy and seemed to be resolving in the few patients studied by electron microscopy. In these late specimens the densities seemed to be entirely within the epithelial cells and showed changes interpretable of ongoing lysis.

This lesion is morphologically distinct from the diffuse linear distribution of γ -globulin and complement observed by fluorescent microscopy within glomerular basement membrane in Goodpasture's disease and in some patients with chronic glomerulonephritis, in which no discrete deposits are present. Nodular basement membrane fluorescence has also been observed in disseminated lupus erythematosus and in some cases of chronic glomerulonephritis (39); however, the γ G and β_{1C} are not as discretely deposited.

β_{1C} -globulin was demonstrated more consistently in the glomeruli of patients than was γ G-globulin, which was not demonstrable even in trace amounts in four children. This may be analogous to the non- γ -globulin Coombs' test in certain hemolytic anemias where complement or its components, and not γ -globulin, may be found on the red cell surface (40, 41). Leddy, Hill, Swisher, and Vaughan (41) have suggested that the γ -globulin is present, but sterically hindered from reacting with its homologous antiserum, or that γ -globulin has in fact dissociated from the cell leaving complement behind. It may also be that the location of the deposit in some way determines detectability of the γ -globulin.

The closest experimental analogue to the lesions in acute poststreptococcal glomerulonephritis is antigen-antibody complex nephritis, as observed by Dixon, Feldman, and co-workers (42-45). Our own studies (3) and those of Germuth and McKinnon (46, 47) support the concept that the lesions of serum sickness reflect the toxicity of these complexes, which are also complement fixing. Light microscopy of the kidney in rabbits with experimental serum sickness shows acute proliferative glomerulonephritis and vasculitis, and electron microscopy reveals swelling and proliferation of the endothelial cells and deposition of elec-

tron-dense material adjacent to and within the glomerular basement membrane (42-44). Ferritin-labeled studies have shown that these deposits contain bovine serum albumin (antigen) and rabbit γ -globulin (antibody) (48). The discrete nodular fluorescent and electron microscopic appearance of these nodular masses on the epithelial side of the basement membrane in acute serum sickness in rabbits is indistinguishable from the renal lesion of acute poststreptococcal glomerulonephritis in children (49).

Although the exact mechanism of production of acute glomerulonephritis is speculative, the sequence of events may be similar to that occurring in experimental antigen-antibody complex disease. The presence of streptococcal antigen in the glomeruli of some patients with this disease tends to support but does not prove the antigen-antibody complex hypothesis.

Although the deposits of acute glomerulonephritis bear similarities to those of lupus nephritis and some forms of chronic glomerulonephritis, there are differences. In acute nephritis the deposits tend to be discrete and appear to be present wholly within the epithelial cell; in the other diseases, the nodular deposits may be located entirely within the basement membrane, as in some cases of chronic glomerulonephritis (39); the electron-dense material or γ G- and β_{1C} -globulins may also appear as a linear density within the basement membrane without extramembranous deposits as in Goodpasture's disease. The appearance of the glomeruli on immunofluorescent staining of the biopsies in the latter disease is identical to that previously shown to be characteristic of nephrotoxic serum nephritis (3). In acute nephritis there is little distortion or disruption of the basement membrane, and the masses are not usually trapped or incorporated within the basement membrane; in the other diseases the basement membrane is extensively involved and becomes thickened and distorted.

Summary

1. A coordinate study of the light, immunofluorescent, and electron microscopy of the kidney was carried out in 16 children with acute poststreptococcal glomerulonephritis.

2. Discrete deposits of β_{1C} -globulin or γ G-globulin or both were present within and along the epi-

thelial surface of the glomerular basement membrane during the acute phase of the disease. By electron and thin section microscopy, these immune deposits were shown as dense masses lying on the epithelial surface of the basement membrane, and rarely within the endothelial cell. This discrete deposition of γ G- and β_{10} -globulins is morphologically distinct from other glomerular diseases. Correlative experimental evidence indicates that these deposits represent immune aggregates, probably antigen-antibody complexes. In three of ten patients streptococcal cell antigen was also present in the glomerulus.

3. The amount of γ G- and β_{10} -globulin in the glomeruli decreased markedly or disappeared in four patients studied up to 9 months after onset.

4. Immunofluorescent studies on kidney tissue obtained from 14 patients 10 years after epidemic acute poststreptococcal glomerulonephritis reveals no deposition in 11 and minimal abnormalities in 3.

Acknowledgments

We appreciate the thoughtful editorial assistance of Miss Ann Gabrielsen.

References

1. Michael, A. M., K. N. Drummond, R. A. Good, and R. L. Vernier. Immunoglobulins: clarification of their significance in renal disease and demonstration of response to immunosuppressive therapy (abstract). *J. clin. Invest.* 1964, **43**, 1291.
2. Schick, B. Die Nachkrankheiten des Scharlach. *Jb. Kinderheilk.* 1907, **65**, 132.
3. Michael, A. F., K. N. Drummond, R. L. Vernier, and R. A. Good. Immunologic basis of renal disease. *Pediat. Clin. N. Amer.* 1964, **11**, 685.
4. Taft, L. I., J. K. Dineen, and I. R. Mackay. The localization and binding of serum proteins in the glomeruli of kidney biopsies in disseminated lupus erythematosus and glomerulonephritis. *Aust. Ann. Med.* 1958, **7**, 5.
5. Freedman, P., J. H. Peters, and R. M. Kark. Localization of gamma-globulin in the diseased kidney. *Arch. intern. Med.* 1960, **105**, 524.
6. Freedman, P., and A. S. Markowitz. Gamma globulin and complement in the diseased kidney. *J. clin. Invest.* 1962, **41**, 328.
7. Seegal, B. Fluorescent antibody studies of human glomerulonephritis in Hereditary, Developmental, and Immunologic Aspects of Kidney Disease, J. Metcalf, Ed. Evanston, Northwestern University Press, 1962, p. 148.
8. Lachmann, P. J., H. J. Müller-Eberhard, H. G. Kunkel, and F. Paronetto. The localization of in vivo bound complement in tissue sections. *J. exp. Med.* 1962, **115**, 63.
9. Koffler, D., and F. Paronetto. Immunofluorescent localization of immunoglobulin, complement, and fibrinogen in human disease. II. Acute, subacute, and chronic glomerulonephritis. *J. clin. Invest.* 1965, **44**, 1665.
10. Seegal, B. C., G. A. Andres, K. C. Hsu, and J. B. Zabriskie. Studies on the pathogenesis of acute and progressive glomerulonephritis in man by immunofluorescein and immunoferritin techniques. *Fed. Proc.* 1965, **24**, 100.
11. Steiner, J. W., and R. Volpe. Autoimmunization—a possible mechanism of tissue injury. III. Clinical aspects of autoimmunity. *Canad. med. Ass. J.* 1961, **84**, 1297.
12. Movat, H. Z., J. W. Steiner, and D. Huhn. The fine structure of the glomerulus in acute glomerulonephritis. *Lab. Invest.* 1962, **11**, 117.
13. Kimmelstiel, P., O. J. Kim, and J. Beres. Studies on renal biopsy specimens, with the aid of the electron microscope. II. Glomerulonephritis and glomerulonephrosis. *Amer. J. clin. Path.* 1962, **38**, 280.
14. Trump, B. F., and E. P. Benditt. Electron microscopic studies of human renal disease. Observations of normal visceral glomerular epithelium and its modification in disease. *Lab. Invest.* 1962, **11**, 753.
15. Churg, J., W. Mautner, E. Grishman, and G. M. Eisner. Structure of glomerular capillaries in proteinuria. *Arch. intern. Med.* 1962, **109**, 97.
16. Movat, H. Z., J. W. Steiner, and R. J. Slater. The fine structure of the glomerulus in Bright's disease: a clinico-pathological study in Ciba Foundation Symposium on Renal Biopsy, G. E. W. Wolstenholme and M. P. Cameron, Eds. London, J. and A. Churchill, 1961, p. 103.
17. Strunk, S. W., W. S. Hammond, and E. P. Benditt. The resolution of acute glomerulonephritis. An electron microscopic study of four sequential biopsies. *Lab. Invest.* 1964, **13**, 401.
18. Farquhar, M. G., R. L. Vernier, and R. A. Good. An electron microscope study of the glomerulus in nephrosis, glomerulonephritis, and lupus erythematosus. *J. exp. Med.* 1957, **106**, 649.
19. Vernier, R. L. Kidney biopsy in the study of renal disease. *Pediat. Clin. N. Amer.* 1960, **7**, 353.
20. Perlman, L. V., R. C. Herdman, H. Kleinman, and R. L. Vernier. Poststreptococcal glomerulonephritis: a ten year follow-up of an epidemic. *J. Amer. med. Ass.* 1965, **194**, 63.
21. Condie, R. M., R. Y. Tousignant, and R. A. Good. Rapid staining of osmic acid-fixed methacrylate-embedded tissue sections for light microscopy. *Anat. Rec.* 1958, **130**, 399.
22. Chandra, S., and F. R. Skelton. Staining juxtaglomerular cell granules with toluidine blue or with basic fuchsin for light microscopy after Epon embedding. *Stain Technol.* 1964, **39**, 107.

23. Watson, M. L. Staining of tissue sections for electron microscopy with heavy metals. *J. biophys. biochem. Cytol.* 1958, **4**, 475.
24. Reynolds, E. S. The use of lead citrate of high pH as an electron-opaque stain in electron microscopy. *J. Cell Biol.* 1963, **17**, 208.
25. Coons, A. H., and M. H. Kaplan. Localization of antigen in tissue cells. II. Improvements in a method for the detection of antigen by means of fluorescent antibody. *J. exp. Med.* 1950, **91**, 1.
26. Coons, A. H. Fluorescent antibody methods in *General Cytochemical Methods*, J. F. Danielli, Ed. New York, Academic Press, 1958, vol. 1, p. 399.
27. Mellors, R. C. Fluorescent antibody-method in *Analytical Cytology*, R. C. Mellors, Ed. New York, McGraw-Hill, 1959, p. 1.
28. Ortega, L. G., and R. C. Mellors. Analytical pathology. IV. The role of localized antibodies in the pathogenesis of nephrotoxic nephritis in the rat. *J. exp. Med.* 1956, **104**, 151.
29. Müller-Eberhard, H. J., U. Nilsson, and T. Aronsson. Isolation and characterization of two β_2 -glycoproteins of human serum. *J. exp. Med.* 1960, **111**, 201.
30. Laki, K. The polymerization of proteins: the action of thrombin on fibrinogen. *Arch. Biochem.* 1951, **32**, 317.
31. Mills, D. A., R. Coyne, B. Pollara, and R. W. von Korff. The action of plasmin on fibrinogen and fibrin. I. Changes in the N-terminal residues. *Biochim. biophys. Acta (Amst.)* 1964, **86**, 527.
32. Wannamaker, L. W. Electrophoretic studies of the extracellular products of group A streptococci. *J. exp. Med.* 1958, **107**, 783.
33. Marshall, J. D., W. C. Eveland, and C. W. Smith. Superiority of fluorescein isothiocyanate (Riggs) for fluorescent-antibody technic with a modification of its application. *Proc. Soc. exp. Biol. (N. Y.)* 1958, **98**, 898.
34. Riggs, J. L., R. J. Seiwald, J. H. Burckhalter, C. M. Downs, and T. G. Metcalf. Isothiocyanate compounds as fluorescent labeling agents for immune serum. *Amer. J. Path.* 1958, **34**, 1081.
35. Fothergill, J. E., and R. C. Nairn. Purification of fluorescent protein conjugates: comparison of charcoal and "Sephadex." *Nature (Lond.)* 1961, **192**, 1073.
36. George, W., and K. W. Walton. Purification and concentration of dye-protein conjugates by gel filtration. *Nature (Lond.)* 1961, **192**, 1188.
37. Goldstein, G., I. S. Slizys, and M. W. Chase. Studies on fluorescent antibody staining. I. Non-specific fluorescence with fluorescein-coupled sheep antirabbit globulins. *J. exp. Med.* 1961, **114**, 89.
38. Frommhagen, L. H., and M. J. Martins. A comparison of fluorescein-labeled γ -globulins purified by rivanol and DEAE chromatography. *J. Immunol.* 1963, **90**, 116.
39. Michael, A. F. Unpublished observations.
40. Müller-Eberhard, H. J. Identification of complement antigens coating red cells in acquired hemolytic anemia in *Immunopathology*, Third International Symposium, P. Grabar and P. A. Miescher, Eds. Basel, Schwabe, 1963, p. 332.
41. Leddy, J. P., R. W. Hill, S. N. Swisher, and J. H. Vaughan. Observations on the immunochemical nature of red cell autosensitization in *Immunopathology*, Third International Symposium, P. Grabar and P. A. Miescher, Eds. Basel, Schwabe, 1963, p. 318.
42. Dixon, F. J., J. D. Feldman, and J. J. Vazquez. Experimental glomerulonephritis. The pathogenesis of a laboratory model resembling the spectrum of human glomerulonephritis. *J. exp. Med.* 1961, **113**, 899.
43. Feldman, J. D. Electron microscopy of serum sickness nephritis. *J. exp. Med.* 1958, **108**, 957.
44. Feldman, J. D. Pathogenesis of ultrastructural glomerular changes induced by immunologic means in *Immunopathology*, Third International Symposium, P. Grabar and P. Miescher, Eds. Basel, Schwabe, 1963, p. 263.
45. Dixon, F. J., J. J. Vazquez, W. O. Weigle, and C. G. Cochrane. Pathogenesis of serum sickness. *Arch. Path.* 1958, **65**, 18.
46. Germuth, F. G., Jr. A comparative histologic and immunologic study in rabbits of induced hypersensitivity of the serum sickness type. *J. exp. Med.* 1953, **97**, 257.
47. Germuth, F. G., Jr., and G. E. McKinnon. Studies on the biological properties of antigen-antibody complexes. I. Anaphylactic shock induced by soluble antigen-antibody complexes in unsensitized normal guinea pigs. *Bull. Johns Hopk. Hosp.* 1957, **101**, 13.
48. Andres, G. A., B. C. Seegal, K. C. Hsu, M. S. Rothenberg, and M. L. Chapeau. Electron microscopic studies of experimental nephritis with ferritin-conjugated antibody. *J. exp. Med.* 1963, **117**, 691.
49. Fish, A., A. F. Michael, R. L. Vernier, and R. A. Good. Correlation of experimental serum sickness nephritis with acute post-streptococcal glomerulonephritis in man, Seventeenth Annual Conference on the Kidney, J. Metcalf, Ed. Warrenton, Va., 1965, in press.