

Immunofluorescent Localization of Immunoglobulins, Complement, and Fibrinogen in Human Diseases. II. Acute, Subacute, and Chronic Glomerulonephritis *

DAVID KOFFLER † AND FIORENZO PARONETTO ‡

(From the Department of Pathology, The Mount Sinai Hospital, New York, N. Y.)

Gamma globulin and complement have been demonstrated in renal glomeruli of patients with glomerulonephritis (1-10). Certain problems, which are the subject of the present investigation, remain to be elucidated: 1) the type of immunoglobulin (γ_2 , γ_{1M} , or γ_{1A}) present in the renal lesion and its relation to complement localization; and 2) the significance of fibrinogen localization. Kidneys from patients with acute, subacute, and chronic glomerulonephritis were examined by the fluorescent antibody technique to assess the nature of protein deposition in the renal parenchyma.

Methods

Specimens from 17 patients with acute, subacute, and chronic glomerulonephritis were quick-frozen in dry ice and isopentane at -70°C . The methods of tissue fixation, preparation of fluoresceinated antisera, and fluorescence microscopy have been described in a previous paper (11). Histological examination was performed on paraffin sections stained with hematoxylin and eosin and subjected to the periodic acid Schiff reagent after diastase treatment. Phosphotungstic acid hematoxylin (PTAH) and Lendrum stains for detection of fibrin were also employed.

Major clinical and pathological findings pertinent to the present study are summarized in Table I. Any patient with clinical symptoms suggestive of systemic lupus erythematosus (SLE) was excluded. All patients with subacute and chronic glomerulonephritis were uremic and hypertensive on their final admissions to the hospital, except for two patients (No. 5 and 16). Autopsy tissues were obtained in all cases except for renal biopsies obtained in three patients with acute glomerulonephritis.

* Submitted for publication March 31, 1965; accepted June 28, 1965.

This investigation was supported by U. S. Public Health Service grants AM-07790, AM-03846, and AM-20199.

† Research fellow, U. S. Public Health Service.

‡ Address requests for reprints to Dr. Fiorenzo Paronetto, The Mount Sinai Hospital, 100th St. and Fifth Ave., New York, N. Y. 10029.

Acute glomerulonephritis. Patients 1 and 2 showed acute proliferative glomerulonephritis with marked swelling and proliferation of glomerular capillary endothelium. Focal hemorrhage was noted in Bowman's space and within tubules. Patients 3 and 4 revealed a milder degree of glomerular endothelial swelling and proliferation without hemorrhage.

Subacute glomerulonephritis. All patients exhibited diffuse proliferative glomerulonephritis with extensive crescent formation and occasional partially hyalinized glomerular tufts. There were intimal proliferation and thickening of medium sized arterioles. In Patient 6, segmental fibrinoid necrosis and hemorrhage were found in the media of several arterioles.

Chronic glomerulonephritis. All patients revealed moderate to severe sclerosing glomerulonephritis with partial or complete hyalinization of glomerular tufts, atrophy, and concomitant hypertrophy of tubules and interstitial fibrosis. Glomerular obliteration was of greatest severity in Patients 11, 13, and 14. Patient 11, in addition to stigmata of chronic glomerulonephritis, had multiple medullary cysts involving collecting tubules.

Arterioles uniformly demonstrated medial hypertrophy and intimal proliferation, but vascular necrosis was not observed.

Results

Immunoglobulin localization. Gamma₂- and γ_{1M} -globulins were demonstrated in glomeruli in all stages of glomerulonephritis (Table II). These proteins appeared to be deposited in a diffuse membranous fashion throughout the glomerulus (Figure 1), and they could be partially eluted by acid buffer. Occasionally, homogeneous foci of fluorescence were noted at the hilus or in partially hyalinized glomerular tufts. Gamma globulin deposition was usually limited to intact, nonhyalinized glomeruli. Patients with acute glomerulonephritis showed a few glomeruli containing γ_2 - and γ_{1M} -globulins. In subacute glomerulonephritis glomeruli were stained with greater frequency and intensity than in chronic glomerulonephritis. Staining for γ_{1A} -globulin did not reveal a membranous

TABLE I
Clinical and pathological findings in patients with glomerulonephritis

Patient no.	Kidney weights combined	Gross appearance of kidneys	Age	Sex	Race	Clinical history	BUN*	Proteinuria	Blood pressure
	g		years				mg/100 ml		mm Hg
Acute glomerulonephritis									
1	180	Swollen, pale gray surface with petechiae	8	M	W	URI† and scarlet fever 4 weeks before admission. Hematuria and hypertension on admission. Died in acute pulmonary edema.	15	1+	140/100
2	†	†	55	F	W	Postnecrotic cirrhosis, URI before admission. Oliguria and hematuria on admission.	23	Trace	120/80
3	†	†	28	F	W	Sore throat 6 weeks before admission. Mild persistent hematuria on admission.	10	1+	130/70
4	†	†	10	M	W	URI and gross hematuria 3 months before admission. Mild persistent hematuria.	12	2+	120/80
Subacute glomerulonephritis									
5	235	Smooth, pale, many petechiae	49	F	W	Photophobia and leg edema for 1 month. Expired after peritoneal dialysis for severe oliguria.	19	1+	170/90
6	200	Smooth, pale, many petechiae	10	F	W	Acute glomerulonephritis (clinical) 3 months before admission, followed by facial and leg edema. Died in comatose state.	100	2-3+	180/140
7	530	Smooth, pale, many petechiae	46	M	W	Renal disease in childhood. Albuminuria and hypertension for many years. Marked oliguria terminally.	146	4+	170/110
8	225	Slightly granular, surface pale gray	75	F	W	Flank pain for 1 week and hematuria (duration unknown). Expired with severe vomiting, dehydration, and oliguria.	236	2+	210/110
Chronic glomerulonephritis									
9	310	Finely granular, pale, slight contraction	25	M	N	Five months of hypertension. Terminal intermittent convulsions and congestive heart failure.	125	3-4+	200/80
10	175	Finely granular, pale, with few petechiae, marked contraction	51	M	N	Sore throat 8 months before admission followed by fatigue, dyspnea, and ankle edema. Died after a convulsive seizure.	170	2-3+	201/110
11	130	Finely granular, pale, marked contraction, medullary cysts	27	F	W	One month of pruritis, weakness, and anorexia. Died in comatose state.	200	1-2+	170/80
12	185	Granular, pale, marked contraction	25	M	W	Sore throat with fever and hematuria 7 years before admission. Died in acute pulmonary edema.	170	3+	190/110
13	150	Granular, pale, marked contraction	32	M	W	Acute glomerulonephritis 21 years ago; hypertension noted 11 years ago, controlled by medication. Died in acute pulmonary edema.	96	4+	250/160
14	125	Finely granular, pale, with few petechiae, marked contraction.	22	F	N	Nephrotic syndrome 11 years ago followed by persistent hypertension. Died in congestive heart failure.	56	3+	240/160
15	160	Finely granular, pale, few petechiae, marked contraction	28	F	N	Painless hematuria and subsequent fatigue and dyspnea. Peritoneal dialysis for progressive oliguria.	215	3+	180/150
16	360	Slight granularity, pale, with multiple petechiae	76	M	N	Weakness for 3 weeks. Anuria and coma terminally.	235	4+	124/66
17	160	Granular, pale, contraction, with few fleabites	28	M	W	Recurrent edema and albuminuria for many years. Died in coma.	148	4+	220/130

* BUN = blood urea nitrogen.

† Renal biopsy.

‡ URI = upper respiratory infection.

TABLE II

Renal localization of immunoglobulins, complement, and fibrinogen in glomerulonephritis

Patient no.	γ_2 -Globulin*	γ_{1M} -Globulin	γ_{1A} -Globulin	Fibrinogen	β_{1C} -Globulin	β_{1C} -Globulin <i>in vitro</i> fixation
Acute glomerulonephritis						
1	+	0	0	+	++	++
2	++	±		+	++	
3	+			+	++	
4	+	±		+	++	
Subacute glomerulonephritis						
5	+++	+	0	+	++	++
6	± vessels	± vessels	± vessels	± vessels	±	
7	± vessels			± vessels		
8	++			+	++	
8	++	+		+	±	
Chronic glomerulonephritis						
9	+++	++	±	++	±	+++
9	± vessels	± vessels			± vessels	
10	±	+	0	+	±	++
11	++	+	+	±	±	±
12	++	+	0	++	+	++
13	+	+	0	±	+	+
14	+	+	0	+	+	
15	++	+		±	±	
16	± vessels	± vessels		± vessels		
16	+++			+	+++	
17	± vessels			± vessels	± vessels	
17	+	±	0	++	+++	+++
	± vessels			± vessels	++ vessels	

* 0 = negative; ± = rare glomerulus or vessel; + = few glomeruli or vessels; ++ = moderate number of glomeruli or vessels; +++ = many glomeruli or vessels; blank space = not done.

distribution in glomeruli at any stage of glomerulonephritis, but occasionally focal interstitial fluorescence was observed in the subacute and chronic stages. Tubular epithelium was stained by anti- γ_{1A} -serum (Figure 2), in all stages of glomerulonephritis, but occasionally weak fluorescence with anti- γ_2 - and γ_{1M} -sera was also present. Gamma $_{1A}$ localization in tubular epithelium was most marked in cases of chronic glomerulonephritis with severe proteinuria. Deposits of immunoglobulins were rarely observed in the walls of the small arterioles, some of which showed fibrinoid degeneration (Patient 6).

Beta $_{1C}$ -globulin localization. Complement was deposited in the renal glomerulus in a pattern similar to γ_2 - and γ_{1M} -globulins. The glomerular fluorescence was least intense in cases of chronic glomerulonephritis. When sections from these kidneys were incubated with fresh human serum before treatment with fluoresceinated anti-complement serum, a marked increase in fluorescence was noted (Figure 3). Acute and subacute glomerulonephritis showed more significant *in vivo* deposi-

tion of complement in glomeruli. Complement was not present in tubular epithelium, although an occasional cast was positively stained. Blood ves-

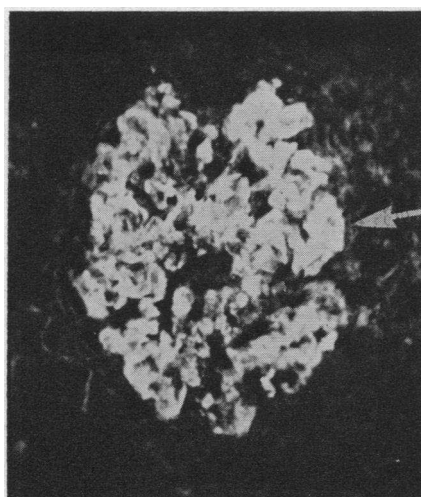


FIG. 1. DIFFUSE FLUORESCENCE IN A RENAL GLOMERULUS STAINED FOR γ_2 -GLOBULIN. Note bright homogeneous fluorescence in partially hyalinized tuft (arrow). Chronic glomerulonephritis, Patient 12 ($\times 250$).

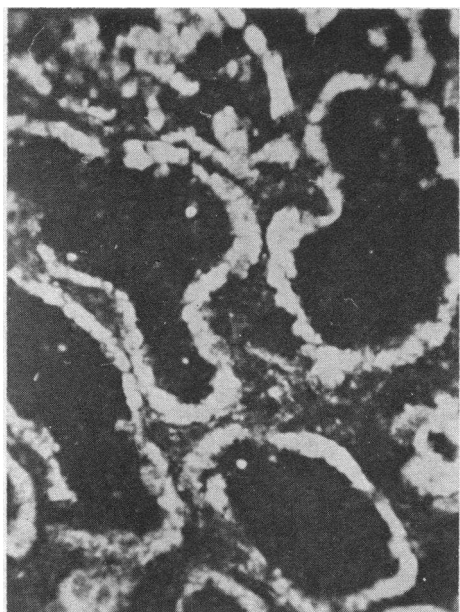


FIG. 2. TUBULAR EPITHELIAL CELLS STAINED BY ANTI- γ_{1A} -GLOBULIN SERUM. Chronic glomerulonephritis, Patient 12 ($\times 250$).

sels exhibiting immunoglobulins also contained complement.

Fibrinogen localization. In acute glomerulonephritis, patchy interstitial staining was observed

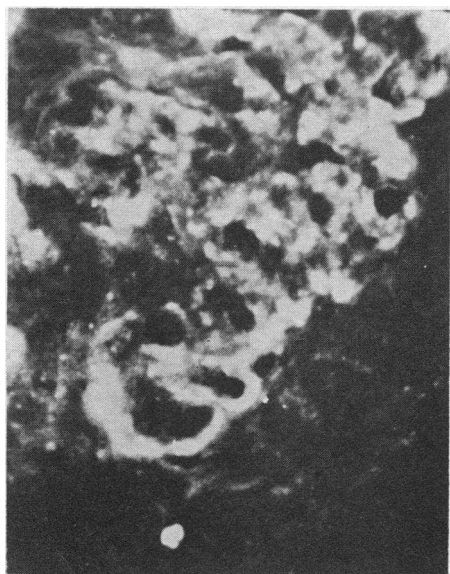

FIG. 3. SEGMENT OF GLOMERULUS SHOWING BASEMENT MEMBRANE FLUORESCENCE AFTER TREATMENT WITH FRESH HUMAN SERUM FOLLOWED BY FLUORESCINATED ANTI- β_{1C} -GLOBULIN SERUM. Chronic glomerulonephritis, Patient 12 ($\times 970$).

in a few glomeruli when sections were incubated with antifibrinogen serum.

Membranous and interstitial deposition of fibrinogen in glomeruli (Figure 4A) and diffuse localization in some crescents were observed in subacute and chronic glomerulonephritis. Many glomeruli in which fibrinogen could be localized also con-

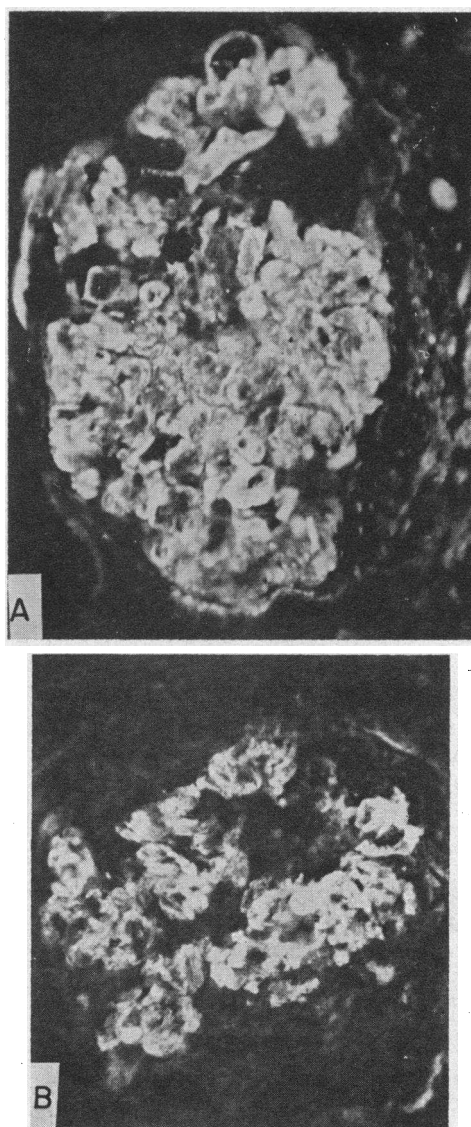


FIG. 4. RENAL GLOMERULI EXHIBITING FIBRINOGEN LOCALIZATION DEMONSTRATED BY STAINING WITH FLUORESCINATED ANTIHUMAN FIBRINOGEN SERUM. A. Diffuse membranous and interstitial glomerular fluorescence. Chronic glomerulonephritis, Patient 12 ($\times 400$). B. Partially hyalinized glomerulus with undulating membranous structure exhibiting fluorescence. Chronic glomerulonephritis, Patient 12 ($\times 400$).

tained γ_2 - and γ_{1M} -globulins. Partially or almost completely hyalinized glomeruli in advanced glomerulonephritis contained undulating membranous structures brightly stained with antifibrinogen serum and weakly stained by anti- γ_2 -sera (Figure 4B). Blood vessels with immunoglobulins and complement deposition showed fibrinogen deposits as well. PTAH and Lendrum stains revealed rare focal fibrin deposits in crescents and glomeruli of subacute and chronic glomerulonephritis. A membranous fibrin distribution was not demonstrable by these stains.

Alpha₂-macroglobulin and albumin localization. Occasional glomeruli exhibited small interstitial foci of α_2 -macroglobulin and albumin deposition. Tubular epithelium was weakly stained, and some tubular casts fluoresced after treatment of sections with the antisera to these proteins (Figure 5).

Discussion

Previous investigations have demonstrated the presence of γ -globulin and complement in the renal lesions of acute, subacute, and chronic glomerulonephritis (1-10). In the present study immunoglobulin deposition noted in renal glomeruli and small blood vessels was qualitatively similar to that seen in SLE. Gamma₂- and γ_{1M} -globulins were localized in glomeruli, whereas γ_{1A} -globulin was demonstrable in tubular epithelium. The number of glomeruli stained and the intensity of fluorescence were less than that observed in SLE kidneys. Vascular involvement, although less severe than in SLE, is also a feature of glomerulonephritis (12).

Deposits of immunoglobulins were usually limited to nonhyalinized glomeruli showing thickening of the mesangium and basement membrane. A recurrent deposition of immunoglobulin and complement affecting fewer glomeruli from patients with subacute and chronic glomerulonephritis may account for the lack of uniform glomerular involvement in contrast to SLE. The development of membranous glomerulonephritis in normal isologous renal transplants from some identical twins (13) supports the hypothesis that host activity persists in the late stages of the disease.

Similar to SLE, it appears that γ_2 - and γ_{1M} -globulins localized in the kidney are antibody components of immune complexes. Although faint lo-

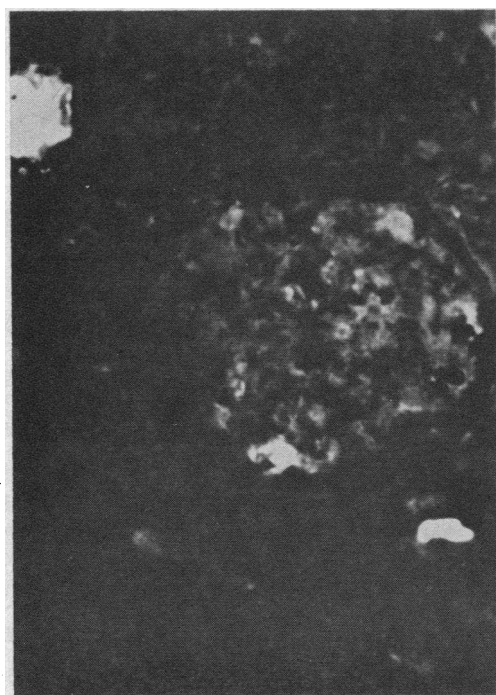

FIG. 5. KIDNEY SECTION STAINED FOR α_2 -MACROGLOBULIN. Few small foci of interstitial fluorescence noted in a glomerulus. Tubular casts fluoresce brightly. Chronic glomerulonephritis, Patient 13 ($\times 250$).

calization of complement was demonstrated in chronic glomerulonephritis, *in vitro* fixation with human complement induced bright fluorescent staining of glomeruli, indicating that complexes in glomeruli may be partially unsaturated *in vivo* or that complement disappears from the lesions more rapidly than the γ -globulin components. Gamma_{1A}-globulin, however, was found only in tubules unassociated with complement.

In acute glomerulonephritis small amounts of fibrinogen are present in a patchy distribution in renal glomeruli, in contrast to subacute and chronic glomerulonephritis, in which primarily a membranous distribution is present. The propensity of fibrinogen localization for the later stages of glomerulonephritis suggests that it is localized in previously damaged renal glomeruli, although in experimental Masugi nephritis, fibrinogen deposition has been demonstrated in the early stages of the disease (14). A concomitant abnormality of the coagulation system may contribute to fibrinogen trapping in the glomerulus. Fibrinogen persists in older lesions, as indicated by its presence

in partially hyalinized glomerulus, and it may contribute to the glomerulosclerotic process (15). Demonstration of this protein in SLE (11), toxemia of pregnancy (16), renal cortical necrosis (17), periarteritis nodosa (18), and malignant nephrosclerosis (19, 20) indicates that it is not a unique feature of glomerulonephritis. The failure of histochemical stains to detect the membranous distribution of fibrinogen may be related to the occurrence of urea soluble fibrinogen polymers in the basement membrane (21).

The striking similarity of the immunoglobulin, complement, and fibrinogen localization in patients with glomerulonephritis and SLE may imply a common immunologic pathogenesis. The selective deposition of two immunoglobulins and complement in renal glomeruli, and the similarity of the glomerular distribution of γ -globulin and complement to experimental immunologic renal disease (22, 23) support the hypothesis that antibody is an etiologic factor. Differences in the antigenic moieties of the immune complexes and in the intensity of the antibody response to these antigens may be reflected in the more prolonged course of chronic glomerulonephritis.

Summary

Gamma₂- and γ_{1M} -globulins in association with complement and fibrinogen have been localized in the glomeruli of kidneys showing acute, subacute, and chronic glomerulonephritis. Gamma_{1A}-globulin was present in tubular epithelium in the absence of complement. Complement was also fixed to glomeruli *in vitro*. The similarity of immunological findings in systemic lupus erythematosus and glomerulonephritis implies a common injury induced by antigen-antibody complexes and possibly by fibrinogen.

Acknowledgments

We gratefully acknowledge the excellent technical assistance of Miss Patricia Saigo and Miss Sara Echeverria-Cruz, the encouragement and criticism of Dr. Hans Popper, and the help of Dr. Mardoqueo Salomon, who granted us permission to study two of his patients.

References

1. Mellors, R. C., and L. G. Ortega. Analytical pathology. III. New observations on the pathogene-

- sis of glomerulonephritis, lipid nephrosis, periarteritis nodosa, and secondary amyloidosis in man. *Amer. J. Path.* 1956, **32**, 455.
2. Mellors, R. C., L. G. Ortega, and H. R. Holman. Role of gamma globulins in pathogenesis of renal lesions in systemic lupus erythematosus and chronic membranous glomerulonephritis, with an observation on the lupus erythematosus cell reaction. *J. exp. Med.* 1957, **106**, 191.
3. Taft, L. I., J. K. Dineen, and I. R. MacKay. Localization and binding of serum proteins in glomeruli of kidney biopsies in disseminated lupus erythematosus and glomerulonephritis. *Aust. Ann. Med.* 1958, **7**, 5.
4. Freedman, P., J. H. Peters, and R. M. Kark. Localization of gamma-globulin in the diseased kidney. *Arch. intern. Med.* 1960, **105**, 524.
5. MacKay, I. R., and L. I. Taft. Renal biopsy. With particular reference to the study of diabetes mellitus, systemic lupus erythematosus and subacute glomerulonephritis. *Aust. Ann. Med.* 1961, **10**, 178.
6. Burkholder, P. M. Complement fixation in diseased tissues. I. Fixation of guinea pig complement in sections of kidney from humans with membranous glomerulonephritis and rats injected with anti-rat kidney serum. *J. exp. Med.* 1961, **114**, 605.
7. Freedman, P., and A. S. Markowitz. Gamma globulin and complement in the diseased kidney. *J. clin. Invest.* 1962, **41**, 328.
8. Lachmann, P. J., H. J. Müller-Eberhard, H. G. Kunkel, and F. Paronetto. The localization of *in vivo* bound complement in tissue sections. *J. exp. Med.* 1962, **115**, 63.
9. Burkholder, P. M. Complement fixation in diseased tissues. II. Fixation of guinea pig complement in renal lesions of systemic lupus erythematosus. *Amer. J. Path.* 1963, **42**, 201.
10. Seegal, B. C., G. A. Andres, K. C. Hsu, and J. B. Zabriski. Studies on the pathogenesis of acute and progressive glomerulonephritis in man by immunofluorescein and immunoferritin techniques. *Fed. Proc.* 1965, **24**, 100.
11. Paronetto, F., and D. Koffler. Immunofluorescent localization of immunoglobulins, complement, and fibrinogen in human diseases. I. Systemic lupus erythematosus. *J. clin. Invest.* 1965, **44**, 1657.
12. Fishberg, A. M. The arteriolar lesions of glomerulonephritis. *Arch. intern. Med.* 1927, **40**, 80.
13. Murray, J. E., J. P. Merrill, and J. H. Harrison. Kidney transplantation between seven pairs of identical twins. *Ann. Surg.* 1958, **148**, 343.
14. Vassalli, P., and R. T. McCluskey. The pathogenic role of the coagulation process in rabbit Masugi nephritis. *Amer. J. Path.* 1964, **45**, 653.
15. Vassalli, P., G. Simon, and C. Rouiller. Electron microscopic study of glomerular lesions resulting from intravascular fibrin formation. *Amer. J. Path.* 1963, **43**, 579.

16. Vassalli, P., R. H. Morris, and R. T. McCluskey. The pathogenic role of fibrin deposition in the glomerular lesions of toxemia of pregnancy. *J. exp. Med.* 1963, **118**, 467.
17. Koffler, D., and F. Paronetto. Unpublished observations.
18. Paronetto, F., and L. Strauss. Immunocytochemical observations in periarteritis nodosa. *Ann. intern. Med.* 1962, **56**, 289.
19. Paronetto, F. Immunocytochemical observations on the vascular necrosis and renal glomerular lesions of malignant nephrosclerosis. *Amer. J. Path.* 1965, **46**, 901.
20. Fennel, R. H., Jr., C. R. R. M. Reddy, and J. J. Vazquez. Progressive systemic sclerosis and malignant hypertension. *Arch. Path.* 1961, **72**, 209.
21. Gitlin, D., and J. M. Craig. Variations in the staining characteristics of human fibrin. *Amer. J. Path.* 1957, **33**, 267.
22. Dixon, F. J., J. D. Feldman, and J. J. Vazquez. Experimental glomerulonephritis. The pathogenesis of a laboratory model resembling the spectrum of human glomerulonephritis. *J. exp. Med.* 1961, **113**, 899.
23. Unanue, E., and F. J. Dixon. Experimental glomerulonephritis. IV. Participation of complement in nephrotoxic nephritis. *J. exp. Med.* 1964, **119**, 965.