

# THE RENAL LESION IN EPIDEMIC HEMORRHAGIC FEVER<sup>1</sup>

By JEAN OLIVER AND MURIEL MACDOWELL

(From the Renal Research Unit, Overlook Hospital, Summit, N. J.)

(Submitted for publication June 21, 1956; accepted September 5, 1956)

Structural and functional derangements in the kidney during the course of Epidemic Hemorrhagic Fever run as a continuing thread of cause and effect through a complex of physiological and biochemical disturbances that has perhaps no parallel among the acute infectious diseases. So closely knit are these renal aberrations in the fabric of the clinical syndrome that investigators have found it impractical to disentangle the element of "renal failure" from the related phenomena of shock, hypotension or hypertension and electrolyte or water imbalance, and so simply state as their conclusion that "renal complications" are present in all examples of the disease and at every stage of its progress (1).

The general nature of the renal lesion has been established. In its clinical aspects, it is an example of "acute renal failure" with the typical characteristics of proteinuria, oliguria and late diuresis. From the physiological viewpoint, the investigations of Froeb and McDowell (2) and of Syner and Markels (3) have demonstrated similar disturbances of renal blood flow which occur either as a part, or at times independently, of the general circulatory collapse which so frequently ensues in the early phases of the disease.

The pathological alterations that occur in the kidneys have been described by the Russian investigators who first recognized the disease in eastern Siberia (4),<sup>2</sup> and in later studies by the Japanese (4). More recently, Hüllinghorst and

Steer (6), Steer (7) and Lukes (8) have reported on material obtained during epidemics among American troops in Korea. Though the resemblance of the histological picture to that which is found in other forms of the acute renal necrosis associated with traumatic and toxic injury has impressed pathologists, certain characteristics of the structural lesions of EHF are so distinctive that in the absence of a demonstrable etiological agent they have become the final criterion for its diagnosis.

A general discussion and detailed analysis of the clinical, physiological and biochemical derangements that occur in EHF have appeared in a Symposium published under the editorial direction of Dr. David P. Earle (9). Against this background an attempt will now be made to integrate the development of the structural aspects of the renal lesion with the progress of its functional disturbances.

## MATERIAL AND METHODS

The clinical data and pathological material of this study have been taken from the records of the Commission of Epidemic Diseases and the collections of the Armed Forces Institute of Pathology.

Thirty-nine fatal cases of EHF which occurred during the Spring and Fall epidemics of 1952 and 1953 among American troops in Korea have been examined. An analysis of thirty-four of these appears in the Symposium (9); the case numbers of this earlier study have been retained, and though much of its substance has been incorporated into our report further pertinent information may be derived from this source, in particular from Table VIII, page 636.

The distribution of the cases in regard to the phase of the disease in which the individual died was as follows:

Hypotensive phase:	19
(PPrimary shock    12)	
(Transition shock  7)	
Oliguric phase:	10
Diuretic phase, 1 to 16 days of diuresis:	9
Convalescence, 149 days from onset:	1
	—
	39

<sup>1</sup> This work was done under the auspices of the Commission on Hemorrhagic Fever, Armed Forces Epidemiological Board, and was supported by the Office of the Surgeon General of the Army, and in part by a research grant (H-1515-C2) from the National Heart Institute, of the National Institutes of Health, Public Health Service, and the Life Insurance Medical Research Fund.

<sup>2</sup> Though the earlier reported cases of EHF were limited to Manchuria and eastern Siberia, later observations have shown that a very similar disease occurs in the Balkans and Czechoslovakia. The mild "epidemic nephropathy" observed in Finland, Sweden and Norway resembles EHF in some ways, but an identity has not been proved (5).

The method of study was as follows. The autopsy protocols and clinical records were first reviewed. Sections of all the tissues from each autopsy were then examined for whatever relation they might bear to the renal lesion and the sections of kidney studied in detail by the conventional methods of histological examination. In the material of this preliminary survey 10 per cent formalin and Zenker's solution had been the fixative, and hematoxylin and eosin the stain; in subsequent examinations the Masson stain, iron hematoxylin and eosin, Acid Fast Green and certain histochemical procedures were used.

After this examination had established the general nature of the renal lesion, microdissection of the kidney tissue as previously described (10) was done to observe the detail and topographical relations of abnormalities in the nephrons. The dissected nephrons were stained with iron hematoxylin, and camera lucida drawings or photomicrographs were made for permanent record. As will appear in the descriptions of the structural alterations, a continuous comparison was made during the progress of the work between the appearance of the lesions as they were revealed by the two methods of examination.

Selected examples illustrating the course and development of the pathological alterations appear in our illustrations. It is perhaps unnecessary to point out that considerations of expense and space have made necessary a considerable restriction in the presentation of our findings. During the dissection of each case hundreds of nephrons were examined, many were drawn by means of the camera lucida, and a lesser number photographed at magnifications of up to 200 times. Of the latter only typical examples can be published, and at great reduction; the original of Plate I, for example, is composed of 97 individual 4 by 5 microphotographs which, when assembled to show the complete nephron, cover a space of 4 by 9 feet; much detail is therefore lost in the process of publication.

In the exposition of our findings the nomenclature used by clinical investigators to designate the course of the disease has been adopted. A brief review of the syndrome of EHF may orient the reader for the more detailed description of the physiological, clinical and pathological correlations that are to follow.

#### THE CLINICAL SYNDROME OF EHF

During all but the first of the five successive phases, Febrile, Hypotensive, Oliguric, Diuretic and Convalescent, into which the clinical course of EHF has been divided, disturbances of renal activity are prominent. The Febrile Phase is characterized by the usual fever, chills, headache and nausea of an acute infectious disease, and ends around the fifth day by defervescence.

With passage into the Hypotensive Phase, the earlier manifestations of disturbance in the peripheral circulation, such as the intense flush of the

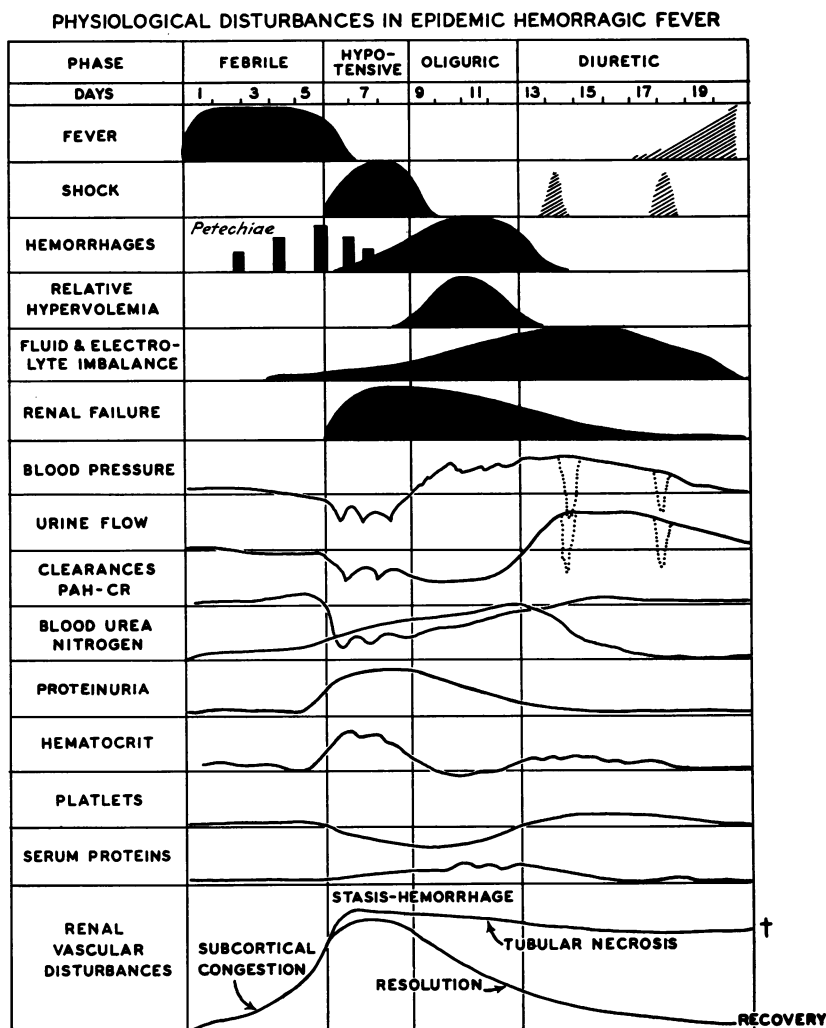
face and the injection of the pharynx, become definitive in the appearance of petechiae. Concomitantly, there occurs a rise in the hematocrit which, along with direct determinations of decreased circulating volume, suggests that plasma fluid is leaking through damaged capillaries into tissue spaces. As a result, the blood pressure falls and shock ensues.

These conditions persist during the Hypotensive Phase, in which death from primary shock accounted for one-third of all fatalities. Proteinuria is now massive and the urinary output is irregularly decreased. Blood urea nitrogen rises and, with passage from the Hypotensive Phase, the oliguria, previously irregularly manifested, becomes permanently established to mark the third stage of the disease.

The elevated hematocrit of the Hypotensive Phase has now decreased toward normal, at times abruptly, but more usually requiring one to three days before it becomes stabilized at its original level. During this Transition Period from the Hypotensive to the Oliguric Phase, a circulatory collapse of a nature somewhat different from the "primary shock" of the earlier period may occur; in "transition shock" the observation that total serum proteins do not change as the hematocrit falls, and direct measurements of an increasing circulatory volume, suggest that fluid previously lost to the extravascular spaces is returning.

During the Phase of Established Oliguria which follows, hypertension is commonly observed, but a more remarkable circulatory disturbance during this period is the development in certain cases of a *relative* hypervolemia along with hemorrhagic phenomena during which the complications of pulmonary edema, hemorrhage or convulsions may be fatal.

After 3 to 5 days of oliguria, the Diuretic Phase begins; a daily output as high as 18 L. has been recorded. During this phase abnormalities in electrolyte and water balance may develop and a condition of "limited homeostasis" be established in which secondary shock and pulmonary edema occur. Judging from the evidence of increasing clearances there then follows an improvement in the renal circulation which gradually reaches normal in the following weeks. The BUN has fallen, proteinuria has disappeared, and in the Convalescent Period most patients after two months



TEXT FIG. 1. COURSE OF CLINICAL AND LABORATORY OBSERVATIONS IN SEVERE EPIDEMIC HEMORRHAGIC FEVER

Modified from Sheedy and his associates (1).

can concentrate their urine to a specific gravity of 1.023 or better.

Text Figure 1, which is a modification of Figures 2 and 3 of Sheedy and his co-workers (9), shows the clinical manifestations and laboratory measurements of EHF in graphic form. The lowest level illustrates the occurrence and relative intensity of certain pathological phenomena that were observed in the kidney, and will be explained by our later descriptions.

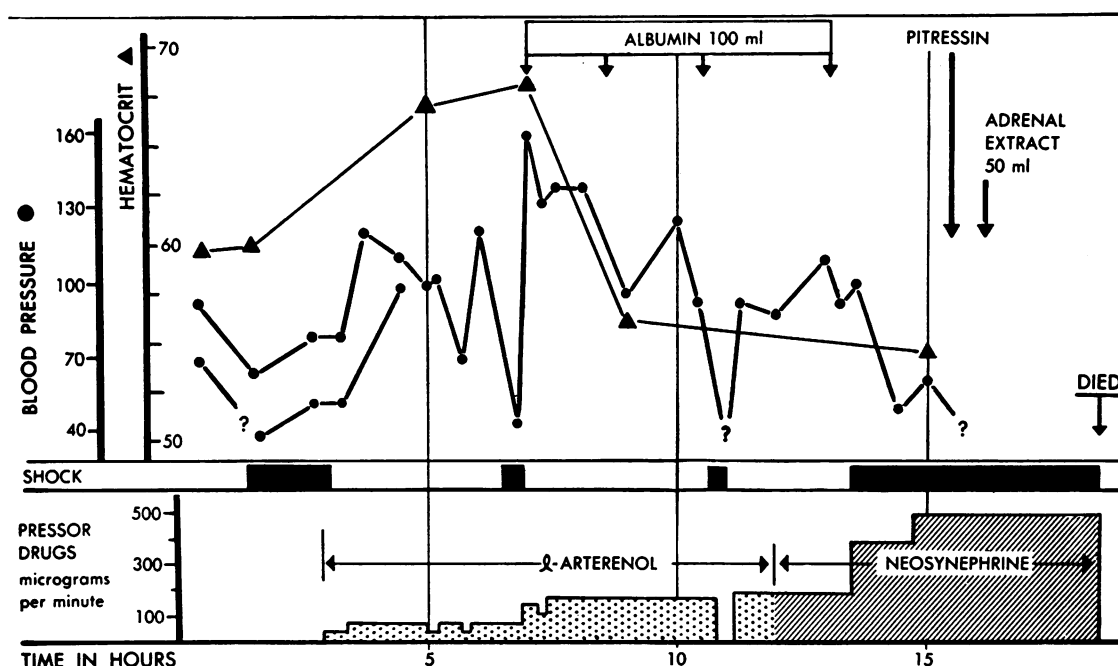
Although, as previously stated, the renal lesion is to be described as it develops in the consecutive clinical stages of the disease, the procedure of presenting the individual cases has been to arrange

them in a series based on the evolution of the pathological lesions. As these lesions are of varied nature, involving vascular, interstitial and parenchymal reactions which may develop at differing rates of intensity, such a series can be only approximate in arrangement.

#### THE RENAL LESION IN THE FEBRILE AND HYPOTENSIVE PHASE

##### (The Prehemorrhagic Stage of Subcortical Congestion)

The earliest view of the renal lesion in EHF encountered in this series was obtained in Case



TEXT FIG. 2. CASE 38—DEATH IN PRIMARY SHOCK PHASE OF HEMORRHAGIC FEVER

Note initial response to continuous intravenous pressor therapy but increasing requirements during subsequent course, and death after 18 hours' observation despite 400 cc. concentrated human albumin, Pitressin® and adrenal cortical extract. Note also shock at eleventh hour when L-arterenol infusion infiltrated into subcutaneous tissue. Blood pressure could be measured only by palpatory method after fifth hour. Marked retroperitoneal edema was present at autopsy.

Text Figures 2, 4, 6, 7 and 9 and their legends are from the Symposium on Epidemic Hemorrhagic Fever (9) and are published by permission of author and publisher from the American Journal of Medicine, 1954, 16, 617.

38, who died on the fourth day of his illness. After three days of severe headache, chills, fever, nausea and vomiting, he entered the hospital with a temperature of 103°, a blood pressure of 100/70 mm. Hg, a 1 + proteinuria and a hematocrit of 59 per cent. Physical examination showed intense injection of the conjunctivae and soft palate, but no petechiae were present. During the examination he suddenly vomited and collapsed; his blood pressure fell to 58/0 mm. Hg. In spite of continuous treatment,<sup>3</sup> including the infusion of 4 units of serum albumin which produced intermittent re-

establishment of blood pressure (Text Figure 2), he expired in shock 18 hours after admission. During this period, with a fluid intake of 2864 cc. he passed 415 cc. of urine; the last sample before death showed 2 + protein and the terminal BUN was 42.3 mg. per cent.

At autopsy no petechiae were present. There was a considerable amount of retroperitoneal edema lightly stained with the dye, T-1824, that had been injected for determination of blood volume. The kidneys were not swollen (175 to 200 gm.) and the prosector noted that though the cortex was more sharply differentiated from the medulla than normally, there was not the intense congestive zone which he was accustomed to find as typical of EHF. There were, however, the usual hemorrhages in the right atrium and an extensive hemorrhagic infiltration of the anterior lobe of the pituitary.

On histological examination the glomerular

<sup>3</sup> In this and the cases which follow, only that therapeutic procedure has been given for which there is evidence that it may produce a structural alteration in the kidney, namely, the administration of concentrated human serum albumin (1 unit = 100 cc. 25 per cent salt-poor serum albumin). Many individuals also received whole blood transfusions, glucose and nor-adrenalin infusions and occasionally Dextran. A summary of these procedures may be found elsewhere (9).

tufts were essentially normal; the capillaries contained red blood cells in normal numbers and there was precipitated granular material in Bowman's space. Cross sections of proximal convolutions in the cortex were lined with their typical epithelium which showed some evidence of apical swelling of its cells (Figures 1 and 2); the cytoplasm of these cells was normal. The lumens of cross sections of ascending limbs in the medullary rays and the distal convolutions in the cortex were dilated and appeared empty (Figure 2).

In the subcortical medullary zone were scattered areas of dilatation of intertubular vessels which were crowded with discrete red blood cells (Figure 3). The thin outlines of the intact walls of these vessels were clearly evident and there was no escape of blood into the interstitial tissue (Figure 4). In these areas of congestion the epithelium and basement membranes of the "straight tubules", terminal proximal convolutions and ascending limbs of Henle's loop, though somewhat compressed, were well preserved. Throughout the deeper portions of the medulla were irregularly distributed patches of intertubular edema, but little evidence of congestion and none of hemorrhage (Figure 5). The tubules of the collecting system were normal and contained few casts.

Microdissections of the renal tissue showed essentially normal configurations in the nephrons, except for some slight pressure effect on those terminal segments of the proximal convolutions and ascending limbs of Henle's loop which passed through areas of congestion.

Plate I, A to F, shows a complete nephron stained with iron hematoxylin. Apart from the localized effects just noted, the general configurations of this nephron are so slightly disturbed that it may serve as a control example of the appearance of a normal nephron prepared by our technique for comparison with the damaged specimens that are to follow. In all the preparations, the intense black staining of the proximal convolution is the reaction of the mitochondria which fill the cytoplasm of its epithelial cells in decreasing amount as one departs from the glomerulus; these cellular organelles no longer exist in their original rod-like form but, apparently as a result of the maceration in HCl, are resolved into fine "granules". As in histological preparations stained with iron hematoxylin, the nuclei do not

stain heavily but appear as light round spots on the dark background of the cytoplasm, except in the premitotic phases of regenerative proliferation when their excessive and hyperchromatic chromatin makes them clearly visible. It should be recalled that the tubule is being viewed through its entire thickness, 60 to 70  $\mu$  in the case of the proximal convolution, so that cellular detail is of necessity somewhat clouded; on the other hand this increase in the absolute amount of tissue under observation at times permits the recognition of cytoplasmic lesions which are not appreciable in thin histological sections. Since a familiarity with the microscopic appearance of dissected nephrons is essential to the recognition and the interpretation of the alterations that are to be seen in the abnormal specimens, a detailed description of Plate I will be given.

The glomerulus, due to the bulk of its tissues, shows little cellular detail; its size and shape are normal, however, and the relation of the more opaque tuft to Bowman's capsule is evident.

The proximal convolution is of normal configuration and diameter, except in its terminal medullary portion, which, passing into an area of congestion in the subcortical outer stripe of the outer zone of the medulla, is somewhat compressed. The cytoplasmic pattern is in general well preserved; the normal mitochondrial gradient is shown by the gradual decrease in the intensity of the reaction to iron hematoxylin, and the clear, vacuolar, round nuclei, more visible as the intensity of the mitochondrial staining lessens, are normally distributed in the tubule wall. At *a* in Plate IB, the medullary segment of the convolution entered an area of intense intertubular congestion which lay just below the cortex. The tubule is definitely narrowed, and although its cells are in general well preserved, slight irregularities are noted toward the end of the segment, and a scattering of intracellular detritus indicates some epithelial damage.

The greater part of the thin portion of Henle's loop, though successfully dissected and mounted, was swept away during the process of staining (Plate ID); a short remnant, somewhat dilated, remains (Plate IE) and passes abruptly into the thick portion of the limb which, continuing to descend, forms the loop and turns towards the cortex. In the area of congestion, lying adjacent

to the compressed terminal segment of the proximal convolution, the cellular pattern of the ascending limb is slightly disturbed and there is some deeply stained intracellular detritus. Above this point and extending high into the cortex the ascending limb is moderately dilated; its cellular components appear essentially normal.

The distal convolution (Plate IF) is much more and very unevenly dilated, so that there is a consequent patchy thinning of its wall which accounts for the irregularity of its staining; there are no coagula or casts in its distended lumen. The juncture of its terminal portion, the connecting tubule, with that of a neighboring nephron is not dilated.

Dissected collecting tubules, from cortex to deep medulla, were entirely normal; those which passed through the areas of congestion were unaffected by the dilatation of the intertubular vessels which surrounded them.

The nephron shown in Plate I was typical of those which were involved in an area of subcortical congestion, and none of these showed more severe alterations. Those which passed outside or between the scattered areas of congestion, at a rough estimate perhaps one-half of all nephrons, showed no visible abnormalities in their structure.

Text Figure 3 is a graphic representation of a renal lobule from this kidney. The nephrons shown are camera lucida tracings of dissected specimens. They and the areas of intertubular congestion are arranged as they were observed to lie in the kidney during the course of dissection and as similar structures and relations appeared in histological sections. For the sake of clarity only a few nephrons are shown and these are widely spaced, but otherwise the figure presents not an interpretive diagram but a reconstruction of actuality.

It is clear that the architecture of the kidney and the topographical relation of its constituent nephrons have not been greatly affected by the vascular disturbance in the subcortical medulla. The dilatation of the distal portions of the nephron lying in the cortex, including ascending limbs of Henle's loop and distal convolutions, is, however, definite if not striking (Figure 2 and Plate IF); this dilatation was associated with a zone of moderate pressure effect from the congestion in the sub-cortical medulla, a relation that will

assume greater significance with the progress of the renal lesion.

\* \* \* \* \*

Since the renal lesions become increasingly complex with the progress of the disease, a summary of the structural findings and a discussion of their significance along with a reference to pertinent literature will be given at the end of each clinical period. This procedure may make for reiteration, but will perhaps be less burdensome to the reader than the continuing back reference to minutiae long since described which would be required if critical considerations were postponed to a final conclusion.

The kidney of this individual in whom deferescence was interrupted by sudden death from primary shock may be taken as illustrative of the renal status during the late Febrile Phase at its passage into the Hypotensive Phase. The lesion can be briefly summarized. There is a marked congestive hyperemia localized to the subcortical zone of the medulla, occurring not diffusely but in irregular patchy areas, with no intertubular hemorrhage. There are some slight localized pressure effects of this congestion, both of compression and dilatation, on the tubules of nephrons that by chance pass through it, but no structural evidence of general cellular damage in any of the tubules. The tubular passages are clear; there are few casts.

The correlation of these structural changes with the clinical and physiological data of the period seems reasonably clear; all lines of evidence indicate the beginning of widespread disturbances in the peripheral vascular bed which are characterized first by dilatation and then by increased permeability of capillaries and venules.

In the kidneys, the functional effects of these disturbances are reflected in the clearance examinations of Froeb and McDowell (2) and of Syner and Markels (3), who found not a lessening of renal blood flow, as is observed in classical acute renal failure, but either its full maintenance or actual increase. The histological sections show the distribution of this abundant blood flow in the congestive hyperemia of the subcortical medulla. To a consideration of the reason for this localization we shall return in a later description of the progress of the vascular lesion. Neither histo-



TEXT FIG. 3. A RENAL LOBULE FROM THE EARLY HYPOTENSIVE PHASE OF EPIDEMIC HEMORRHAGIC FEVER—  
CASE 38

Except for some dilatation of the distal convolutions the topography of the nephrons is normal. There is an irregular intense congestion of the subcortical medulla but no intertubular hemorrhage. Magnification 18 $\times$ .

logical sections nor dissections showed frank structural alterations in the nephrons, a finding which correlates with the clinical observation that there was only a moderate degree of proteinuria and elevation of BUN.

It may be concluded, therefore, from both the structural and functional findings, that the vascular bed of the kidney shares in the general disturbance of the peripheral circulation, the clinical evidences of which were vividly present in the intense flush of the skin of the face and chest and mucous membranes. All these phenomena together constitute the first evidences of generalized capillary damage, and in the case described they terminated abruptly in primary shock when plasma escaped into the extravascular spaces, a phenomenon indicated by the clinical observation of a rising hematocrit and confirmed by the pathological finding of massive retroperitoneal edema. It is noteworthy that the ultimate lesion of vascular damage was as yet not developed in either the skin or the kidney, for neither petechiae were present nor intertubular hemorrhage. This gravest aspect of the vascular lesion was, however, present in two areas, the right auricle and the anterior hypophysis; the small vessels of these regions are apparently peculiarly susceptible since in every case in this series they were the seat of extensive hemorrhage.

\* \* \* \* \*

The remaining cases of those dying in primary shock may be considered to have definitely entered the Hypotensive Phase, a conclusion supported not only by the evolution of the clinical symptomatology but by the progress of the renal lesion.

The first of these, Case 9, entered hospital with a 3+ proteinuria 3½ days after a typical febrile onset. The next morning the hematocrit rose to 61.9 per cent, the blood pressure fell, and the patient went into shock; in spite of the administration of 1200 cc. of blood and 3 units of serum albumin, he died in shock the morning of the following day. There was no oral intake of fluid, and there was a urinary output of 760 cc.; the terminal temperature was 106°; the BUN on the day before death was 16.8 mg. per cent. At autopsy, marked retroperitoneal edema, hemorrhages in the right auricle and an extensive hemorrhagic

infiltration in the anterior pituitary were present. The kidneys were swollen; their medullae are described as "reddish purple".

Histological examination showed an intense, patchy engorgement of the subcortical zone of the medulla. In certain areas the capillaries between the terminal proximal convolutions and ascending limbs of Henle's loop were dilated to the diameter of the adjacent tubules and crowded with red blood cells which in some vessels were discrete and in others packed and fused into a hyaline mass (Figure 6). In spite of this distention the walls of the vessels were not greatly thinned and their intact endothelial cells were plainly visible. The tubules surrounded by these vessels were compressed by the resulting tension and their epithelium showed a moderate degree of protoplasmic disturbance.

Not only were the small vessels of the outer medulla distended with red cells, but the capillaries of the swollen glomerular tufts throughout the cortex were greatly dilated and packed with red blood cells (Figure 7). There was considerable precipitated granular material in Bowman's space. Between the cross sections of the cortical proximal convolutions the intertubular capillaries were not particularly prominent. Both the large veins and the arteries of the cortico-medullary junction were, however, engorged with blood.

Whereas the epithelium of the proximal convolutions of the previously described case was essentially normal, there was now present diffusely throughout the cortex a definite swelling of the epithelial cells, and their protoplasm showed irregular variations in density without, however, the occurrence of definite vacuoles. Although the epithelial protoplasm was increased in its granularity, no large, discrete hyaline droplets were present.

\* \* \* \* \*

In this individual, who died somewhat later in the course of the disease than the previous case, a definite increase in renal structural change is apparent. The subcortical congestion is more intense, though the excess blood is quite clearly contained within the dilated straight vessels of the outer medulla. There is also a marked congestion of glomerular capillaries and somewhat less of the

cortical intertubular network, and both the large arteries and veins are greatly distended. One has the impression, since there was no general visceral congestion observed post mortem to account for the excess blood in the kidney, that dilatation of an atonic intrarenal vascular bed had, by a reduction in peripheral resistance, flooded the entire organ.

The other advance in the development of the renal lesion concerned the epithelium of the proximal convolutions. Throughout their length there was noted a frank protoplasmic disturbance.

\* \* \* \* \*

Case 14 was a man admitted on the third day of his illness with a temperature of 105° and a blood pressure of 128/70 mm. Hg; on the third day in the hospital it fell suddenly to 90/74. Three units of serum albumin were given. The urine showed a 3 + proteinuria; on an intake of 800 cc. his urinary output was 2280 cc.; the BUN was 24 mg. per cent.

The renal lesion may be briefly summarized as similar to the preceding case, except that the congestion was more closely limited to the subcortical medulla, and the protoplasmic swelling of the cells of the proximal convolutions was more pronounced.

A further development of the disturbance in the cortex of the kidney was noted in Case 20. This man died of primary shock on the seventh day of his illness in spite of the repeated administration of infusions over a period of 3 days of serum albumin to a total amount of 8 units. There was no fluid intake other than by these infusions, and there was a urinary output in 4 days of 1060 cc. His urine was negative for protein for the first 5 days; then a trace appeared increasing in a few hours to 4 +. BUN on entrance was 22.9 mg. per cent, and on the day before death, 85.0 mg. per cent.

Histological examination showed the subcortical congestion and in the cells of the proximal convolutions the protoplasmic disturbance that has previously been described; the latter had advanced to the formation of definite vacuoles. In addition, irregular areas of edema were scattered throughout the cortex, the cross sections of tubule being widely separated by collections of fluid (Figure 8). The cells of the proximal convolutions in

the congested subcortical zone were filled with large hyaline droplets.

Case 26 was admitted on the third day of his illness with a temperature of 105°; his urine was free of protein. Shock intervened almost immediately and continued in spite of the administration of 16 units of serum albumin over a period of 3 days. On the fifth day of his illness, the urine showed a 4 + proteinuria. His urinary output during hospitalization was 460 cc.; the BUN rose to 69 mg. per cent; he died in shock on the sixth day of the disease.

At autopsy, massive retroperitoneal edema was noted. The prosector was impressed by the "dark appearance" of the subcortical congestion. Histological examination showed this congestion in the form of dilated but intact intertubular vessels; congestion was not excessive in the cortex. The glomeruli were normal but the capsular spaces contained considerable amounts of precipitated protein. The most pronounced abnormality noted was the marked swelling of the tubular epithelium in the cortical portions of the proximal convolutions. Vacuolization was extreme, large, clear, rounded spaces extending through the entire depth of the epithelial cells (Figure 9). The terminal segments of proximal convolutions that lay in the subcortical zone of dilated intertubular vessels were less swollen; their lumens contained considerable amounts of clear, coagulated protein in which were enclosed bubble-like spaces and many desquamated cells with pyknotic nuclei. The cells which still lined the compressed tubule were filled with hyaline droplets.

The increasing alteration of the epithelium of the proximal convolution described in the preceding three cases appeared at a maximum in an individual (Case C) who, entering the hospital with a temperature of 105.8° on the third day of his illness, went into shock on the following morning. In spite of treatment, including the administration of 3 units of serum albumin and 3 units of Dextran, he succumbed with pulmonary edema on the eighth day. The maximum hematocrit on the first day of shock was 64.2 per cent, falling on the seventh day to 32.9 per cent; in 5 days the intake of fluid was 10,505 cc., the urinary output, 1300 cc. A 4 + proteinuria developed and the BUN rose from 21.4 mg. per

cent on the fourth day reaching 250 mg. per cent on the day preceding death.

At autopsy the kidneys showed a moderate degree of cortico-medullary congestion. Retro-peritoneal edema was present.

On histological examination the usual dilation of the intertubular capillaries in the cortico-medullary zone was observed. The most striking alteration was an extreme swelling of the epithelium of the proximal convolutions. The finely granular cytoplasm of the cells appeared as if inflated, resulting in a protrusion of their apices into the lumen of the tubule; the brush border was, however, preserved, as were the nuclei which were displaced towards the base of the cells. This intense swelling of tubular epithelium was sharply limited in its distribution to the proximal convolution, the epithelium of the ascending limbs being essentially normal (Figure 10). It extended into Bowman's space, which was in part obliterated by the protrusion of the foamy cytoplasm of the cells of its parietal layer; the epithelium covering the tuft was not involved (Figure 11). No hyaline droplets were observed in the altered epithelium of the proximal convolutions.

\* \* \* \* \*

The evolution of the renal lesion as shown by the development of structural alterations in the preceding four cases is evidenced by two phenomena; increase in the intertubular congestion of the cortico-medullary zone, and a swelling of the proximal convolutions. The latter has the histological appearance of an increased hydration of the protoplasm of the epithelial cells which reached the point of vacuolization.

The increase in subcortical congestion took the form of a spread in the extent of involved areas rather than in a progressive dilatation of individual channels. In the less far advanced lesion, the groups of dilated intertubular vessels were widely spaced on a background of less affected medulla and had therefore the normal distribution of the horsetail-like strands of capillaries which result from the subdivision of each of the large, straight efferents from juxta-medullary glomeruli in the lower cortex (11). Originally forming isolated clusters, the addition of more dilated capillary radicles at their periphery resulted in their fusion to a more or less continuous band

which in the end separated cortex from medulla. The congested zone thus occupied the entire outer stripe and extended into the inner stripe of the outer zone of the medulla. The altered vascular pattern is therefore that which might result from a continuing flow of blood into abnormal intertubular vessels that had lost their tonicity; the localized distinctiveness of this pattern will be considered later.

Swelling of the tubular epithelium and protoplasmic disturbances in its cytoplasm have not received great attention in considerations of the pathogenesis of acute renal failure and are frequently dismissed under the stock description of "cloudy swelling" with the implication that the importance of this at times dubious histological lesion is not great. Funck-Brentano has corrected this arbitrary view in his thesis on the physiopathological mechanisms of anuria in the acute nephropathies (12). In experiments on rabbits, oliguria and anuria were found to follow the infusion of serum containing 50 per cent glucose, whereas no such effect was produced by infusions of serum containing 9.9 per cent NaCl. Sections of the anuric kidneys showed a marked swelling of the epithelial cells of the proximal convolutions very similar to the illustrations of the swollen epithelia in Figures 10 and 11. He concludes that the swelling is due to cellular hyperhydration which is derived as an effect of alterations in the osmotic pressure of the plasma; this he demonstrates by a corrected freezing point determination. Similar changes in the freezing point of the plasma were noted in human clinical examples of the oliguric phase in acute renal failure. There are no data available on plasma osmolality in EHF, but the results of Funck-Brentano's experiments in the production of epithelial lesions by modification of osmotic factors and consequent shifts in hydration of cells are remarkably similar to those seen in EHF.

In Case 20 of the preceding group there is noted for the first time in our description of the renal lesion the occurrence of hyaline droplets in the epithelial cells of the proximal convolutions, and these objects will be found in many examples that follow. A consideration of their significance in this report would lead to a considerable digression. We shall therefore only state that in our opinion these droplets do not represent an effect of the

disease processes, though these do modify the conditions of their formation, but rather are the result of a therapeutic procedure, namely, the administration of large amounts of human serum albumin. The hyaline droplets are in other words regarded not as the products of some hypothetical cellular "degeneration" but as droplets of absorbed modified protein similar to those which form in the cells of the proximal convolutions of experimental animals which have been given similarly large injections of homologous plasma proteins (13). Since the droplets are therefore not considered an essential feature of the renal lesion of EHF, the data concerning them will be presented elsewhere in a general discussion of hyaline droplet formation in human renal disease and its significance in the metabolism of the plasma proteins.

\* \* \* \* \*

The three remaining cases from the Hypotensive Phase of EHF show increasing structural change of the nature so far described and the development of another aspect of the renal lesion that is to assume predominating proportions and result in grave renal damage in later stages of the disease, namely, the ill effects of the vascular disturbance on the tubules of the nephrons.

Case A developed fever and nausea the day after his discharge from the hospital following an acute appendectomy from which he had apparently recovered with an uneventful convalescence. Two days after readmission to the hospital a Douglas' pouch abscess perforated and drained spontaneously; he then went into shock. An intra-abdominal hemorrhage was suspected but none was found on laparotomy. Transferred to the EHF hospital in shock, he received 5 units of albumin and other treatment with little effect, and died on the fifth day. He was anuric during his last hospitalization; his BUN rose to 64 mg. per cent.

At autopsy the kidneys presented the usual subcortical congestion and the anterior lobe of the pituitary was hemorrhagic.

Histological examination showed that in the renal cortex the epithelium of the convoluted tubules was greatly swollen and vacuolated, resembling the alterations illustrated in Figure 9; there were few if any hyaline droplets in their

epithelial cells except as the convolutions approached the cortico-medullary boundary. In the area of subcortical congestion the excess blood was still contained within widely dilated capillary spaces. The straight tubules in this region were filled with great numbers of what appeared at first glance to be "hyaline casts"; these also extended upwards in the medullary rays (Figure 12). Collecting tubules in the deeper parts of the medulla and papillae showed only moderate numbers of casts.

The terminal medullary segments of the proximal convolutions which lay in the congested subcortical zone were compressed and crowded together though their lumens were irregularly dilated and filled with hyaline material. These collections on closer examination did not have the appearance of solid casts, the great majority being composed of an albuminous fluid which had, under the influence of the fixative, coagulated in bubble-like configurations containing debris and desquamated cells (Figure 13). The epithelial wall lying contiguous to the entrapped fluid was infiltrated with eosinophilic material; its cells were disarranged, in part desquamated, and showed pyknotic nuclei. The protoplasm of the better preserved cells was crowded with hyaline droplets of varying size.

Similar changes were noted in Case 21, who was admitted with a typical 3-day history of EHF and a temperature of 103°, a blood pressure of 118/58 mm. Hg, and 1 + proteinuria. After an uneventful 24 hours, his hematocrit abruptly rose to 59.0 per cent, and his blood pressure fell to 86/64 mm. Hg with a pulse of 140. In spite of 5 units of serum albumin and other supportive treatment, he died in primary shock on the next day, the sixth day of the disease.

At autopsy there was marked retroperitoneal edema; the kidneys presented the typical appearance of subcortical congestion and there was a gross hemorrhage in the anterior pituitary.

Histological examination showed the usual swelling and vacuolization of the proximal convolutions in the cortex and scattered areas of intertubular edema similar to those illustrated in Figure 8. In the markedly congested subcortical medullary zone the terminal proximal convolutions and ascending limbs were compressed and filled with hyaline material and desquamated cells.

The intact epithelium of proximal convolutions was filled with hyaline droplets; these and the entrapped fluid are shown in the dissected specimens of Plate II. Droplet formation was not limited to this region but extended throughout the entire length of the proximal convolutions up to the glomeruli, so that every cross section of them in the cortex was filled with large Gram positive droplets (Figure 14). The integrity of the cells, even when crowded almost to bursting, was apparently preserved for, when visible among the massed droplets, their nuclei appeared normal (Figure 15).

Essentially similar alterations were observed in the kidneys of Case 8. This man was admitted with a typical 5-day history and a temperature of 103°. On the sixth day he went into shock and in spite of treatment, including the administration of 4 units of albumin in 24 hours, he died on the next day. His urinary output was 1410 cc.; there was a 3+ proteinuria.

At autopsy the usual subcortical congestion and pituitary hemorrhage were present. The histological appearances were very similar to those described in the previous case, hyaline droplets filling the cells in cross sections of proximal convolution throughout the cortex as well as in the terminal segments where entrapped albuminous material was concentrated.

\* \* \* \* \*

A résumé may now be given of the development of the renal lesion as it is seen during the first week of EHF, a period including the Febrile and the Hypotensive Phases of the disease, in individuals where its further evolution was arrested by death from circulatory collapse. Combining the physiological, clinical and pathological data, the following would appear to be the course of events.

In the Febrile Phase, which initiates the clinical syndrome, the physiological evidence of high clearances indicates that renal blood flow is either normal or increased. In the transition from the Febrile to the Hypotensive Phase, various clinical phenomena appear which indicate widespread damage to small vessels, capillaries and venules; the intense and increasing flush of the skin and mucous membranes and, more certainly, widely dilated nail bed capillaries detectable by micro-

scopic examination (14) are indications of loss of arteriolar tone and vasodilatation. It is noteworthy that skin hemorrhages in the form of petechiae develop somewhat later. A rising hematocrit without corresponding increase in serum protein concentration and the post-mortem finding of T-1824 which has escaped into massive retroperitoneal edema are conclusive demonstrations that plasma is now leaking from the damaged vessels. The abrupt occurrence of a heavy proteinuria, which in the Febrile Phase had been insignificant or absent, shows that the renal capillaries as well are involved in this general vascular lesion.

Renal blood flow now decreases as indicated by a depression of clearances (2, 3); this may occur independently of general circulatory collapse and is exaggerated when primary shock intervenes, as it did in all the cases of this series. The result of this decreased flow through the kidney is, however, quite different in case of EHF than it is in the individual with normal renal vessels who suffers a similar circulatory depression as a result, say, of surgical shock. In both instances there is one factor in common—the distinctive anatomical pattern of the vascular bed in the subcortical zone of the medulla; in the kidney of EHF, however, this peculiar vascular bed is abnormal since the vessels which compose it are both atonic and permeable.

The vascularization of the medulla has been the object of extensive anatomical and functional study in recent years. The older descriptions of the *arteria rectae* which supply it from efferents of glomeruli in the juxta-medullary zone of the cortex have been amplified by the studies of Trueta, Barclay, Daniel, Franklin, and Prichard (11), which demonstrate their relatively large diameter. In extensive anatomical and physiological experiments, Block, Wakim, and Mann (15) have revealed the complexity of the reactions that occur in the subcortical zone to various abnormal situations, in particular those of shock and related conditions. Barrie, Klebanoff and Cates have described this vascular bed most aptly as the "arcuate sponge" (16) and have pointed out the possibility of free communication by sinusoids between the arcuate arteries, the medullary network and the veins.

Although there have been some differences in

interpretations of the functional effects of these anatomical peculiarities, our examination of the disturbed renal circulation in the acute renal failure associated with traumatic and toxic injury (10) agrees in both its experimental and pathological aspects with the more detailed and exact studies of Block, Wakim, and Mann (15). These investigators point out three constantly occurring phenomena in their varied experiments in which the renal circulation was disturbed by electrical stimulation of the renal nerves, sudden clamping of the renal artery, injection of substances such as epinephrine, and the reduction by hemorrhage of the mean arterial pressure: 1) when renal vasoconstriction operates in a renal vascular disturbance it appears to be limited to the cortex alone; 2) under conditions of sharply decreased blood pressure and flow in the kidney the medulla may become congested even though blood is not flowing through it; such an appearance, therefore, does not of necessity indicate an actual "shunting" of the renal circulation past the cortex through the medulla into the renal veins; and 3) in all situations, as the blood flow fails, it is best preserved in the cortico-medullary zone of the kidney. They further point out that from the anatomical standpoint two paths are present for the flow of blood into the medulla—the long *arteriolae rectae* and the general network of peritubular capillaries which supply the cortico-medullary region. When renal blood flow is reduced, most of the flow from the cortex into the medulla is through the peritubular network into the cortico-medullary region with a corresponding decrease through the longer *arteriolae rectae* which pass to the deeper medulla. Blood flow may, therefore, continue *into* but not *through* the cortico-medullary region under circumstances in which flow is reduced to a minimum elsewhere in the kidney.

If, in the light of these considerations, one considers the situation in EHF in which after the increased influx of blood of the Febrile Phase, a reduction of flow ensues in a renal vascular bed which is atonic, dilated and permeable to the escape of plasma, it is evident how and why the intertubular vessels of the "medullary sponge" become so intensely engorged with blood in spite of the decrease in RBF which characterizes the Hypotensive Phase. As is illustrated in Figure 6 the contents of the subcortical capillaries be-

come an almost solid mass of entrapped red blood cells. Plasma which has escaped through the abnormally permeable vessel walls is found in areas of intertubular edema which may extend into the medulla (Figure 5) and, by means of medullary rays, into the cortex (Figure 8).

The effect of these circulatory disturbances on the nephrons is already apparent in the studies of individuals who died in primary shock. In the earliest example (Case 38, Figures 1 and 2) they were so minimal as to be of doubtful significance as a factor in the renal lesion. If death from circulatory collapse had not occurred, it is reasonable to suppose that a return of renal blood flow would have resulted in complete restitution of a normal renal status. In most of the examples of the Hypotensive Phase described, however, there was definite and increasing evidence of damage to nephrons, so that here again the structural changes and the physiological aspects of the renal lesion correlate with the clinical indications of a beginning "renal failure" that were shown in the rise of BUN.

The earliest tubular alterations to develop, present indeed in slight degree in Case 38, were swelling and subsequent vacuolization of both the cortical and medullary portions of the proximal convolutions. Except for the increase in volume of the renal cells and a decrease in the density of their cytoplasm which reached its maximum in Case C (Figures 10 and 11), there was no great alteration of their configuration; their nuclei appeared normal. One might suppose, therefore, that here again the renal lesion is reversible.

The similarity in appearance of the swollen epithelium of the Hypotensive Phase to the changes produced by Funck-Brentano by experimentally altering the osmolarity of the plasma has been noted. Whereas in his experiments hyperhydration of the epithelium may be considered the chief factor in the cause of oliguria, acting either directly by luminal compression or indirectly through a modification of renal blood flow from increased intrarenal tension, the relations are less simple in the case of EHF. Decreased urine flow was irregularly observed during the Hypotensive Phase but not the definitive oliguria to be described later, so that incidental factors, such as variations in cardiac output, fall in blood pressure, decreases in renal blood flow and consequent glomerular fil-

tration would seem to be alternative explanations for the variation in renal output in the earlier phases of the disease.

If the effects of cellular swelling and the pressure of engorged intertubular capillaries had not greatly interfered with urine flow through the lumen of the tubule, they nevertheless had produced their deleterious effect on the integrity of the nephrons. This was apparent in the irregular compression, dilatation and entrapment of proteinaceous urine and desquamated epithelial cells in the terminal medullary segments of the proximal convolutions, as illustrated in Figure 13 and Plate II.

In EHF, these tubular changes in the subcortical zone are the first evidences of a destructive damage to the nephrons which increases to irreversible and irreparable alterations in later stages of the renal lesion.

#### THE RENAL LESION IN THE PERIOD OF TRANSITION

##### (The Incidence of Intertubular Hemorrhage)

The transition from the Hypotensive Phase to that of Oliguria is characterized by physiological and clinical phenomena which indicate that escaped plasma is returning to the circulation: the hematocrit falls, retroperitoneal edema decreases and direct measurements of plasma volume are higher. In spite of these evidences of circulatory recovery, fatal "transition shock" may occur, apparently due to arteriolar dysfunction (9, p. 695). Eight fatalities occurring under these circumstances appear in this series; all of these showed the development of a structural alteration previously unencountered.

This characteristic lesion of the Transition Period was the appearance of hemorrhage in the congested subcortical zone. Whereas in the previous Hypotensive Phase the excess of blood was contained within greatly dilated intact intertubular vessels (Figures 4 and 6), foci of exudative hemorrhage were now seen scattered widespread through the area of congestion.

Case 39 was admitted on the fourth day of his illness with a temperature of 101°, a blood pressure of 100/80 mm. Hg and a 4+ proteinuria. He went into shock shortly after admission and remained in circulatory collapse, with remissions, in spite of 9 units of serum albumin and other

treatment until his death on the seventh day. On the fifth day, his hematocrit was 49.5 per cent. His urinary output was 150 cc. the day before death and the BUN was 50 mg. per cent. Certain details of his clinical course are shown in Text Figure 4.

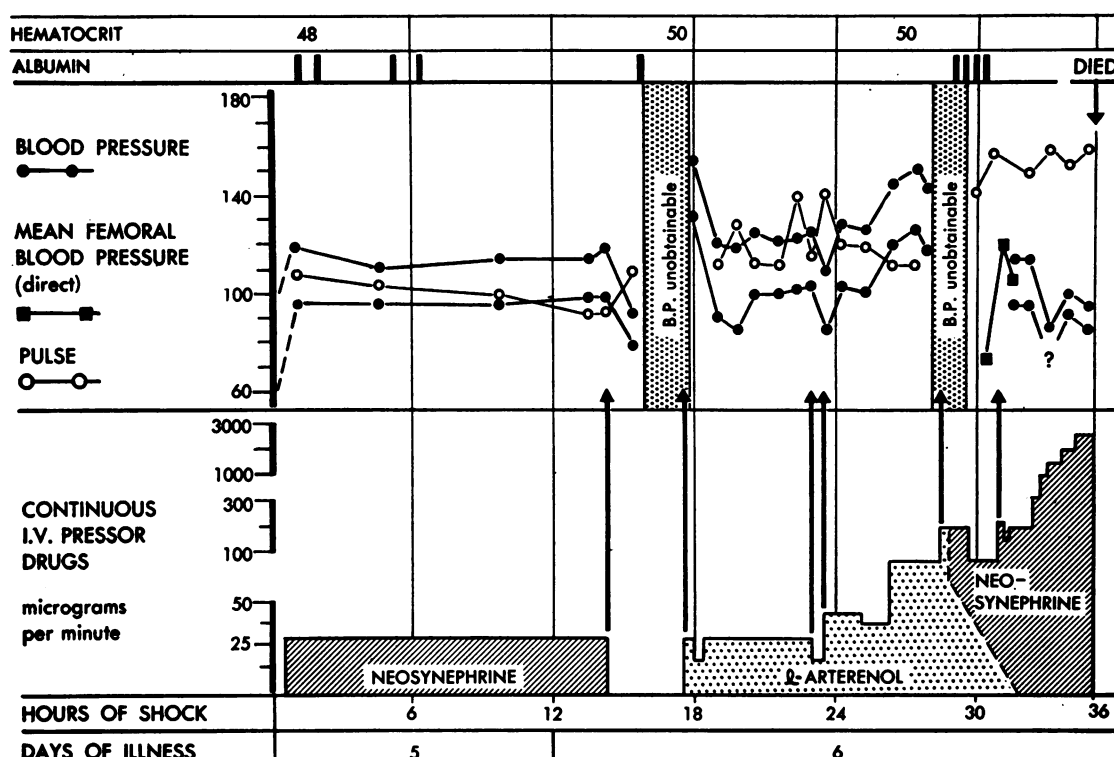
At autopsy there was only a moderate retroperitoneal edema; the kidneys showed the typical congestion of the cortico-medullary zone, and the usual extensive hemorrhage was present in the anterior pituitary.

The general condition of the kidneys was an exaggeration of what has been observed in the more severe cases during the Hypotensive Phase. Swelling and epithelial alteration of the proximal convolutions and scattered focal areas of intertubular edema were present in the cortex (Figure 16); entrapment of albuminous fluid and desquamated epithelial cells was seen in the straight tubules of the subcortical zone of congestion (Figure 17), which, along with irregular areas of intertubular edema, extended into the deeper medulla reaching the papillae. The ducts of Bellini were filled with renal failure casts (Figure 18).

In the subcortical zone of congestion, many capillaries, though packed with red blood cells, were intact; though the outlines of the vessels were still visible, the intertubular spaces between certain tubules contained free red blood cells.

Three other cases, 8, 4 and 27, were so similar in their clinical behavior and in the nature of the pathological lesions found at autopsy that a description of them would be needlessly reiterative. All showed a somewhat higher elevation of BUN; on admission the BUN figures were 27, 49 and 12 mg. per cent, respectively, and on the day before death, 117, 117 and 122 mg. per cent. Proteinuria showed a similar increase from 1+ on admission to 4+ on the day of death, which occurred on the ninth day of illness in the first case and the eighth day in the other two.

Case 28, who died of transition shock on the tenth day, illustrates the acme of intensity in the renal lesion present in this series. He was admitted on the fifth day of his illness with many petechiae and a 3+ proteinuria. He immediately went into shock. In spite of temporary improvement under the usual treatment, which included the administration of 16 units of concentrated se-



TEXT FIG. 4. CASE 39—EXAMPLE OF TRANSITION SHOCK IN HEMORRHAGIC FEVER

Note the dependency of blood pressure on pressor therapy and the relative ineffectiveness of serum albumin therapy despite minimal increase in hematocrit.

rum albumin in 72 hours, he passed from one episode of shock to another, 14 in all, to death on the tenth day. The hematocrit was 53.5 per cent on the first day of hospitalization, and 51.3 per cent on the day before death. A urinary output of 200 cc. was noted on the first day and "less than 50 cc." in the remaining period. Blood urea nitrogen was 58.5 mg. per cent on the day preceding death.

At autopsy only a moderate retroperitoneal edema was observed; the kidney showed extreme subcortical congestion and there was a hemorrhage in the anterior pituitary.

Histological examination showed the subcortical zone to be the seat of widespread infiltrative hemorrhage; the intertubular capillaries, which in examples of earlier stages of the disease were widely distended but whose endothelium was still intact, were now no longer visible as distinct channels. The fibrillar remnants of their walls, however, could be seen scattered through the irregular spaces which, densely packed with red

blood cells, isolated each tubular cross section from its neighbor. The enclosed tubules were compressed and distorted and their epithelium necrotic and desquamated so that the characteristic cellular pattern of the various tubular segments was lost (Figure 19).

This intense vascular disturbance separated the cortex by a broad band from the deeper medulla; it was not, however, confined to the subcortical zone. Extending into the cortex with decreasing intensity as the capsule was approached were extensions of the same extreme congestion and frank intertubular hemorrhage (Figure 20). In the areas free of congestion and hemorrhage, the epithelial cells of the proximal convolutions showed the usual swelling and vacuolization of the earlier periods; in tubules surrounded by infiltrating hemorrhage, necrosis of portions of the entire wall including the basement membrane was apparent (Figure 21). The intact epithelial cells of the proximal convolutions were crowded with great numbers of hyaline droplets, both in the

cortical convolutions and in those few terminal straight segments in the subcortical zone which were better preserved.

Congestion, hemorrhage and tubular necrosis also extended deep through the medulla into the papillae. Straight tubules, including collecting ducts, were thus isolated and compressed; their epithelium and even the basement membranes were necrotic over great stretches of their extent (Figure 22). The large ducts of Bellini were surrounded by widely dilated vascular spaces and scattered areas of hemorrhage, and contained renal failure casts (Figure 23).

Dissection of nephrons showed the nature and widespread distribution of the tubular damage, and in particular its topographic relation to the subcortical zone of intertubular hemorrhage.

In Plate III, A to D, all that remained of a proximal convolution is shown; the degree and extent of irregularly scattered tubular disruption as observed when a continuous tubule is examined, rather than in the interrupted cross sections of a histological section, are apparent. Beginning at the origin of the convolution, its cellular pattern is markedly disturbed as can be appreciated by comparison with the more normal convolution of Plate I; nuclei are obscured in the disintegrating cytoplasm of the tubular epithelium, which forms irregular masses of deeply stained material alternating with areas of more lightly stained disrupted tubular wall. The lesion increases in intensity (Plate III, B and C) as the straight segment leaves the cortex and enters the subcortical zone.

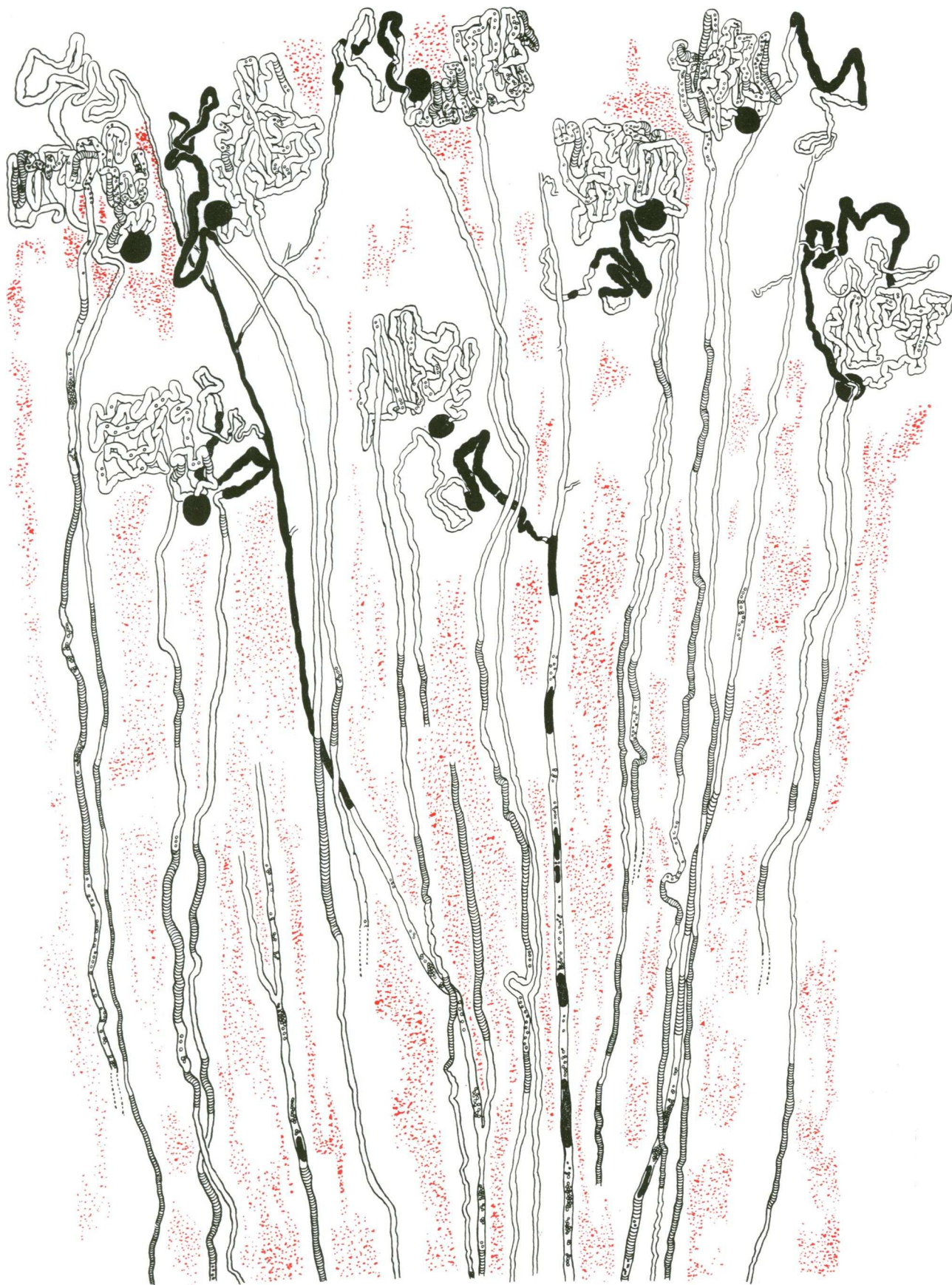Here the tubule thins to a bare basement membrane which ultimately disappears as its course is interrupted by complete disintegration (Plate III D). An exact determination of the percentage of proximal convolutions thus physically interrupted was impossible since the lesion consists of a gradual attenuation of the tubule in which a few fibrillar remnants indicative of its former course remain. Such remnants are so fragile that they cannot be dissected, and though in a sense they might be considered still existent, they certainly can have none of the functional attributes of a tubule, even the mechanical effect of constituting a confining channel for fluid. Regarded from this simplest of tubular functions, only a few intact terminal proximal convolutions could be found in the zone of hemorrhage.

As previously mentioned, the hemorrhagic area formed an almost continuous band between the cortex and deeper medulla, and extended to the papillae by irregular infiltrations. Within these extensions of the hemorrhage all tubules showed in varying degree the deleterious effect of pressure and anoxia. In Plate IV a fairly intact loop of Henle lying within the hemorrhagic zone is shown, throughout the course of which irregular stretches of damages are evidenced by cellular detritus and the obliteration of nuclear detail; at the bend of the loop the tubule is filled with a dense coagulum which stains black.

Dissected collecting tubules passing through the zone of hemorrhage, though they had preserved their external configuration, were in great part entirely necrotic, showing nothing of the distinctive clear cellular pattern which characterizes these structures; their luminal space was filled with debris and densely black stained casts (Plate V).

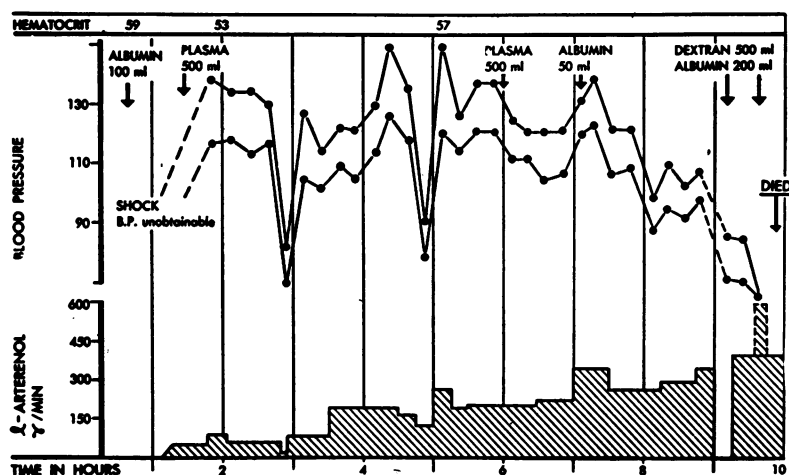
Returning to a description of the cortex in which lay portions of nephrons which, in relation to the direction of urine flow, lay both before and beyond the interrupting band of subcortical hemorrhage, it was evident that the tubules distal to the zone were not only much better preserved than the severely damaged terminal proximal convolutions which lay in it, but in general were less severely affected than the first portions of the cortical proximal convolution which led directly from the glomeruli.

In Plate VI, the origin of a collecting duct is shown with four ascending limbs which, passing into distal convolutions, join by way of connecting tubules to form the peripheral origin of the collecting system. All these structures lay in the outer cortex beneath the capsule and were not involved by the irregularly scattered hemorrhagic infiltration that extended from the subcortical zone. It will be noted that all these tubules are, compared to the severe damage illustrated in the cortical portions of proximal convolutions (Plate III), relatively well preserved. There is, therefore, as in all examples of acute tubular necrosis and renal failure, no preferential damage to the "lower nephron" but rather the reverse. The normal cellular pattern of the ascending limbs that lie in the cortex is visible although some are dilated and contain coagulated material and debris.



TEXT FIG. 5. A RENAL LOBULE FROM CASE 28 WHO DIED OF TRANSITION SHOCK ON THE TENTH DAY

Note the extensive subcortical intertubular hemorrhage with extension into the cortex. Necrosis of tubules within the involved areas. Heavy black, glomeruli and casts within tubules; cross-hatching, necrosis of tubules; small circles within tubules, desquamated cells and debris. Many terminal proximal convolutions end by disruption in the zone of hemorrhage. Magnification 18  $\times$ .



TEXT FIG. 6. CASE 42—EXAMPLE OF FATALITY IN SEVERE PRIMARY SHOCK IN HEMORRHAGIC FEVER DESPITE CONTINUOUS L-ARTERENOL INFUSION

This patient was in severe shock when admitted and blood pressure was unobtainable until given both plasma volume expander and an infusion containing a large amount of L-arterenol. Accidental stopping or slowing of the infusion resulted in marked decrease in blood pressure. The severe shock that followed the second episode did not respond to further plasma volume expanders or heroic pressor therapy.

The distal convolutions are also dilated, and though cellular detail is obscured by the intense black staining of the solid coagulum that distends their lumens, occasionally a flattened but intact epithelium is visible. The connecting tubules are not dilated and in most instances are free of black stained coagula; this dense material appears again in the peripheral collecting tubules and, obscuring cellular detail, fills the remaining portion of the collecting duct.

Text Figure 5 shows a reconstruction of a lobule from camera lucida drawings of dissected nephrons; it may be compared with Text Figure 3, a similar reconstruction of the earlier stage which showed so little departure from normal topographical relations. The important features now noted are: 1) the presence of an irregular band of hemorrhage separating cortex from medulla; 2) the extension of the congestion and hemorrhage to the papillae on the one hand and, in diminishing scattered areas, to the surface of the kidney on the other; 3) the interruption by necrosis of the majority of all the tubules, terminal medullary segments of proximal convolutions, descending and ascending limbs—both broad and thin—and collecting tubules, which pass through the zone of

hemorrhage; and 4) the dilatation with coagulated proteinaceous material of those tubules which lie in the cortex distal to the zone of hemorrhage.

The clinical course of Case 42 is shown in Text Figure 6; admitted in a state of shock on the fifth day of illness, he died in 10 hours in spite of treatment that included the administration of  $3\frac{1}{2}$  units of serum albumin and 500 cc. Dextran; 400 cc. of urine were passed. At autopsy a moderate retroperitoneal edema was present as well as the usual subcortical congestion in the kidney and hemorrhage in the pituitary.

Histological examination showed an intense hemorrhagic infiltration throughout the cortico-medullary zone. The outlines of the intertubular capillaries could not be made out, red blood cells filling the spaces between the cross sections of tubules in densely packed masses. Congestion and hemorrhage extended deep into the medulla and also into the cortex. Many of the proximal convolutions in the cortex were filled with hyaline droplets; the nuclei of the cells containing them were well preserved. In the areas of subcortical intertubular hemorrhage the tubules were compressed and distorted and their epithelial walls destroyed.

The two remaining cases, which showed massive intertubular hemorrhage in the congested cortico-medullary zone, and which were considered clinically to have died in the late Hypotensive Phase or in the Transition Period of shock, may be briefly mentioned, as the renal lesions were essentially similar to those which have been described. Case 17 survived for 10 days, the last 5 days of which he was in more or less continuous shock in spite of intensive treatment which included the administration of 12½ units of serum albumin during the last 4 days. During this period he passed 190 cc. of urine; it is of interest that his urine had been free of protein during the Febrile Phase until the fifth day, when, with the onset of the Hypotensive Phase, it suddenly showed a 4 + proteinuria.

Case 1 was admitted on the fifth day of illness with a blood pressure of 90/60 mm. Hg, and died the next morning in shock. Two units of serum albumin were given; with a total fluid intake of 1500 cc., his urinary output was 390 cc.

The structural changes were essentially similar in these two cases. Intense subcortical intertubular hemorrhage was present with extension into the papillae and less to the cortex, with tubular destruction not only in the medullary zone but scattered irregularly throughout the cortex and deep medulla. In the individual who had received 12½ units of human serum albumin, the cells of the better preserved convoluted tubules were filled with droplets; these were present but sparse in the other, who had been given 2 units.

\* \* \* \*

Since the period covered by the group of cases just described is by definition transitional from the Hypotensive to the Oliguric Phase, a discussion of the structural findings can be postponed until the full development of the renal lesion in the next period has been given. An important correlation between clinical and pathological aspects should be noted in passing; as the clinical phenomena required the special recognition of an interim between two major phases in the term Transition Period, so the finding of a distinctive structural element, intertubular hemorrhage, sets this period off pathologically in the evolution of renal lesion. There has been no need for such a subdivision in descriptions of general Acute Renal Failure, for

no such structural distinction in the form of subcortical hemorrhage occurs.

As will become apparent when the functional effects of this new development are described, its importance in the ultimate fate of the kidney as a collocation of nephrons is critically determinative.

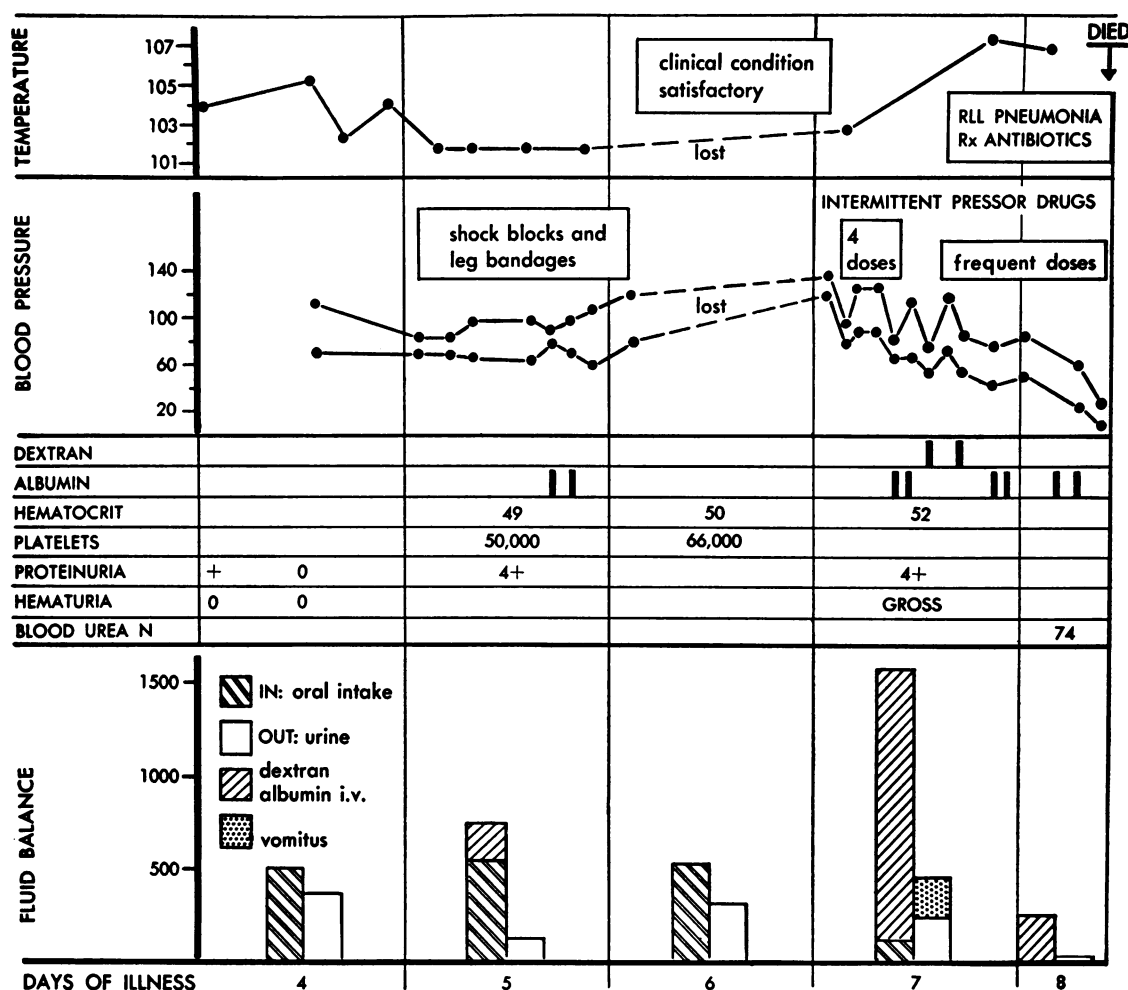
#### THE RENAL LESION IN THE PHASE OF ESTABLISHED OLIGURIA

(Infiltrative Intertubular Hemorrhage and Stasis;  
Tubular Necrosis and Intrarenal  
Obstruction)

Intertubular hemorrhage resulting from increasing congestion that proceeds to ultimate stasis in damaged terminal vessels is not, by the nature of its origin, a sudden event but a gradual infiltration that develops at varying rates depending on the severity of both congestion and vascular damage. It is not surprising, therefore, to find its structural and functional effects spread over three phases of the renal lesion, the late Hypotensive, the Transition Period and the Oliguric Phase.

Ten cases, each of whom died on or between the eighth to eleventh days, presented the clinical characteristics of an established oliguria and showed the full development of the renal transformation of EHF. The physiological disturbances, in particular the detail of fluid balance, of a typical example, Case 23, are shown in Text Figure 7. All cases showed the lesions which have been noted above in our description of those who died in late primary or transition shock, *i.e.*, a subcortical zone of intertubular congestion and hemorrhage with extension of both to the deep medulla and in lesser degree to the cortex, with tubular disruption of those portions of nephrons which were included in the affected areas.

All ten cases showed in addition, however, an added structural change which characterized the Phase of Established Oliguria pathologically, namely, a marked dilatation of the cortical tubules of the nephrons. This is illustrated in Case 31, an individual who entered hospital on the fourth day of his illness, went through the Hypotensive Phase with shock, for which he received 2 units of albumin, and passed into the Oliguric Phase in which he died on the eleventh day with a BUN of 184 mg. per cent. His fluid intake during the last five



TEXT FIG. 7. CASE 23—EXAMPLE OF DEATH IN SECONDARY SHOCK DURING OLIGURIC PHASE OF HEMORRHAGIC FEVER

Primary shock on fifth day during Hypotensive Phase was mild. Subsequent slight increase of hematocrit was presumably due to dehydration rather than to continued capillary leakage of plasma. On the seventh day the patient developed right lower lobe pneumonia and hyperpyrexia that precipitated shock not responsive to therapy. At autopsy characteristic findings of hemorrhagic fever were present, although there was no retroperitoneal edema. In addition, a patchy pneumonia chiefly in the right lower lobe was noted.

days was 4184 cc. and his urinary output was 360 cc.

Histological sections showed a wide dilatation of all tubules in the cortex. In the case of the dilated proximal convolutions, the distention reached Bowman's space with a resulting compression of the glomerular tuft (Figure 24). Not only those portions of the nephrons lying proximal to the zone of medullary hemorrhage were distended but the cortical ascending limbs and distal convolutions, the latter containing cellular debris, were also dilated. The relation of this tubular dilatation

to the compression of the subcortical zone of hemorrhage is shown in Figure 25.

The effects of the dilatation of all the cortical portions of the nephron are shown in dissected specimens in Plate VII, A to D. The wide lumen of the proximal convolution is clearly apparent throughout its entire length, as can be seen by comparison with Plate I; the stretching of the epithelial wall increases the space between the nuclei, and so exaggerates the cellular pattern. The epithelial cells are, however, fairly well preserved. As its terminal segment approaches and enters the

subcortical region of congestion it narrows to one-third its previous diameter and is lost in the intertubular hemorrhage. A portion of ascending limb and the distal convolution from the cortex, which was originally entwined with the dilated proximal, and which was therefore known to be the continuation of the same nephron, show an equal dilatation; there is some dark stained material in the distal convolution.

In Case 25 there was more than the usual cellular damage in proximal convolutions, and evidences of beginning repair were visible both in regenerative mitotic proliferation of epithelium (Figure 26) and in the ingrowth of interstitial granulation tissue into the disrupted tubule lumens. Case 41 showed somewhat less dilatation of the lumens of the cortical tubules, and scattered areas of intertubular edema (Figure 27). The remaining cases showed the general picture of cortico-medullary hemorrhage and dilatation of cortical tubules above it, but added nothing further towards the elucidation of the renal lesion.

\* \* \* \* \*

It is in the Phase of Established Oliguria that the structural and functional lesions of EHF reach the height of their evolution. When the structural changes in the nephron are thus fully established they appear to constitute an irreversible status, for though a "kidney" of sorts might evolve from those nephrons which by the fortunate circumstance of their location had escaped the effects of congestion and hemorrhage, the reconstitution of nephrons whose middle half has been destroyed would seem impossible. We shall see in later descriptions that the attempt is made, but the appropriate anastomosis of four frayed ends of fragile tubule lying loose in a mass of interstitial hemorrhage under considerable pressure is on the sheer basis of probability unlikely, even when the potentialities of repair are present. It would seem, therefore, that the renal lesions we have seen in the fatal cases of established oliguria could not have existed in similar quantitative relations in the great majority of those suffering from EHF, for they survived and went on to eventual recovery.

In the earlier stages of the syndrome tubular damage was evident in the general swelling and vacuolization of the epithelium of the proximal convolution, whereas in the Transition Period and

Oliguric Phase the tubular alteration consists of localized physical disruption; the two lesions are therefore quite different in their structural aspect. Though the early epithelial changes are of the sort that have been classically derived from "toxic action," there has been no demonstration of a toxin in EHF other than the hypothetical substance which acts on the small blood vessels. Disturbances of circulation, however, are clearly visible at this time, so that it seems reasonable to accept them as the cause of the early epithelial damage.

Structural interruption of the nephrons involves proximal convolutions, ascending and descending limbs of Henle's loops and collecting tubules indiscriminately. The damage is confined to the areas of congestion and hemorrhage, and so lies chiefly in the medulla, but is also present extensively throughout the cortex when the circulatory disturbance has spread to this area. Here again, it would be difficult to explain this random distribution in terms of the direct action on the renal epithelium of a nephrotoxic poison derived, hypothetically, from the infectious agent of the disease. The histological appearance of the epithelial lesion is also not that of nephrotoxic damage, in which epithelial cells, absorbing the poisonous substance, die and desquamate within a tubule still maintained by an intact basement membrane. There has occurred, rather, a disruption of the entire tubule wall, the tubulorhexic lesion characteristic of the kidney of Acute Renal Failure (10). The inference seems certain, therefore, that the tubular lesions of EHF, both early and late, are the result of circulatory disturbances. This conclusion does not, of course, rule out the primacy of an infectious agent or its products as the cause of the vascular disturbances, for recent experiments by Thal (17) in the production of bilateral cortical necrosis by means of staphylococcus toxin show how this may be produced in the kidney and so result indirectly in extensive tubular damage. There are many similarities between the nature of the tubular lesion in his experiments and what is seen in the kidney of EHF; the differences in topographical distribution seem less important, for, as Thal points out, "cortical necrosis" is not so restricted as the descriptive term would suggest, nor are the tubular lesions of EHF limited to the medulla.

There is evidence that the circulatory disturbance acts on the tubule by means of two deleterious forces; the first, and perhaps less important, is physical pressure, and the second is anoxia following the congestive stasis and the infiltrative intertubular hemorrhage which has produced a cessation of circulation in the involved areas.

Evidences of pressure, especially on the more sensitive proximal convolutions, were seen in the earliest stages of the renal lesion where there was only a simple and moderate congestion of the terminal vessels of the subcortical zone. With an increase in vascular distention the effect of increasing intertubular pressure was evident in the compression and consequent entrapment of proteinaceous fluid in the lumens of the terminal proximals that lay in the involved area (Figure 13 and Plate II), and its final effect is demonstrated by the "intrarenal hydronephrotic" tubular dilatation which ultimately develops in the definitively oliguric kidneys (Figure 24). This dilatation involved all the tubules lying in the cortex above the subcortical zone of pressure and included not only proximal convolutions which are, in regard to the direction of urine flow, proximal to the zone of compression in the medulla but also the distal convolutions, cortical ascending limbs and peripheral collecting tubules which lie distal to it.

This apparent paradox of postobstruction dilatation arises from current misconceptions of the topographical arrangement in the human kidney of nephrons of varying length. In most diagrams (Peter, 18, Figure 63) two types of nephrons are shown, short-looped and long-looped, both of which pass through the outer stripe of the outer zone which in EHF is the zone of hemorrhage. If this were an accurate and complete picture of the human kidney, the distal convolutions and collecting tubules would be cut off from the source of glomerular filtrate and could not dilate. As a matter of fact, the human kidney contains a very considerable number of nephrons similar to those shown in Peter's diagram of the pig's kidney (18) which turn within the cortex and never reach the medulla. An example is given in our Plate VIII, A to C; many have been shown elsewhere (19).<sup>4</sup>

<sup>4</sup> Work in progress in this laboratory on quantitative aspects of the morphology of nephrons shows that their classical subdivision in the human kidney into two arbitrary groups of "long-looped" and "short-looped" neph-

In a kidney with a zone of subcortical obstruction glomerular filtrate can therefore flow through uninterrupted cortical nephrons to the point of origin of the collecting system (*cf.* Plate IXA) and from thence to all distal portions of the neighboring nephrons which are connected with it, even when they have been shut off from their normal source of filtrate by the zone of medullary hemorrhage. This retrograde flow is in fact favored by the obstruction in the lower collecting system which itself passes through the obstructing zone of hemorrhage.

The question may be asked why then do not all kidneys which suffer extensive disruption of their nephrons, such as, for example, Case 28 of the Transition Period, show extensive tubular dilatation in their cortices. The answer would seem to be that for dilatation to occur there must be an adequate source of filtrate; a comparison of Figures 20 and 24 suggests that in the former case the extreme cortical congestion and hemorrhage is incompatible with a sufficient glomerular circulation and consequent formation of filtrate. Thus a lesion which interrupts tubules in the medulla yet spares the circulation in glomeruli is necessary for the development of the tubular pattern observed in the Phase of Established Oliguria.

The discussion of these minutiae concerning fluid flow in damaged nephrons would seem to warrant attention not so much for an importance inherent in their functional effect—for in both the situations described above urinary output was similarly lessened—but as illustrating how the same or similar pathological processes can by variation in their temporal or spatial relations modify or even change the direction of the evolution of the renal lesion. In the examples cited it was a spatial relation; in the ensuing Phase of Diuresis it is temporal. In any case, the simple statement that this lesion or that is present in a section of kidney is meaningless as a description of the structural-functional renal status.

The structural evidence of physical impedance to the flow of urine through the nephrons is of

rons is a considerable and, as in the present case, at times misleading oversimplification. Our findings show that the loops of nephrons are indeed of varying length but that this variation can be described by a normal frequency distribution curve rather than by absolute categories; in short, some loops are longer than others.

interest to others in addition to the theoretical pathologist. The clinical observers who noted varying degrees of reduction in urinary output in the earlier Hypotensive Phase recognized the distinctive and definitive character of the oliguria which ensued in the later period, and so designated it to the Phase of Established Oliguria. The structural findings show that the distinction is real, since it is based on a difference in causal mechanisms. In the earlier Hypotensive Phase no structural lesion other than evidences of disturbed circulation was present in the kidney to account for decreases in urinary volume, and it is therefore reasonable to suppose that factors such as variations in tissue hydration, cardiac output, renal blood flow and glomerular filtration were responsible for this variable oliguria. In the later phase, what "established" the oliguria is clearly evident in the compression and destruction of tubules and the obstructive dilatation of nephrons that followed.

Of greater importance than pressure effects in the production of tubular damage is the anoxia that results from the stagnation and cessation of blood flow in the widely dilated and abnormally permeable intertubular capillaries of the subcortical zone. It would appear likely that the blood is moving with some difficulty under such circumstances as are shown in an earlier period in Figure 6, where crowded red blood cells are packed to a solid hyaline mass. Any doubts that circulation may cease entirely under these conditions have been answered by the conclusive experimental demonstration of Thal (17), who injected India ink into the general circulation of the living rabbit with an analogous renal "stagnation hyperemia" and found that it did not penetrate into vascular channels which were similarly distended and packed with red blood cells. The further evolution of the congestive lesion in EHF through diapedesis to frank, diffuse intertubular hemorrhage ends, therefore, in stasis.

Under the conditions here described we are dealing with what Ricker, in his classical study of the nature and effects of local circulatory disturbances (20, p. 96 *et seq.*), would have called "rote stasis," and from the late irreversible stage of this rubrostasis he would have derived the "Sequestrationsnekrose" that interrupted the course of the nephrons. It is of particular interest in our problem that in his examination of these effects in various tissues and organs he chose, in the case of

the kidney, the necrosis that is produced experimentally by injection of vinylamin. This toxic agent differs from other renal poisons by producing necrosis of tubules in the medulla rather than in the proximal convolutions of the cortex.

Ricker points out that the lesion of vinylamin poisoning begins in the papilla with a "prästatisch" hyperemia followed by diapedesis of red blood cells, and progresses to "Stasis" and eventual "Dauerstasis." The vascular disturbance in his experiments extended to the subcortical zone, and in one instance to the cortex, with resulting necrosis of tubules in the involved areas. His conclusion that the tubular damage cannot be the result of either a functional secretion or absorption of the poison by epithelial cells, as was suggested by Oka (21), or due to specific "affinity" for the poison as Levaditi (22) assumed, has been convincingly confirmed by subsequent evidences that proximal convolutions, Henle's loops and collecting tubules cannot be considered functionally similar; hence it would not seem likely that they should all absorb a poison similarly or, much less, be given to the same "affinities." We can accept, therefore, Ricker's explanation that the tubular necrosis is a phenomenon of ischemic sequestration due to the anoxia of the vascular disturbance;<sup>5</sup> with his broader conclusion that local circulatory disturbances are mediated through the nervous system we need not here be concerned.

#### THE RENAL LESION IN THE PHASE OF DIURESIS

##### (Intertubular Hemorrhage; Tubular Disruption with Evidences of Resolution, Regeneration and Repair)

The remaining cases in this series show structural changes that should be considered as illustrative of the effects of the passage of time on the

<sup>5</sup> Ricker also compares the action of vinylamin with that of mercury, which damages the proximal convolutions; this effect he also derives from circulatory disturbances and not from direct nephrotoxic action on the epithelium. Here, modern studies, histochemical and pharmacological, do not support his contentions, though it should be noted that he anticipated a later demonstration (10) that the vascular element of ischemia may play an important if subsidiary role in the production of tubular damage (tubulorhexis) in renal lesions of poisoning. A recent study by Lindegård and Löfgren (23) has confirmed and extended these observations by demonstrating an irregular cortical ischemia not only in the anuric phase of mercuric poisoning but also in its diuretic phase.

fully developed lesions of the Oliguric Phase rather than as representative of the exact picture of the Diuretic Phase observed by the clinician during the recovery of the great majority of his cases. If the individual in the Oliguric Phase does not die of secondary shock, dehydration, electrolyte imbalance or infection by the eighth to tenth days, but survives another week or two, the processes of resolution, regeneration and repair, as in all pathological complexes, begin their automatic operation. A part of these mechanisms of restitution is the functional phenomenon of diuresis. As the pathologist sees them, the progress of these processes, even if in the right direction, is blind and in the end futile, and the individual dies of a renal failure often obscured by some complication such as the infection of a bronchopneumonia, the hyperkalemia of electrolyte and fluid imbalance, or a cerebral accident. It would seem unlikely that these complications can be merely incidental to the renal lesion, but rather it seems that in some manner, either directly or indirectly, renal insufficiency is the basis of their development; for in all the examples studied, though the complications were various, the renal lesion, with its grave structural damage and evidence of functional inadequacy in a BUN elevated at times to over 400 mg. per cent, was constant.

What happens then in the great majority, 95 per cent of all cases of EHF, has not been seen; the description of the typical kidney in the survivor must therefore be deduced and reconstructed on a hypothetical basis, and will be further considered in our discussion.

\* \* \* \* \*

As happens not infrequently in the descriptions of passage from one phase of a disease to the next, our first case, D, might well have been classified as an example of a renal lesion at the end of the Oliguric Phase; he survived, however, 15 days and as the urinary output, though continuing low, increased somewhat on the last day but one of his life, the description was clinically placed under the title of the Diuretic Phase and will be here so considered. As will be seen, there is no evidence of restitution of disrupted nephrons and in general the renal lesion resembles that observed in the previous phase.

This patient was admitted on the fourth day of

his illness with a typical history of the Febrile Phase. The next day he abruptly developed a 4 + proteinuria. From the seventh to the tenth day he was in the Hypotensive Phase with repeated shock that responded poorly to treatment; an established oliguria followed but the urine volume increased from around 15 cc. in 24 hours to 250 cc. on the day before his death. On the twelfth day dialysis by the artificial kidney reduced the serum K from 6.9 to 4.2 mEq. per L. but the patient lapsed into coma, his temperature rose and coughing with bloody purulent sputum developed; a bronchopneumonia was confirmed by X-ray examination. On the day before his death, the fifteenth day of illness, the BUN was 484 mg. per cent.

At autopsy the kidneys weighed 300 gm. and showed the typical and fully developed lesion of subcortical congestive hemorrhage with deep medullary involvement. There was a bilateral bronchopneumonia with multiple small abscesses containing Gram positive cocci, scattered hemorrhages in the right atrium, gastrointestinal tract, the cerebral hemispheres and pons and the anterior pituitary.

Histological examination showed that congestive hemorrhage was extreme in the subcortical zone and had extended irregularly and deeply into the medulla, reaching the papillae (Figure 28). In the outer zone there was an almost complete destruction by necrosis of all tubules contained in the areas of hemorrhage, and these, coalescing, separated cortex from medulla (Figures 29 and 30). Extending downward into the infarct-like area of hemorrhagic infiltration could be seen wisp-like unoriented remnants of straight tubules; their walls were disrupted and in great part bare, but scattered along the denuded basement membranes were huge, atypical nuclei with intensely stained chromatin (Figure 31). Mitotic figures were frequent. The intensity of this excessive regenerative proliferation distorted the tubular configuration so that it was impossible to accurately identify the parts of the nephron concerned in histological section.

In the cortex the characteristic dilatation of the Phase of Established Oliguria was still present (Figure 32), involving Bowman's space and both proximal and distal convolutions; it will be recalled that in this patient's "diuresis" only 250

cc. per 24 hours was draining from the renal tubules. The epithelium of the proximal convolutions was not only thin but cellularly atypical; its nuclei were not round, but oval, and were irregularly distributed in the tubule wall, in some places forming islands of excessive proliferation (Figure 33); the appearance was that of a regenerated epithelium. Moreover, the tubules were more widely spaced than normal (*cf.* Figure 1) and the interstitial tissue was infiltrated with mononuclear cells and fibroblasts. The glomerular tufts were large with widely dilated capillaries that contained discrete, apparently circulating red blood cells.

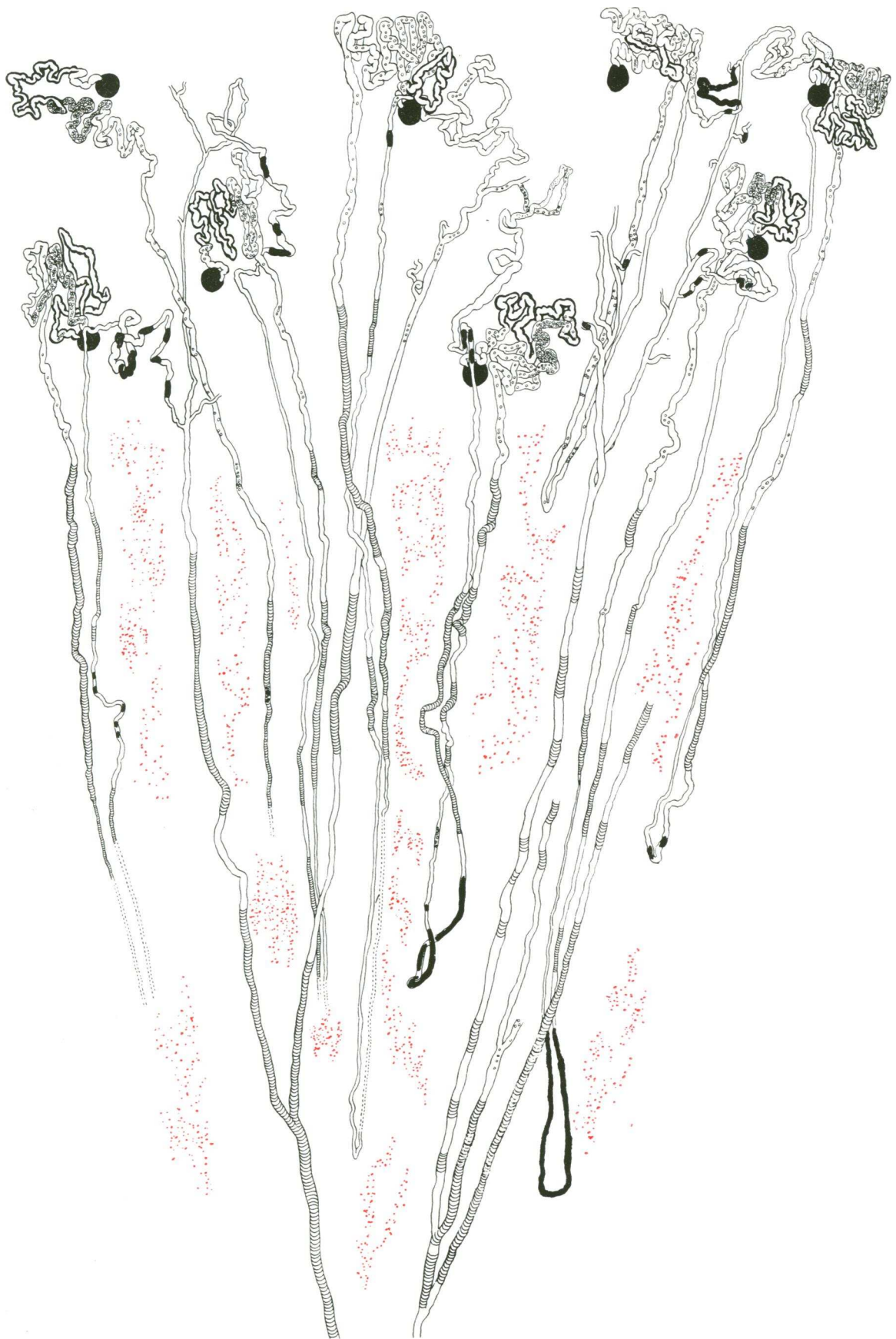The topographical aspect of the lesions just described is shown in the dissected nephrons. Plate VIII, A to C, shows a complete cortical nephron with a short loop that did not extend into the subcortical zone of intertubular hemorrhage and is therefore uninterrupted. As in all examples of acute renal failure associated with traumatic and toxic injury, the tubule is damaged from glomerulus to collecting tubule. As is usual, the damage is more severe in the proximal convolution than in the so-called "lower nephron," consisting of scattered areas of tubulorhexic disruption with the lumen containing desquamated epithelial cells. Where disruption has not occurred, the wall is composed of a heavily stained, irregularly thin layer of atypical, regenerated epithelial cells quite different from the plump, evenly contoured cells of the normal tubule (*cf.* Plate I). The transition to the loop of Henle is abrupt and there is, as in all cortical nephrons, only a suggestion of a thin portion. From here on through the loop and ascending limb and distal convolution the tubule is greatly dilated with clear tubule fluid and contains desquamated cells and debris. As is so often the case, the short connecting tubule is less distended.

Plate IX, A to E, shows the peripheral collecting system from its origin in a junction of connecting tubules of five nephrons that lay beneath the surface of the kidney to its destruction in the hemorrhagic zone of the subcortical medulla. The connecting tubules of 9 nephrons in all, filled with black stained material that obscures their epithelial pattern, join to form a collecting tubule which is empty. In many instances the collecting tubules contained similar material, but this exceptional example was chosen for illustration be-

cause it shows the cellular pattern more clearly. It will be observed that the epithelium is not disturbed until the proximity of the subcortical zone of hemorrhage is approached; scattered particles of cellular debris then appear in increasing numbers until, in the substance of the hemorrhagic zone, a complete necrosis and coagulation of the entire tubular wall is evident. The tuning-fork juncture with a neighboring collecting tubule which is similarly affected is well shown; below this point the single common duct contains black-stained material. The appearance on histological section in other cases of similar, completely necrotic collecting tubules which have nevertheless maintained their external configuration is shown in Figures 22 and 29. The general architectural pattern of the kidney is shown in Text Figure 8 in a reconstruction of the renal lobule composed of camera lucida tracings of dissected nephrons.

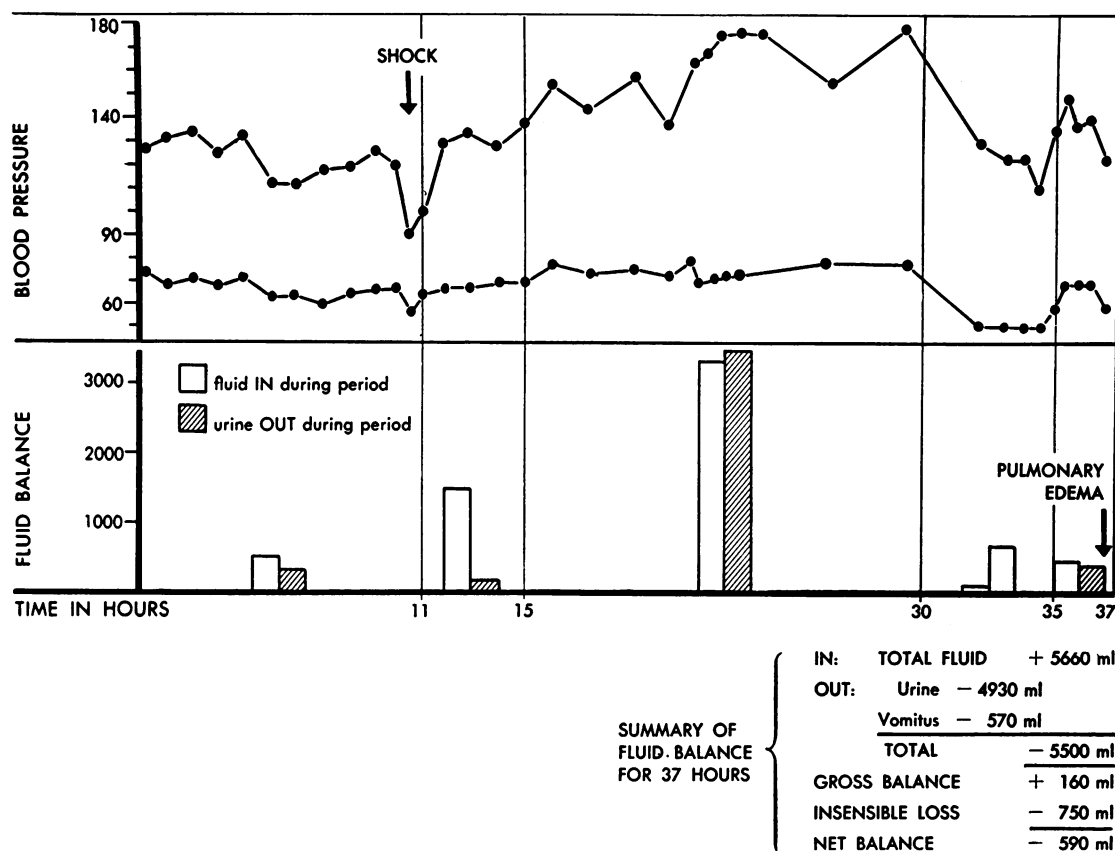
In Case 43 a frank diuresis had been established for the last five days of the patient's life, and the renal lesion has special interest because, of all the examples of this phase of the disease that came to autopsy, in this one alone resolution of whatever structural damage had occurred had reached at least the point at which one might imagine a chance of eventual functional restitution to be possible. The resulting "kidney" of such a problematical restitution would, however, have been severely deficient in its "reserve" of nephrons.

The patient entered hospital on the third day of his illness in the Febrile Phase with a temperature of 103.6°, and on the fifth day went into typical shock of the Hypotensive Phase with the hematocrit reaching 66 per cent. With appropriate treatment he passed through this episode to the Oliguric Phase, in which his average daily urinary output was approximately 100 cc. with a BUN rising to 280 mg. per cent. His blood pressure also rose (170/106 mm. Hg), and the hypervolemic syndrome accompanied by 5 convulsions followed. Daily urinary output increased rather abruptly in 24 hours on the twelfth day from 190 to 1000 cc. and reached 4600 cc. the day before his death. During this terminal period he presented the difficult problem in water and electrolyte balance of a "limited homeostasis" illustrated in Text Figure 9, so that the margin between dehydration with the threat of secondary shock and ample hydration with impending pulmonary edema was represented



TEXT FIG. 8. A RENAL LOBULE FROM CASE D WHO DIED ON THE FIRST DAY OF THE DIURETIC PHASE

Note the persisting subcortical hemorrhage with destruction of tubules. Heavy lined proximals indicate re-generated atypical epithelium (*cf.* Figure 33 and Plate VIII A) ; other symbols as in Text Figure 5. Magnification 18 $\times$ .



TEXT FIG. 9. CASE 43—EXAMPLE OF LIMITED HOMEOSTASIS DURING DIURETIC PHASE OF HEMORRHAGIC FEVER

These observations were made on fourteenth and fifteenth days of illness. Death occurred on the sixteenth day, 24 hours after study. The patient was very dehydrated at the start of the observations, having been in negative fluid balance for many days. Note the response of shock and blood pressure to increased fluids between the eleventh and fifteenth hours. Also note decrease in blood pressure between the thirtieth and thirty-fifth hours when output was allowed to exceed intake. Pulmonary edema occurred in last period when intravenous fluids were increased even though net balance was just barely positive during this time. (Note: Right-hand column, bottom line in 30 to 35-hour box should be cross-hatched.)

by a net negative fluid balance of 600 cc. During episodes of hypotension and shock the diuresis disappeared and urinary output was at oliguric levels, to rise again to 4000 cc. when arterial pressure was restored by nor-adrenalin. The last BUN taken the day before his death had decreased to 173 mg. per cent, and there was only a trace of protein in a urine of 1.011 specific gravity.

At post mortem there was found a confluent bronchopneumonia, hemorrhages in the right atrium, cerebral hemispheres and basal ganglia, and in the anterior pituitary. The gross appearance of the renal lesion is summarized in the autopsy protocol as "lower nephron nephrosis, slight."

Histological examination showed a marked contrast to the pattern of a general dilatation of all cortical tubules seen in the previous stage of established oliguria; the lumens of the proximal convolutions and other cortical tubules were not widely dilated but contained some granular material, as did Bowman's spaces of glomeruli which were otherwise normal (Figure 34). The proximal convolutions were lined with an epithelium of the original normal type; there was little evidence of any regenerative renewal of cells, such as the irregularity in thickness and nuclear size and shape and staining affinity that characterized the epithelium of proximal convolutions in most cases at this stage of the disease. The general appear-

ance was therefore of a cortex which had never been greatly damaged.

Contrasting, was the alteration in the subcortical outer stripe of medulla. Extending downward from the cortex into this zone, which had the appearance of a region of resolution of hemorrhage and replacement fibrosis, were the thickened terminal segments of proximal convolutions; their epithelium was quite atypical, varied in thickness and containing many irregularly distributed large nuclei (Figure 35). In the broad band of the affected region irregular foci of typical hemorrhagic infiltration persisted, alternating and blending with ill-defined areas where the tubules were separated not by masses of red blood cells but by cellular fibrous tissue (Figure 36); a considerable increase in collagenous fibrils surrounded atrophic tubules and fused with their thickened basement membranes (Figure 37). Extension of the fibrosis could be traced upwards into the lower cortex in the form of cellular scars which replaced tubules and surrounded glomeruli (Figure 38).

The renal lesions in five cases—two of which, 16 and 46, died on the fourth day of diuresis, two others, 11 and 19, on the ninth day, and one, 29, on the eleventh day—showed essentially similar lesions to those just described but with more evidence of previous damage and a lesser degree of restitution. In the subcortical zone of the medulla, intertubular hemorrhage still persisted in all instances with intermingled areas of resolution and interstitial reaction (Figure 39). In two of the five cases, 16 and 46, the epithelium of the cortical proximal convolutions was of the original mature type; in three, 11, 19 and 29, it resembled a replacement by atypical regenerated epithelium similar to that shown in Figure 40; in none were there the marked distention and dilatation of tubule lumens observed in the preceding Phase of Established Oliguria.

The last two cases were of the longest duration that occurred in this series and therefore present the maximum effect of the passage of time on the renal lesion that was available for observation.

The first of these, Case 33, died on the nineteenth day of his disease in the tenth day of the Diuretic Phase. He had passed through the Hypotensive Phase with two episodes of shock which responded to appropriate therapy, and an Oligu-

ric Phase of 4 days in which his urinary output averaged 250 cc. in 24 hours when the BUN reached a maximum of 286 mg. per cent. During this period he was hypertensive (158/112 mm. Hg). On the ninth day of his illness, diuresis began abruptly and continued until his death on the nineteenth day, the urinary output ranging from 1410 to 4400 cc. in 24 hours. The last days of his life were an example of homeostatic instability with repeated episodes of dehydration, hypotensive shock, fluid replacement and threatening pulmonary edema. During this terminal period he received 11 units of serum albumin. Cerebral involvement became apparent, his temperature reached 104° and he died on the nineteenth day of his illness. The BUN on the day preceding death had decreased to 145 mg. per cent.

At autopsy a confluent bronchopneumonia in addition to hemorrhages in the right auricle, pituitary, and interventricular septum were present. The renal lesion is described as showing "a fairly marked degree of congestion and focal hemorrhage in the renal medulla."

In the histological sections the proximal convolutions in the cortex were lined with an atypical epithelium. The lumens were therefore irregularly widened and contained a moderate amount of coagulated material and desquamated cells (Figure 40). The contrast in appearance between these tubules whose lumens were somewhat increased by the irregularity of their epithelium and the frank and even distention of a tubule dilated by internal pressure, as occurred in the Oliguric Phase, may be seen in a comparison of Figures 40 and 24, and of Plates X and VII. Bowman's space was not dilated and the glomerular tufts appeared normal. The tubules of the cortex were widely spaced and the interstices filled with a loose fibrous connective tissue in which were clusters of round cell infiltration. In the subcortical zone of the medulla and extending to the papillae extensive areas of persisting intertubular hemorrhage were seen; in these areas the smaller tubules were widely separated and apparently reduced in number, but the larger collecting tubules were not only intact but showed an extreme and irregular proliferation of their distinctive epithelium, which formed irregular plaque-like formations distorting the normally even contours

of their lumens (Figure 41). The resulting distortions of the terminal collecting tubules and the ducts of Bellini entering the pelvis, the latter filled in part with renal failure casts, are shown in Plate XI.

Case 18 survived 27 days; he had passed through the typical Febrile and Hypotensive Phases of the disease with only moderate shock. On the seventh day of his illness he entered a 6-day period of Established Oliguria with hypertension and a rising BUN that continued without remission until his death, reaching a final figure of 329 mg. per cent. On the twelfth day his urinary output increased from 195 to 2175 cc. in 24 hours and a moderate but irregular diuresis, at times of 3000 cc., continued to his death. During this terminal period the usual problem of maintenance of fluid balance between dehydration and pulmonary edema was present with repeated episodes of secondary shock. In this period he received no serum albumin.

At autopsy, a marked hypostatic congestion and edema of the lungs were present with the usual hemorrhages in right auricle and pituitary. The renal lesion is described as showing the "classical medullary hemorrhage with some evidence of resorption."

Histological examination showed extensive intertubular hemorrhage in the subcortical region extending deep into the medulla. The areas of hemorrhage were not continuous, but formed an irregular zone in which regions of tubular collapse and dilatation alternated with definite fibrosis of the intertubular tissue. The dilated tubules lying in the fibrous areas extended by medullary rays into the cortex and were either empty or filled with hyaline material. Proximal convolutions in the cortex were irregularly dilated; their epithelium was of a normal mature type. The glomeruli, save for coagulated material in Bowman's space, were not remarkable.

\* \* \* \* \*

All of the individuals surviving the phase of oliguria for periods varying from 1 to 16 days showed widespread evidence of the usual renal reparative processes of epithelial regeneration and replacement fibrosis; the general dilatation of cortical tubules was not present. The structural repair concerned the kidney tissue rather than the

nephrons, for there had occurred no restitution of organ structure in those elements whose continuity had been destroyed. In Case 43 the histological pattern of the cortex with its glomeruli and proximal convolutions appeared not greatly abnormal (Figure 34) and, at least from the structural viewpoint, had the appearance of a possible functional adequacy even though renal insufficiency was still evident in the BUN which had decreased from a maximum of 280 to 173 mg. per cent. Judging from the amount of scattered scar tissue and distorted tubules in both the subcortical zone and in the cortex, a considerable number of nephrons must have been in part destroyed.

\* \* \* \* \*

Further evidence of the nature of the repair is found in an individual who, having recovered from EHF, died of causes other than renal insufficiency 149 days later.

This patient was first admitted to hospital on the third day of his illness with the typical clinical picture of EHF. On the next day, with a blood pressure of 110/90 mm. Hg, a pulse of 112 and a hematocrit of 60 per cent, he was given one unit of serum albumin; from then on the blood pressure was stable. On the sixth day, the urinary output dropped to 25 cc.; on the seventh it was 125 cc.; he then became hypertensive (150/100; 170/100 mm. Hg). On the tenth day diuresis of 1700 cc. ensued; the BUN, which had risen to 70 mg. per cent, fell to 43 on the twelfth day. He was transferred to a hospital in the States where, 79 days after the onset of his illness, a test of his maximum concentration capacity showed a specific gravity of 1.010. During this stay in hospital the patient presented symptoms of adrenal insufficiency, cardiac irregularity and occasional "clonic seizures." In one of these he died, 149 days after the onset of the attack of EHF.

At autopsy the anterior pituitary was found to be almost entirely destroyed by an old hemorrhagic infarction; the adrenals weighed 6.2 gm.; in histological section there was a thinning of the cortex with a marked lipid depletion and areas of necrosis in the zona glomerulosa; the medulla was well preserved. The other endocrine glands, save for atrophy and maturation arrest of spermatogenesis in the testicles, were not remarkable.

The kidneys weighed 370 gm.; the surface of one was described as smooth, the other as finely granular.

Histological examination showed similar lesions in both kidneys, but the cellular scars to be described were more prominent in one. The subcortical zone of the medulla, which from the history may be assumed to have been the seat of circulatory disturbances, showed an increase in intertubular fibrous tissue and a consequent wide spacing of the tubules passing through it. The majority of these straight tubules appeared normal, but scattered through the denser areas of fibrosis were collecting tubules which showed a hyperplastic proliferation of their epithelium (Figure 42). The deeper parts of the medulla, including the papillae, were free of fibrosis and appeared normal. Rather different from the acellular fibrous scarring were other more recently appearing wedge-shaped areas of monocytic infiltration and fibrous proliferation which extended from mid-medulla through the cortex to the surface of the kidney. Within the confines of these scars remnants of atrophic tubules and glomeruli were visible (Figure 43).

\* \* \* \* \*

In the kidneys of this individual who had recovered from the acute episode of EHF there are two types of fibrous scarring and tubular destruction. The one, present in the subcortical zone, is composed of an acellular fibrosis; the other, extending from medulla to cortex, is relatively afibrous and is filled with an infiltration of inflammatory monocytic cells. The former corresponds in location and in its fibrous components with that seen in the reparative process in cases of shorter duration. The frankly inflammatory nature of the latter type of fibrosis seems to be either a new element in the pathological complex or a greatly exaggerated one, since in the cases formerly described cellular infiltration of an inflammatory reaction, though occasionally present, was at a minimum. In the present case the noncommittal diagnosis of sub-acute pyelonephritis is at least warranted; it is a matter of speculation what relation it bears to the original lesion of EHF which appears to have healed with a benign fibrosis and the destruction of a certain number of nephrons.

## RÉSUMÉ

Concurrent with our description of the structural changes in the kidneys during the succeeding phases of EHF have run a discussion of their significance as factors in the renal status and a critical consideration of the pertinent literature. What now follows is an uninterrupted recapitulation of the course of the disease, attempting a chronological synthesis in structural-functional correlations that will integrate the renal lesion into the clinical syndrome.

During the first hours of the Febrile Phase the individual shows clinical evidence in the intense flush of the skin and visible mucous membranes of vasodilatation of peripheral small vessels. The capillaries of the nail folds are widely dilated; the same is apparently true of the small vessels in the renal vascular bed, as ERBF is either normal or increased. It can be assumed, therefore, that the kidney during this first stage is flooded with a rapid circulation of blood through vessels which are, save for vasodilatation, essentially normal. Since only traces of protein are found in the urine, it would seem that the glomerular capillaries have not as yet suffered the characteristic and catastrophic lesion of the disease which is to develop in the next stage.

This vascular disturbance is revealed in the succeeding Hypotensive Phase by the abrupt leakage of plasma from the capillaries, and results in a reduced circulating blood volume. It is associated with decrease in arteriolar tone so that hypotension and shock are the result. The structural-functional correlation at this point is clear, for at autopsy the escaped plasma is found in the retroperitoneal spaces.

Lowered arterial pressure of shock is a sufficient cause of decreased renal blood flow, but there are also local disturbances in the renal vascular system. Proteinuria abruptly increases, often in the course of a few hours, as evidence of leakage of plasma through glomerular capillaries that have undergone damage similar to that which is so widely spread throughout the tissues; the correlative structural aspect of the lesion is seen in the precipitate which fills Bowman's space and in the areas of intertubular edema, analogous to the retroperitoneal edema, that are found in medulla and cortex. Clearances show a sharp reduction in

ERBF even in the absence of clinical shock; if the latter concomitantly or subsequently occurs, as it did in most of the fatal cases, a summation of general and local effects operates to reduce renal blood flow.

It is the failure of renal blood flow, previously either abundant or excessive in an engorged vascular bed the arterioles of which have lost their tone and whose capillaries and venules are permeable to plasma but not to red blood cells, that is responsible for the origin of the characteristic renal lesion of the disease. The distinctive localization of this circulatory disturbance is due to the anatomical and functional peculiarities of the vascular system of the kidney which have been previously described. Even with a reduced blood flow, the atonic and permeable vessels of the "medullary sponge" in the subcortical zone of the medulla, a region shown to be the last to suffer ischemia, are flooded and distended to the point of tubular compression. At this stage the circulation in cortex and deep medulla is not greatly disturbed.

The status of the renal circulation is now that which Ricker (20) would have called a "prestatic" congestion, for, judging from histological appearances, the blood within the intact dilated intertubular capillaries is circulating. There is little structural or functional effect other than moderate pressure on the tubules in the region of subcortical congestion. Urinary output has been irregularly and variably reduced and follows, in the main, alterations of blood pressure and consequent renal blood flow. In clinical terms, oliguria has not been "established."

In the Transition Period and Oliguric Phase, clinical evidences accumulate of an intensification of the general damage to small vessels and the consequent escape of more than plasma. Petechiae in the skin increase to a maximum on the fifth or sixth day; ecchymoses or hematmata at the site of trivial trauma, hematemesis, melena and hemoptysis all appear toward the end of the Hypotensive Phase along with a reduction in platelets. So in the subcortical zone of the medulla, hemorrhage, at first by diapedesis and in the end by capillary disruption, infiltrates the renal parenchyma. All tubules in the areas of involvement now lie widely separated in a mass of non-circulating red blood cells.

The circulatory disturbance has now passed from Ricker's prestatic phase to that of rubrostasis and is accompanied by necrosis of those portions of the nephrons which lie in the anoxic areas of congestive stasis. This interruption of the intrarenal passages which tends to isolate cortex from medulla is not complete, however, for it is formed by the coalescence of focal areas of congestive hemorrhage which arose from the peculiar horse-tail configuration of the *arteriae rectae* of the lower glomerular efferents. The tubules of many nephrons and of the collecting system may be preserved even in what appears in section to be a severely affected kidney. The importance of intact channels through the area of destruction for the continuation of some flow of urine in the Oliguric Phase and for its increase in the Diuretic Phase which may follow, is apparent.

The clinical observation of the development of an established oliguria during this period correlates with the pathological finding of compressed and interrupted intrarenal channels. Not only are the compression and disruption of tubules seen in the subcortical zone of intertubular hemorrhage, but, more conclusive, the effect of that obstruction is evident in the consequent dilatation of cortical tubules, both proximal and distal, that lie above it. Such retrograde alterations in the course of urine flow through the kidney are made possible by the presence of intracortical nephrons which have escaped medullary disruption. It is noteworthy that this distention disappears with the onset of diuresis, for it is not present in the kidney of those who have passed through a similar period and died in the Diuretic Phase.

Tubular destruction is not limited to the subcortical zone of congestion; stasis in the *arteriae rectae* reaches the papillae and the tissue lesions of hemorrhage and necrosis follow. Extension into the cortex is less obvious, yet nephrons from severely damaged kidneys regularly showed the tubulorhexic, disruptive lesions of anoxia throughout the proximal convolutions.

Those who died in the Phase of Established Oliguria and in the following Phase of Diuresis showed such extensive damage to both nephrons and collecting system that any adequate structural restitution in their kidneys would seem to have been impossible. We have previously considered in detail the mechanisms of both struc-

tural and functional recovery after the tubular necrosis of acute renal failure (24); it is unlikely, therefore, considering the broad extent of tubule that may be destroyed by the tubulorhexic lesion, that the repair of the damaged nephrons in EHF is possible. Healing, as has been demonstrated in the case of acute renal necrosis, is due to formation of scars that contain afunctional remnants of destroyed nephrons.

Survival of the individual and ultimate recovery therefore depends on the escape of an adequate number of nephrons from anoxic necrosis. Since 95 per cent of the individuals with EHF survive and, in routine clinical examination during convalescence, appear to have recovered normal renal function, it follows that the great majority never could have developed the extensive structural damage that was present in those who died in oliguria or later diuresis. In the typical case of EHF the turning point towards recovery or exitus comes in the Transition Period; if the vascular disturbance remains at the level of a prestatic congestion with little or only moderate intertubular hemorrhage and consequent destruction of a few nephrons, then a return of adequate blood flow is the major requisite for the restitution of the renal status. These relations are illustrated graphically in the lowest subdivision of Text Figure 1. Individuals recover from the renal lesion of EHF not by repair of nephrons but because a great number of their nephrons have not been irreparably damaged.

How frequently future difficulties in renal function are to be anticipated in those who have survived an attack of EHF remains uncertain until exact measurements by clearances of suitable cases have been accumulated. In all but the milder cases some nephrons have most likely been destroyed, and it is known that after most forms of acute renal failure, in spite of some hypertrophy and hyperplasia of the survivors (24), this loss is demonstrable for a considerable time (25). Whether a kidney with such a lessened "reserve" is a potential hazard remains speculative; the one case available for examination in this series showed the lesions of a sub-acute pyelonephritis.

Since the Transition Period and the Oliguric Phase is the time of renal crisis, it would be most helpful if some distinguishing clinical characteristic or laboratory procedure might be discovered

that would differentiate the passing "renal insufficiency" occurring in the Oliguric Phase in the individual who ultimately is to recover, from the definitive "renal failure" of one who has an irreparable destruction of nephrons and is to die. Can the former temporary insufficiency be considered, for example, a "functional" phenomenon in some nature different from an "organic," irreversible failure, and if so cannot the two sorts of disturbance be distinguished by a refinement of clinical or laboratory technique?

These questions of differential diagnosis which, though they certainly have metaphysical implications that need not here concern us, would, if answerable, be eminently practical. The problem has been examined under experimental conditions in the perfused frog's kidney, where a simplification of the factors involved, if extreme, at least makes its consideration possible (26). If the conclusions of these experiments are accepted, that which has been assumed to be two different sorts of disturbed renal activity, "functional" and "organic," are not similar; they are in fact one and identical and no elaboration of technique can make them two. It is true that because of present limitations in the scope of morphological techniques the visible structural aspect of the situation at times differs; if one can *see* a structural alteration, then the differentiation between the evanescent and the irreversible renal disturbance may be possible. For these reasons it is understandable how an "established oliguria" in the clinical sense was observed in individuals who recovered; in their kidneys some nephrons may have undergone the irreversible structural lesions that characterized the phenomenon in the pathological sense, but not, as in the fatal case, a significant number to preclude recovery of an adequate renal status. To distinguish between the two situations the structural alterations evident in a renal biopsy, which in the present case was impractical, would be required.

In general, the mechanisms of the two variations in urinary output, oliguria and diuresis, are similar in EHF to those which operate in the classical example of Acute Renal Failure associated with various forms of traumatic or toxic injury. In both, a decrease and subsequent restoration of renal blood flow would seem to be im-

mediate factors in the production of decreased and augmented urine flow. As accessory mechanisms that reduce tubule flow in both forms of renal damage, increased intra-renal tension from interstitial edema or swelling of osmotic origin of the epithelium of the proximal convolutions must be considered, and any "casts" that may be present must act as deterrents of tubular flow.

In contrast to these similarities between the nature and causes of decreased urinary output in Acute Renal Failure and EHF one difference has been previously noted; the *establishment* of the oliguria in the latter. Though the factors which establish the oliguria, tubular disruption, are present in all forms of ischemic renal damage, the concentration of its obstructive effect by a zone of subcortical hemorrhage is present only in EHF.

The sudden onset of diuresis, at times from no urine excretion to over several liters in 24 hours, makes it certain that a circulatory phenomenon is concerned and not the restitution of some structural element.

It should be noted that the diuresis observed in the fatal cases was not the flood that occurred in those who recovered. In the latter instances the urinary output commonly stabilized at 6 to 8 liters per day with an exceptional output of 18 liters. In the fatal cases here reported, only an occasional individual passed as much as 4 liters and the more common daily output was around 2. This depression in fatal cases of a diuresis that was "normal" in the recovering case is explicable by the predominating and persisting effect of the structural alterations making for decreased flow in the Phase of Established Oliguria, namely, intertubular hemorrhage and tubular disruption. Here again is evidence that the cases which recovered did not have the grave disruptive lesion in the nephrons that was observed in the fatal cases.

Variations in urinary volume in Acute Renal Failure and EHF are both "glomerular" and "tubular" in their origins. The glomerular functional mechanism is relatively simple, the tuft filtering more or less in accord with the flow and pressure of blood circulating through its capillaries. Its functional response to the return of circulation is immediate, since its structure has not been greatly altered and filtration is a simple process. Return of tubular function, absorption of elec-

trolyte and water, is slow because of the need of elaborate reconstitutions of cellular mechanisms, such as the mitochondrial apparatus (24). Hence it is the temporal relation of varying responses, prompt filtration and delayed reabsorption, to one event, the return of circulation, that determines the final effect, *i.e.*, diuresis and loss of elements which are normally conserved.

The tubular element in abnormal variation of urine output is more complex, even if we ignore the obligatory phase of water absorption which is presumed to occur in the distal portions of the nephrons or collecting ducts. To do so in our problem would seem permissible, since the magnitude of output during the Diuretic Phase points to trouble in that portion of the nephron where we know by direct observation (27) that 80 per cent of the glomerular filtrate is absorbed, namely, the proximal convolution.

The anomalous and paradoxical effects of disturbances in tubular function are apparent enough when attempts are made to examine them indirectly by means of "clearances" done in mammalian experiments; it is perhaps equally optimistic to pass to the other extreme of the situation, in which the experimental oversimplification of examining the problem in the perfused frog's kidneys may seem excessive. However, certain phenomena become apparent under these conditions which are at least suggestive in a hypothetical consideration of the problem in man.

If a frog's kidney, lying *in situ*, is perfused by the renal artery and renal-portal vein with modified Locke's solution containing glucose, a normal "urine" is formed in which the effects of tubular function are evident in the hyposthenuria, the absence of sugar and, if present in the perfusate, the secretion and concentration in the urine of a dye, neutral red. If a poison, urethane or  $\text{HgCl}_2$ , is administered in low dosage to the tubules alone and their functions are thus moderately depressed, there develops a marked increase in volume output, a fall in rate of dye excretion, an increase in total electrolyte elimination, and the appearance of sugar in the urine. If the dosage of poison is increased the urine volume decreases, with no return of sugar absorption or dye secretion, ultimately reaching zero, and the kidney is seen to be swollen and edematous. Histological examination of such perfused kidneys shows no

frank epithelial structural lesions in the "stage of diuresis," and marked epithelial destruction and intertubular edema in the later "stage of oliguria" (28, 29).

In a tentative manner one might imagine analogous tubular disturbances operating in the complexity of the renal lesions of Acute Renal Failure and EHF. Under clinical conditions the sequence of events in the two diseases is reversed, oliguria and structural damage of the grave renal insult preceding a phase of restitution of renal function that is indicated by diuresis when tubules, still inadequate, fail to absorb the fluid of an increasing glomerular filtration that has followed a return of renal circulation.

As this discussion has progressed comparisons and analogies have continuously presented themselves relating the structural and functional aspects of the renal lesion of EHF to those of the renal lesion of Acute Renal Failure which is associated with all the various forms of traumatic and toxic injury. In another place (30) these renal lesions have been compared, in their merging patterns that lie between two types of structural alteration, nephrotoxic and tubulorhexic, to the gradation of spectral bands that, individual, yet blend to a continuum; in this spectrum each case presents its characteristic signature which is derived from the peculiar qualities of its clinical origin. On such a spectrum the distinctive elements of the renal lesion in EHF, such as its prominent Transition Period and the Established Oliguria Phase with its causal relation to the interruption of urinary channels by the characteristic subcortical zone of congestive hemorrhage, stand out in bright lined contrast; appearances both functional and structural, are very similar and yet sharply different from those of Acute Renal Failure. It would seem possible to resolve this apparent anomaly and rationalize our metaphor by the recognition that the renal lesion in EHF is Acute Renal Failure in an individual whose peripheral vascular bed, including the renal, is atonic and permeable as a result of an infectious disease. Thal's experiments (17) have removed all doubts that infectious noxa can produce the vascular disturbance of renal ischemia and its distinctive tubulorhexic necrosis.

There still remains the task of establishing what the exact nature of the infectious noxa in EHF

may be. It has been shown that it does not have the characteristics of a histamine-like substance, and preliminary evidences of a specific vasodilator substance that circulates in the plasma have so far proved inconclusive (31). As in the more fundamental problem of the nature of the causative agent in the disease, it would seem that here lies hidden what might prove to be the definitive contribution to the understanding of the renal lesion in Epidemic Hemorrhagic Fever.

#### REFERENCES

1. Giles, R. B., Sheedy, J. A., Ekman, C. N., Froeb, H. F., Conley, C. C., Stockard, J. L., Cugell, D. W., Vester, J. W., Kiyasu, R. K., Entwisle, G., and Yoe, R. H., The sequelae of epidemic hemorrhagic fever: with a note on causes of death. *Am. J. Med.*, 1954, **16**, 629.
2. Froeb, H. F., and McDowell, M. E., Renal function in epidemic hemorrhagic fever. *Am. J. Med.*, 1954, **16**, 671.
3. Syner, J. C., and Markels, R. A., Continuous renal clearance studies in epidemic hemorrhagic fever. *U. S. Armed Forces Med. J.*, 1955, **6**, 807.
4. Mayer, C. F., Epidemic hemorrhagic fever of the Far East (EHF) or endemic hemorrhagic nephroso-nephritis. *Lab. Invest.*, 1952, **1**, 291.
5. Mayer, C. F., European outbreaks of the Far-Eastern (Korean) type of epidemic hemorrhagic fever (EHF). *Mil. Med.*, 1955, **117**, 502.
6. Hullinghorst, R. L., and Steer, A., Pathology of epidemic hemorrhagic fever. *Ann. Int. Med.*, 1953, **38**, 77.
7. Steer, A., Pathology of hemorrhagic fever. A comparison of the findings—1951 and 1952. *Am. J. Path.*, 1955, **31**, 201.
8. Lukes, R. J., The pathology of thirty-nine fatal cases of epidemic hemorrhagic fever. *Am. J. Med.*, 1954, **16**, 639.
9. Symposium on Epidemic Hemorrhagic Fever, David P. Earle, Ed. *Am. J. Med.*, 1954, **16**, 617.
10. Oliver, J., MacDowell, M., and Tracy, A., The pathogenesis of acute renal failure associated with traumatic and toxic injury. Renal ischemia, nephrotoxic damage and the ischemic episode. *J. Clin. Invest.*, 1951, **30**, 1305.
11. Trueta, J., Barclay, A. E., Daniel, P. M., Franklin, K. J., and Prichard, M. M. L., *Studies of the Renal Circulation*. Oxford, Blackwell Scientific Publications, 1947.
12. Funck-Brentano, J. L., Contribution à L'Étude du Mechanism Physiopathologique de L'Anurie au Cours des Nephropathies Aigües. Paris, Imprimerie Cario, 1953.
13. Oliver, J., Straus, W., Kretchmer, N., Lee, Y. C., Dickerman, H. W., and Cherot, F., The histochemical characteristics of absorption droplets in the nephron. *J. Histochem. & Cytochem.*, 1955, **3**, 277.

14. Greisman, S. E., Nailfold Capillary Observations in Hemorrhagic Fever. Report to the Commission on Hemorrhagic Fever, August 25, 1954.
15. Block, M. A., Wakim, K. G., and Mann, F. C., Certain features of the vascular beds of the corticomedullary and medullary regions of the kidney. *Arch. Path.*, 1952, **53**, 437.
16. Barrie, H. J., Klebanoff, S. J., and Cates, G. W., Direct medullary arterioles and arteriovenous anastomoses in the arcuate sponges of the kidney. *Lancet*, 1950, **1**, 23.
17. Thal, A., Selective renal vasospasm and ischemic renal necrosis produced experimentally with staphylococcal toxin. Observations on the pathogenesis of bilateral cortical necrosis. *Am. J. Path.*, 1955, **31**, 233.
18. Peter, K., Untersuchungen über Bau und Entwicklung der Niere. Gustave Fischer, Jena, 1927.
19. Oliver, J., The Architecture of the Kidney in Chronic Bright's Disease. New York, Paul B. Hoeber, 1939.
20. Ricker, G., Pathologie als Naturwissenschaft, Relationspathologie; für Pathologen, Physiologen, Mediziner und Biologen. Berlin, J. Springer, 1924, p. 104, *et seq.*
21. Oka, K. A., Zur Histologie der Vinylaminnephritis. *Virch. Arch.*, 1913, **214**, 149.
22. Levaditi, C., Eperimentelle Untersuchungen über die Nekrose der Nierenpapille. *Arch. internat. de pharmacodyn. et de therap.*, 1901, **8**, 45.
23. Lindegård, B., and Löfgren, F., The circulatory pattern of the kidney in mercuric chloride poisoning. *Kingl. Fysiograf. Sällskapet. Lund Förhand.*, 1953, **23**, 39.
24. Oliver, J., Correlations of structure and function and mechanisms of recovery in acute tubular necrosis. *Am. J. Med.*, 1953, **15**, 535.
25. Lowe, K. G., The late prognosis in acute tubular necrosis: an interim follow-up report on 14 patients. *Lancet*, 1952, **1**, 1086.
26. Oliver, J., When seeing is believing. *Stanford M. Bull.*, 1948, **6**, 7.
27. Walker, A. M., Bott, P. A., Oliver, J., and MacDowell, M. C., The collection and analysis of fluid from single nephrons of the mammalian kidney. *Am. J. Physiol.*, 1941, **134**, 580.
28. Oliver, J., and Shevky, E., Experimental nephritis in the frog. II. Perfusion methods of testing the kidney by dissociation of its functions. *J. Exper. Med.*, 1931, **53**, 763.
29. Oliver, J., and Smith, P., Experimental nephritis in the frog. III. The extravital production of anatomical lesions in the kidney and their correlation with the functional aspects of damage. *J. Exper. Med.*, 1931, **53**, 785.
30. Oliver, J., The spectrum of structural change in Acute Renal Failure. *Mil. Med.*, 1955, **117**, 229.
31. Greisman, S., and Moe, G. K., A Vasodilator Substance in the Plasma of Hemorrhagic Fever Patients. Report to the Commission on Hemorrhagic Fever, Jan. 8, 1954.