

**INHIBITION OF URINE CITRATE EXCRETION AND THE PRODUCTION OF RENAL CALCINOSIS IN THE RAT BY ACETAZOLEAMIDE (DIAMOX®) ADMINISTRATION**

Harold E. Harrison, Helen C. Harrison

*J Clin Invest.* 1955;34(11):1662-1670. <https://doi.org/10.1172/JCI103220>.

Research Article

**Find the latest version:**

<https://jci.me/103220/pdf>



# INHIBITION OF URINE CITRATE EXCRETION AND THE PRODUCTION OF RENAL CALCINOSIS IN THE RAT BY ACETAZOLEAMIDE (DIAMOX®) ADMINISTRATION<sup>1</sup>

BY HAROLD E. HARRISON AND HELEN C. HARRISON

*(From the Pediatric Division, Baltimore City Hospital and the Department of Pediatrics, Johns Hopkins University School of Medicine, Baltimore, Md.)*

(Submitted for publication June 23, 1955; accepted July 19, 1955)

We have previously observed that the urinary excretion of citrate is reduced to low levels in rats treated with the carbonic anhydrase inhibitor, acetazoleamide (Diamox®) (1). This first experiment was prompted by the fact that the elevated serum chloride and decreased serum bicarbonate concentrations, and the fixation of the urine pH at approximately 7 or above following administration of an agent which inhibits carbonic anhydrase activity resembles the findings in patients with congenital renal tubular acidosis. In a study of an infant with this syndrome we found that the urinary excretion of citrate was too low to be measured (1). The absence of citrate in the urine of this patient persisted even after the hyperchloremia and acidosis were corrected by administration of 40 mM of sodium lactate daily and the urine pH was raised to about 8.0. This is in contrast to the findings in normal subjects in whom the renal excretion of citrate increases when the urine is made alkaline by administration of sodium or potassium bicarbonate or the sodium and potassium salts of organic acids (2). It has also

been shown that the administration of parathyroid extract (3) or vitamin D increases urinary output of citrate (4, 5). When these agents are given there is often a concomitant rise of urinary calcium excretion but the urinary output of citrate and of calcium do not necessarily parallel each other. Since citrate forms an undissociated complex with calcium the possibility that it is important in increasing the solubility of calcium salts in urine has been suggested (3).

## METHODS

The importance of urine citrate as a complexing agent could be tested by means of the effect of acetazoleamide upon renal excretion of citrate. These studies were devised to determine whether the increased citraturia due to administration of alkalizing salts or of vitamin D could be inhibited by acetazoleamide and whether reduction of urinary excretion of citrate following acetazoleamide might be associated with precipitation of calcium salts in the renal tubules and formation of renal calculi. Three to four-week-old male albino rats of the Sprague-Dawley strain were placed on purified experimental diets for three weeks. At this time, when they had reached a weight of about 100 gm., they were divided into two groups, one a control and the other acetazoleamide-treated. Two diets were used which differed in their content of Ca and P and in their acid-base ratio as summarized in Table I. When acetazoleamide was given it was incorporated in the diet in the ratio of 250 mg. of drug per 100 gm. diet. The average daily dosage calculated from food intake was approximately 15 to 20 mg. per 100 gm. of body weight. The basic diets did not supply vitamin D which was added as mentioned in the description of the separate experiments. The animals were kept in metabolism cages permitting collection of urine without contamination by feces or spilled food and the urine was collected under toluene. Citrate in serum and urine was determined by the method of Natelson, Pincus, and Lugovoy (6). Calcium in urine was determined by the Clark-Collip modification of the Kramer-Tisdall method (7), and in serum by this method or by a micro method developed in this laboratory (8). Phosphorus was determined by the Fiske and Subbarow technique (9). Urine pH was measured by indicators.

TABLE I  
*Composition of diets  
(basic diet)*

	<i>gm.</i>
Casein	180
Cornstarch	450
Dextrose	250
Peanut Oil	80
Brewer's Yeast	50
Salt Mixture	50*
Vit. A. Conc.	10,000 units

\* Two salt mixtures were used which provided the following compositions in the final diet.

	Ca	P	
	<i>mg./gm.</i>		
Diet A	16	2	Ash
Diet C	7	5.6	Alkaline Acid

<sup>1</sup> Aided by a grant from the National Institutes of Health, U. S. Public Health Service.

## RESULTS

In Figure 1 is shown the effect of acetazoleamide upon the urinary excretions of calcium and citrate of a rat fed diet A which is an alkaline ash, high calcium, low phosphorus ration. Although no vitamin D was given, the urinary excretions of citrate in the control period are considerable because of the marked cation excess (urine pH approximately 8.0). The sharp drop in citrate excretion following acetazoleamide addition is evident. The urine citrate output returns to control levels when the drug is discontinued and decreases again when it is resumed. The urinary excretion of phosphorus on this diet is negligible and is not influenced by the drug. The urinary excretion of calcium in the control period is high and there may be some inconstant decrease following acetazoleamide. The precipitous fall in urine citrate after acetazoleamide feeding is a consistent finding as is shown in Table II, which summarizes the results in six rats on diet A, four acetazoleamide fed and two control animals. Table III shows the results of a similar experiment in two rats fed diet A to which had been added a mixture of sodium bicarbonate and citric acid which supplied 90 mM of extra sodium and 60 mM (11.5 gm.) of citric acid per 100 gm. of diet. The purpose of this addition of sodium citrate was to increase further

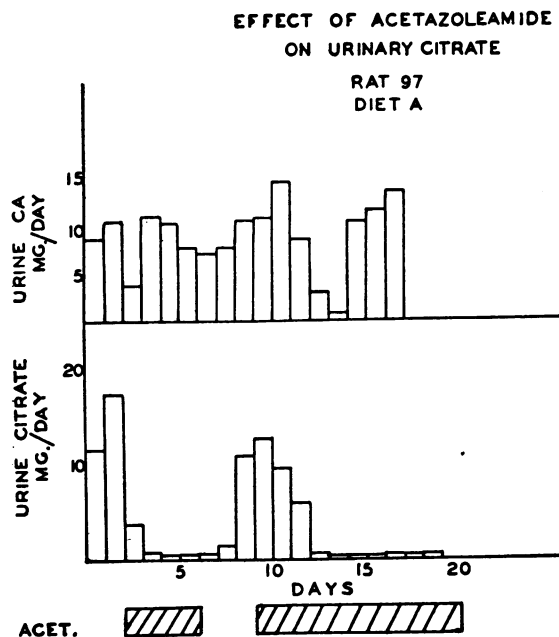


FIG. 1. EFFECT OF ACETAZOLEAMIDE ON URINE EXCRETION OF CITRATE AND CALCIUM OF RAT FED HIGH CALCIUM, LOW PHOSPHORUS, ALKALINE ASH DIET (DIET A)

Acetazoleamide added to diet during periods shown by diagonally striped bars at bottom of diagram.

urinary excretion of citrate with the production of maximally alkaline urine. The urine citrate excretion is raised by addition of sodium citrate to

TABLE II

*Effect of acetazoleamide on urinary excretion of citrate by rats fed high calcium, low phosphorus diet*

Day	Rat No.											
	122*		123*		124		125		126		127	
	Ca.	Cit.	Ca.	Cit.	Ca.	Cit.	Ca.	Cit.	Ca.	Cit.	Ca.	Cit.
	<i>mg./day</i>											
1	13.3		15.7		18.5		11.0		3.6		15.7	19.2
2	14.4	20.0	12.5	19.2	15.2	19.2	9.2	15.0	9.3	21.8	14.0	14.8
	Acetazoleamide added											
3	15.2		11.9									
4	11.8		11.5									
5	13.1	15.0	12.4	14.3	9.2	0.2	9.2	0.6	11.1		7.4	0.4
6	10.3	14.0	8.2		9.6	0.5	8.1		10.1	1.4	11.5	0.8
7	11.4		10.2		8.2	0.5	8.0	1.3	12.7	1.8	10.3	
8	7.2		11.7		6.0		4.2		9.1		6.2	
9	14.2		13.6		11.6		8.8		12.2		11.3	
10	12.4		12.7				6.7		8.0		6.1	
11	11.5	14.2	14.6	17.8	9.3	0.3	9.0	0.6	11.4	0.8	11.3	0.8
12	11.7		14.9		8.5		9.2		11.5			
13	10.1		14.6		9.4		8.0		11.5			
14	9.3	12.8	13.6	17.0	5.8	0.2	8.6	0.7	7.4	0.4		

\* Control rats.

EFFECT OF VIT. D ON URINARY  
P, CA AND CITRATE  
DIET C RAT 144

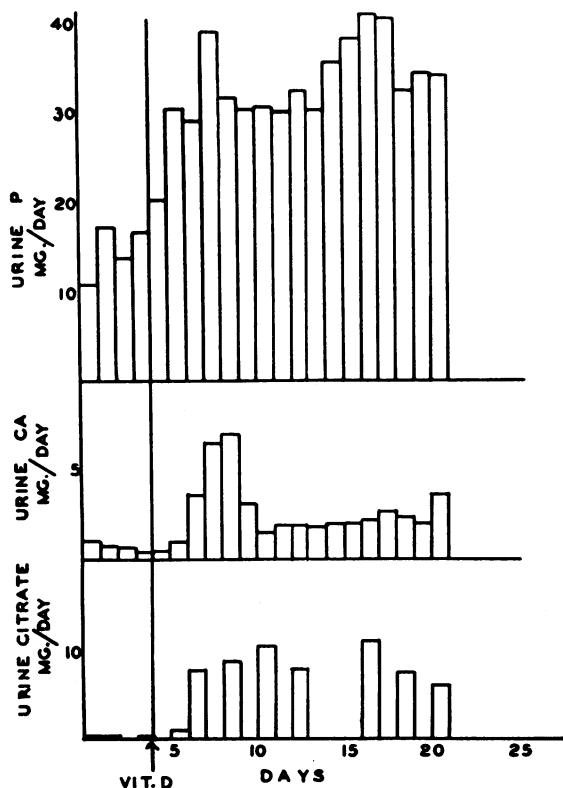


FIG. 2. INCREASE OF URINE CITRATE EXCRETION FOLLOWING VITAMIN D ADMINISTRATION TO RAT FED ACID ASH DIET, HIGH IN CALCIUM AND PHOSPHORUS (DIET C)

The arrow indicates day on which single dose of 5,000 units of vitamin D was given.

the high calcium, low phosphorus diet but the urinary excretion of calcium is reduced and urinary excretion of phosphate remains low. The inhibitory effect of acetazoleamide upon citrate excretion is still apparent despite the sodium citrate supplement although the urinary citrate is not reduced to the extremely low levels found in rats fed diet A without added sodium citrate. No evidence of refractoriness to the acetazoleamide effect on urine citrate excretion was found in rats treated continuously for three weeks. In a few experiments, doses of Diamox® of only 4 to 5 mg. per 100 gm. body weight per day were also effective

in reducing urine citrate output to the same minimal values shown in Table II.

In Figures 2 and 3 are shown the effects of acetazoleamide upon vitamin D induced citraturia. In this experiment the animals were fed diet C in which the Ca to P ratio and the content of these elements per calorie of diet is approximately the same as in cow's milk. This is an acid ash diet and in the vitamin D deficient state the urinary citrate excretion is less than 0.5 mg. per day. The effect of the administration of a single dose of 5,000 units of vitamin D upon citraturia in a control rat is shown in Figure 2. The rapid increase of urinary citrate excretion to values of about 10 mg. per day following vitamin D is roughly paralleled by an increase in urinary excretion of both calcium and phosphorus. The increased urinary output of calcium and phosphorus presumably reflects increased intestinal absorption of these minerals due to vitamin D effect. Figure 3 shows a similar study in an acetazoleamide treated rat. The drug was added to the diet two days prior to the administration of vitamin D. The expected increase in citraturia due to vitamin D is almost completely prevented although the increased urinary output of calcium and phosphorus is approximately the same as in the control vitamin D treated rat. Similar results were obtained in three other rats on this regime. Urinary pH values ranged about 6.0 in the rats fed this diet without

TABLE III

*Effect of acetazoleamide on urinary excretion of citrate by rats fed high calcium, low phosphorus diet supplemented with sodium citrate*

Day	Rat No.			
	106		107	
	Ca	Cit.	Ca	Cit.
	mg./day		mg./day	
1	0.2	12.0	2.0	29.4
2	0.3	13.8	1.3	30.1
Acetazoleamide added				
3	0.2	2.0	3.4	27.5
4	0.9	1.6	6.7	13.4
5	0.6	2.7	3.4	11.7
6	0.6	5.5	1.9	6.1
Acetazoleamide discontinued				
7	1.0	5.9	3.0	10.7
8	0.4	6.9	2.0	18.0
9	1.7	17.5	0.9	25.2
10	1.0	23.5	2.1	24.4

acetazoleamide and were about 0.5 pH unit higher in the acetazoleamide-fed rats.

If urine citrate plays an important role in maintaining urinary calcium in solution as has been suggested by Kissin and Locks (10), Shorr, Almy, Sloan, Taussky, and Toscani (3), and Scott, Huggins, and Selman (11) the inhibition of citraturia by acetazoleamide without proportionate decrease of urine calcium excretion should conduce to the precipitation of calcium salts in the urinary tract. Six rats of the group fed diet C were given a single dose of 5,000 units of vitamin D. Four were fed acetazoleamide for a period of three weeks and two were maintained on the control diet. At the end of a three-week period the rats were sacrificed and blood samples and the kidneys were taken for analysis. The animals were not fasted and the treated rats received the Diamox® containing diet up to the time they were sacrificed.

The concentrations of calcium, phosphorus, and citrate in the serum of these animals are given in Table IV. The serum citrate values are essentially the same in control and treated rats despite marked differences in urinary excretion of citrate. Three additional control rats on this dietary regime had serum citrate concentrations of 3.0, 3.3 and 3.7 mg. per 100 cc., respectively. The serum calcium and phosphorus levels of both control and treated rats are all in the normal range for rats of this age although the serum phosphorus values are slightly higher in the treated animals. Half of each kidney was taken for chemical analysis and half for histological examination. The kidneys were ashed and calcium determined in the ash solution. The calcium contents of the kidneys are

TABLE IV

*Serum citrate, calcium and phosphorus levels in control and acetazoleamide-fed rats, diet C\**

Rat No.	Serum		
	Citrate	Ca mg./100 cc.	P
143	4.4	10.2	9.0
144	3.5	10.2	8.8
145†	3.9	10.1	10.1
146†	4.0	9.6	9.6
147†	3.7	10.0	9.5
148†	3.3	10.2	10.6

\* All rats had received a single dose of 5,000 units of vitamin D three weeks before they were sacrificed.

† Acetazoleamide added to diet.

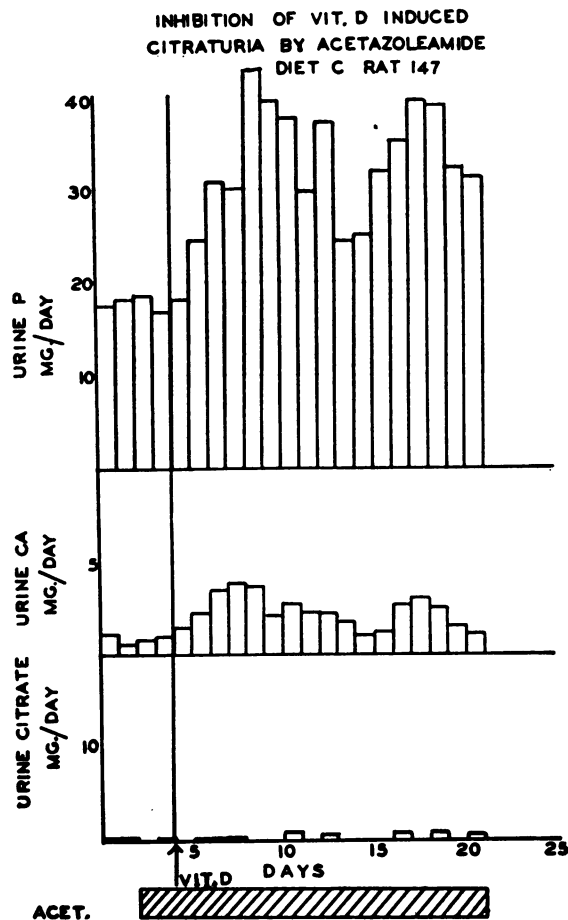


FIG. 3. INHIBITION OF VITAMIN D EFFECT ON URINE CITRATE AS RESULT OF ACETAZOLEAMIDE FEEDING

Period of acetazoleamide treatment shown by diagonally striped bar. The arrow indicates day on which single dose of 5,000 units of vitamin D was given.

shown in Table V. The kidneys of the two control animals contained too little calcium to be determined accurately and also showed no evidences of calcium precipitate on histological examination. The kidneys of the four acetazoleamide-fed rats contained between 27 and 355 mg. of calcium per 100 gm. fresh kidney. The location of the calcium deposits in the kidneys was determined by histological examination. The sections in Figure 4 stained by the von Kossa method show precipitated calcium in the kidney tubules chiefly at the cortico-medullary junction. The precipitated material is intratubular although the tubules are in many places disrupted by the precipitate. There is no histological evidence of

TABLE V  
*Calcium content of kidneys of control and acetazoleamide-fed rats*

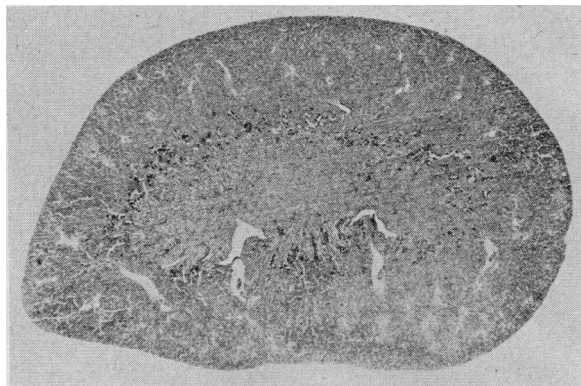Diet A			Diet C		
Group	Ca mg./100 gm.	Visible calcification	Group	Ca mg./100 gm.	Visible calcification
Control	Trace*	0	Control	Trace*	0
Control	9	0	Control	Trace	0
Control	1	0	Acet.	113	Intratubular in outer zone of medulla
Control	3	0	Acet.	217	Intratubular in outer zone of medulla
Acet.	105	Tips of papillary ducts; renal calculi	Acet.	27	Intratubular in outer zone of medulla
Acet.	46	Tips of papillary ducts; renal calculi	Acet.	355	Intratubular in outer zone of medulla
Acet.	51	Tips of papillary ducts; renal calculi			
Acet.	29	Tips of papillary ducts; renal calculi			
Acet.	87	Tips of papillary ducts; renal calculi			
Acet.	96	Tips of papillary ducts; renal calculi			
Acet.	59	Tips of papillary ducts; renal calculi			

\* Amount insufficient for quantitative determination.

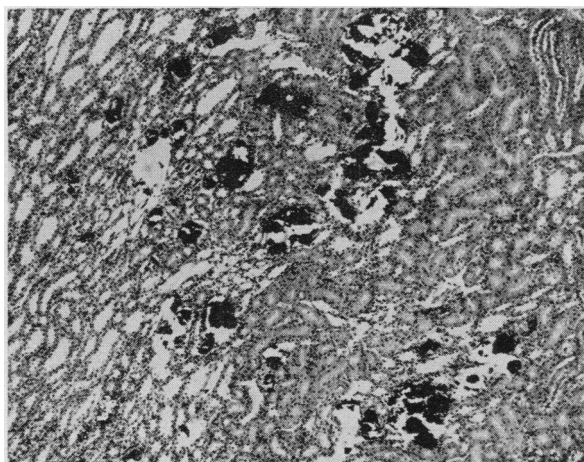
renal tubule cell injury except at the site of calcium precipitation where the tubules are ruptured and there is no inflammatory reaction in the interstitial tissue. The calcium precipitates are found sharply localized at the cortico-medullary junction with some scattered foci in the inner medullary zone. The proximal and distal convoluted tubules in the cortex are free of calcium, as are the collecting tubules in the tip of the pyramid. The intratubular calcium precipitates are even more strikingly shown in the specimen illustrated in Figure 5. The kidney of an acetazoleamide-treated rat was split along the longitudinal axis and one-half was cleared by treatment with potassium hydroxide solution. The calcium was then stained with alizarin red. The calcium precipitates form casts of the tubules starting abruptly at the cortico-medullary junction and only a relatively short portion of the tubule is involved as is shown in the higher magnification (Figure 5B). The histological pattern suggests that most of the precipitation of calcium is in the terminal or straight segment of the proximal convoluted tubules. There may also be some precipitate in Henle's loops and in collecting tubules.

Similar studies were made on the kidneys of rats receiving the high calcium, low phosphorus diet without vitamin D supplement (diet A). The calcium contents of the kidneys of these rats are also given in Table V. The kidneys of the

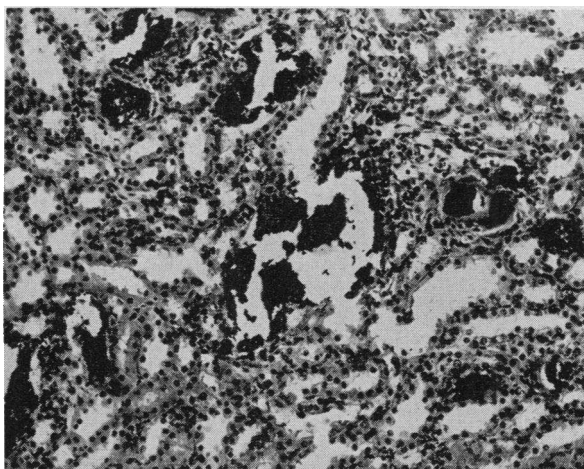
rats not receiving acetazoleamide showed only small amounts of calcium although the urine of these animals contained high concentrations of calcium. The kidneys of the control rats were normal both on gross and microscopic examination. Analyses of the kidneys of the acetazoleamide-fed rats showed considerable quantities of calcium. The pathological findings in these kidneys, however, differed from those seen in the kidneys of the rats fed diet C. On gross examination calculi of various sizes were found in the renal pelvis adherent to the renal papilla in almost all of the kidneys of the acetazoleamide-treated group. In one animal a calculus, weighing about 5 mg. had broken off and lodged in the bladder. This calculus was soluble in dilute hydrochloric acid and on analysis was a calcium stone, but no phosphate, citrate, oxalate, or sulfate was found. It was thought to be chiefly a calcium hydroxide, carbonate concretion. In two rats ureteral obstruction and hydronephrosis were found. On microscopic examination of the kidneys laminated masses of calcium precipitate were seen at the tips of the papillary ducts covered by the papillary epithelium as shown in Figure 6. Scattered foreign body giant cells were present at the periphery of these masses. No calcium precipitate was seen in any other portion of the kidney, however, although a deeply stained eosinophilic coagulum was found in many



A. LOW POWER PHOTOGRAPH SHOWING CALCIUM DEPOSITS AT THE CORTICO-MEDULLARY JUNCTION



B. MEDIUM POWER PHOTOMICROGRAPH OF CORTICO-MEDULLARY JUNCTION SHOWING INTRATUBULAR CALCIUM PRECIPITATE IN DISTENDED THIN-WALLED TUBULES



C. HIGHER POWER OF CORTICO-MEDULLARY JUNCTION SHOWING ABSENCE OF RENAL TUBULE CELL INJURY EXCEPT FOR MECHANICAL DISRUPTION OF TUBULES, AND LACK OF TISSUE REACTION IN INTERSTITIAL TISSUE

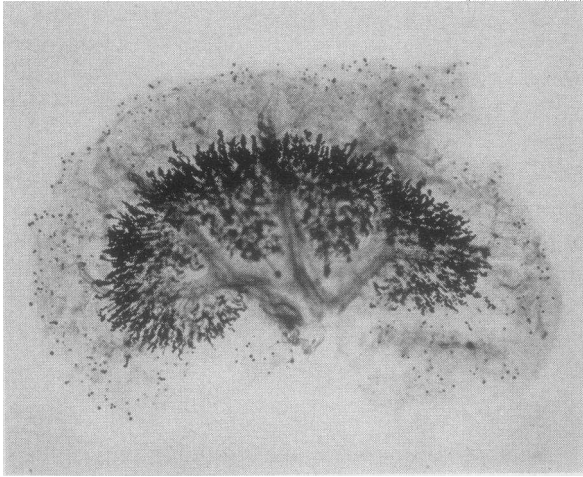
dilated tubules both in the cortex and medulla. The site of calcium precipitation in the kidneys of acetazoleamide-treated rats therefore differs with the type of diet fed and this effect of diet is apparently related to the concentration of phosphate in urine. The effect of acetazoleamide in the rats fed diet A was not altered by administration of vitamin D. The degree and site of calcium precipitation remained the same. In the rats fed this diet the urine phosphate excretion is practically nil with or without vitamin D feeding.

#### DISCUSSION

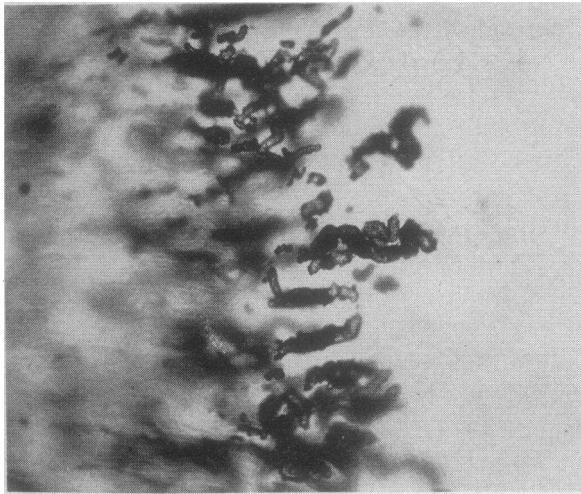
The mechanism of renal excretion of citrate has not been comprehensively studied but calculation of the clearances of this ion indicate that ordinarily most of the filtered citrate is reabsorbed (12). The effect of vitamin D in increasing urinary citrate might be due to increase in the amounts filtered since plasma citrate levels are increased by vitamin D (4). The excretion of citrate drops with decrease of urine pH and rises with increase of urine pH when the pH is altered by administration of acidifying or alkalinizing salts. This relationship to pH also holds true for other organic acids whereas the excretion of organic bases decreases as urine pH rises (12). It has been suggested that the increased urinary citrate excretion with cation excess is a buffer mechanism analogous to the increased excretion of ammonia under conditions of anion excess (2). Shorr, Carter, Smith, and Taussky (13) reported preliminary observations on the mechanism of citrate excretion in man. On the basis of simultaneous citrate and inulin clearances in a patient with Paget's disease they suggested that the increased citraturia due to alkali, and the decrease in citrate excretion due to testosterone administration resulted from changes in tubular reabsorption of citrate.

Acetazoleamide reduces urine citrate excretion despite its effect in increasing urine pH and it also prevents the increase of urine citrate output following vitamin D administration. The plasma citrate levels of acetazoleamide fed rats are the same as those of control rats fed a similar diet without acetazoleamide so that the differences in

FIG. 4. KIDNEY SECTIONS OF ACETAZOLEAMIDE-TREATED RAT FED DIET C; STAINED BY VON KOSSA SILVER NITRATE METHOD WITH HEMATOXYLIN AND EOSIN COUNTERSTAIN



A. LOW POWER OF ENTIRE HEMI-KIDNEY SHOWING INTRATUBULAR CALCIUM CASTS BEGINNING AT CORTICO-MEDULLARY JUNCTION



B. HIGHER MAGNIFICATION OF CORTICO-MEDULLARY JUNCTION SHOWING INTRATUBULAR CALCIUM PRECIPITATE BEGINNING SHARPLY AT CORTICO-MEDULLARY BORDER AND EXTENDING ONLY A SHORT DISTANCE INTO THE MEDULLA

FIG. 5. KIDNEY OF ACETAZOLEAMIDE-TREATED RAT FED DIET C

Specimen cleared by treatment with potassium hydroxide solution and the calcium stained with alizarin red.

urinary citrate excretion must presumably be explained in terms of renal tubular activity. How this effect is related to the inhibition of carbonic anhydrase activity by acetazoleamide and to its postulated effect in reducing secretion of  $H^+$  ions in exchange for  $Na^+$  and  $K^+$  ions (14) can only

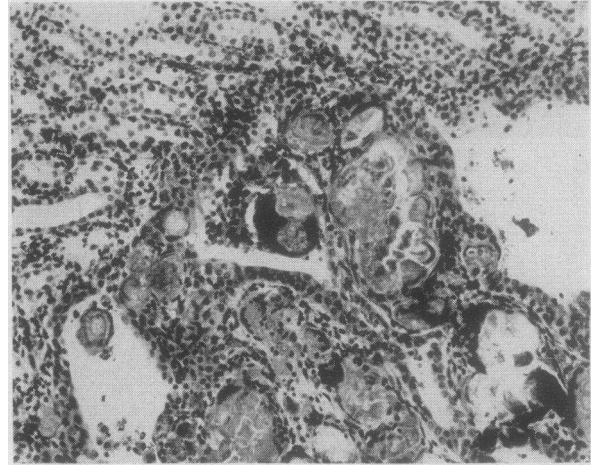

FIG. 6. SECTION OF KIDNEY OF ACETAZOLEAMIDE-TREATED RAT FED DIET A; SECTION TAKEN AT EDGE OF PAPILLA; STAINED BY VON KOSSA SILVER NITRATE METHOD AND HEMATOXYLIN AND EOSIN

Laminated masses of calcium precipitate at tips of papillary ducts covered by papillary epithelium. Foreign body giant cells can be seen at periphery of these masses.

be conjectured. The intracellular pH of renal tubule cells might possibly be the factor controlling the excretion of citrate rather than the pH of tubular contents.

Whatever the mechanism which may be involved in the reduction of urinary citrate by acetazoleamide the sequence of events observed, namely, increase of urinary pH and decrease of urinary citrate without proportionate decrease in calcium or phosphate excretion evidently predisposes to precipitation of calcium in the renal tubules or in the upper urinary tract. These findings support the idea that urinary citrate does increase the solubility of calcium in urine by virtue of its property of forming an undissociated calcium complex and that this mechanism is of importance in the prevention of calcium precipitation in the kidney. The molar ratio of calcium to citrate in the urine of the control rats not receiving acetazoleamide ranged from 3:1 to 3:2. No studies were made to determine whether there might be other polycarboxylic acids excreted in the urine which could sequester calcium.

The site of precipitation of calcium in the urinary tract in these experiments is apparently determined by the concentration of phosphate in the urine. In both experiments the diets were such as to produce calculia although the urine calcium



excretion was greater in the rats fed diet A. In the animals fed diet C supplemented with vitamin D the serum phosphorus concentrations are high and the phosphate load exceeds the renal tubular capacity to reabsorb phosphate so that the urine excreted contains phosphate. Under these conditions phosphate may be assumed to be present in the fluid leaving the proximal convoluted tubules. In the acetazoleamide-treated rats of this series calcium phosphate is precipitated in the renal tubules probably as the result of disappearance of citrate and also increase of pH of the tubular contents. The localization of the precipitate is of theoretical interest since the acetazoleamide effect upon citrate concentration or urine pH must presumably be exerted proximal to or in the portion of the tubule where precipitation of calcium phosphate occurs. The histological pattern of involvement of the tubules at the cortico-medullary junction, and the configuration of the tubular casts in the cleared specimen suggests that the precipitate is in the terminal or straight segment of the proximal convoluted tubule. Isolation of single nephrons by micro-dissection would be necessary to demonstrate conclusively the segment of the tubule in which precipitation occurs.

The feeding of a high calcium, low phosphate diet reduces the serum phosphorus level and therefore the phosphate filtered so that practically all of the phosphate filtered is reabsorbed in the proximal tubule. In the absence of phosphate in the tubular contents no calcium precipitation occurs in the upper nephron despite lack of citrate. Precipitation is found only at the tips of the papillary ducts with formation of calculi in the renal pelvis. Decrease in CO<sub>2</sub> tension with increase of pH or the physical factors of eddy currents and stasis may be involved in the precipitation of calcium from a supersaturated solution at this site.

The modifying effect of dietary factors upon precipitation of calcium in the kidney may explain the fact that such calcification has not been found by other workers who have been investigating acetazoleamide effect upon kidney function. Maren, Mayer, and Wadsworth (15) did note renal calcification in a few rats receiving very large doses of Diamox®, 900 mg. per Kg. No reports of renal calculus formation in patients receiving Diamox® have been published. The dos-

ages given to patients in terms of body weight are much smaller than those used in the rat but the amounts used in these experiments are considerably greater than those needed to inhibit urine citrate excretion. Studies of the effect of Diamox® upon the urinary excretion of citrate, calcium, and phosphate in human subjects are needed before any conclusion can be drawn concerning the possibility of the development of renal calcinosis in patients receiving this drug. The renal calcification found in patients with renal tubular acidosis (16) might indeed be associated with an abnormality of urine citrate excretion in view of the extremely low urine citrate levels found in an infant with this syndrome.

#### SUMMARY

Administration of acetazoleamide to rats results in reduction of urinary citrate excretion to extremely low levels. The usual effect of cation excess or of vitamin D in increasing citraturia is inhibited by acetazoleamide.

The feeding of acetazoleamide to rats also causes the precipitation of calcium salts in the kidney or lower urinary tract under certain dietary conditions. On a diet which resembles cow's milk in its content of calcium and phosphorus, calcium phosphate is precipitated in the renal tubules at the cortico-medullary junction. If the diet is low in phosphate and high in calcium, calcified plaques are formed at the tips of the papillary ducts with formation of calculi in the pelvis. These findings indicate that the concentration of citrate in urine is of physiological importance in the stabilization of urinary calcium and that calcuria in the absence of urinary citrate results in precipitation of the calcium. The nature of the precipitate and its location in the renal tubule is apparently dependent upon the concentration of phosphate in the urine. The site of intratubular precipitation of calcium in the acetazoleamide-treated rats fed the high calcium and phosphorus diet suggests that the acetazoleamide effect upon citrate occurs in the proximal portion of the tubule.

#### ACKNOWLEDGMENT

We are indebted to Dr. Edwards A. Park for valuable suggestions, and to Dr. Abou D. Pollack who advised and assisted us in the study of the kidney sections.

## REFERENCES

1. Harrison, H. E., Mechanisms of action of vitamin D. *Pediatrics*, 1954, **14**, 285.
2. Östberg, O., Studien über die Zitronensäureausscheidung der Menschenniere in normalen und pathologischen Zuständen. *Skandinav. Arch. f. Physiol.*, 1931, **62**, 81.
3. Shorr, E., Almy, T. P., Sloan, M. H., Taussky, H., and Toscani, V., The relation between the urinary excretion of citric acid and calcium; its implications for urinary calcium stone formation. *Science*, 1942, **96**, 587.
4. Harrison, H. E., and Harrison, H. C., Vitamin D and citrate metabolism: Studies on rachitic infants. *Yale J. Biol. & Med.*, 1952, **24**, 273.
5. Bellin, S. A., Herting, D. C., Cramer, J. W., Pileggi, V. J., and Steenbock, H., The effect of vitamin D on urinary citrate in relation to calcium, phosphorus and urinary pH. *Arch. Biochem. & Biophys.*, 1954, **50**, 18.
6. Natelson, S., Pincus, J. B., and Lugovoy, J. K., Microestimation of citric acid; a new colorimetric reaction for pentabromoacetone. *J. Biol. Chem.*, 1948, **175**, 745.
7. Clark, E. P., and Collip, J. B., A study of the Tisdall method for the determination of blood serum calcium with a suggested modification. *J. Biol. Chem.*, 1925, **63**, 461.
8. Harrison, H. E., and Harrison, H. C., A micro-method for determination of serum calcium. *J. Lab. & Clin. Med.*, In press.
9. Fiske, C. H., and Subbarow, Y., The colorimetric determination of phosphorus. *J. Biol. Chem.*, 1925, **66**, 375.
10. Kissin, B., and Locks, M. O., Urinary citrates in calcium urolithiasis. *Proc. Soc. Exper. Biol. & Med.*, 1941, **46**, 216.
11. Scott, W. W., Huggins, C., and Selman, B. C., Metabolism of citric acid in urolithiasis. *J. Urol.*, 1943, **50**, 202.
12. Smith, H. W., *The Kidney: Structure and Function in Health and Disease*. New York, Oxford Univ. Press, 1951, p. 217.
13. Shorr, E., Carter, A. C., Smith, R. W., Jr., and Taussky, H., Factors regulating citric acid excretion in the human. Conference on metabolic aspects of convalescence. Transactions of the seventeenth meeting, 1948. Josiah Macy, Jr. Foundation, New York, p. 106.
14. Berliner, R. W., Kennedy, T. J., Jr., and Orloff, J., Relationship between acidification of the urine and potassium metabolism. Effect of carbonic anhydrase inhibition on potassium excretion. *Am. J. Med.*, 1951, **11**, 274.
15. Maren, T. H., Mayer, E., and Wadsworth, B. C., Carbonic anhydrase inhibition. I. The pharmacology of Diamox® 2-acetylamino-1,3,4-thiadiazole-5-sulfonamide. *Bull. Johns Hopkins Hosp.*, 1954, **95**, 199.
16. Albright, F., Burnett, C. H., Parson, W., Reifenstein, E. C., Jr., and Roos, A., Osteomalacia and late rickets. The various etiologies met in the United States with emphasis on that resulting from a specific form of renal acidosis, the therapeutic indications for each etiological sub-group, and the relationship between osteomalacia and Milkman's Syndrome. *Medicine*, 1946, **25**, 399.