

# THE PATHOLOGY OF SPONTANEOUS AND INDUCED SUBCUTANEOUS NODULES IN RHEUMATIC FEVER<sup>1</sup>

By JOHN R. MOTE, BENEDICT F. MASSELL, AND T. DUCKETT JONES

(*From the House of the Good Samaritan, Boston*)

(Received for publication October 8, 1936)

The purpose of this report is, first, to present a composite histological picture of subcutaneous nodules of rheumatic fever as obtained from a review of the literature; second, to attempt a pathological description on the basis of their known clinical age; and third, to describe the structure of a number of artificially induced nodules and compare them with spontaneously occurring nodules in rheumatic fever subjects. The production of these induced nodules and their clinical similarity to spontaneous nodules is the subject of the previous report (1).

Since the descriptions of subcutaneous rheumatic nodules found in the literature are very conflicting, it is desirable to summarize the available information to determine if the wide variations of structure are consistent with the findings which we propose to present. In the review of these reports, it is surprising that the descriptions are in most instances limited to single nodules removed at death. Only the more adequate descriptions will be quoted.

## LITERATURE

Barlow and Warner (2) in 1881 described the subcutaneous nodule as "consisting of small masses of loose fibrous bundles, sometimes very vascular." Hirschsprung (3) reported that nodules consisted of "connective tissue rich in cells similar to granulation tissue with necrobiosis." Cavafy (4) described two nodules, "a small one consisted of young actively growing fibrous tissue cells with much intercellular tissue," and a "larger one had much looser structure though consisting undoubtedly of fibrous tissue. Strands of fibers were separated widely by edema and cellular infiltration. . . . Both nodules were very vascular, and the small arteries were enormously thickened in the inner coat so as to obliterate the lumen of some of the vessels. Many of them showed only proliferation of the endothelium." Later he (5) described in addition "a peculiar reticular tissue with strikingly rectangular meshes . . . , in some parts this peculiar substance was fibrinous." Money (6) and Parker (7) very briefly described several nodules but added no further

information. Middleton (8) considered the nodule to be "made up of fibrous tissue in various stages of development, . . . at its periphery the arteries seem to be abnormally numerous and in many instances the coats are greatly thickened by infiltration, the intima being particularly affected. Collections of cells frequently extend to a considerable distance from the vessels." Mitchell (9) reported a nodule described by Osler as "a dense fibrous stroma with cells chiefly ovoid, the ends prolonged into fibrils. There was no arrangement of round celled elements as in granulation tissue." Nepveu (10) removed a nodule 36 hours after its appearance and reported "two small foci of granulated necrotic material with very faintly staining cells and necrotic fibrils of connective tissue. There is a zone of infiltration of leukocytes around the areas with transition of cells into necrosis." Fitcher (11) next described a nodule thus, "portions are composed largely of cellular elements, which under high power are seen to consist of small round cells, fibroblasts, and polymorphonuclear leucocytes. In these situations blood vessels are quite numerous so that to a certain extent there is a resemblance to granulation tissue. Several giant cells were present in younger portions of the nodule. . . . Some sections show a very interesting feature in the occurrence of a definite hyaline degeneration of the fibrous tissue in certain situations. . . . Portions of the fibrous tissue which have undergone hyaline change show quite marked cellular infiltration. . . . The vascularity of the nodule is a striking feature. The blood vessels are most numerous at the periphery of the nodule, the center being comparatively free excepting in the areas of cellular infiltration where minute vessels are present. Some larger vessels show an infiltration of small round cells into their walls, these in some instances extending some distance into the surrounding tissue. . . ." Poynton and Still (12) described a nodule removed three weeks after its appearance. "In the center of the nodule there is a homogeneous material arranged in layers and free of cellular elements. . . . There is fibrin, in the interstices of which there was originally fluid. . . . Toward the periphery many cellular elements can be seen encroaching on this fibrinous center. . . . Still further to the periphery fibrous tissue is apparent, some swollen and hyaline and in places there are distended and distorted vessels."

Wick (13) reported a correct objective description of a nodule, but misinterpreted the constituents. "The nodule consists of connective tissue moderately rich in cells and vessels, and inclosing several foci of various size and peculiar structure. The periphery of these foci consists of closely arranged cells of round, elongated, notched, or

<sup>1</sup> The expenses of this study have been defrayed by a grant from the Commonwealth Fund.

irregular shape. Most of these cells have a comparatively large nucleus and may be called epithelioid cells." Coombs (14) briefly described a nodule and remarked on the presence of multinuclear cells. Frank (15) reported on the histopathology of three nodules removed at death. "... a hyaline homogeneous substance is found (in the center) which stains intensively with eosin and contains a large amount of fibrin, as is seen with special staining. This hyaline substance penetrates between the fibrils of the connective tissue, the nuclei of which are only partially and poorly stained. ... The periphery exhibits marked growth of connective tissue, which consists of young, fusiform, or epithelioid cells, and of fibrils of connective tissue with numerous thin, elongated cells. Moderately numerous leukocytes are found in this young growing tissue." Tilp (16) described a number of nodules. "The smaller nodules consist of relatively large, round or pear-shaped endothelioid cells which are often arranged around capillaries or precapillaries with small round cells disseminated between them. The periphery of the nodules consists of radially arranged, predominantly fusiform cells with rod or comma-shaped nuclei. ... Bundles of fibrous connective tissue invade the marginal areas. The larger nodules all exhibit a central area consisting of filamentous masses, and of serous fluid. There are no nuclei in these central areas, but at the margins larger cells are seen in groups, particularly in the neighborhood of small blood vessels. ..."

In 1924, Swift (17) described the structure of subcutaneous nodules as, "In close apposition to areas of cellular proliferation there is tissue destruction varying in size from submiliary areas to long strands of hyaline necrosis affecting connective tissue fibers; combined with necrosis are deposits of fibrin. Surrounding these foci are numerous cells similar in appearance and staining reaction to the type of cells found in Aschoff bodies; multinuclear giant cells are also present." He further remarks on the vascularity and vessel damage noted by previous writers and states, "A participation of fibroblasts arising from the connective tissue is easy to demonstrate. A few polymorphonuclear leukocytes and lymphocytes invade the diseased tissue and foci of edema are demonstrable. ... The larger nodules are composed of a conglomeration of submiliary nodules." Coates (18) described two nodules and states, "Some of arterioles show punctate proliferation of endothelial lining. Perivascular mononuclear proliferation is frequent. The vessels present intimal and sub-intimal cellular proliferation and necrosis and are in an early stage of endarteritis." MacCallum (19) gives one of the best descriptions of the cellular constituents of nodules to be found in the literature. "... whenever a distinct line of demarkation is visible between this (central necrotic tissue) and living tissue, one may find a palisade-like arrangement of large cells with an irregular cell body and a large deeply stained vesicular nucleus or sometimes several nuclei. There is no distinct granulation of the cytoplasm of these cells, but their protoplasmic processes extend among the neighboring cells. Outside this layer,

which may be broad, there appears a highly vascular mass of branching and anastomosing fibroblast-like cells which form a coherent tissue in which wander a few leukocytes frequently with eosinophil granulations and rather more mononuclear wandering cells. It is difficult to feel sure of the nature of the large cells that form the immediate mantle about the necrotic material. ... The nucleus is large and vesicular, usually with a very distinct nucleolus and many irregularly arranged chromatin particles. Some have several nuclei each with a distinct nucleolus. ... They are paler than nearby endothelial cells, and they seem to form a tissue—at least they are the only cells in a tissue that shows intercellular fibrils. ... The trend of their form is that of the tissue and they are distinctly and finely branched and attached to their neighbors by these branches ... (they) seem slightly different from fibroblasts and rouse the question of their possible closer relation to such phagocytic mononuclear wandering cells or clasmotocytes as are so generally concerned when necrotic tissue is present."

Coates and Coombs (20), Merritt (21), and Clawson (22) reported on the structure of nodules but contributed no further information on their histopathology. Dawson and Boots (23) in a paper on subcutaneous nodules in rheumatoid arthritis describe the structure of nodules which by inference applies as well to those of rheumatic fever. This description is as follows: "1. An area of central necrosis due in its earliest stages to a gelatinous swelling and disintegration of collagen bundles. Depending on the age of the nodule and the severity of the process there is a variable amount of fibrin deposition and inflammatory cell infiltration. The vessels in the nodule itself rarely show significant changes, but the arteries and capillaries in surrounding tissue show: (a) subendothelial deposition of fibrin, hyperplasia of subendothelial cells, narrowing and even occlusion of the lumen, and in some instances canalization of the hyperplastic intima; (b) splitting of the elastica and occasional formation of a new elastic coat; (c) perivascular cell infiltration by large mononuclear and small round cells. 2. A surrounding zone of peculiar and characteristically arranged large mononuclear cells. These cells are for the most part disposed in radial fashion and are largely responsible for the characteristic appearance of the whole lesion. 3. An inclosing zone of dense and relatively avascular fibrous tissue." These very marked vessel changes described by Dawson are more severe than those usually seen in nodules as described by others or those which comprise the present study. Klinge (24) in discussing the pathology of rheumatic fever does not describe the subcutaneous nodule separately from the myocardial lesion, since he believes the two are simply tissue variations of a single basic alteration of structure, the result of the rheumatic fever virus. "The rheumatic nodule is not the first or most important alteration, but is a stage of higher development. It is formed on the groundwork of a primary degenerative alteration of the connective tissue, especially of the interfibrillar and intercellular substance. A degeneration of the connective tissue with swelling of the

interfibrillar substance is the most important and ubiquitous part in the development of the rheumatic lesion." He describes at some length the connective tissue changes seen in the early lesion of rheumatic fever, and emphasizes the degeneration of collagen with later fibrin deposition and edema and states that only lymphocytes and polymorphonuclear leukocytes may be seen in the early stage of development. In his description of older lesions he describes the granuloma cells developing from the fibrocytes in the region of the lesion. McEwen (25) used the supravital technic in an attempt to identify more accurately the cells in subcutaneous nodules, but concluded only that they were not clasmatocytes or epithelioid cells, and that the giant cells were of neither the tuberculous nor the foreign body type.

From the above review of the literature it is apparent that there are distinct variations in description and yet in most of them there are three general types of change to be noted. First, there is an alteration of collagen, associated frequently with fibrin deposition; second, there is a cellular infiltration and proliferation of large cells some of which resemble fibroblasts; and third, there is present increased vascularization of the surrounding tissue with concurrent vessel damage. These are the three basic types of tissue reaction seen in the subcutaneous nodule, and it is our purpose to correlate the variations of these three types of change with the clinical age and type of nodule to determine if many of the discrepancies in the literature are not simply nodules obtained in different stages of their evolution or regression.

#### MATERIALS AND METHODS

The nodules studied were with two exceptions biopsy specimens. In each instance the nodule was carefully dissected out after regional nerve block anesthesia had been instituted to prevent distortion of the tissue by the local injection of an anesthetic. The specimens were fixed in most instances in Zenker's fixative, but in some cases Zenker-Formol was used. The blocks were paraffin imbedded, sectioned at 6 micra, and representative sections from all blocks stained with Delafield's hematoxylin-eosin and with Mallory's aniline blue stain. In addition, sections from most of the specimens were stained with Mallory's phosphotungstic acid hematoxylin and Maximow's eosin azur II. Van Gieson's stain and Weigert's elastic tissue stain were also applied to representative sections.

The nodules were removed in the following time intervals from their clinical appearance:

- |                                     |    |
|-------------------------------------|----|
| 1. Present less than 1 month .....  | 6  |
| 2. Present 1 to 3 months .....      | 10 |
| 3. Present more than 3 months ..... | 7  |

A summation description of each group is presented. Since the subcutaneous nodule is frequently made up of a number of minute lesions in various degrees of injury or organization, the structure of the large majority of lesions is interpreted to represent the histopathology of the clinical nodule.

When the clinical variations of the appearance, characteristics, and duration of nodules is considered, definite differences of histopathology are to be expected. In an attempt to ascertain the basis for these differences, we have accumulated a small series of nodules, the clinical ages of which are known. This was done in order to define, if possible, the progressive histological structure of the subcutaneous nodule.

#### *Subcutaneous nodules present less than 1 month*

Nodules of this age group have characteristic features which exhibit a general basic similarity although there may be some variation of finer structure. Histologically there is in most instances widespread edema of the intercellular and interfibrillar spaces which is not sharply demarkated from the surrounding tissue (Figures 11 and 12). This edema is usually present to some extent throughout the gross lesion, but more commonly there are areas of varying size of more conspicuous accumulation of fluid separating intervening altered tissue. This loose edematous structure accounts for the fact that, in the gross, newly detected nodules are usually relatively soft to palpation and are ordinarily poorly circumscribed. There are several changes which are fundamentally the same in all nodules of this group, although the structure may vary from one specimen to another. This in part depends on the density of the tissue concerned.

*1. Collagen change.* The collagen in all of the young specimens has a uniform change of staining reaction. It is brightly eosinophilic staining with Delafield's hematoxylin-eosin, fails to take Mallory's aniline blue, and may or may not take a specific fibrin stain. In agreement with Klinge (24) there is to be found an alteration of the collagen fibrils themselves as well as a change in the interfibrillar and intercellular spaces with the deposition of a substance which in most instances takes a fibrin stain. The modified collagen has

exhibited four different trends depending in part at least on the density of the tissue in which the lesion is located. (a) The collagen in dense connective tissue may form wide, compact, acellular, homogeneous, acidophilic bands in which fibrils cannot be made out by ordinary stains (Figure 1). This tissue is usually separated by more or less fluid. In the gross this is usually a small, firm, discrete nodule. (b) There may be widespread necrotization and fragmentation and even complete dissolution of collagen resulting in edema filled spaces with large fragments of necrotic, gelatinized, acellular, eosinophilic collagen (Figure 11). This type of nodule is usually large and soft even though it is in dense connective tissue. (c) The changed connective tissue may be arranged as coarse, intensely eosinophilic strands which tend to form a distinct concentric lattice work widely dispersed by edema, usually at a little distance from blood vessels, and richly infiltrated with cells. This type of nodule is usually large, soft, and situated in loose, irregular subcutaneous tissue (Figures 4, 8, and 12). (d) The collagen change may manifest itself as a fine, irregular, interweaving, fragmented network of loose necrotic fibrillar collagen with or without fibrin deposition (Figure 3). These areas are usually small, scattered, multiple, and situated at a short distance from the commonly damaged vessels. This type of reaction is usually found in loose subcutaneous tissue.

2. *Vessel change.* At the periphery of, or traversing the areas of necrotic tissue in these younger nodules, there are usually a number of small arteries, veins, and capillaries. Practically all the vessels, including capillaries, exhibit thickened, proliferative, rounded or almost cuboidal, deeply basophilic staining endothelium (Figures 3, 4, and 5). Many of the larger vessels show an intima thickened by subendothelial proliferation (Figure 8). Vacuolization and swelling of the subintimal cells is not uncommon with resulting marked narrowing of the lumen. The alterations in the media, when present, consist mostly of vacuolization and general diffuse swelling of the cells of the muscularis (Figures 4 and 8). Many of the vessels have a moderate polymorphonuclear leukocytic and lymphocytic infiltration involving all their layers and extending

into the perivascular tissues. Thrombus formation in the vessels has not been observed. In general, the vessel changes are not as severe as those described by Dawson and Boots (23).

3. *Cellular reaction.* In this early stage, there is usually a very definite perivascular proliferation and infiltration of the surrounding tissues. This is less marked in the small compact nodules and more general in the larger acute edematous specimens. The most marked proliferation is on the part of large, pale staining perivascular cells, the cytoplasm of which cannot be clearly defined by any of the stains used. The nuclei of these are large and oval with a pale staining, widely dispersed chromatin network. There is a large round nucleolus demonstrable by Maximow's eosin azur II stain. The exact nature of these cells cannot be ascertained, but they appear to be of the undifferentiated mesenchymal type (Figures 4 and 5). Surrounding and merging with this perivascular mantle of cells, and invading the border of the necrotic tissue are numerous scattered, more distinct, irregularly shaped mononuclear cells. These cells have a pale to deeply staining large reticular nucleus and a scanty, deeply basophilic staining, dusty, non-granular cytoplasm with one or more blunt, indistinct cytoplasmic processes, demonstrable by Mallory's phosphotungstic acid hematoxylin stain. A single large nucleolus may be seen with Maximow's eosin azur II stain. Some of these cells have much more distinct numerous long branching cytoplasmic processes demonstrable by the Mallory phosphotungstic acid hematoxylin stain, and appear to be altered fibroblasts (Figures 3 and 5). Multinuclear cells are uncommon, but when present they have the same general type of nucleus as the cells just described with either pale or deeply staining scanty and poorly outlined cytoplasm with or without branching, blunt cytoplasmic processes. In general, none of the above cells is strikingly similar to the Aschoff cell as seen in the myocardium, particularly in the appearance of the nuclei. Among these invading cells and scattered throughout the perivascular areas are many lymphocytes and a fair number of polymorphonuclear leukocytes and phagocytic wandering cells.

*Subcutaneous nodules present 1 to 3 months*

The characteristics of the nodules of this group substantiate the impression that there is a progressive organization of the lesions seen in the younger specimens. Consequently edema is insignificant, the vascularization is much more intense, and the lesion much more richly cellular than in younger nodules (Figure 6). As a result of this, grossly, nodules of this age group although they may vary considerably in size, are usually firm to palpation and ordinarily well circumscribed. As is the case with younger nodules there are three general types of change to be seen.

1. *Collagen change.* The foci of altered collagen are usually smaller and situated at a distance from invading blood vessels (Figures 6, 9, and 10). The staining affinity instead of having one type of reaction may stain either red or blue with hematoxylin and eosin stain and may appear to have in many instances basophilic granular precipitated material superimposed or in the tissue. The material does not take Mallory's aniline blue and frequently does not show an affinity for the fibrin stain. As may be expected from the several types of collagen alteration seen in the younger specimens, there is more than one type of collagen focus to be seen in specimens of this group. (a) The necrotic collagen may be present as compact fibrillar or amorphous acidophilic or basophilic staining plaques usually with detectable fibrin and invaded at the periphery by an intense cellular reaction (Figure 6). (b) The altered collagen may consist of small foci of fragmented, irregular, anastomosing, amorphous or beaded, eosinophilic or basophilic staining, interweaving strands of irregular size and shape. This material usually takes neither the aniline blue stain nor a fibrin stain. Invading these foci are densely packed cells of the type to be described shortly, similar in type to that seen in Figure 3.

2. *Vessel change.* There is a very definite vascularization of the whole nodule with a marked increase in the number of arterioles, venules, and capillaries present. The endothelium of most of the vessels has the same characteristics as those seen in the vessel linings of younger specimens, but they exhibit in addition marked vacuolization of the endothelial lining cells. In many instances

there is proliferation and thickening of the subintimal tissue with the deposition of an amorphous intercellular material which takes a diffuse blue color with Mallory's aniline blue stain (Figures 6 and 8). The elastica is not infrequently interrupted and fibrillar. Definite injury to the media is evidenced by swelling of muscularis cells and hyalinization with replacement of fibrous tissue in some instances. These changes result in marked narrowing of the lumen particularly of the arterioles. No actual thromboses or canalization of vessels have been seen. Lymphocytes are not uncommonly seen infiltrating the vessel walls, but polymorphonuclear leukocytes are rare.

3. *Cellular reaction.* About most of the vessels there is only a slight proliferation on the part of undifferentiated perivascular cells, similar to that seen in the younger nodules (Figures 6, 8, or 9). In general the perivascular cells are more distinct, the cytoplasm is clearly outlined, the nuclei are more deeply staining and reticular, and do not appear as actively proliferating as in younger nodules. About this irregular area of perivascular cells there is a gradation into closely radially arranged more mature cells having definite, sharply outlined basophilic staining, dusty, non-granular cytoplasm. The nuclei are dark, irregularly staining or reticular, and either single or multiple. Long, branching, intertwining cytoplasmic processes may be seen in sections stained with Mallory's phosphotungstic acid hematoxylin. There is definitely an increase in normal young fibrous tissue about the blood vessels and numerous normal looking collagen fibrils may be seen between the cells just described. As the areas of necrosis are approached, the collagen fibers become less numerous and less distinct, the cells tend to be more closely packed, and the processes of individual cells are made out with much greater difficulty. The cytoplasm is more deeply basophilic staining, is less abundant, is more poorly outlined, and cytoplasmic processes are few or absent. Multinuclear cells are common though in no instance are they numerous. These basophilic cells are similar in character though much more numerous than in younger lesions. The infiltration by polymorphonuclear leukocytes is minimal, phagocytic cells are few, and the lymphocytic reaction only moderate. The general appearance is that

of a progressive organization of the larger areas of collagen change seen in many of the younger nodules.

*Subcutaneous nodules present more than 3 months*

The characteristics of the nodules in this age group indicate a further organization of the previously described lesions.

1. *Collagen change.* There is a continuation of fibrous tissue organization with large areas of normal looking dense collagen for considerable distances from vessels (Figures 10 and 15). There are in some instances plaques of dense amorphous eosinophilic or basophilic material, the borders invaded by intensely basophilic cells and situated in large surrounding areas of normal looking young fibrous tissue (Figure 10). More common are small foci of amorphous or beaded, irregular, anastomosing, deeply blue staining strands located at a considerable distance from blood vessels (Figure 15). These represent the remnants of incompletely organized areas of injury noted in the younger nodules.

2. *Vessel change.* The vascularity of the lesion is still apparent but the number of capillaries is very definitely decreased in comparison with younger nodules. In these nodules the thickened basophilic endothelium, the narrowed lumen, the thickened intima, and fibrosed media persist in the medium sized vessels as do the endothelial changes in the precapillaries and capillaries. There is little or no cellular infiltration of the vessel walls although there is usually a slight lymphocytic reaction about the vessels.

3. *Cellular reaction.* In most sections there is practically no proliferation or extension of perivascular cells into the surrounding tissue. There is a large amount of proliferation of fibrous tissue which near the vessels is not very cellular, but nearer the remaining necrotic areas is more cellular. Immediately about the foci, the structure is like that at the periphery of the foci in the younger nodules with numerous closely packed basophilic cells with numerous intercellular fibrils. The cells in and around the necrotic areas are of the same type as those seen about the necrotic foci in nodules of the second group, although they are in general more intensely basophilic with both

the nucleus and cytoplasm taking a deep hematoxylin stain. Cytoplasmic processes are few and blunt, but normal intercellular collagen fibrils may be made out. Surrounding these peri-focal cells are numerous more normal looking, branching, active fibroblasts with large amounts of fibrillar intercellular collagen. The cells in the more mature connective tissue are not numerous and are elongated, normal, non-proliferative, inactive fibroblasts. There is a gradual gradation in characteristics from normal looking fibroblasts to the typical basophilic mononuclear and multinuclear cell which is so characteristic of the nodule and raises the question of their origin and function.

It should be noted that there were two nodules on which could be made no specific tissue diagnosis from their histological structure. They appeared to be more of a foreign body organization of nonspecific character.

The foregoing descriptions have been presented in an attempt to define the structure of the subcutaneous nodule and to gain some insight into the evolution and regression of these structures in subjects with rheumatic fever. That there is a considerable variation of structure is evident, but it seems likely that these variations may be explained on the basis of different stages in their evolution, and probably also on differences of anatomical location, i.e., whether they evolved in dense or loose connective tissue.

*The structure of induced subcutaneous nodules in subjects with rheumatic fever*

In the previous report (1) it has been demonstrated that the injection of blood into the deep subcutaneous tissues of subjects with rheumatic fever in certain stages of the disease is followed by a definite nodular reaction after about one to two weeks. It has further been stated that these nodules are grossly indistinguishable from the spontaneously occurring nodules so frequently seen in this disease. A comparison of the histological structure of these lesions with those of spontaneously occurring rheumatic fever nodules will be presented.

Of 37 nodules which were observed to appear following the procedures described in the preceding report, 19 were biopsies. They were removed carefully after regional anesthesia and were fixed,

sectioned, and stained in the same manner as were the spontaneously occurring nodules.

The nodules were removed after the following intervals from the time of their clinical detection:

1. Present less than 1 month .....	15
2. Present 1 to 3 months .....	4
3. Present more than 3 months .....	0

#### *Induced nodules present less than 1 month*

About half of the nodules in this group were removed after being present about 2 weeks; the other half after nearly 4 weeks. The latter in most instances presented the more characteristic histological structure. There is a considerable variation of structure in this group of nodules, but there is the same general tissue reaction noted in spontaneous nodules. As is the case with most young spontaneous nodules, edema is usually quite marked, separating the more common wide bands of necrotic connective tissue (Figures 13, 14, and 19). The fluid filled spaces have more amorphous precipitated material than do most spontaneous nodules, and there may be remaining old red blood cells in the same areas.

1. *Collagen change.* The alteration of structure and the staining reaction of the collagen in these induced lesions is similar to that seen in spontaneously occurring nodules of similar age. The area of the altered collagen is usually large and even macroscopic in size. The necrotic collagen usually forms wide bands of intensely eosinophilic homogeneous or fibrillar material, separated by fluid spaces containing considerable precipitated amorphous protein (Figure 19). In some instances there is found at a short distance from blood vessels an intensely eosinophilic staining irregular lattice work structure, identical to that seen in some spontaneous lesions (Figures 13 and 14). The altered collagen does not stain by Mallory's aniline blue and may or may not take a fibrin stain. The condition of the collagen fibrils and the interfibrillar spaces are indistinguishable from the changes seen in spontaneous nodules except for the presence of more amorphous precipitate.

Centrally in these large areas of collagen necrosis there is usually a fair amount of the above mentioned precipitate and sometimes old red blood cells and fibrin deposition. In these same

central areas there are few if any remaining blood vessels and little if any cellular infiltration; these latter are limited usually to the periphery of the lesion (Figure 19).

2. *Vessel change.* Invading the periphery of and in some cases traversing the lesion may be seen numerous proliferating, invading blood vessels and many dilated capillaries. There is the same markedly thickened basophilic endothelium seen in spontaneous nodules, and many of the vessels exhibit marked vacuolization of the intima with subintimal and medial swelling resulting in a definite decrease in the lumina of the vessels (Figures 16 and 20). There is in most instances a very definite polymorphonuclear leukocytic and lymphocytic infiltration of all of the layers of the vessel walls as well as of the perivascular tissues, appearing occasionally almost as a periarteritis. The vascular damage in these induced nodules is similar to, if not identical with that seen in spontaneous nodules, but in general is less severe.

3. *Cellular reaction.* Immediately surrounding the vessels in many nodules there is a definite proliferation of pale staining mononuclear cells which have very vague or indistinguishable cytoplasm, by any method of staining used. The nuclei are very large, oval, and pale staining with a widely dispersed chromatin network. A large purplish eccentrically placed nucleolus may be demonstrated by the polychrome stain. This perivascular proliferation in many instances forms a definite mantle about the vessels and is identical with the reaction seen about blood vessels in some young spontaneous nodules (Figures 20, 21 and 24). These seem to be undifferentiated perivascular mesenchymal cells. There is an associated moderate, perivascular, polymorphonuclear leukocytic and lymphocytic infiltration with a variable number of phagocytic cells. In the more typical nodules about this perivascular reaction there is a more extensive cellular response consisting of basophilic staining, elongated cells which have a large irregularly staining almost reticular nucleus. The cytoplasm is usually scanty, has an indefinite outline, is commonly basophilic and may or may not have cytoplasmic processes demonstrable by Mallory's phosphotungstic acid stain. Their long axes are in the direction of and in some instances encroaching on the border of the necrotic col-

lagen. These cells are indistinguishable from those seen in spontaneously occurring nodules. Occasionally, multinuclear cells of similar character may be seen (Figures 16, 20, 21, and 24). In the more atypical nodules there are fewer of these cells and more phagocytic wandering cells (Figure 17). Lymphocytes, polymorphonuclear leukocytes, and phagocytes are more common in most of the induced nodules than in spontaneous nodules, and occasional foreign body giant cells are seen. In 4 instances the tissue reaction seems to be a nonspecific type of reaction to a foreign material except for the collagen change, the edema, and the vessel alteration. In this respect it is to be recalled that in two spontaneously occurring nodules it was impossible to make a specific tissue diagnosis histologically.

#### *Induced nodules present 1 to 3 months*

All of the induced nodules in this group were removed after an interval of 2 to 3 months had elapsed since their clinical detection. Since they were in every detail indistinguishable from spontaneously occurring nodules of a similar age it is unnecessary to describe them separately (Figures 18, 22, and 23).

One induced nodule appeared in the control group. No definite diagnosis of rheumatic fever could be made in this patient, although the evidence against it was not absolutely convincing. Histologically, this nodule appeared to be simply an old organizing fibrosis of nonspecific character.

#### DISCUSSION AND CONCLUSIONS

From the review of the literature and from the descriptions given above it is evident that considerable variations of structure may be seen in the subcutaneous nodules of rheumatic fever. This tissue alteration may vary from a very characteristic structure to a microscopic picture resembling simply foreign body or necrotic tissue organization with few typical changes to permit a specific tissue diagnosis. An attempt has been made to explain these variations of microscopic structure from a consideration of the clinical age of the nodules studied and the density of the tissue in which they are located. This has been

difficult and only roughly approximate since the nodule is made up of submiliary and microscopic areas in different stages of organization. Therefore, only the trend of the majority of lesions may be considered to represent the pathological structure of the clinical nodule.

In spite of the difficulties encountered in studying these structures, it is believed that the histological evolution and regression of the subcutaneous nodule has been approximated in the small series studied. There is apparently first an alteration in the structure of collagen with the resulting edema formation and deposition of fibrin-like material. Concurrent with or shortly after this there is a vascular damage and a polymorphonuclear leukocytic and lymphocytic cell infiltration with a proliferation on the part of primitive perivascular mesenchymal and other cells which invade the borders of the altered collagen foci. Subsequent to this there is a gradual organization progressing from the perivascular areas toward the centers of the necrotic foci. During the course of this organization there results a typical type of cellular reaction consisting of closely packed, radially arranged, basophilic staining mononuclear and multinuclear cells which have staining reactions somewhat similar to fibroblasts and which are apparently capable of depositing intercellular collagen. The outcome is a progressive organization to a normal fibrous tissue replacement of the lesion. From this it appears that there is a definite progression of structure throughout the evolution and regression of the lesion.

Histologically, the structure of the artificially induced nodules is found to be very similar to, if not identical with that of spontaneously occurring nodules. There are, however, certain types of alteration in the histopathology of induced nodules which are inherent in the method of traumatization used and which distort the minute structure whether or not the tissue reaction is similar to that of the spontaneously occurring nodule. In the method used, there resulted a considerable damage and distortion of the subcutaneous connective tissue structure with resulting interference with tissue nutrition. Consequently, in the induced nodules there are the following three points



in common and different from most of the spontaneously occurring nodules. First, the areas of collagen alteration are much larger and the strands of collagen are considerably wider than is the case with most spontaneous nodules. Second, an appreciable amount of blood is introduced intercellularly which results in a larger phagocytic cell response than is the case in most of the young spontaneous nodules; this is most apparent in the younger nodule. Third, there is a considerable amount of intercellular and interfibrillar amorphous precipitate in these lesions apparently the result of introducing large amounts of blood into the tissue spaces. These differences are present whether or not the vascular and cellular response is similar to that of the spontaneous nodules, and are significant only in the nodules in the younger age group. Although these artifactual characteristics usually allow for a differentiation between young induced and young spontaneous nodules, the type of tissue response is in most instances similar and in some cases indistinguishable. No difference of structure can be determined between induced and spontaneous nodules in the older age group.

The results indicate that not only are the induced nodules clinically indistinguishable but pathologically also there is a great similarity of structure between these and spontaneously occurring nodules of similar age.

To Doctors John W. Spellman and Grantley W. Taylor, of the House of the Good Samaritan Surgical Staff, we wish to express our appreciation for performing the biopsies. The authors are indebted to Doctors Granville F. Bennett and Shields Warren for helpful suggestions and criticism.

#### BIBLIOGRAPHY

1. Massell, B. F., Mote, J. R., and Jones, T. D., The artificial induction of subcutaneous nodules in patients with rheumatic fever. *J. Clin. Invest.*, 1937, **16**, 125.
2. Barlow, T., and Warner, F., On subcutaneous nodules connected with fibrous structures occurring in children the subjects of rheumatism in rheumatics. *Tr. Internat. M. Cong.*, 7th session, London, 1881, **4**, 116.
3. Hirschsprung, H., Eine eigenthümliche Localisation des Rheumatismus acutus im Kindesalter. *Jahrb. f. Kinderh.*, 1881, **16**, 324.
4. Cavafy, Dr., Discussion in meeting of Pathological Society of London, *Lancet*, 1883, **1**, 544.
5. Cavafy, Dr., Pathological Society of London. Communications on rheumatic nodules. *Brit. M. J.*, 1883, **1**, 622.
6. Money, A., Same as reference (5).
7. Parker, R. W., Same as reference (5).
8. Middleton, G. S., A case of subcutaneous nodules in the hands of a rheumatic patient. *Am. J. M. Sc.*, 1887, **94**, 433.
9. Mitchell, J. K., Fibrous nodules in rheumatic fever. *Univ. Med. Mag.*, 1888, **1**, 161.
10. Nepveu, M., Sur l'origine embolique des nodosités éphémères du rhumatisme. *Compt. rend. Soc. de biol.*, 1890, ser. 9, **2**, 328.
11. Fitcher, T. B., A study of subcutaneous fibroid nodules. *Bull. Johns Hopkins Hosp.*, 1895, **6**, 133.
12. Poynton, F. J., and Still, G. F., The histology of the rheumatic nodule. *Tr. Pathological Society of London*, 1899, **50**, 324.
13. Wick, L., Ueber rheumatische Knoten bei akutem und chronischem Gelenkrheumatismus. *Wien. Med. Presse*, 1904, **45**, 1117.
14. Coombs, C., The microscopic or "submiliary" nodules of active rheumatic carditis. *J. Path. and Bact.*, 1911, **15**, 489.
15. Frank, P., Ueber den Rheumatismus nodosus mit besonderer Berücksichtigung des pathologisch-anatomischen Befundes. *Berl. klin. Wchnschr.*, 1912, **49/2**, 1358.
16. Tilp, Nodi rheumatici galeae aponeuroticae. *Centralbl. f. allg. Path. u. path. Anat.*, 1914, **25**, 425.
17. Swift, H. F., The pathogenesis of rheumatic fever. *J. Exper. Med.*, 1924, **39**, 497.
18. Coates, V., Rheumatic infection in childhood. The subcutaneous fibroid nodule as an early manifestation. *Brit. M. J.*, 1925, **1**, 550.
19. MacCallum, W. G., Rheumatism, *J. A. M. A.*, 1925, **84**, 1545.
20. Coates, V., and Coombs, C. F., Observations on the rheumatic nodule. *Arch. Dis. Childhood*, 1926, **1**, 183.
21. Merritt, K., Rheumatic nodules: Their incidence in rheumatic infections. *Am. J. Dis. Child.*, 1928, **35**, 823.
22. Clawson, B. J., The Aschoff nodule. *Arch. Path.*, 1929, **8**, 664.
23. Dawson, M. H., and Boots, R. H., Subcutaneous nodules in rheumatoid (chronic infectious) arthritis. *J. A. M. A.*, 1930, **95**, 1894.
24. Klinge, F., Der Rheumatismus. Ergebnisse der allgemeinen Pathologie und pathologischen Anatomie des Menschen und der Tiere. *J. F. Bergmann, Munich*, 1933.
25. McEwen, C., Cytologic studies on rheumatic fever: The characteristic cell of the rheumatic granuloma. *J. Exper. Med.*, 1932, **55**, 745.

## LEGENDS TO FIGURES

FIG. 1. SPONTANEOUS SUBCUTANEOUS NODULE REMOVED 7 DAYS AFTER ITS APPEARANCE. H & E.  $\times 135$ .

Right upper portion of section consists of broad fragmented bands of intensely eosinophilic dense altered connective tissue separated by edema. Extending diagonally across the center of the section may be made out a radially invading layer of thin, elongated, closely packed, poorly outlined basophilic cells. Infiltration by other types of cells is minimal.

FIG. 2. SPONTANEOUS SUBCUTANEOUS NODULE REMOVED 3 MONTHS AFTER ITS DETECTION, AREA OF ACUTE CHANGE WITHIN AN OLDER NODULE. H & E.  $\times 135$ .

In the right lower portion may be made out several small vessels which are normal except for dilatation. The perivascular tissue is very edematous with a slight lymphocytic infiltration. In the upper left portion of the section are wide homogeneous bands of deeply eosinophilic collagen in which the normal collagen structure is masked. There is no characteristic cellular reaction in this section.

FIG. 3. SPONTANEOUS SUBCUTANEOUS NODULE REMOVED 7 DAYS FROM ITS CLINICAL APPEARANCE. H & E.  $\times 150$ .

In the left lower portion are a number of small dilated capillaries with definite perivascular fibrosis. The upper central portion is occupied by a focus of fragmented necrotic collagen with considerable edema. Lymphocytes and large basophilic mononuclear cells may be seen invading the periphery of the focus. The cellular nature of the surrounding fibrous tissue indicates the probable existence of an older subclinical nodule for some time.

FIG. 4. SPONTANEOUS SUBCUTANEOUS NODULE REMOVED 5 DAYS AFTER ITS APPEARANCE. H & E.  $\times 135$ .

This section demonstrates well the small vessel damage, the perivascular mononuclear cell proliferation, and the irregular lattice work structure which is seen in some nodules. The cellular reaction is typical but not marked for an early nodule of this type.

FIG. 5. SPONTANEOUS SUBCUTANEOUS NODULE REMOVED 7 DAYS AFTER ITS DETECTION. H & E.  $\times 150$ .

To the right are seen several small vessels which have somewhat thickened endothelial lining cells. There is definite edema of the perivascular tissues with a moderate lymphocytic infiltration. The larger elongated deeply basophilic cells are discernible with their radial arrangement at the border of the necrotic edematous collagen at the extreme left.

FIG. 6. SPONTANEOUS NODULE REMOVED 3 MONTHS AFTER ITS CLINICAL DETECTION. H & E.  $\times 175$ .

There is definite vascularization of the tissue in the left center with thickening of the walls of the small vessels and thickening of the endothelium. The young loose fibrous tissue in the whole area is apparent. The large mononuclear and multinuclear cells are numerous and the intercellular collagen is easily seen. This is a progression of the organizing process.

FIG. 7. SPONTANEOUS SUBCUTANEOUS NODULE 5 MONTHS OLD. H & E.  $\times 135$ .

Upper portion of section consists of normal dense irregular connective tissue. The left lower portion is a very cellular fibrous tissue having no distinguishing cellular characteristics. This is a late stage of fibrosis in a subcutaneous nodule.

FIG. 8. SPONTANEOUS SUBCUTANEOUS NODULE REMOVED 3 MONTHS AFTER ITS APPEARANCE. H & E.  $\times 275$ .

This section is of an area of more acute damage in a nodule constituted mainly of tissue consistent with an older nodule. The vascular damage is the most obvious alteration with thickening of both the endothelial lining and the vessel walls with swelling, subintimal proliferation, and polymorphonuclear leukocytic infiltration. The perivascular edema and cellular infiltration with polymorphonuclears, lymphocytes, phagocytic cells, and necrotic collagen strands may be made out in the extreme upper portion. There is no characteristic cellular reaction.

FIG. 9. SPONTANEOUS SUBCUTANEOUS NODULE 3 MONTHS OLD. H & E.  $\times 300$ .

Moderately high power magnification to show the cellular detail. Fine long normal intercellular fibrils of collagen may be made out between the large rather closely packed basophilic staining cells.

FIG. 10. SPONTANEOUS SUBCUTANEOUS NODULE OF 4 MONTHS DURATION. H & E.  $\times 135$ .

Lower portion of section is made up of dense irregular connective tissue; the mild reaction about the small vessels is to be noted. The middle portion is made up of rather cellular proliferating fibrous tissue with a few of the typical basophilic cells invading the necrotic material.

FIG. 11. SPONTANEOUS SUBCUTANEOUS NODULE REMOVED 7 DAYS AFTER ITS CLINICAL APPEARANCE. H & E.  $\times 25$ .

Low power view to show the almost cystic character of the damaged areas of collagen. The upper center portion is a very edematous area of fragmented necrotic collagen. There are several small vessels traversing the lower half of the section with a perivascular cellular reaction.

FIG. 12. SPONTANEOUS SUBCUTANEOUS NODULE REMOVED 5 DAYS AFTER ITS APPEARANCE. H & E.  $\times 25$ .

Low power view to show the widespread edema of the tissue with the numerous irregular strands of intensely eosinophilic altered collagen.

FIG. 13. INDUCED SUBCUTANEOUS NODULE REMOVED 10 DAYS AFTER ITS APPEARANCE. H & E.  $\times 45$ .

Low power view to show the widespread edema of the tissue with the characteristic lattice type of condensed eosinophilic staining necrotic collagen strands so frequently seen.

FIG. 14. BIOPSY OF INDUCED SUBCUTANEOUS NODULE 3 WEEKS AFTER ITS APPEARANCE. H & E.  $\times 35$ .

Low power view to demonstrate the deeply staining irregular fragmented collagen strands in the center. Edema is not so marked as in younger specimens.

FIG. 15. SPONTANEOUS SUBCUTANEOUS NODULE OF 4 MONTHS' DURATION. H & E.  $\times 135$ .

Another area of nodule as shown in Figure 10. The abundant cellular fibrous tissue with a slight lymphocytic reaction is the only residuum of the organizing nodule.

FIG. 16. BIOPSY OF INDUCED SUBCUTANEOUS NODULE 3 WEEKS FROM THE TIME OF ITS DETECTION. H & E.  $\times 150$ .

The general edema of the section is evident. Definite alteration of small vessel structure may be made out and the slight proliferation of pale staining perivascular cells may also be seen. The presence of large deeply staining cells may be seen as well as numerous lymphocytes and phagocytes.

FIG. 17. INDUCED SUBCUTANEOUS NODULE REMOVED 4 WEEKS AFTER ITS APPEARANCE. H & E.  $\times 135$ .

Necrotic fragmented collagen may be seen above. In the central portion of the section are lymphocytes, a few phagocytes, and a fair number of large basophilic cells similar to those seen in young spontaneous nodules.

FIG. 18. INDUCED SUBCUTANEOUS NODULE REMOVED 8 WEEKS AFTER ITS APPEARANCE. H & E.  $\times 125$ .

The necrotic deeply staining, fragmented collagen may be made out to the right. The alteration of vessels is definite but not marked, but the cellular reaction invading the collagen is typical and indistinguishable from that seen in spontaneous nodules.

FIG. 19. INDUCED NODULE REMOVED 3 WEEKS AFTER ITS DETECTION. H & E.  $\times 45$ .

Low power field to show the widespread damage that may be present in some induced nodules. Red blood cells may be made out in the fluid-filled spaces. Relatively normal, dense connective tissue may be made out to the extreme left.

FIG. 20. BIOPSY OF INDUCED SUBCUTANEOUS NODULE  $2\frac{1}{2}$  WEEKS FROM CLINICAL APPEARANCE. H & E.  $\times 275$ .

The vascular change is evident with a definite lymphocytic infiltration of the walls and thickened, swollen

endothelium and media. The surrounding edema with the "lattice work" collagen change above is apparent. Lymphocytes and phagocytes are definite and a few large reticular nucleated, basophilic staining mononuclear cells may be made out.

FIG. 21. INDUCED SUBCUTANEOUS NODULE REMOVED 4 WEEKS AFTER ITS APPEARANCE. H & E.  $\times 250$ .

This section demonstrates the characteristic small vessel change with surrounding perivascular proliferation, edema, and lymphocytic and phagocytic cell infiltration. Large elongated deeply basophilic staining cells, which cannot be differentiated from those seen in spontaneous nodules, are also present. In the left upper corner are irregular fragmented strands of collagen.

FIG. 22. BIOPSY OF INDUCED SUBCUTANEOUS NODULE  $2\frac{1}{2}$  MONTHS FROM TIME OF APPEARANCE. H & E.  $\times 150$ .

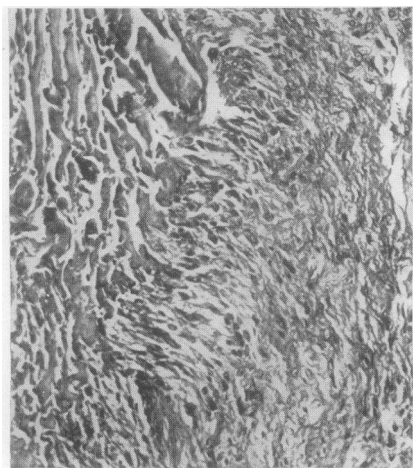
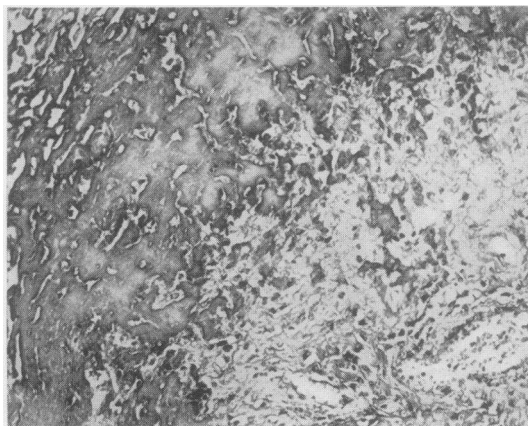
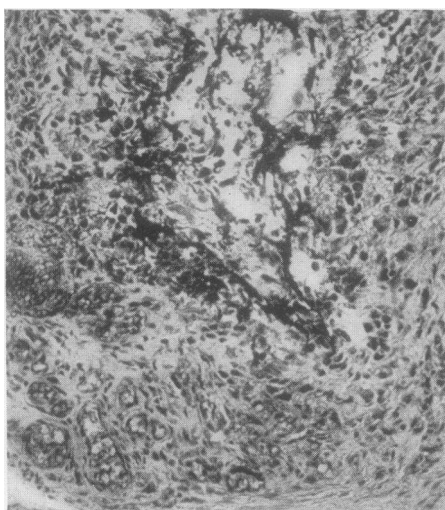
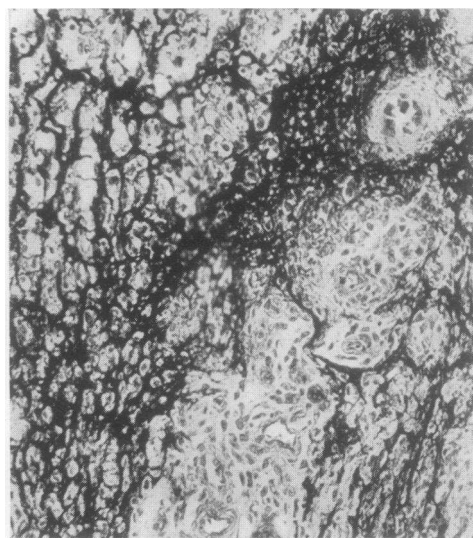
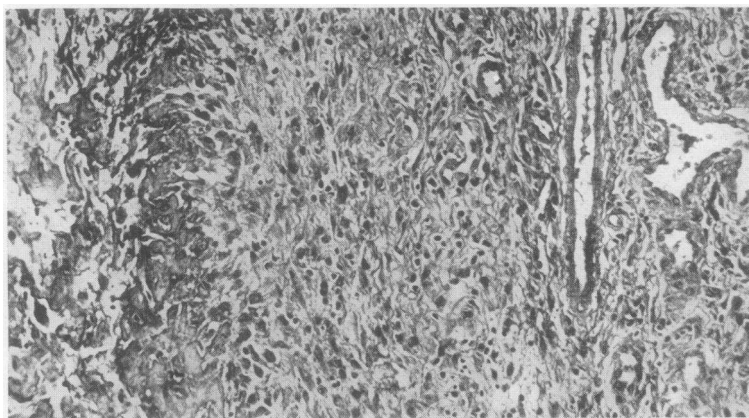
Section shows fibrosis about borders with centrally an area of cellular reaction, encroaching on a few strands of deeply basophilic staining necrotic collagen. The cells involved and general structure cannot be distinguished from those seen in spontaneously occurring nodules of similar age.

FIG. 23. INDUCED SUBCUTANEOUS NODULE REMOVED 4 WEEKS AFTER ITS DETECTION. H & E.  $\times 275$ .

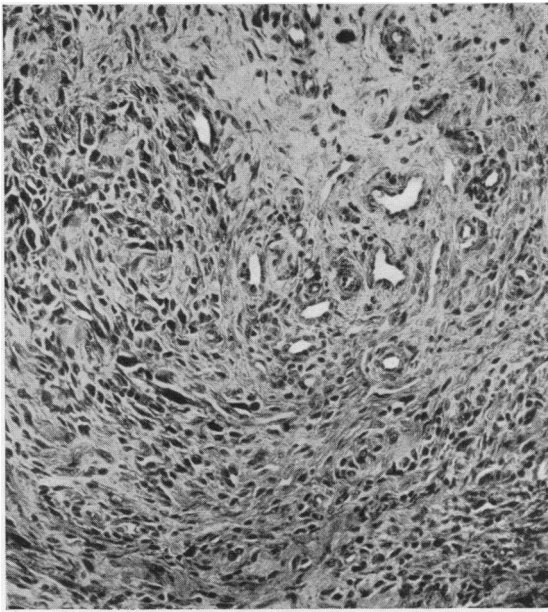
In the left upper corner is degenerated, eosinophilic, fragmented collagen. The greater portion of the section is made up of closely packed large basophilic staining cells with indistinct cytoplasmic processes. These cells are in character indistinguishable from those found in spontaneous nodules. There is as yet little intercellular collagen present.

FIG. 24. INDUCED SUBCUTANEOUS NODULE REMOVED 3 WEEKS AFTER ITS CLINICAL APPEARANCE. P. T. A. H.  $\times 135$ .

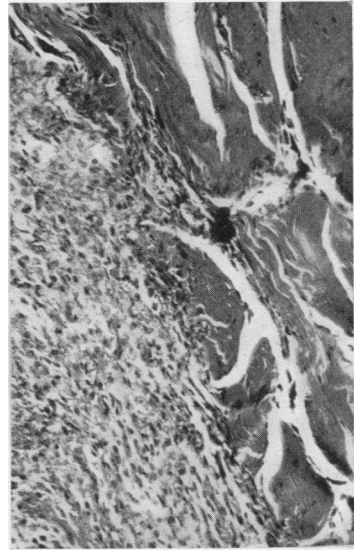
The widespread edema is evident. The small vessel change can be easily made out as can the collagen change in the upper and left field. The cytoplasmic processes of the large basophilic staining cells are well shown. These cells cannot be differentiated from those seen in spontaneously occurring nodules. Lymphocytes and phagocytes are both present. The general structure is identical to that seen in younger spontaneous lesions.

**FIG.1****FIG.2****FIG.3****FIG.4****FIG.5**

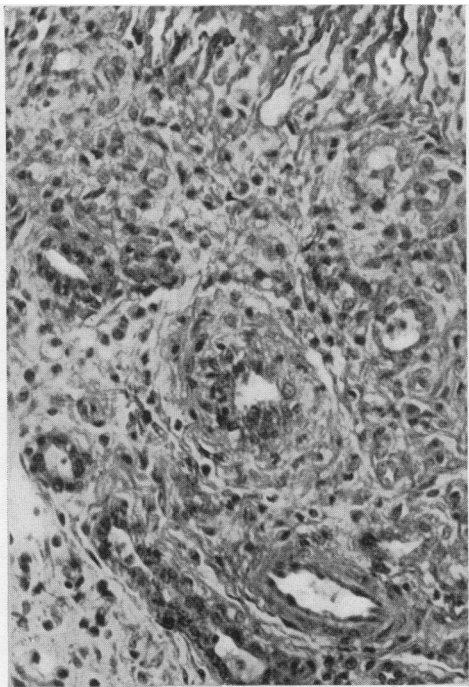
SEE PAGE 138 FOR LEGENDS.



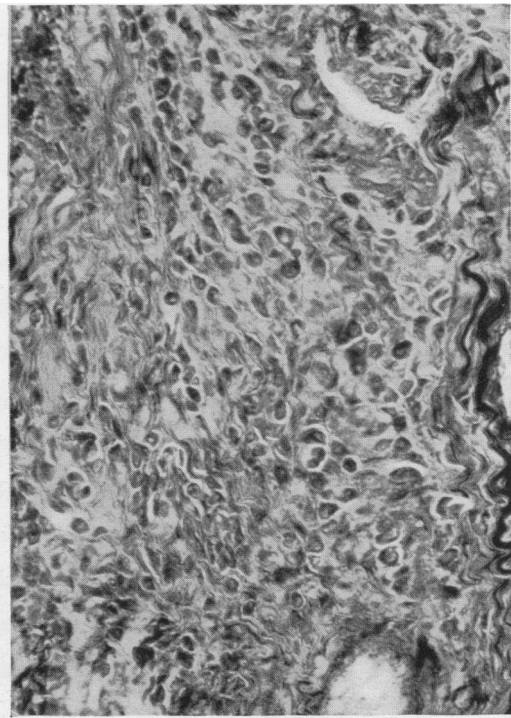
**FIG.6**



**FIG.7**

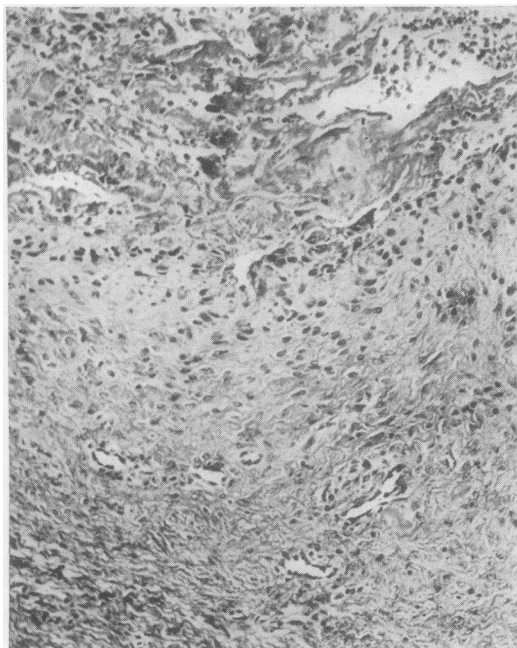
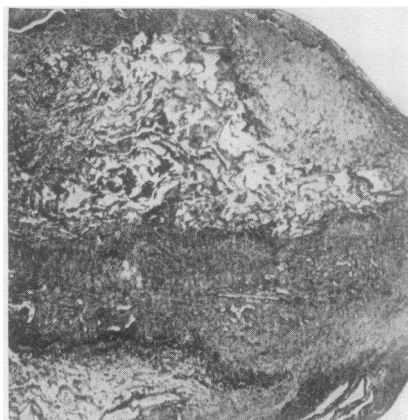

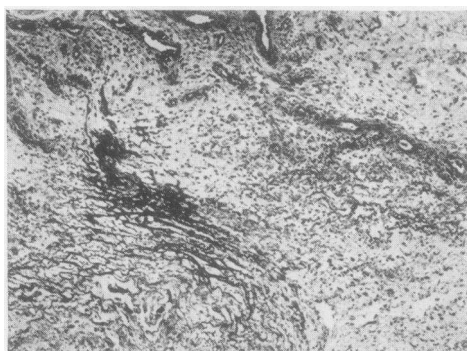
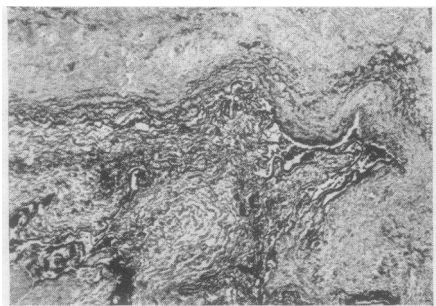
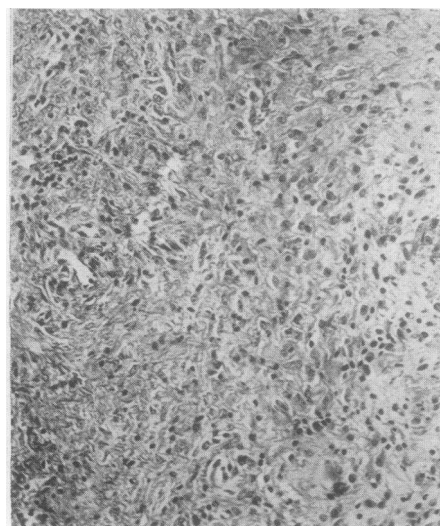


**FIG.8**



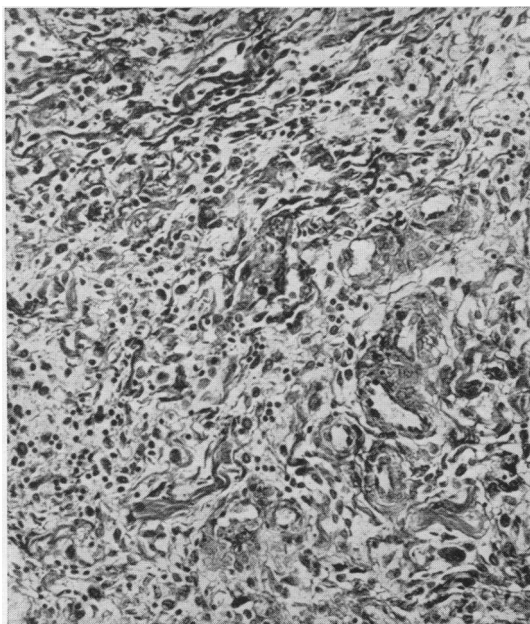
**FIG.9**

SEE PAGE 138 FOR LEGENDS.

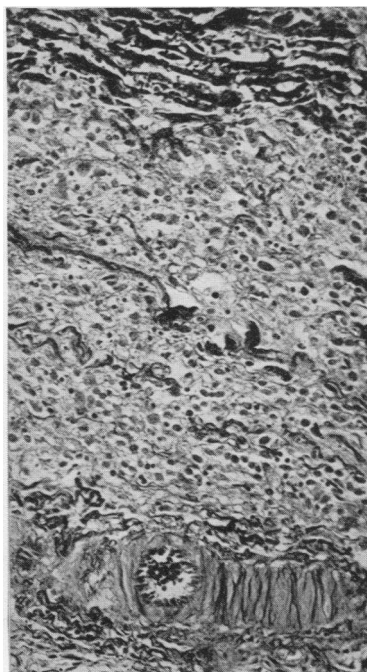
**FIG. 10****FIG. 11****FIG. 12****FIG. 13****FIG. 14****FIG. 15**

SEE PAGES 138-139 FOR LEGENDS.

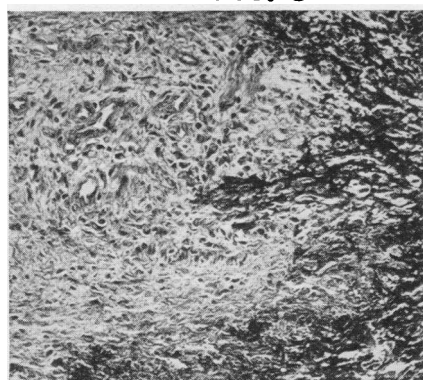




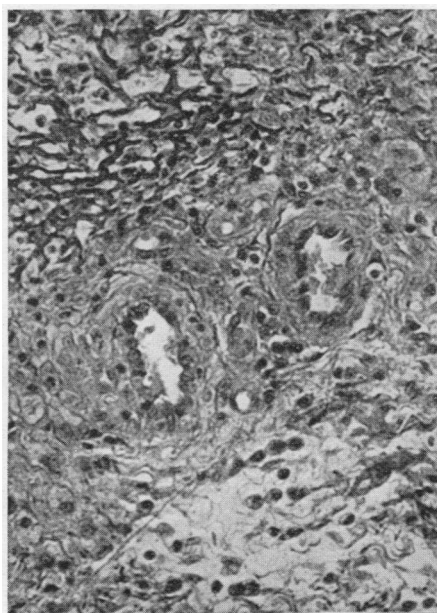
**FIG.16**



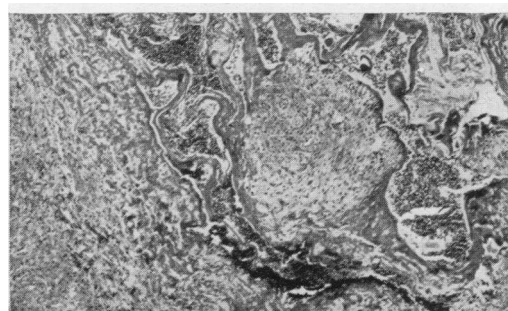
**FIG.17**



**FIG.18**

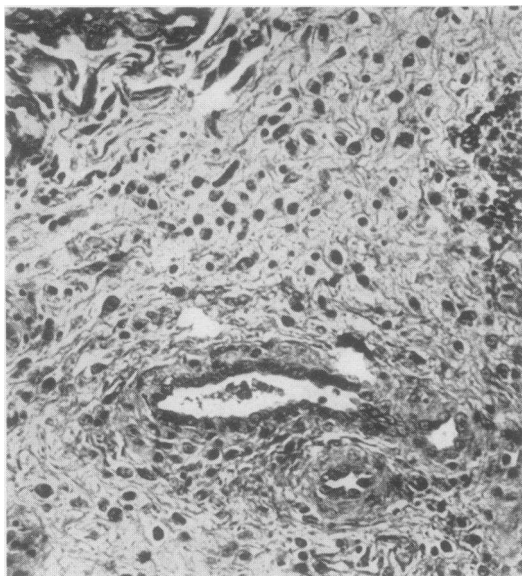
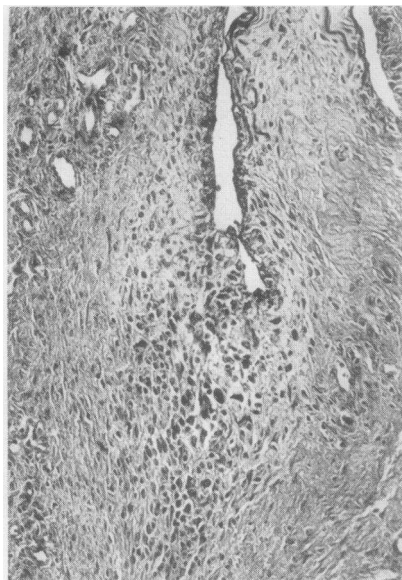
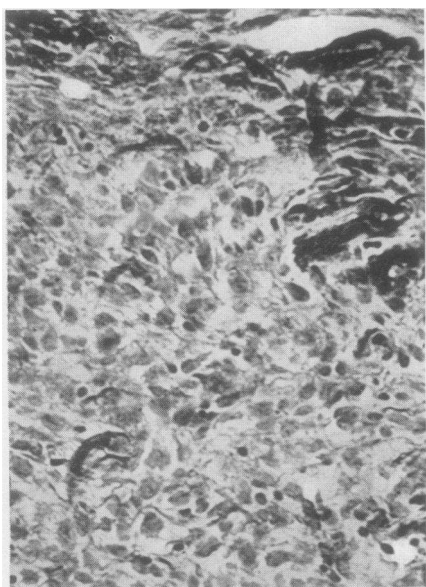
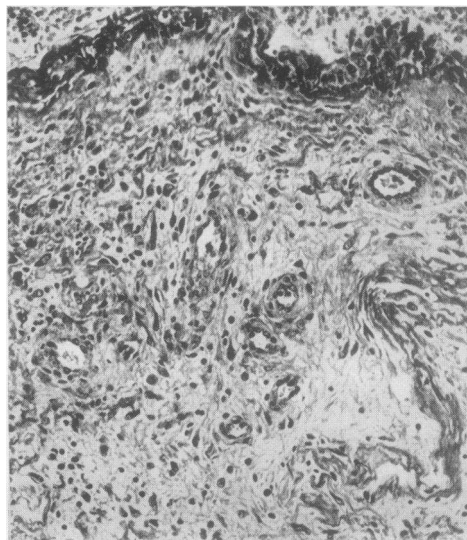


**FIG.20**



**FIG.19**

SEE PAGE 139 FOR LEGENDS.

**FIG.21****FIG.22****FIG.23****FIG.24**

SEE PAGE 139 FOR LEGENDS.