

**EXPERIMENTAL PNEUMOCOCCUS LOBAR PNEUMONIA IN THE
DOG : *I. Method of Production and Course of the Disease***

Edward E. Terrell, ... , Oswald H. Robertson, Lowell T. Coggeshall

J Clin Invest. 1933;12(2):393-432. <https://doi.org/10.1172/JCI100510>.

Find the latest version:

<https://jci.me/100510/pdf>



EXPERIMENTAL PNEUMOCOCCUS LOBAR PNEUMONIA IN THE DOG^{1, 2}

I. METHOD OF PRODUCTION AND COURSE OF THE DISEASE

BY EDWARD E. TERRELL, OSWALD H. ROBERTSON
AND LOWELL T. COGGESHALL

(From the Department of Medicine, University of Chicago, Chicago)

(Received for publication October 31, 1932)

Until the work of Blake and Cecil (1) lobar pneumonia had not been produced in the lower animals with any degree of constancy. These authors succeeded in producing in monkeys (*Macacus Syrichtus* and *Cebus Capucinus*) by means of the intratracheal injection of small quantities of pneumococcus culture a lobar pneumonia which in its symptomatology, evolution and pathological histology resembled closely the disease seen in man. This work was repeated by Schöbl and Sellards (2), who confirmed the clinical findings of Blake and Cecil but concluded that the pathology of the pulmonary process resembled more nearly the picture of the confluent bronchopneumonia produced by the pneumococcus in the rabbit, than the characteristic lesion in man.

Other investigators working with the dog have found that in order to produce pulmonary infection with the pneumococcus not only must the infecting agent be implanted far down into the bronchial tree but that the inoculum must be massive. Lamar and Meltzer (3), using such a method, were successful in establishing in some of their animals lobar consolidation and a disease resembling an abortive lobar pneumonia. Those in which the disease ran a longer course died within two to four days with bacteremia and pyemic complications. One or more lobes showed consolidation which was considered to be similar to that of the human lobar pneumonia. Some of their dogs escaped infection. More recently Coryllos and Birnbaum (4) have employed a modification of this method, spraying large quantities of pneumococcus culture—10 to 15 cc.—into the lung through a bronchoscope either with or without subsequent occlusion of the main bronchus. This resulted either in a transient infection or a widespread pneumonia accompanied by extensive atelectasis and an ensuing generalized infection usually with a fatal termination. Lobar consolidation has also been produced in rabbits by the intrapulmonary injection of pneumococci with similar (5) (6) or other (7) methods, but the course of the disease in these animals showed neither constancy nor close resemblance to the clinical syndrome of lobar pneumonia.

It has been assumed that the antipneumococcal resistance of the dog was much higher than that of man, and hence a correspondingly larger

¹ This work was supported in part by the Douglas Smith Foundation of the University of Chicago.

² Reported in abstract form in the Proc. of Exper. Biol. and Med., 1929-30, xxvii, 973.

dosage was necessary to produce pulmonary infection. We have found, however, in our studies on natural immunity that the pneumococcal action of the blood of the dog is not much greater than that of the average human being. While we do not know that the pneumococcal property of the blood has the same significance in the immunity of both species, we have evidence, derived from several varieties of animals including the dog, to show that the pneumococcal power of the blood parallels in general the species' resistance to pneumococcus infection (8) (9). Hence it seemed reasonable to suppose that could suitable conditions for the inception of lobar pneumonia be contrived, the establishment of this disease in the dog might be attained with a dosage not entirely incomparable with that producing the disease in man.

Previous investigation of the natural pneumococcal potency of the blood of patients with lobar pneumonia (10) revealed the fact that, in a considerable proportion of instances, this property was present to a normal degree at the beginning of the disease. The inference was that the initial environment for the growth of the pneumococcus in the lungs must be one which affords protection against the pneumococcus-killing agencies of the blood. Experimentally such protection might be provided by implanting pneumococci, suspended in a suitably viscous medium, into the terminal portion of the bronchial tree from which position it could not be readily expelled. Numerous experiments were undertaken on the basis of this conception.

METHOD

The method finally adopted consisted in the intrabronchial injection of pneumococci suspended in a starch-broth mixture through a radiopaque catheter with the dog under the fluoroscope. The details are as follows:

(1) *Dogs.* Considerable care was taken to select suitable dogs for the experiments. These were observed for a week to ten days beforehand, the temperature recorded daily, cod liver oil given with their food and conditions for considerable activity provided. Dogs in poor nutritional condition, those showing signs of snuffles, or other respiratory disease, or having a temperature above normal were discarded. An attempt was made to obtain animals with round chests as being more suitable for x-raying. With one or two exceptions male dogs were employed throughout the study.

(2) *Pneumococci.* The strains used were pneumococcus Types I and II isolated from the blood of patients with lobar pneumonia and highly virulent for rabbits and mice. The Type I (A_6) was of considerably higher virulence for dogs than the Type II (V_0) strain. In some instances other strains of lower virulence were employed. However, except where particularly noted, the cultures used were A_6 and V_0 . These organisms were subjected to repeated animal passage during the course of the work. All cultures used for inoculation were in the phase of active growth.

(3) *Starch-broth mixture.* To 30 cc. of a cold meat infusion broth pH 7.8, 5.5 grams of starch were added. This was well mixed and added slowly to 70 cc. of broth, heated in a boiling water bath. The mixture was stirred to a thick translucent paste. At this time it was found advisable to transfer the

mixture from the beaker to a flask which was allowed to remain for five minutes in the water bath to insure sterility. (H-ion concentration of the original broth remained unchanged.) To mix the starch and pneumococci the culture was first centrifuged and the supernatant fluid discarded. Sufficient warm starch-broth mixture to make the desired dilution was added to the sedimented pneumococci and stirred thoroughly but slowly in order to avoid bubble formation. However, with small doses, 0.02 cc. or less, the culture was mixed directly with the starch-broth.

(4) *Anesthesia.* In order to quiet the animal and produce the necessary fall in temperature (the importance of which will be commented on later) a preliminary injection of morphine sulphate was given. The most suitable dose was found to be 6 mgm. per kilo of body weight. Then to abolish the cough reflex the larynx was well painted with 10 per cent cocaine solution, care being taken to confine the cocaine as far as possible to this area—the epiglottis to the vocal cords. Ten to fifteen minutes was allowed to elapse before passing the catheter.³

(5) *Technique of x-ray examination.* A special board was devised particularly for the purpose of taking x-rays (Fig. 1). This holder was later




FIG. 1. ANIMAL BOARD FOR HOLDING DOG WHILE TAKING X-RAYS

Dimensions are: length 48 inches, width 15 inches. Cassette holder takes cassette.

modified by Dr. Ching Wu (12) to the extent of substituting for the original canvas sling a thin piece of aluminum with a longitudinal groove in the middle. With his spine in the groove the dog is thus held more firmly in position. The animal's fore legs are fastened down to its side, which removes the scapulae as much as possible from the lung field. The telescopic side rails are lengthened or shortened until the head fits the head restrainer. A band of gauze may also be passed over the chest to help immobilize the dog. The cassette holding the x-ray film is slipped under the board, held in a constant position by the wooden carrier shown in the illustration. Sighting along the prominence of the sternum, the examiner twists the animal slightly to the right or left until in his

³ It was at Dr. Harry B. van Dyke's suggestion that the method of morphine-cocaine anesthesia was first used.

judgment the center of the sternum is perpendicularly above the spinous process of the thoracic spine. The x-ray tube is brought into position directly above the center of the cassette and an exposure is made at the height of inspiration. We have used approximately the following setting: target-film distance, 36 inches; tube current, 100 M. A.; tube voltage, 74 peak K.V.; filter, none; exposure time, one-twentieth of a second for small animals, more for heavier ones; Eastman duplitized film; Patterson cleanable intensifying screens. We are greatly indebted to Dr. Paul Hodges and Dr. Ching Wu, who worked out this technique for us. At least one x-ray was taken on nearly all of the experimental animals. In many of them x-rays were taken daily or every other day throughout the course of the disease. Fluoroscopic examination was used extensively.

(6) *Technique of injection.* The catheter employed was a hard rubber radiopaque ureteral catheter, size 11, the tip of which had been cut off and a small piece of fine bore rubber tubing slipped over the cut end to cover the rough surface. The catheter had been previously cleaned and sufficiently sterilized by washing well in alcohol and ether.⁴ Taking care to avoid all contact with the mouth, the catheter was passed slowly into the bronchial tree and the final position observed under the fluoroscope. After it had been inserted as far as possible, the catheter was withdrawn about 0.5 cm. Bending the top of the catheter a little facilitated passage to the desired bronchus. Next 1 cc. of the starch-broth-pneumococcus suspension was slowly injected. An additional 1.2 cc. was allowed for the capacity of the catheter. If the animal had been adequately prepared there was no coughing except at the moment the catheter touched the terminal point in its passage.

(7) *Post anesthetic care.* Since the dogs had a subnormal temperature for several hours afterwards, the precaution was taken to see that the room temperature was at least 70° F. A board was provided for them to lie on in their cages.

In the early phases of the work several kinds of anesthetics and suspending media for the pneumococci were tried. Ether was found to be unsatisfactory as an anesthetic, because of the frequent occurrence of widespread pulmonary infection after its use. Occasionally the pneumococci remained localized at the point of insertion, but this was not the rule. Better results were obtained by the employment of sodium amytal intravenously. But again the effects of this agent were often deleterious. The dogs sometimes remained in a semicomatose state for twenty-four to thirty-six hours and occasionally developed a spontaneous bronchopneumonia. The most satisfactory anesthetic was morphine combined with the local application of cocaine, as described above. The doses of morphine used at first, 10 to 15 mgm. per kilo, often produced prolonged depression of temperature and pulse rate sometimes lasting twenty-four hours. The dose finally adopted caused fairly regularly a lowering of body temperature of 2 to 4° C., lasting usually four to six hours, with an associated drop in pulse rate. Before the employment of starch, 16 to 20 per cent gelatin was used as a medium of suspension

⁴ It is important to dry the catheters well after cleaning, as the alcohol and ether will dissolve the material in the walls of the tube.

for the pneumococci. While lobar pneumonia was successfully produced by pneumococci suspended in this substance, there were certain drawbacks to its use. Even though adjusted to a pH of 7.6, this concentration of gelatin, employed because of its cohesive properties, was not a favorable medium for the growth of pneumococcus. After sterilization its viscosity and rate of liquefaction was found sometimes to vary. The 5 per cent starch suspension afforded a much better medium and had a more constant viscosity.

The right lower lobe was chosen as the usual site for the production of the experimental disease since this was the easiest route for injection into a terminal bronchus and in addition this lobe was much less obscured by the heart shadow than was the left lower. Initial lesions were also successfully produced in the right middle and left lower lobes.

Lung punctures were made in many of the infected dogs at the height of the disease in order to determine the presence of pneumococci or other organisms in the lesion.

EXPERIMENTAL

The present study comprises observations on considerably more than one hundred dogs. Failures to produce the experimental disease, while numerous at first, became fewer with improvement in technique, until, with the method above described and with carefully selected dogs, it was possible to induce experimental lobar pneumonia with a high degree of constancy. In fact, with the Type I strain, used in appropriate dosage, infection has occurred in every instance.

The course of the experimental disease showed considerable variation in the different animals, depending to a large extent on the infecting dose. Other factors, however, were found at times to have an important influence on the body's reaction to the invading microorganism. These will be discussed later. The several manifestations of disease produced may be divided into two general types: first, animals showing localization of the pulmonary lesion and lobar consolidation with ensuing recovery or death; second, dogs developing, from the beginning or during the course of the disease, a generalized infection with or without lobar consolidation which ended fatally. Illustrative examples follow.

Dogs showing localization of the lesion followed by recovery

Experiment I. Dog 37, weight 10.8 kgm. (Chart 1). On December 12, 1929, the dog was prepared with sodium amytal, 40 mgm. per kilo of body weight, following which 0.5 cc. culture pneumococcus Type I, suspended in gelatin, was injected into the right lower lobe. By the next morning the effects of the amytal had worn off. The dog was lively but had a temperature of 105.6° and a respiratory rate of 126. On examination of the chest the only abnormal findings were coarse râles heard over entire right lung area. X-ray (Fig. 2) showed a small but definite area of clouding in the right lower chest.

The following day faint bronchial breathing was heard over the right lower chest posteriorly, and the dog began to cough. On the fourth day the bronchial breathing was more distinct but on the fifth day disappeared and was replaced

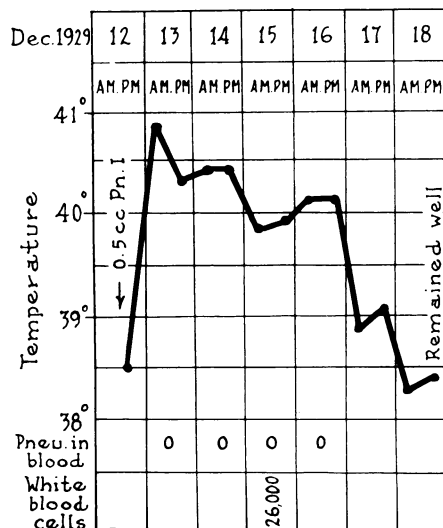


CHART 1. DOG 37. EXPERIMENTAL LOBAR PNEUMONIA FOLLOWING THE INTRABRONCHIAL INJECTION OF 0.5 CC. BROTH CULTURE OF PNEUMOCOCCUS TYPE I SUSPENDED IN 20 PER CENT GELATIN.

by suppressed breath sounds. A critical drop in temperature occurred between the fifth and sixth days.⁵ At no time during the disease did the dog appear ill. The x-rays of the pulmonary lesion in this animal (Fig. 2 and 3) show an even spread of the process from December 13th to 14th, when the whole right lower lobe was involved. There was then no further spread, and the lesion remained unchanged during the febrile course (Fig. 4 and 5).⁶ On December 20th, three days after the temperature had fallen, x-ray showed a definite clearing of the process, which had almost completely disappeared by December 23d (Fig. 6 and 7).

The course of the disease in this animal characterized by an acute onset, a sustained fever for five to six days, a localized pulmonary lesion, as indicated by the absence of blood invasion, a critical drop in temperature and subsequent complete resolution of the lung lesion without apparent tissue destruction, shows a striking resemblance to lobar pneumonia in man, progressing to favorable termination.

⁵ For the sake of uniformity and convenience the day of injection is counted as the first day of disease. It will be shown later that the pathological process begins within a few hours after injection.

⁶ An extension to the post cardiac lobe cannot be excluded since this is entirely hidden by the heart shadow.

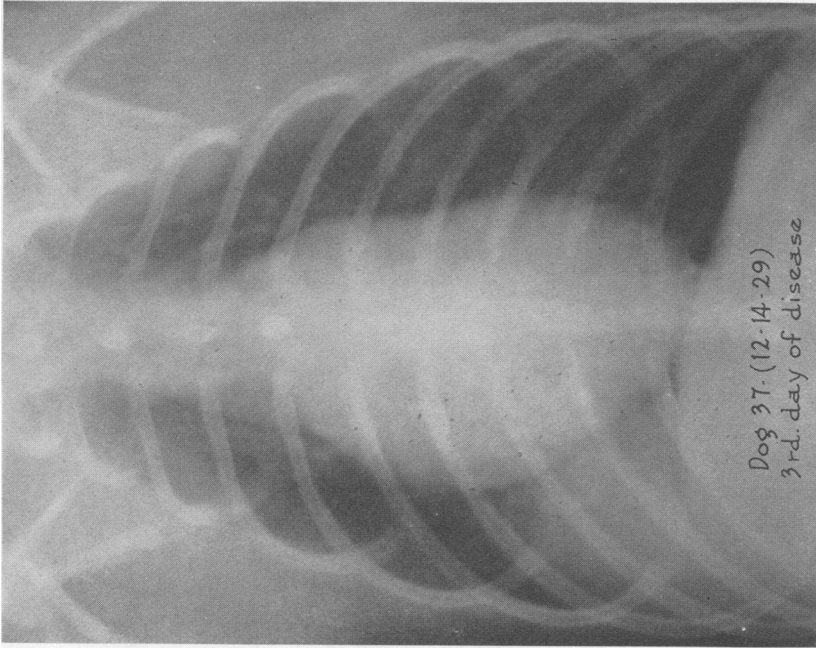


FIG. 3. DOG 37. X-RAY TAKEN ON THE 3^D DAY OF DISEASE SHOWING LOBAR CONSOLIDATION OF THE ENTIRE RIGHT LOWER LOBE

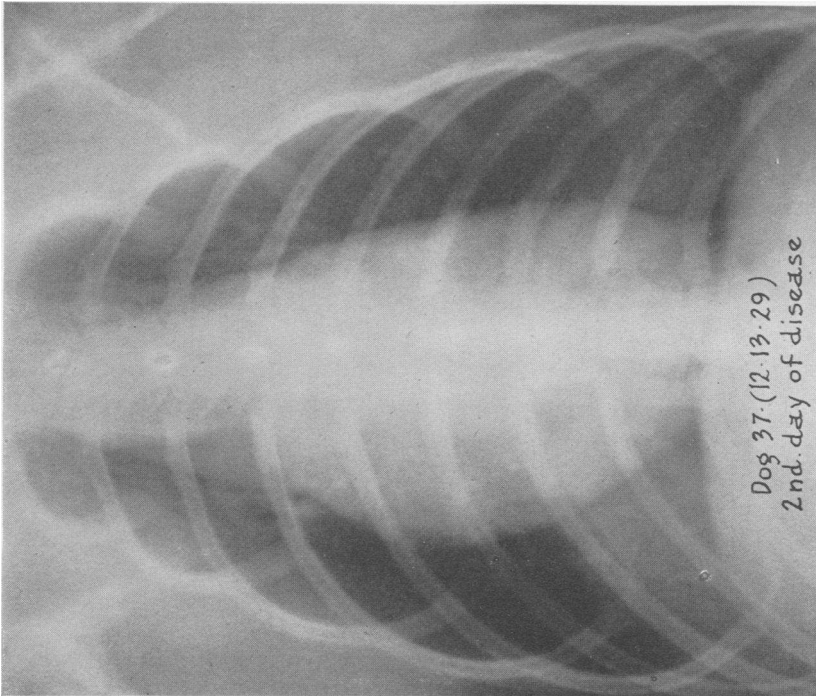


FIG. 2. DOG 37. X-RAY TAKEN ON THE 2^D DAY OF DISEASE SHOWING LOBAR CONSOLIDATION OF AT LEAST TWO-THIRDS OF THE RIGHT LOWER LOBE.

Heart shadow displaced slightly to the right.

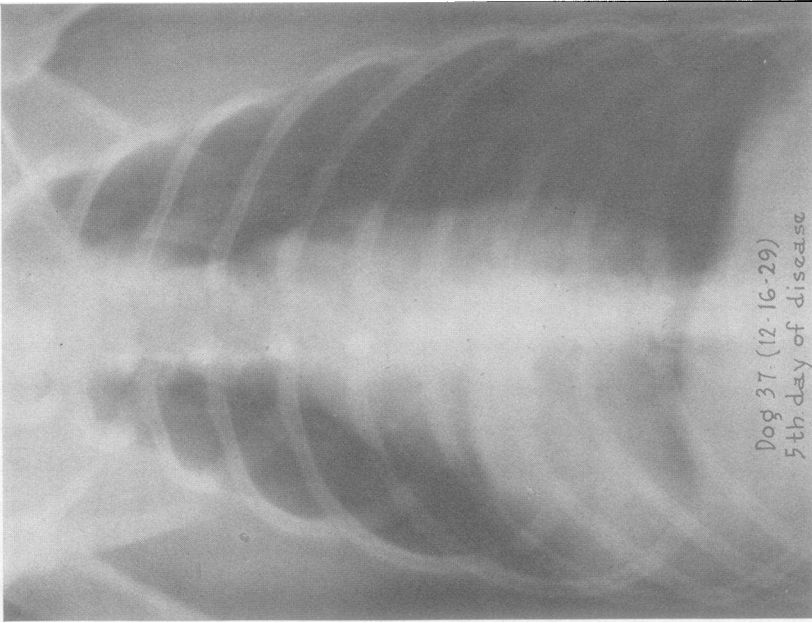


FIG. 4. DOG 37. X-RAY TAKEN ON THE 5TH DAY OF DISEASE SHOWING NO ESSENTIAL CHANGES. The apparent upward extension is probably due to rotation of the heart.

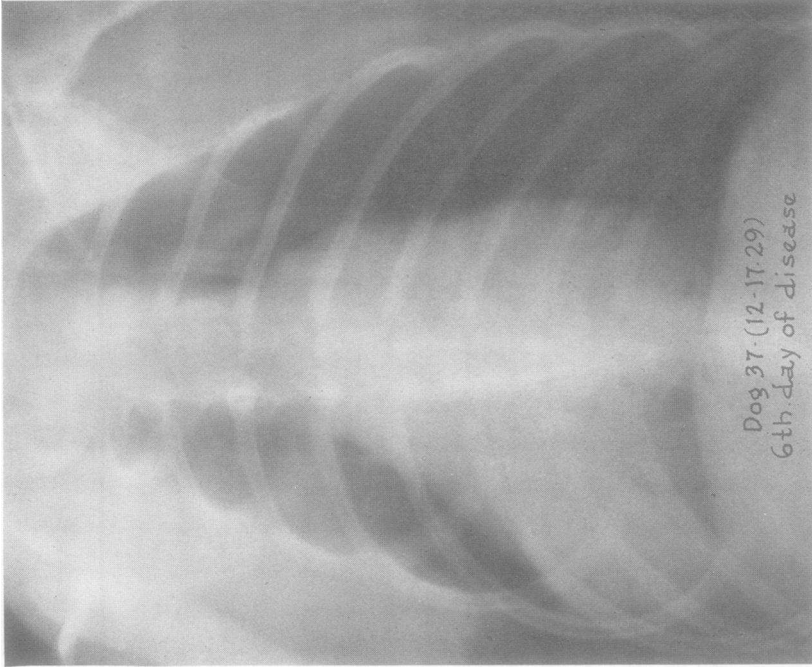


FIG. 5. DOG 37. X-RAY TAKEN ON THE 6TH DAY OF DISEASE SHOWING NO FURTHER CHANGE

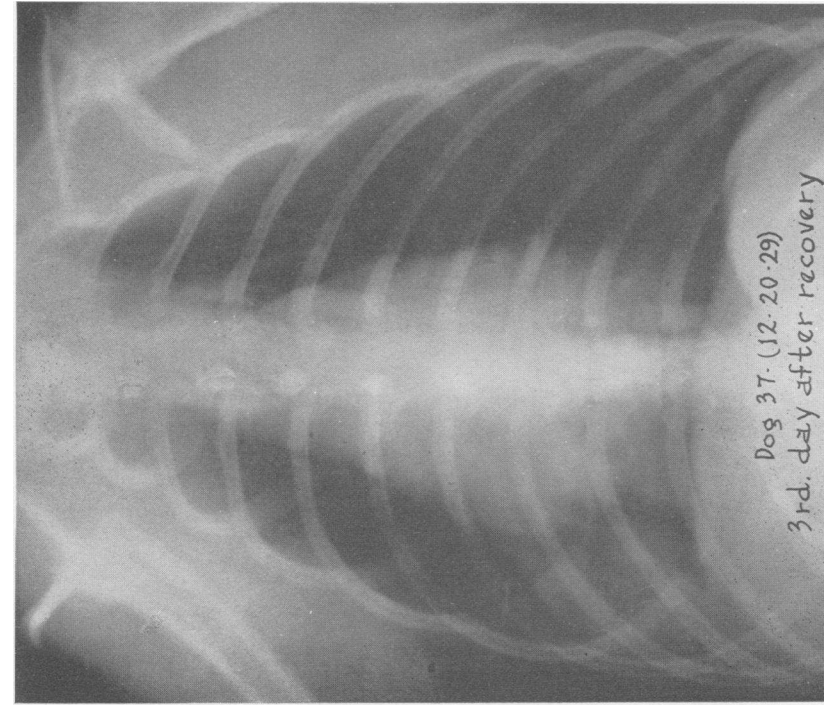


FIG. 6. DOG 37. X-RAY TAKEN ON THE 3D DAY AFTER RECOVERY SHOWING BEGINNING OF THE LESION
Heart shadow displaced further toward right.

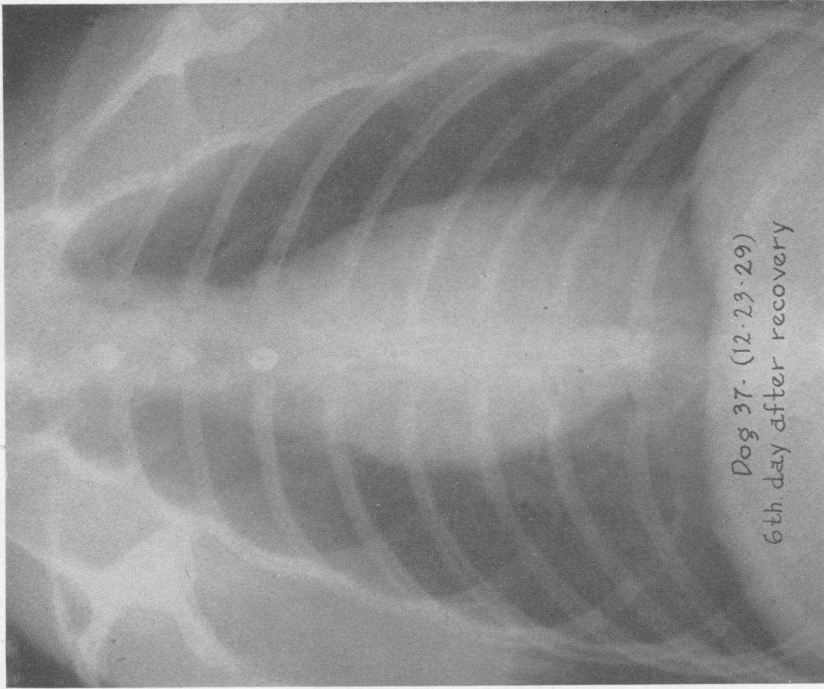


FIG. 7. DOG 37. X-RAY TAKEN 6 DAYS AFTER RECOVERY SHOWING ALMOST COMPLETE DISAPPEARANCE OF THE LESION AND THE HEART IN APPROXIMATELY ITS NORMAL POSITION.

Dog 54. Weight 6.5 kgm. (Chart 2). On March 12th, 1930, the dog was prepared with morphine and cocaine and 0.1 cc. of a culture of pneumococcus Type II, suspended in 5 per cent starch, was injected into the right lower lobe. The following morning the dog was still drowsy from the effects of the morphine

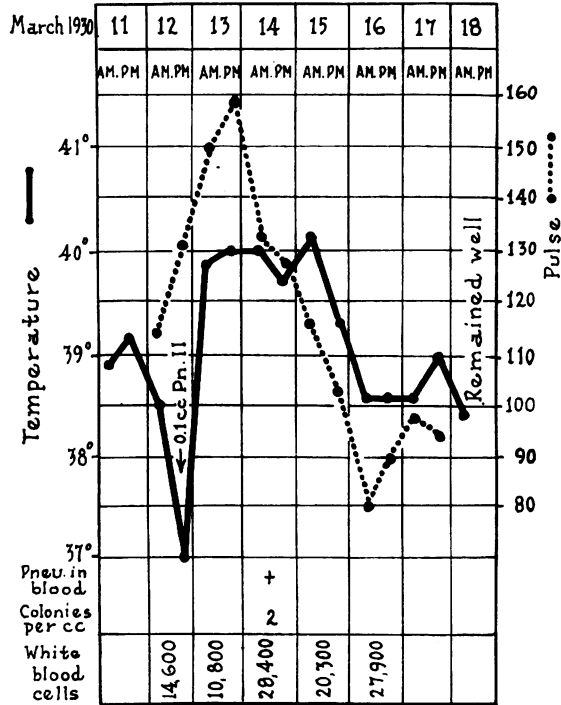


CHART 2. DOG 54. EXPERIMENTAL LOBAR PNEUMONIA FOLLOWING THE INTRABRONCHIAL INJECTION OF 0.1 CC. BROTH CULTURE OF PNEUMOCOCCUS TYPE II SUSPENDED IN STARCH.

and appeared sick. Examination of the chest showed dulness and bronchial breathing over the lower half of the right side. By the third day, March 14th, the dog appeared sicker. Physical signs unchanged, but the x-ray (Fig. 8) showed consolidation of the right lower lobe, and the lower part of the left upper lobe. Blood culture showed two colonies per 1 cc. of blood. On the morning of the fourth day the dog was definitely more toxic, lying on his side, with labored respirations and frequent cough. Physical examination revealed intense bronchial breathing over right lower and left upper chest. Lung puncture into right lower lobe at this time revealed a pure culture of pneumococci. On the afternoon of the same day the animal appeared much better. He got up promptly and wagged his tail when one of the authors entered the room. The next morning, i.e., the fifth day, his temperature was normal and he appeared lively, although a little weak. X-ray (Fig. 9) showed consolidation of the left upper, and a beginning clearing of the right lower lobe. The dog lost 0.5 kgm. of weight. The physical signs of consolidation persisted for some days after the disappearance of fever. On the 20th, i.e., four days later, breathing had returned to practically normal, in the left upper lung but bronchial breath sounds were still heard in a small area of the right lower lobe.

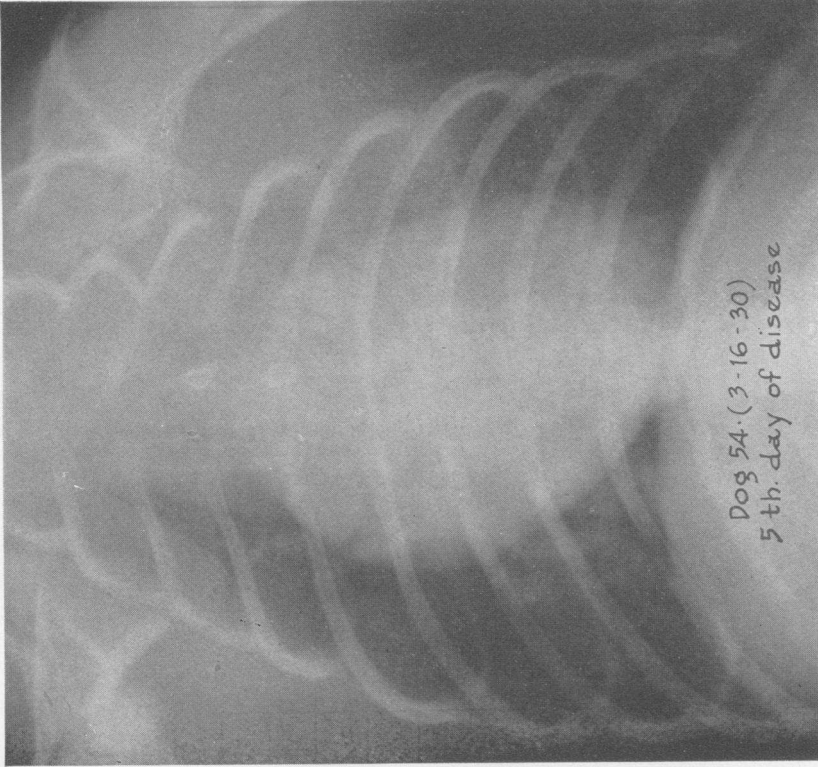


FIG. 9. DOG 54. X-RAY TAKEN ON THE 5TH DAY OF DISEASE SHOWING CONSOLIDATION OF THE ENTIRE LEFT UPPER LOBE AND CLEARING OF THE ORIGINAL LESION IN THE RIGHT LOWER LOBE.

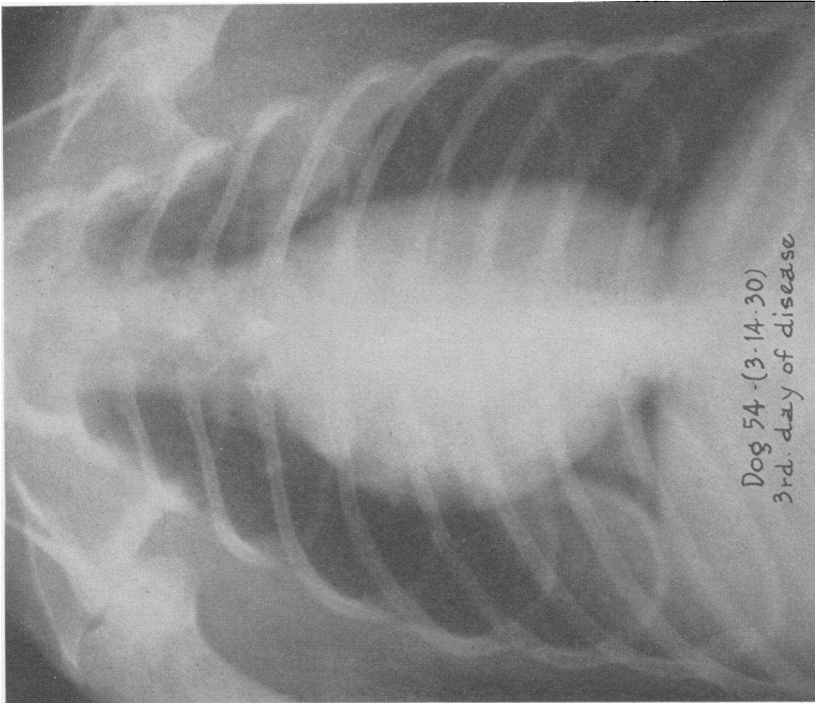


FIG. 8. DOG 54. X-RAY TAKEN ON THE 3D DAY OF DISEASE SHOWING CONSOLIDATION OF THE RIGHT LOWER AND PART OF THE LEFT UPPER LOBES.

The disease in this dog, produced by pneumococcus Type II, while brief, was very stormy and a degree of prostration was reached which in other instances usually indicated a fatal termination. Yet there occurred a sudden amelioration of symptoms and signs of much the same character as that seen in the crisis of the disease in man. This lesion showed an early spread to the opposite side of the chest, but remained localized, as evidenced by the very slight degree of blood invasion at the height of the disease. The well marked rise in white count which occurred in this case undoubtedly bears an important relationship to the effectiveness of the localization of the pneumococci.

Dog 24B. Male, weight 13.6 kgm. (Chart 3). On January 26th, 1931, following preparation with morphine and cocaine, 0.02 cc. pneumococcus Type I suspended in 5 per cent starch was injected into the right lower lobe.

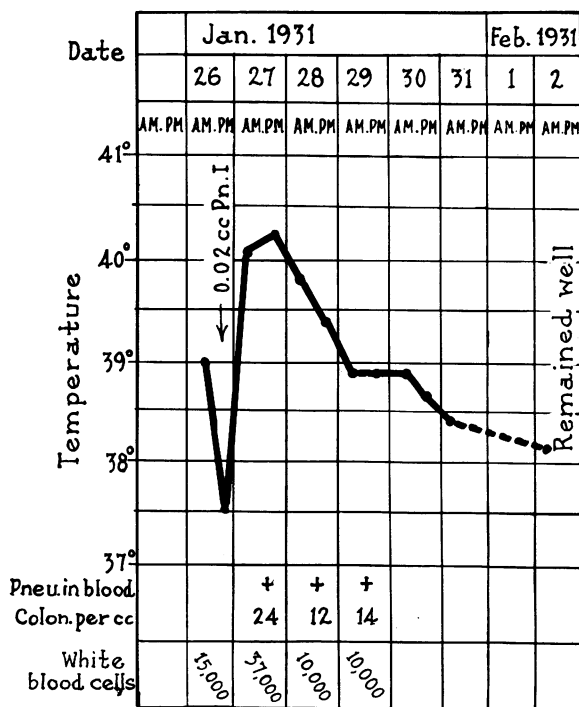


CHART 3. DOG 24B. EXPERIMENTAL LOBAR PNEUMONIA FOLLOWING THE INTRATRACHEAL INJECTION OF 0.02 CC. BROTH CULTURE OF PNEUMOCOCCUS TYPE I SUSPENDED IN STARCH.

The next morning the temperature was 40.1° C. and the dog began to cough. X-ray (Fig. 10) showed consolidation of the right lower and a part of the middle lobes. Blood culture revealed 24 colonies of pneumococci per cc. and the white count was 37,000. The dog did not appear particularly ill. On the 28th the temperature began to fall, but cough persisted as did blood invasion.

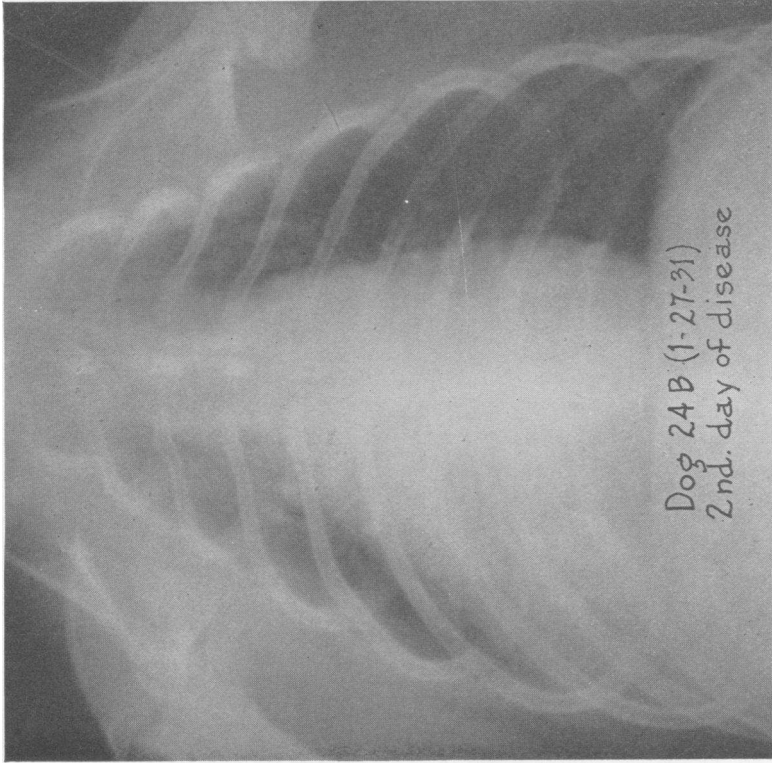


FIG. 10. Dog 24B. X-RAY TAKEN ON THE 2d DAY OF DISEASE SHOWING CONSOLIDATION OF THE RIGHT LOWER AND AT LEAST A PART OF THE MIDDLE LOBES.

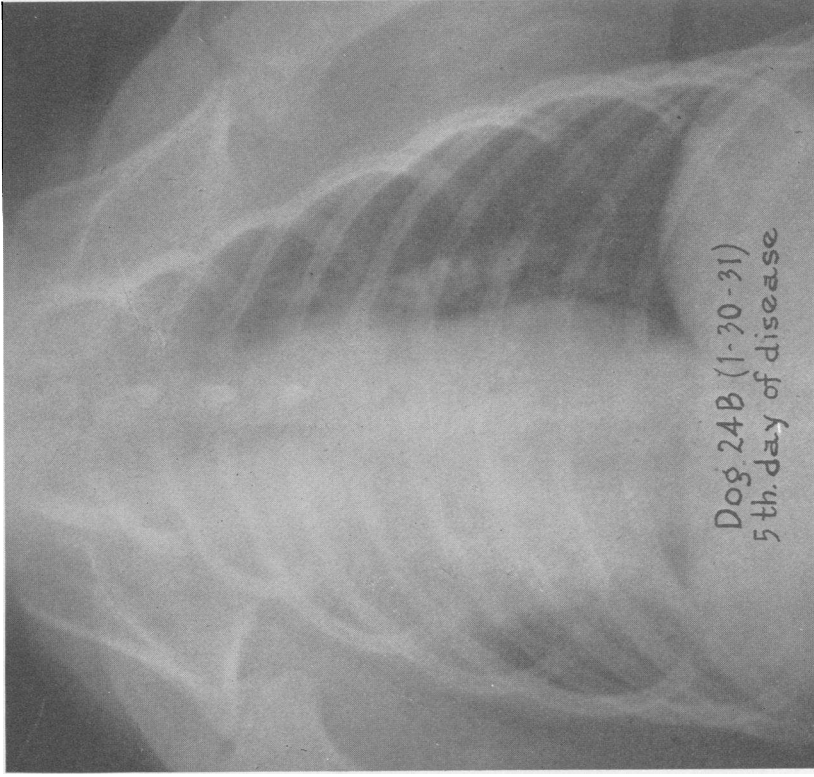


FIG. 11. Dog 24B. X-RAY TAKEN ON THE 5th DAY OF DISEASE SHOWING COMPLETE CONSOLIDATION OF THE RIGHT UPPER AND MIDDLE LOBES AND BEGINNING CLEARING OF THE LESION IN THE RIGHT LOWER LOBE.

The heart shadow is displaced toward the right side.

On the 29th respirations were loud and labored. Lung puncture yielded a pure culture of pneumococcus. An x-ray taken on the 29th showed marked spread of the lesion, which now involved the whole right lung. Slight clearing of the initial lesion was evident on the 30th (Fig. 11). The exact time of recovery is not clear, but it probably took place between the fourth and fifth day of the disease, as the respirations had become normal by the 30th. The dog lost 1.4 kgm. in weight during this time.

It is noteworthy that a dosage of 0.02 cc. culture suspended in starch produced in this animal, a disease of greater severity than that which occurred in dog 37 following injection of 0.5 cc. suspended in gelatin. In dog 24B there was a persistent bacteremia and the process spread to other lobes, while in dog 37 the lesion was confined to the initially infected lobe.

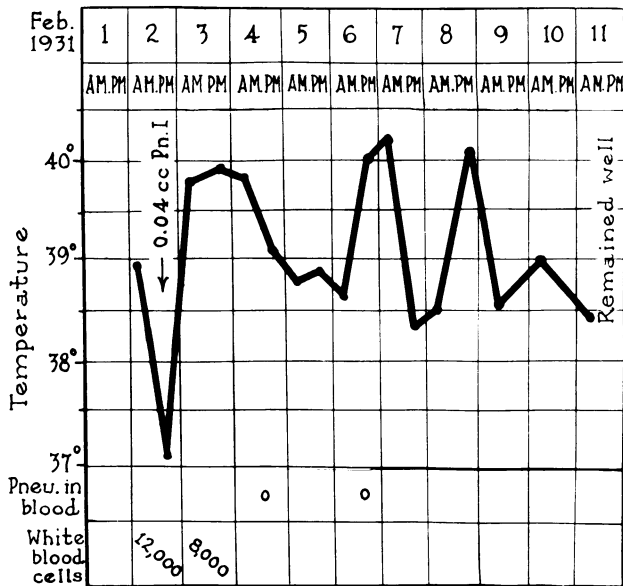


CHART 4. DOG 22B. EXPERIMENTAL LOBAR PNEUMONIA FOLLOWING THE INTRATRACHEAL INJECTION OF 0.04 CC. BROTH CULTURE OF PNEUMOCOCCUS TYPE I SUSPENDED IN STARCH.

A disease of even longer duration was produced with equivalent or smaller doses of Type I pneumococci when suspended in starch (see Table I). The following protocol is illustrative.

Dog 22B. Male, weight 7.4 kgm. (Chart 4). On February 2d, 1931, the dog was prepared with morphine and cocaine and 0.04 cc. culture pneumococcus Type I suspended in starch was injected into the right lower lobe. The usual depression in temperature was noted six hours after injection, but by the following morning it was 39.8° C. The disease ran a somewhat irregular febrile course lasting seven days. A series of x-rays (Fig. 12 to 15) showed

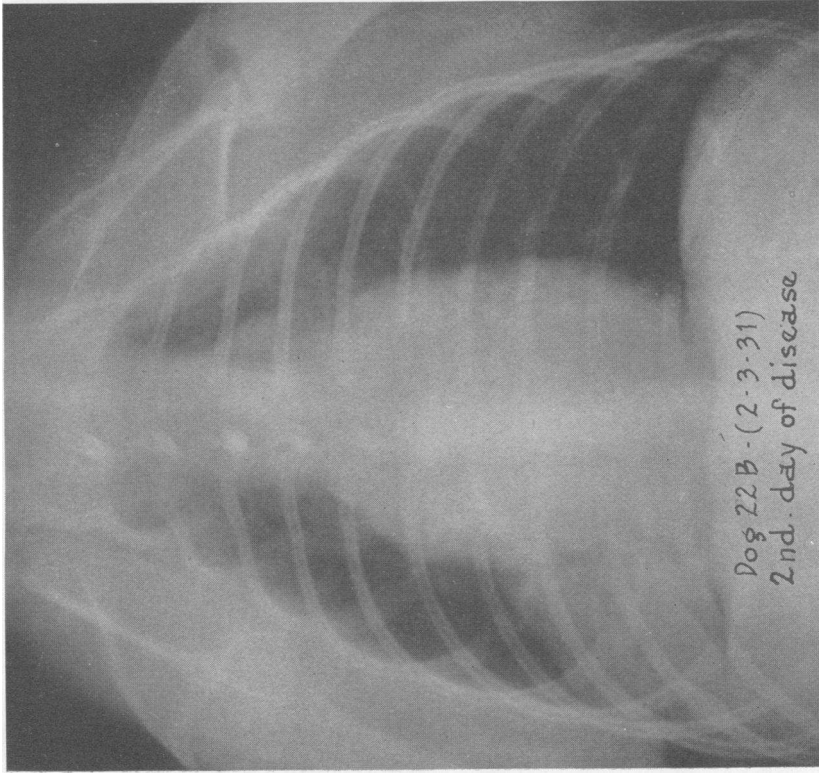


FIG. 12. DOG 22B. X-RAY TAKEN ON THE 2D DAY OF THE DISEASE
SHOWING CONSOLIDATION OF THE RIGHT LOWER LOBE

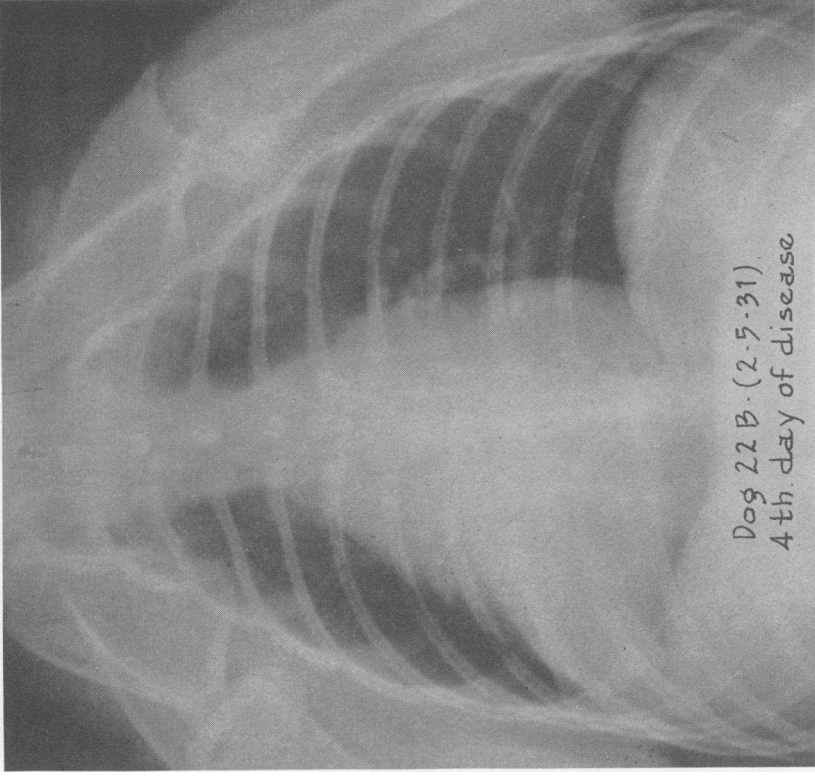


FIG. 13. DOG 22B. X-RAY TAKEN ON THE 4TH DAY OF DISEASE
SHOWING NO ESSENTIAL CHANGE IN THE PULMONARY LESION

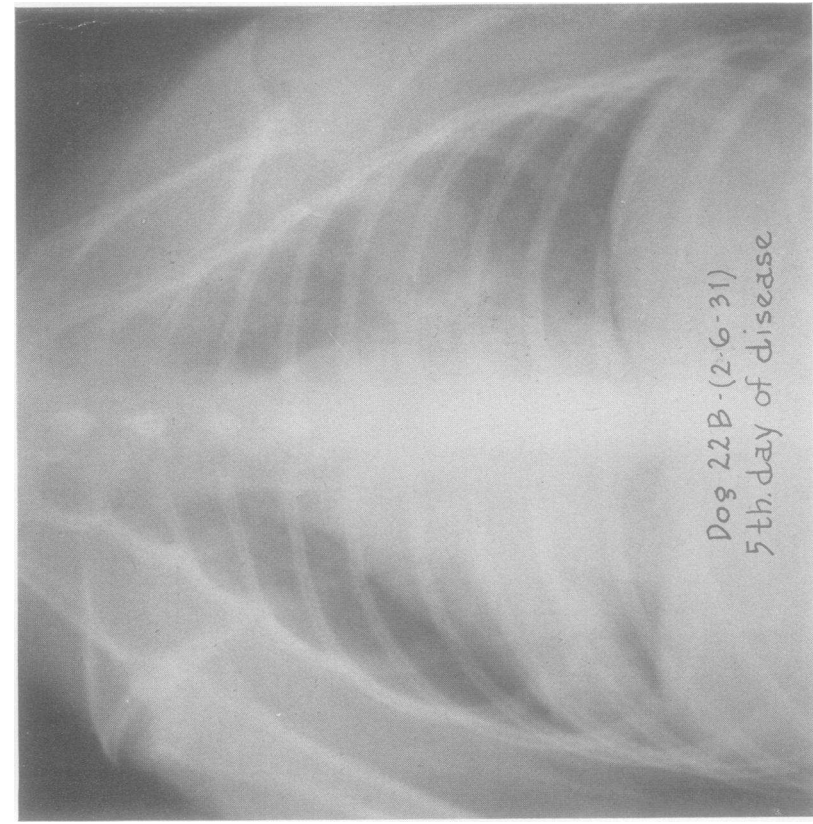


FIG. 14. DOG 22B. X-RAY TAKEN ON THE 5TH DAY OF DISEASE SHOWING A SPREAD OF THE PROCESS TO THE LOWER PART OF THE LEFT UPPER LOBE.

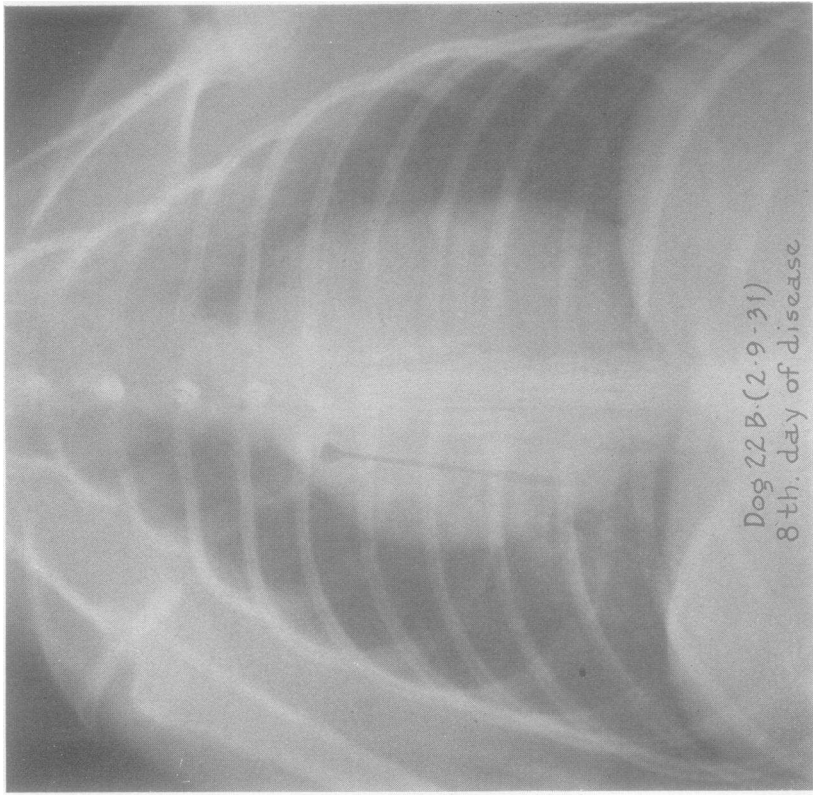


FIG. 15. DOG 22B. X-RAY TAKEN ON THE 8TH DAY OF THE DISEASE (DAY OF RECOVERY) SHOWING CONSOLIDATION OF THE UPPER PART OF THE LEFT UPPER LOBE, CLEARING OF THE LESIONS IN THE RIGHT LOWER LOBE AND THE LOWER PART OF THE LEFT UPPER LOBE.

well marked consolidation of the right lower lobe at the end of twenty-four hours. The lesion remained stationary until the fifth day of the disease, when the process spread to the left middle lobe, as seen in the x-ray taken on February 6th. On this day the dog's temperature rose sharply. A puncture of the mid portion of the left lung on February 7th yielded no growth. No further x-rays were taken until the day of recovery, when an extensive lesion was found in the left upper lobe. This further spread may have occurred on the sixth day coincident with the final peak in the temperature curve. At this time, i.e., the day of recovery, the original process in the right lower lobe had shown marked clearing. The dog was at no time more than moderately ill.

The character of the febrile curve in the longer infections varied considerably. Some were irregular as in dog 22B. Others were much more sustained, as exhibited by the disease course in dog 46, whose protocol follows.

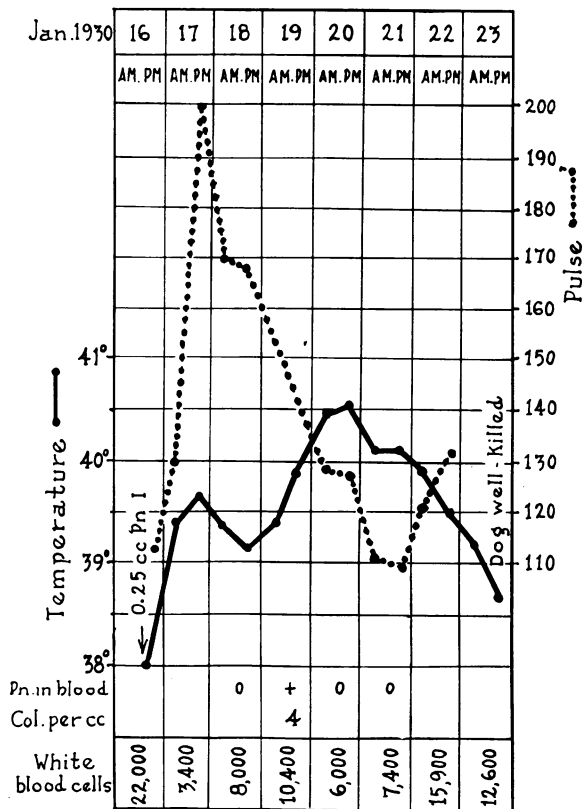


CHART 5. DOG 46. EXPERIMENTAL LOBAR PNEUMONIA FOLLOWING THE INTRATRACHEAL INJECTION OF 0.25 CC. BROTH CULTURE OF PNEUMOCOCCUS TYPE I SUSPENDED IN 20 PER CENT GELATIN.

Dog 46. Male, weight 18 kgm. (Chart 5). On January 16th, 1930, the dog was prepared with morphine and cocaine and 0.25 cc. culture pneumo-

coccus Type I suspended in gelatin was injected presumably into the right lower lobe. The day following there was dulness and bronchial breathing over the mid portion of the right chest. The x-ray showed a definite lesion in the right middle lobe and some haziness over the region of the lower lobe. The dog appeared slightly ill, coughed and breathed rather more rapidly than normal. X-ray taken on January 19th revealed even consolidation of the right lower and middle lobes. On January 21st, i.e., the sixth day of the disease, the x-ray showed an extension of the process to the left upper lobe. Bronchial breathing was confined to the right side. The dog was only moderately ill, not coughing, and breathing more easily. His condition did not change until January 23d when the temperature reached normal, physical signs of consolidation had practically gone, the x-ray showed a clearing lesion, and the dog regained his usual liveliness. He was sacrificed for pathological study. Autopsy showed a resolving lobar pneumonia of the right lower and middle and left upper lobes.

As will be noted in Table I, quite severe and prolonged infection was produced with doses as small as 0.0001 cc. or 0.00001 cc. of culture.

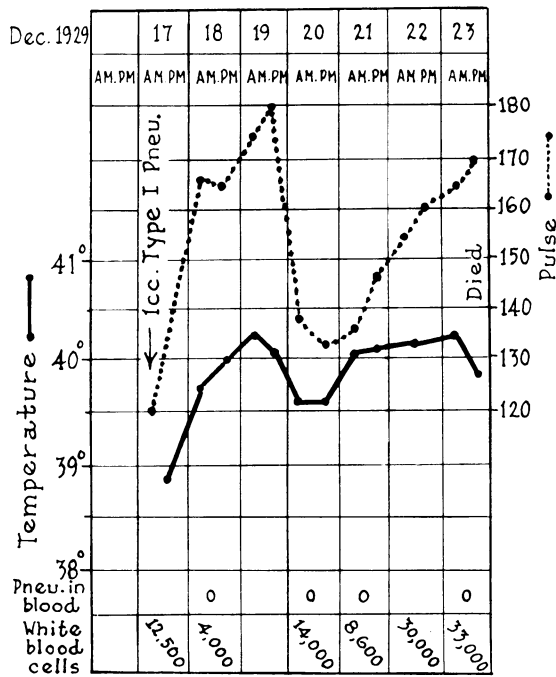


CHART 6. DOG 40. EXPERIMENTAL LOBAR PNEUMONIA FOLLOWING THE INTRATRACHEAL INJECTION OF 1 CC. BROTH CULTURE OF PNEUMOCOCCUS TYPE I SUSPENDED IN 20 PER CENT GELATIN.

Dogs showing localization of the lesion but with fatal termination

Dog 40. Weight 20.8 kgm. (Chart 6). On December 17th, 1929, the dog was prepared only with morphine, 15 mgm. per kilo. Received into the right lower lobe 1 cc. of pneumococcus Type I culture suspended in gelatin. The

following morning the dog did not appear particularly ill, but slight exertion produced marked dyspnea. On physical examination there was dulness to percussion over the lower right chest and in the center of this area was heard faint bronchial breathing. X-ray showed a lesion of the right lower lobe.

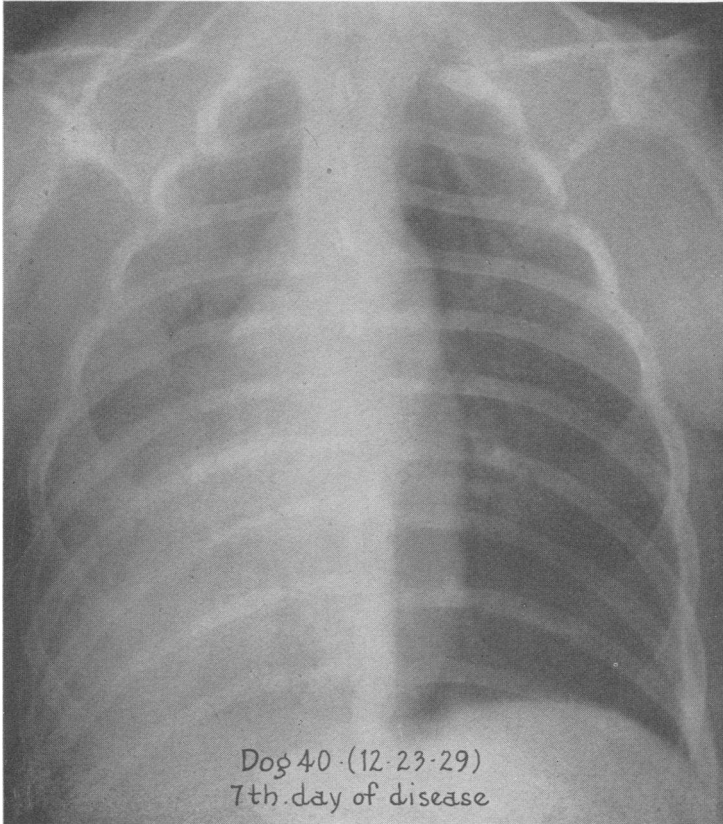


FIG. 16. DOG 40. X-RAY TAKEN ON THE DAY OF DEATH, 7TH DAY OF DISEASE, SHOWING CONSOLIDATION OF ALL THREE LOBES ON THE RIGHT SIDE EXCEPT THE MEDIAL PORTION OF THE RIGHT UPPER.

By December 20th, the fourth day of disease, the dog appeared quite ill. Physical signs remained unchanged. On the fifth day the general condition of the dog had changed little. He had slight dyspnea at rest, which became marked on exertion. Bronchial breathing and dulness were still present over lower half of right chest. X-ray indicated a probable extension to the right middle lobe. No further change was noted until the seventh day, when the dog became distinctly weaker and showed marked dyspnea on slight exertion. There was dulness to percussion and bronchial breathing over the whole right chest, the latter most marked at the base. X-ray (Fig. 16) corroborated the physical signs of complete involvement of the right lung. The extension must have taken place during the preceding twenty-four hours as the x-ray on the sixth day showed the upper right chest clear. The dog died early on the

morning of the eighth day. Autopsy revealed consolidation of the three right lobes. The lower lobe showed red to gray hepatization, the middle and upper lobes red hepatization. The left lung was clear. Pneumococci were present in large numbers in the affected lobes. X-ray of the excised lungs

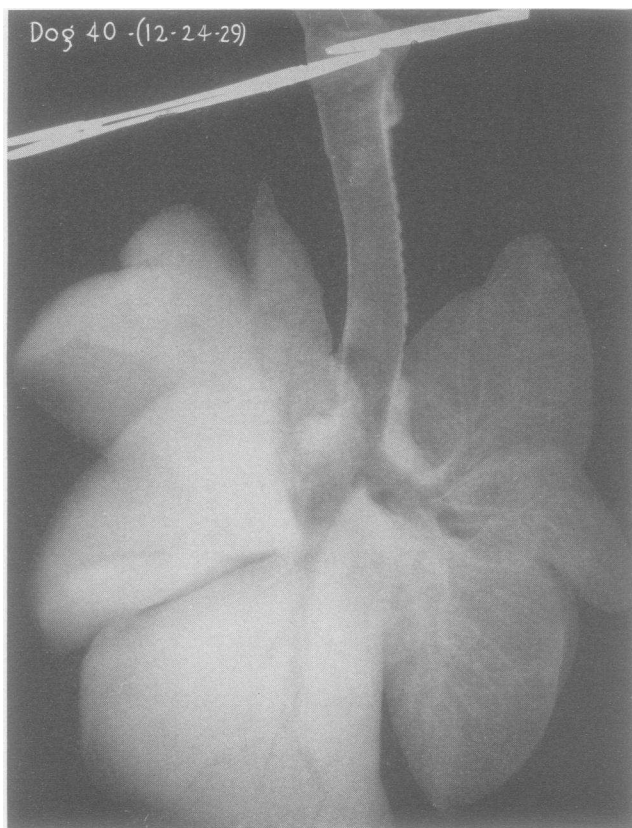


FIG. 17. DOG 40. X-RAY OF THE EXCISED LUNGS, TAKEN IMMEDIATELY AFTER DEATH, SHOWING AN EVEN DENSITY OF ALL THREE RIGHT LOBES EXCEPT THE MEDIAL PORTION OF THE RIGHT UPPER WHICH IS AIR CONTAINING ALTHOUGH PARTLY INFILTRATED.

The left lung is normal.

(Fig. 17) showed an even density of the right lung field except for a small portion of the upper lobe. No fluid in the pleural cavities nor other complications were found.

The disease in this animal is of particular interest in its relation to lobar pneumonia as seen in man. Of chief note is the fact that the blood remained sterile throughout the seven days of the disease. There was a terminal spread of the process accompanied by a marked increase in the number of leukocytes. The occurrence of death in the absence of a gen-

eralized infection and with adequate aerating space in the lungs suggests that exitus was due to toxemia.

Other dogs showing lobar consolidation have passed through a shorter course without blood invasion.

Dog 31. Weight 15 kgm. (Chart 7). On November 19th, 1929, the dog was given 40 mgm. of amytal per kilo of body weight and 2 cc. of Type I pneumococcus culture suspended in 20 per cent gelatin was injected into the right lower lobe. An x-ray was taken of the catheter in place just before the

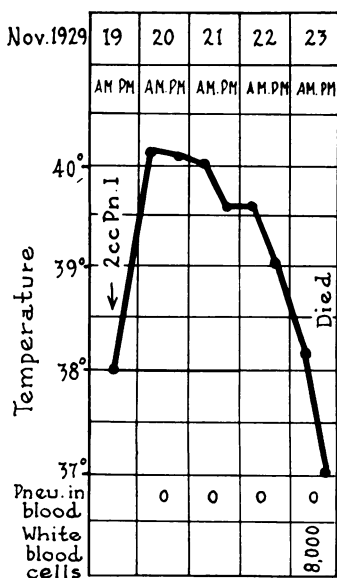


CHART 7. DOG 31. EXPERIMENTAL LOBAR PNEUMONIA FOLLOWING THE INTRATRACHEAL INJECTION OF 2 CC. BROTH CULTURE OF PNEUMOCOCCUS TYPE I SUSPENDED IN 20 PER CENT GELATIN.

injection was made (Fig. 18). By the next morning the dog was still slightly drowsy. He was coughing and apparently trying to bring up sputum. Respiration slightly increased. On physical examination there was a small area about 5 cm. in diameter in the middle right chest where bronchial breathing was heard. X-ray (Fig. 19) showed a cloudiness of the right lower lobe and questionably of the left upper. On November 12th, the third day of the disease, the dog appeared quite ill and was breathing rapidly. Loud bronchial breathing was heard over the lower half of right chest, and also over a smaller area of the lower middle left chest. By the fourth day the condition had changed little except for the occurrence of moist râles in the right lower chest. X-ray showed beginning involvement of the left mid lung field. Respirations were still rapid. On the fifth day the dog was obviously weaker. Respirations 98 per minute and mucous membranes cyanotic. White count 8000. Physical signs showed bronchial breathing in areas before noted but less harsh and accompanied by many medium moist râles. In the x-ray, opacity of more than half of both lung fields was seen. The dog died that night.

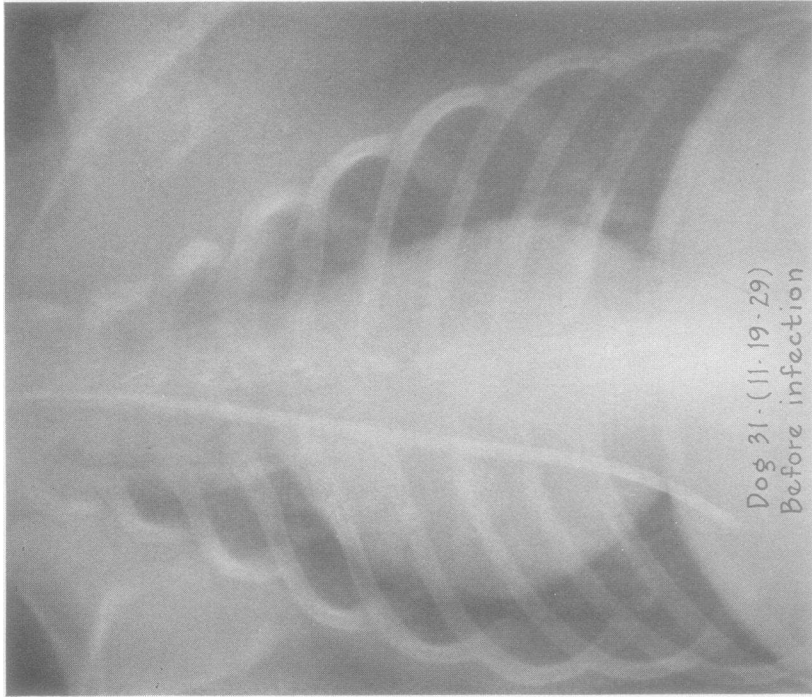


FIG. 18. DOG 31. X-RAY TAKEN WITH THE RADIOPAQUE IN PLACE JUST BEFORE THE INFECTING DOSE WAS GIVEN. The tip of the catheter is near the lower periphery of the lobe.

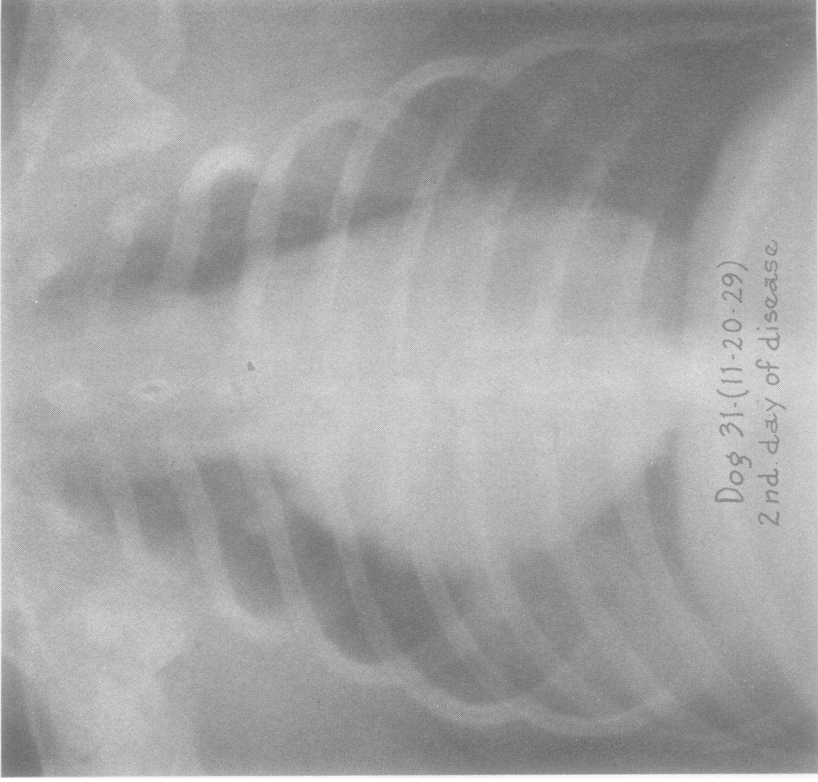


FIG. 19. DOG 31. X-RAY TAKEN ON THE 2D DAY OF DISEASE SHOWING CONSOLIDATION OF THE RIGHT LOWER LOBE AND A SMALL SHADOW IN THE LEFT MIDDLE LUNG FIELD.

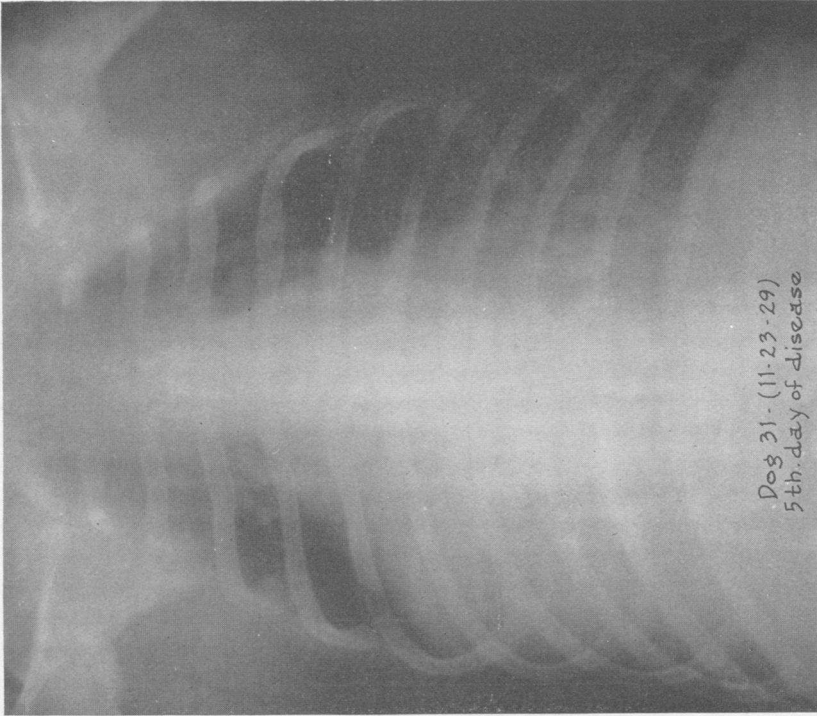


FIG. 21. DOG 31. X-RAY TAKEN ON THE 5TH DAY OF DISEASE SHOWING CONSOLIDATION OF THE RIGHT LOWER, MIDDLE, AND LEFT LOWER LOBES

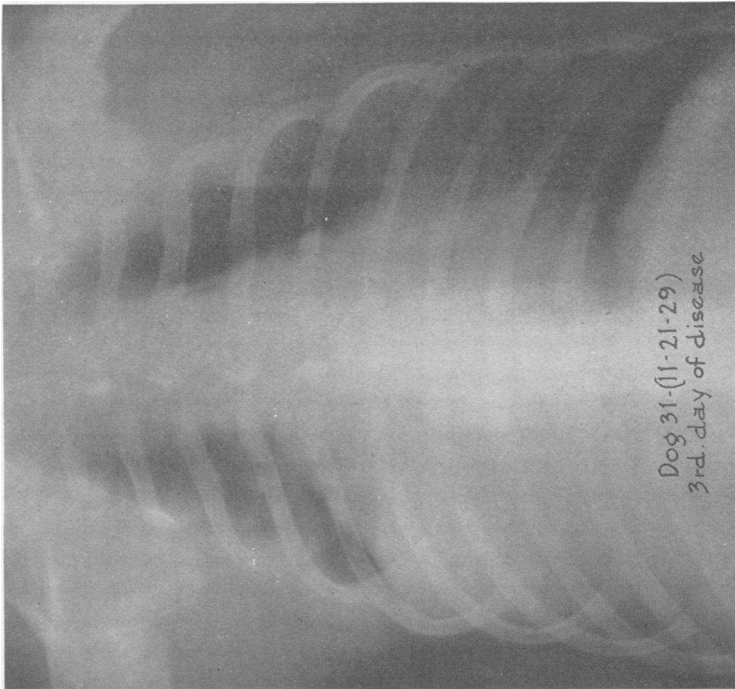


FIG. 20. DOG 31. X-RAY TAKEN ON THE 3D DAY OF DISEASE SHOWING EXTENSION OF THE PROCESS TO THE RIGHT MIDDLE LOBE AND BEGINNING INVOLVEMENT OF THE LEFT LOWER.

TABLE I †
Experimental pneumococcus pneumonia in the dog

Key to abbreviations

R.L.	= right lower lobe.	P.C.	= post cardiac lobe.
R.M.	= right middle lobe.	D.	= died.
R.U.	= right upper lobe.	K.	= killed.
L.L.	= left lower lobe.	Morib.	= moribund.
L.U.	= left upper lobe.		

On account of the variation in the occurrence of a clearly defined left middle lobe, this area has been included in the upper lobe.

Dog number	Weight kgm.	Date of inoculation	Type pneumococcus	Amount of culture injected cc.	Extent of lesion by x-ray	Blood invasion	Outcome	Autopsy and additional data
36D	6.8	February 22, 1932	I	0.000,001	None	0	No disease	No autopsy
38D	8.0	February 22, 1932	I	0.000,01	R.L.	0	Recovered 5th day	No autopsy
34D	11.0	January 25, 1932	I	0.000,1	R.L., R.M., R.U.	+	Recovered 7th day	No autopsy. Blood culture on January 28 = 200 colonies per cc. Lung puncture January 31 = pure culture pneumococcus
31D	9.4	January 25, 1932	I	0.001	R.L., R.M., R.U.	0	Recovered 9th day	No autopsy. Lung puncture January 31 = pure culture pneumococcus
24B	13.6	January 26, 1931	I	0.02	R.L., R.M., R.U.	+	Recovered 5th day	No autopsy. Blood culture 2d day showed gram negative bacillus as well as pneumococcus
35B	15.2	April 6, 1931	I	0.02	R.L.	0	Recovered 3d day	No autopsy
32B	7.4	April 6, 1931	I	0.02	R.L.	0	Recovered 3 d d a y . K.	Lobar pneumonia R.L. Resolution beginning
38B	11.8	April 13, 1931	I	0.02	R.L.	0	Recovered 4th day	No autopsy
3A	10.0	March 31, 1930	I	0.02	L.L., L.U.	-	Recovered 3d day	No autopsy

TABLE I—(Continued)

Dog number	Weight kgm.	Date of inoculation	Type pneumococcus	Amount of culture injected cc.	Extent of lesion by x-ray	Blood invasion	Outcome	Autopsy and additional data
23B	7.0	February 2, 1931	I	0.03	R.L., R.M.	+	Recovered 4th day	No autopsy
22B	7.4	February 2, 1931	I	0.04	R.L., L.U.	0	Recovered 8th day	No autopsy
49B	10.5	June 1, 1931	I	0.04	R.L.	0	Recovered 4th day	No autopsy
50B	10.0	June 1, 1931	I	0.04	R.L.	0	Recovered 3 d day.	Lobar pneumonia R.L., red to gray hepatization. R.M. atelectatic (mucus plug in main bronchus). Acute fibrinous pleuritis
46B	9.8	May 25, 1931	I	0.04	R.L.	+	K. 5th day *	Irregular diffuse pneumonia R.L. Purulent pericarditis. Bacteremia extreme
45B	7.7	June 1, 1931	I	0.04	R.L., L.U., (on 2d day)	+	D. 4th day	Irregular diffuse pneumonia greater part both lungs. Bacteriology showed mixed flora. Emphyema right pleural cavity
20D	6.3	November 30, 1931	I	0.04	R.L.	0	Recovered 5th day	No autopsy
20B	11.9	February 2, 1931	I	0.05	R.L.	0	Recovered 3d day	No autopsy
15B	14.6	January 12, 1931	I	0.05	R.L., R.M., R.U.	0	Recovered 5th day	No autopsy
26B	7.8	February 24, 1931	I	0.05	R.L., R.M., R.U.	0	Recovered 4th day	No autopsy
30B	9.7	April 2, 1931	I	0.05		+	D. 4th day *	Irregular diffuse pneumonia. Bacteremia extreme
22A	10.6	May 16, 1930	I	0.05	R.L., R.M., R.U.	+	D. 6th day	Irregular diffuse pneumonia. R.L. and R.M. stage of resolution. Left lung collapsed. Emphyema both pleural cavities. Bacteremia marked. 360 colonies per cc.

TABLE I—(Continued)

Dog number	Weight <i>kgm.</i>	Date of inoculation	Type pneumococcus	Amount of culture injected <i>cc.</i>	Extent of lesion by x-ray	Blood invasion	Outcome	Autopsy and additional data
2C	9.5	June 15, 1931	I	0.05	R.L.	+	Recovered 4 t h day. K.	Lobar pneumonia R.L., R.M., P.C. stage of resolution. Acute fibrinous pleuritis
19D	13.9	November 23, 1931	I	0.05		+	D. 24 hrs. †	Coalescent lobular pneumonia. Complete consolidation R.L., patchy consolidation. R.M. and R.U. Acute fibrinous pleuritis. Marked bacteremia (300 colonies per cc.) No autopsy
4C	9.5	June 15, 1931	I	0.05	R.L.	0	Recovered 3d day	Coalescent lobular pneumonia R.L., R.M., R.U.
28B	7.8	March 23, 1931	I	0.06	R.L. (2d day)	+	Died 3d day *	No autopsy
10D	10.6	November 2, 1931	I	0.05	R.L.	0	Recovered 7th day	No autopsy
27D	11.8	December 29, 1931	I	0.06		0	Recovered 3d day	No autopsy
4A	10.0	March 31, 1930	I	0.1	R.L., L.U.	0	Recovered 6 t h day. K. 8th day	Lobar pneumonia R.L., R.M., R.U., L.U. stage of resolution. Acute fibrinous pleuritis
19A	11.0	May 8, 1930	I	0.1	R.L., R.M.	+	Died 7 t h day	Irregular diffuse pneumonia R.L., R.M., R.U., L.L. and L.U. Empyema both pleural cavities. Purulent pericarditis. Bacteremia extreme
16B	13.4	January 12, 1930	I	0.1	R.L., R.M.	+	Died 6 t h day	Irregular diffuse pneumonia. R.L., R.M., P.C. Empyema both pleural cavities. Bacteriology showed mixed flora. Bacteremia = marked 300 colonies per cc.
8B	10.2	December 5, 1930	I	0.1	R.L. (3d day)	+	K. 5th day (Morib.)	Irregular diffuse pneumonia. Empyema right pleural cavity. Bacteremia extreme
39C	19.0	October 22, 1931	I	0.1	R.L., R.M.	+	D. 4th day	Lobar pneumonia R.L., R.M., R.U., P.C. Red hepatization. Acute fibrinous pleuritis

TABLE I—(Continued)

Dog number	Weight <i>kgm.</i>	Date of inoculation	Type pneumococcus	Amount of culture injected <i>cc.</i>	Extent of lesion by x-ray	Blood invasion	Outcome	Autopsy and additional data
14B	8.4	January 6, 1931	I	0.25	Diffuse—over both lungs	+	D. 4th day	Coalescent lobular pneumonia R.L., R.M., R.U., L.U. Empyema right pleural cavity. Bacteremia marked (300 colonies per cc.
4D	13.6	October 22, 1931	I	0.25	R.L., R.M., R.U.	+	K. 4th day, (Morib.)	Irregular diffuse pneumonia. R.L., R.M., R.U., P.C. Bacteremia extreme
5B	12.8	November 26, 1930	I	0.25	R.L., R.M., R.U.	+	K. 3d day	Lobar pneumonia R.L., R.M., R.U., P.C. red hepatization
60	8.0	March 21, 1930	I	0.5	No x-rays. No physical signs of consolidation	+	D. 6th day	No pneumonia. Empyema of right pleural cavity. Purulent pericarditis
41D	13.4	February 29, 1932	I	1.0	No x-rays	+	D. 30 hrs.	Lobular pneumonia L.L., L.U., R.L., R.U.
54	6.5	March 12, 1930	II	0.1	R.L., L.U.,	+	Recovered 5th day	No autopsy
15A	9.1	April 24, 1930	II	0.25	R.L.	-	Recovered 3d day	No autopsy
16A	12	May 2, 1930	II	0.25	R.L.	-	Recovered 3d day	No autopsy
14A	6.6	April 24, 1930	II	0.25	R.L., L.U.	0	Died 3d day	Coalescent lobular pneumonia
56	11.6	March 19, 1930	II	0.25	R.L., R.M., R.U., (on 3d day)	0	Died 5 t h day	Lobar pneumonia R.L., R.M., R.U., P.C. Red to gray hepatization. L.L., L.U., engorgement and early red hepatization. Acute fibrinous pleuritis, on right
55	11.6	March 12, 1930	II	0.5	No x-ray. Physical signs of consolidation L.L.	-	Recovered* 3d day	No autopsy
53	15	March 5, 1930	II	0.5	R.M., R.U.	0	Recovered 6 t h day. K. 8th day	Lobar pneumonia R.M., R.U., P.C. stage resolution. Acute fibrinous pleuritis

* Unusually marked or prolonged depression of temperature following morphine.

† Very old dog.

‡ The table comprises only those animals infected with the starch suspension of pneumococci and anesthetized with morphine and cocaine.

Autopsy showed the pleural cavities free from fluid. The right lower, middle and upper lobes were of normal size and firmly consolidated, except for a small portion of the upper lobe near the hilum. On the left side the upper half of the lower lobe was consolidated, likewise the outer two-thirds of the upper lobe. The middle part of the lobe was clear. One-half of the post cardiac lobe showed consolidation. All the involved lobes were in a state of red hepatization. Culture of heart blood was sterile.

In spite of the large infecting dose of pneumococci and the extensive spread of the lesion the process remained strictly localized in the lungs as shown by the persistently sterile blood cultures. At autopsy, approximately three-fourths of the lung tissue was involved, which could account for the high respiratory rate and cyanosis.

Another dog (14A, Table I) died on the third day with a sterile blood culture. However, all the other animals dying within three to four days showed a bacteremia. In this respect dogs resemble cases of fulminating lobar pneumonia in man which are almost always characterized by blood invasion.

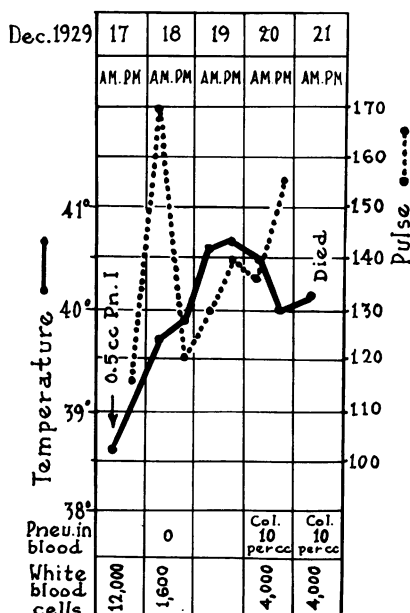


CHART 8. DOG 39. EXPERIMENTAL LOBAR PNEUMONIA FOLLOWING THE INTRATRACHEAL INJECTION OF 0.5 CC. BROTH CULTURE OF PNEUMOCOCCUS TYPE I SUSPENDED IN 20 PER CENT GELATIN.

Dog 39. Weight 14.6 kgm. (Chart 8). December 17th, 1929, the dog was prepared with morphine and ether. One-half cc. of a culture of Type I pneumococcus suspended in gelatin was injected into the right lower lobe. The following morning the dog did not appear particularly ill, but respiration was very rapid, 132 per minute. There was slight dullness to percussion over right

lower chest but no alteration in breath sounds. The x-ray showed cloudiness of the right lower lung field and a shadow in the tip of the left and upper lobe. By the third day the dog seemed moderately ill and the breathing was still rapid. X-ray showed the consolidated area to be of the same extent though denser than the day before. On the fourth day, December 20th, the entire right chest was dull to percussion and loud bronchial breathing was heard on the lower two-thirds of this area. By x-ray the lesion was seen to occupy about three-fourths of the right lung field, the upper one-fourth still clear. The lesion in the left upper lobe was of greater density and extent. By December 21st the dog was definitely worse. Breathing was not as rapid as before, but marked dyspnea appeared on slightest exertion. Physical signs were as before. There were no abnormal findings on the left side of the chest. However, x-ray showed clouding of almost the entire right chest, and of the upper three-fourths of the left chest. Density of the left side, however, was not as great as the right. The dog died at midnight of the fifth day.

Autopsy showed pleural cavities free from fluid. All the lobes of the right lung were evenly and firmly consolidated, of the consistency and color of liver, except for the posterior peripheral part of the right lower, which was a pinkish gray. A small part of the right upper lobe near the hilum contained air. The left upper lobe was similarly consolidated, and the left lower was firm over the greater part of the lobe. The only normal lobe was the left middle. The consolidated lobes appeared as large, or possibly larger than normal. (Lungs were used for perfusion.)

This animal showed a much more marked leukopenia than the three preceding ones with fatal termination, and while consolidation of the affected lobes was well developed, a slight persistent bacteremia occurred during the latter part of the disease. An analogous degree of early and persistent leukopenia was followed in other animals by generalized infection.

Dogs developing a generalized infection with fatal termination

Dog 22A. Weight 10.6 kgm. (Chart 9). On May 16th, 1930, after preparation with morphine and cocaine, the dog was injected with 0.05 cc. pneumococcus Type I suspended in starch into right lower lobe. The following morning the dog showed a high temperature, very rapid pulse, appeared definitely ill and was coughing. There were physical signs of consolidation at the right lower lobe, which were corroborated by x-ray (Fig. 22). By the next day, i.e., the third day of disease, the dog was in good condition. X-ray showed consolidation of the right lower lobe. Under the fluoroscope the diaphragm on that side was elevated and its excursion limited, as was the movement of the right ribs. On the fourth day a marked blood invasion was found and a probable extension of the lesion to the right middle lobe was seen in the x-ray (Fig. 23). By the fifth day the dog was quite ill and breathing rapidly. On the following day, the 21st, the dog was moribund. X-ray showed clouding of the whole right chest (Fig. 24). He died that evening. Autopsy performed the next morning revealed an empyema of each pleural cavity. The lungs were collapsed. The right lower and middle lobes were consolidated and moderately firm, the right upper lobe congested but not consolidated. The left lung was not consolidated and contained a little air. Heart's blood showed a pure culture of pneumococcus.

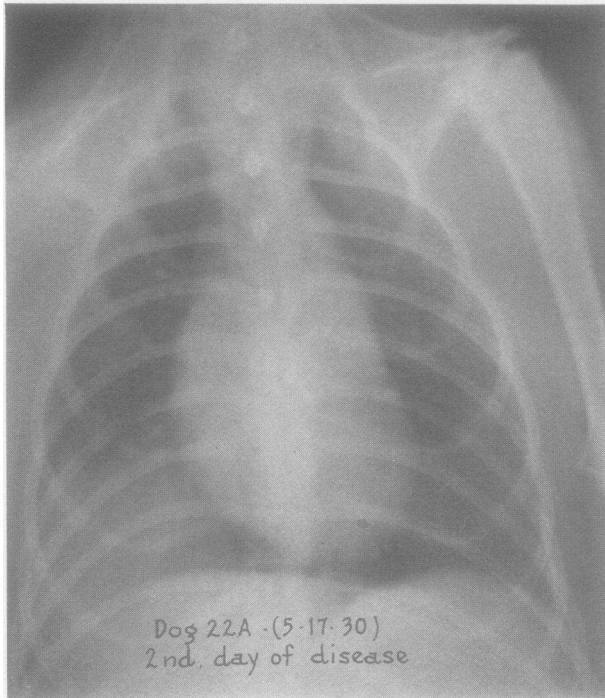


FIG. 22. DOG 22. X-RAY TAKEN ON THE 2D DAY OF DISEASE SHOWING CONSOLIDATION OF THE RIGHT LOWER LOBE

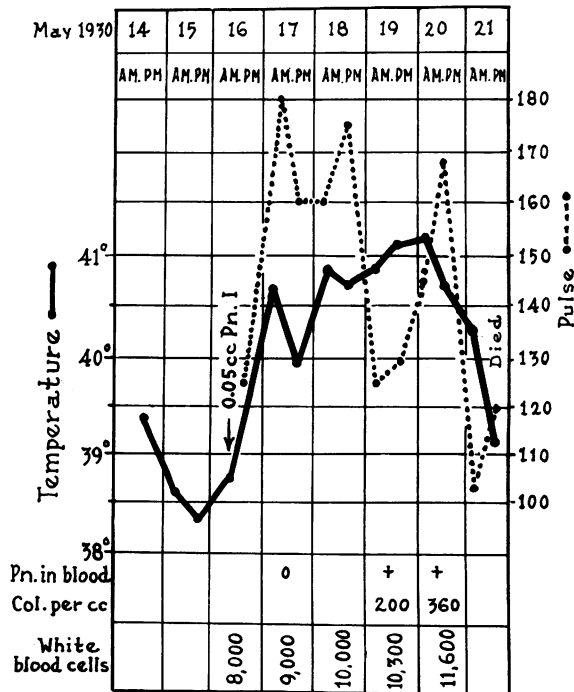


CHART 9. DOG 22A: EXPERIMENTAL LOBAR PNEUMONIA FOLLOWING THE INTRATRACHEAL INJECTION OF 0.05 CC. BROTH CULTURE OF PNEUMOCOCCUS TYPE I SUSPENDED IN STARCH.

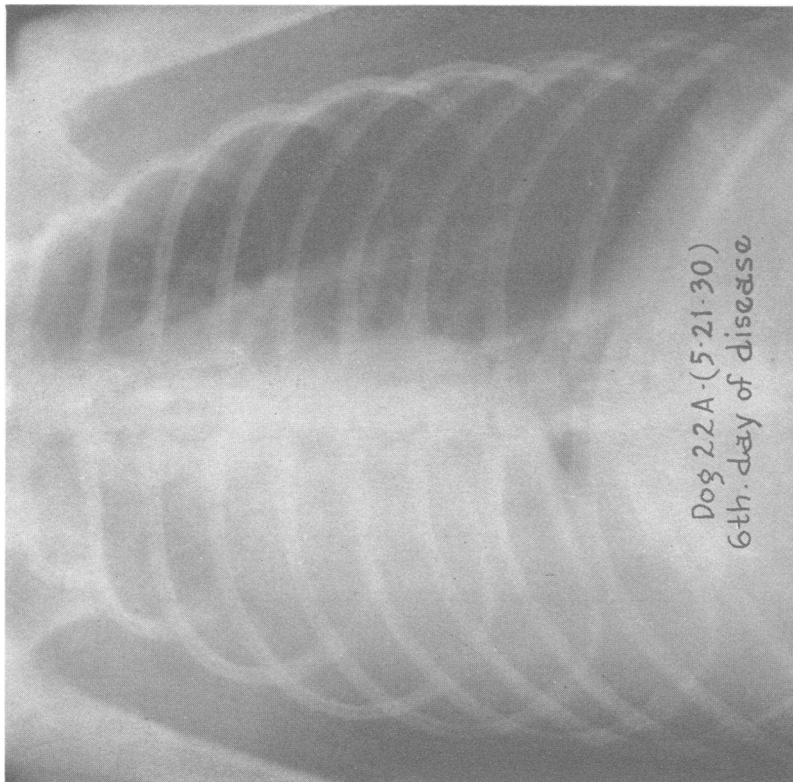


FIG. 24. DOG 22A. X-RAY TAKEN ON THE 6TH DAY OF DISEASE SHOWING A MARKED SPREAD OF THE PROCESS WHICH NOW INVOLVED THE WHOLE RIGHT LUNG.

The heart shadow has disappeared almost completely into the right chest shadow.

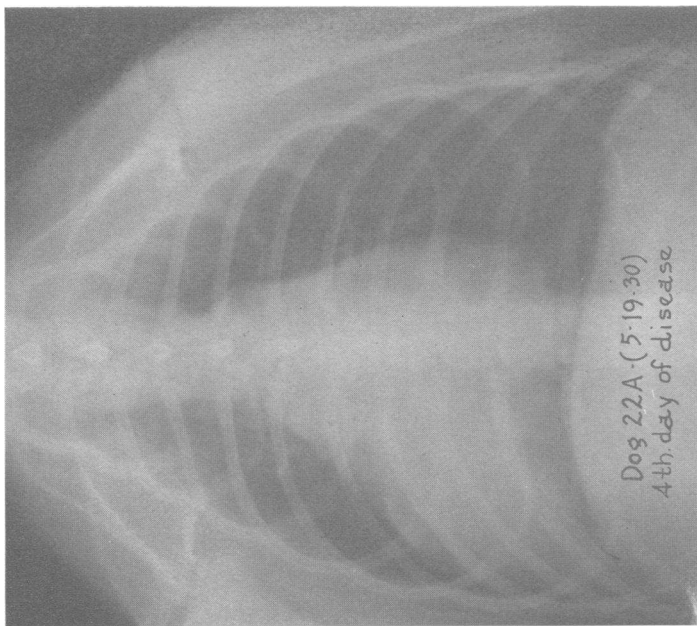


FIG. 23. DOG 22. X-RAY TAKEN ON THE 4TH DAY OF DISEASE SHOWING A PROBABLE EXTENSION OF THE LESION TO THE RIGHT MIDDLE LOBE

The pneumonic lesion began in this animal as a localized process. On the second day of the disease the x-ray (Fig. 22) showed an evenly dense shadow on the right lower lobe and the blood was sterile. Daily x-rays indicated little change until the fourth day when a slight but definite displacement of the heart shadow to the right was seen. This was no greater than that frequently observed in the disease when it progressed favorably. On the same day a marked bacteremia was found. However, on the fifth day of the disease, x-ray showed further displacement of the heart shadow which on the sixth day was entirely in the area of the right chest (Fig. 24), the reason for this state being revealed at autopsy when the right lobes were found to be small, i.e., indicative of incomplete consolidation. The data at hand afford no explanation of this change from a localized to a generalized infection. While the white count did not rise, there was at no time a leukopenia. One must assume from earlier studies that the natural antipneumococcal properties in the blood probably became exhausted (10) (11).

The lesion in dogs receiving doses on the borderline of lethality always began as a localized process. Frequently the process remained localized. However, with larger doses which invariably produced a fatal outcome the infection tended to become generalized early. The course of the disease in such instances varied much. In certain animals the pulmonary lesion spread rapidly, and the dogs died within two to three days with a marked bacteremia and often empyema. In others the lesion spread more slowly, at times remaining confined to a single lobe; but bacteremia was progressive and death occurred within four to seven days. Empyema or other pyemic complications were usually found at autopsy. In one instance, only a diffuse lesion was found scattered throughout both lung fields at the end of twenty-four hours, giving the x-ray appearance of a widespread bronchopneumonia (Fig. 25).

Early reaction

During the greater part of this study, observations on the early febrile reaction were prevented by the depressant action of the morphia employed in the preparation of the animal for injection. With the omission of morphia or its replacement by small doses of codeine it was found that the temperature and white count began to rise within three to six hours after the intratracheal injection. Protocols of two animals observed in this way follow.

Dog 4C. Male, weight 9.7 kgm. (Chart 10). On June 15th, 1931, the dog was prepared by the subcutaneous injection of 60 mgm. codeine sulphate and cocainization of throat. At 8:45 A.M. 0.05 cc. pneumococcus Type I suspended in starch was injected into the right lower lobe. Temperature, and blood for white counts and culture were taken at intervals of several hours during the course of the day. Six hours after injection the animal appeared slightly ill

and at nine hours he was definitely ill, though not in any degree prostrated. By the following morning the dog was somewhat worse and was coughing. X-ray of the chest showed a lesion involving the right lower lobe. On the

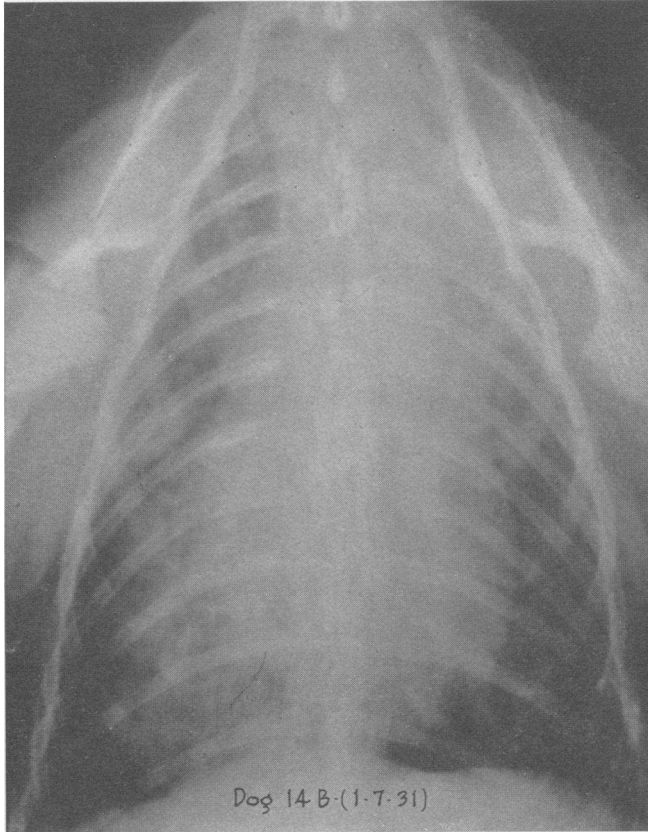


FIG. 25. DOG 14B. X-RAY TAKEN ON THE 2D DAY OF DISEASE SHOWING A DIFFUSE PATCHY INFILTRATION OF BOTH LUNG FIELDS

The dog died on the 4th day with a coalescent lobular pneumonia. The appearance of this x-ray presents a marked contrast to the even densities of the preceding lobar pneumonia lesions.

following day, i.e., the third day of the disease, the dog was definitely better though he still had a slight cough. By the fourth day he appeared to have recovered. He lost 0.6 of a kgm. during his illness.

Dog 2C. Male, weight 9.4 kgm. (Chart 10). Prepared on June 15, 1931, by cocaineization of throat alone and at 8:45 A.M. 0.05 cc. pneumococcus Type I suspended in starch was injected into the right lower lobe. The temperature and blood for white counts and cultures were taken at intervals during the day. Six hours after infection the animal appeared slightly ill and was definitely ill at nine hours. The next morning the dog was worse and showed labored respirations. An x-ray taken at this time revealed uniform consolidation of

the right lower lobe. There was no improvement in the dog's condition until the fourth day, when his temperature and pulse dropped towards normal and he seemed much better. He was sacrificed at this time for pathological study.

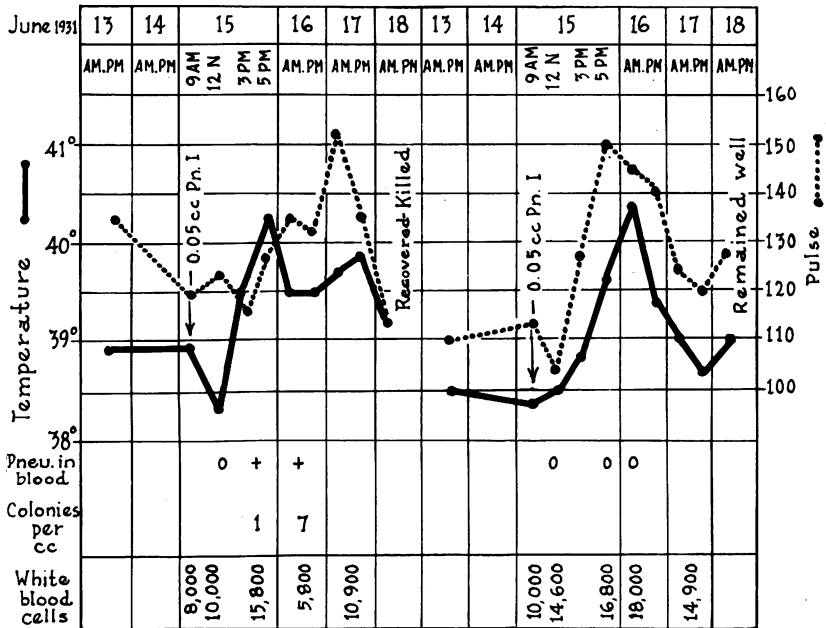


CHART 10. DOG 2C. (LEFT) EXPERIMENTAL LOBAR PNEUMONIA FOLLOWING THE INTRATRACHEAL INJECTION OF 0.05 CC. BROTH CULTURE OF PNEUMOCOCCUS TYPE I SUSPENDED IN STARCH.

DOG 4C. (RIGHT) EXPERIMENTAL LOBAR PNEUMONIA FOLLOWING THE INTRATRACHEAL INJECTION OF 0.05 CC. BROTH CULTURE OF PNEUMOCOCCUS TYPE I SUSPENDED IN STARCH.

Autopsy showed the right lower and middle lobes, and the post cardiac lobe in the stage of beginning resolution, in spite of the fact that pneumococci were recovered from the heart's blood as well as from the lungs.

Dosage

It was only after the employment of starch, as the medium of suspension for the infecting dose of pneumococci, that any degree of relationship was observed between the amount of culture injected and the resulting infection. Furthermore, it was found possible to reduce the dosage markedly when starch was substituted for gelatin. In Table I, which gives a condensed record of dogs, infected with pneumococcus Types I and II suspended in 5 per cent starch-broth, it will be noted that all the animals receiving less than 0.04 cc. pneumococcus Type I culture recovered after a course of three to nine days. Some of these were well within forty-eight hours. With doses of 0.04 cc. to 0.06 cc. approximately 45 per cent of the

dogs died. In some of these dogs other disturbing factors, such as mixed infection and unusual morphine depression, were present. Of five dogs receiving 0.1 cc. culture, four died; and when larger infecting doses were employed, death regularly resulted. However, within the range of non-lethal dosage, great individual variation in degree and length of disease occurred. Another strain of pneumococcus Type I, of considerably lower virulence than A₅ (the strain used throughout the foregoing experiments), failed to produce a lesion even in doses of 1 to 2 cc. of culture.

To produce infection with Type II, considerably larger amounts of culture were required. On account of the small number of observations made with this type the limits of dosage were not determined. Doses of 0.25 cc. to 0.5 cc. appeared to produce experimental pneumonia analogous to that usually resulting from the injection of 0.04 to 0.06 cc. of pneumococcus Type I.

Effect of morphine

The depressant effect of the preliminary injection of morphine seemed to have an important bearing on the inception of the disease. Numerous parallel experiments in which morphinized and unmorphinized dogs were injected with similar or varying doses showed that the unmorphinized animal recovered promptly from doses that regularly produced death in the dog which was in a state of morphine depression at the time of injection. While infection could be induced with relatively small amounts of pneumococcus culture in the unmorphinized dog, the disease was of an abortive character. The dose of morphine employed had evidently to be sufficient to produce a well marked drop in temperature in order to bring about the desired lowering of the animal's resistance. The question as to whether the lowering of body temperature is the essential factor in this reaction, or is only one manifestation of the effect of morphine, which also slows the pulse rate and respirations, cannot be answered at this time.

When the dose of morphine was very large, or the individual dog reacted severely to the usual dose, the dog's resistance was so lowered that a relatively small amount of pneumococcus culture produced a fulminating infection with leukopenia, incomplete consolidation, and bacteremia. In such instances the lowering of the body temperature often lasted twelve to twenty-four hours.

Other factors influencing the course of the disease

Apart from dosage and morphine effect, the disease appeared to be influenced by certain other conditions which might be present at the time of infection. Chief among these was intercurrent respiratory infection. Dogs suffering from snuffles at the time of injection (as was occasionally the case in the early phases of the work), or developing this condition during the course of experimental lobar pneumonia, either showed a

diffuse widespread type of lesion or, if true lobar consolidation did occur, died from pyemic complications. The course was usually brief—often two to three days. The lungs of such animals showed a mixed bacterial flora.

Another factor which influenced the disease was the age of the animal. The dogs selected for this study were young and vigorous. Infection of two old dogs resulted in a fulminating type of disease which was terminated by death within twenty-four to thirty hours. One of these animals is included in Table I (Dog 19D).

The temperature of the environment may also influence the inception of the experimental disease. Several dogs infected during hot weather with a dose that had regularly produced a fatal outcome, recovered after only a moderately severe disease. These were not included in the experimental data since all the other animals were infected during cool or cold weather. This matter is at present under investigation.

Changes in position of thoracic viscera during disease

X-rays and fluoroscopic examination of 105 experimental dogs showed some degree of mediastinal or diaphragmatic displacement toward the affected side in 42 animals.⁷ The degree of displacement of the heart shadow appeared to depend largely on the nature and rate of pulmonary involvement. With an effectively localized, and slowly spreading pneumonic process, there was either no detectable shift or only a slight one. X-rays of dogs 24B (Fig. 10) and 22B (Fig. 12), when compared with the position of the normal heart as seen in Figure 26, both show a slight displacement to the affected side. In dog 22A (Fig. 22) the heart appears to be in the normal position. The lesions in all these dogs began as localized ones. As the process spread the heart shadow often showed an increased shift toward the consolidated side (see series of dog 37, Fig. 2 to 7). Even with densely consolidated lung, such as occurred in dog 40 (Fig. 16), this change was observed. The diaphragm was sometimes elevated on the side of the lesion, sometimes not. However, when the pulmonary process spread rapidly from the beginning, as sometimes occurred, especially after large doses, the heart shadow showed an early and marked displacement toward the affected side. A similar change was noted later in the disease in those animals in which an initially localized infection became generalized. This is illustrated well by the x-rays of dog 22A (Fig. 22 to 24).

⁷ A special study of the displacement of the thoracic viscera in this series of dogs has been made by Ching Wu (12). Ching Wu's modification of our animal holder, employed in the later part of the work, enabled us to secure much more constant centering of the dog's chest than had been possible earlier.

Starch, gelatin and streptococcus controls

Six dogs were injected with sterile starch and one with sterile gelatin. With one exception none of these animals showed any febrile reaction, increase in white blood count, or pulmonary lesion by x-ray. Observations in three instances were continued over a period of three to four days.

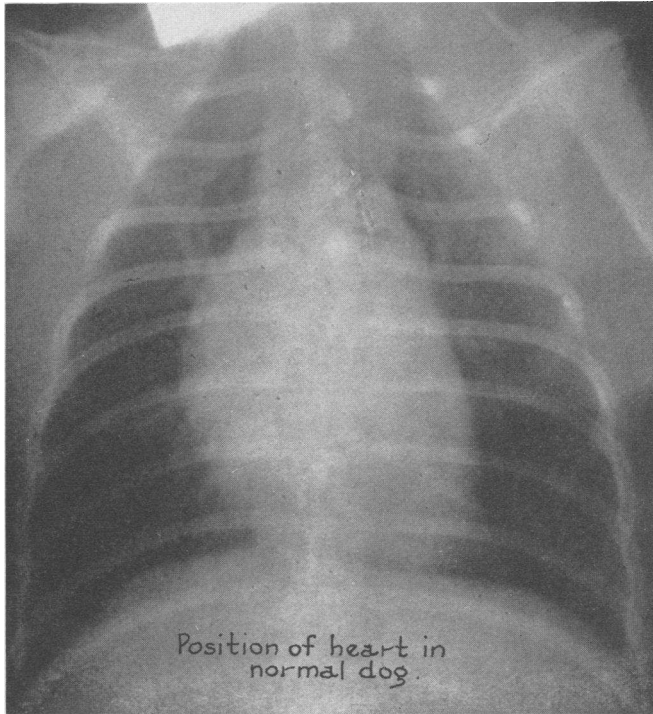


FIG. 26. X-RAY OF THE CHEST OF A NORMAL DOG TO SHOW THE USUAL POSITION OF THE HEART

The single dog in which a slight rise of temperature occurred (102.5° to 103° F.) was killed at 48 hours and showed at the point of injection a nodule of liverish appearance, 1 to 2 cm. in diameter, from which a small gram negative bacillus was cultured. Trauma of the bronchial mucosa resulting from the introduction of the catheter did not, of itself, appear to cause any significant changes. One animal was traumatized to a degree far in excess of that occurring during the process of implanting the pneumococci, without observable effect.

Attempts to produce pneumonia in dogs with hemolytic streptococci were uniformly unsuccessful. Even doses of 5 cc. of a culture recently isolated from a fatal case of hemolytic streptococcus bacteremia failed to produce more than a transient infection.⁸

⁸ This part of the work was carried out by Dr. Ching Wu, to whom we are much indebted.

DISCUSSION

A comparison of the course of lobar pneumonia, experimentally produced in the dog, with the disease observed clinically in man brings out certain similarities and differences between the two conditions. In both man and the dog the onset is rapid and the fever characteristically sustained. The length of the febrile course is definitely shorter in the dog, averaging four to five days. Recovery from the experimental disease is usually abrupt. The sharp fall in temperature and pulse rate, together with the prompt amelioration of the signs and symptoms of the disease, suggest a phenomena analogous to the crisis in man. However, as is seen often in the human disease, recovery from lobar pneumonia in the dog not infrequently is prolonged over a period of two to three days.

By means of serial x-rays it was possible to follow the localization and spread of the process in the lungs throughout the course of the disease. In those instances in which the disease was of a mild and brief nature the lesion remained confined to the lobe in which it was initiated. In cases of more marked severity, the lesion usually spread to other lobes, most often to adjacent lobes on the same side, but not infrequently to a lobe on the opposite side. Dogs going on to fatal termination always showed a spread of the lesion which sometimes included all but one or two of their six or seven lobes. Recovery occurred following the consolidation of as many as three lobes. Thus the distribution of the pulmonary lesions in the dog and man is in general similar except in one respect, namely that we have not observed recovery to take place in the experimental animal showing as much of the lung area involved as is occasionally seen in patients recovering from lobar pneumonia. With more than half the dog's total lung field consolidated, death has always ensued.

Clearing of the x-ray shadow proceeded rapidly after recovery and was usually complete within a week. In many instances beginning clearing of the initial lesion was already evident at the time of recovery (see Fig. 9 and 11). Physical signs of consolidation only very occasionally persisted after recovery. Resolution of the lung lesion is undoubtedly more rapid in the experimental disease than in man. This may be due to a difference in lung structure, the dog's lung being much less fibrous than the human lung and hence more mobile.

Physical signs in dogs and human beings, subjects of lobar pneumonia are essentially the same; the only observed difference being that râles and friction sounds were heard less frequently in the dog.

In the favorably progressing experimental disease the pneumococci tend to remain localized in the lung. Not infrequently, as in human cases, there is an early transient bacteremia. Rarely this may persist throughout the disease course. The occurrence of blood invasion always introduces uncertainty as to the outcome, for the majority of animals showing positive blood cultures died. Only one dog showing a blood

culture of more than fifty colonies per cc. of blood recovered. Blood invasion in some of the experimental animals reached a degree not observed in human beings—1,000 or more colonies per cc. have been noted. This is probably due to the fact that in such instances very imperfect consolidation of the lung was observed. Of thirty dogs dying or killed while very ill six showed sterile blood cultures throughout the course of the disease—a condition observed in a certain percentage of human beings dying from lobar pneumonia.

The relation of the leukocyte count to the experimental disease course is much the same as that observed in human lobar pneumonia. In the majority of animals destined to recover there was an early and marked increase in the white blood cells—chiefly the polymorphonuclear leukocytes. Thereafter the course of the white blood count was irregular as observed in many human cases. Sometimes a fall in the number occurred in the mid part of the disease followed by a sharp rise just before recovery. Again the final rise might not occur, the white count remaining slightly or moderately elevated throughout. An early and persistent leukopenia had the same prognostic import as in the human disease. However, recovering dogs showed not infrequently an early transient leukopenia.

The question of the relationship of pulmonary atelectasis to the initiation and spread of the disease will be discussed in the following paper on pathogenesis

SUMMARY

Utilizing the conception that the initial favorable environment for growth of pneumococci in the lungs would be in the terminal air sacs from which they were not readily expelled, a method for the production of experimental pneumococcus lobar pneumonia in the dog has been devised. This consists of injecting pneumococci, suspended in a starch-broth medium, through a radiopaque catheter inserted into a terminal bronchus with the dog under the fluoroscope. A preliminary injection of morphine sufficient to bring about a well marked depression of the body temperature, and local application of cocain to the larynx were employed. The disease produced with a dose ranging from 0.05 cc. to 0.00001 cc. of highly virulent culture of Type I pneumococcus ran a febrile course of three to nine days, accompanied by cough, dyspnea and prostration, which usually terminated abruptly. Most of the dogs recovered. The physical signs and x-ray findings were those of lobar consolidation which involved one, two or more lobes. When spread occurred it was most often to adjacent lobes, but occasionally lobes on the opposite side were affected. This infection remained characteristically localized in the lung. When blood invasion took place it was either mild or transitory. Resolution of the process occurred rapidly, leaving a lung of normal appearance. With larger infecting doses bacteremia and death resulted more frequently, and when amounts of culture greater than 0.1 cc. were employed

the infection quite regularly became generalized either early or late in the disease. In such animals consolidation of the affected lobes was usually incomplete and pyemic complications were commonly found at autopsy. Experimental lobar pneumonia produced with pneumococcus Type II was of the same character as that caused by Type I. Larger doses of culture of Type II than of Type I were required.

BIBLIOGRAPHY

- (1) Blake, F. G., and Cecil, R. L., *J. Exper. Med.*, 1920, xxxi, 403. Studies on Experimental Pneumonia. I. Production of Pneumococcus Lobar Pneumonia in Monkeys.
- (2) Schöbl, O., and Sellards, A. W., *Philippine J. Sc.*, 1926, xxxi, 1. Experimental Pneumonia in Monkeys.
- (3) Lamar, R. V., and Meltzer, S. J., *J. Exper. Med.*, 1912, xv, 133. Experimental Pneumonia by Intrabronchial Insufflation.
- (4) Coryllos, P. N., and Birnbaum, G. L., *Arch. Surg.*, 1929, xviii, 190. Lobar Pneumonia Considered as Pneumococcic Lobar Atelectasis of the Lung: Bronchoscopic Investigation.
- (5) Kline, B. S., and Winternitz, M. C., *J. Exper. Med.*, 1915, xxi, 304. Studies upon Experimental Pneumonia in Rabbits. VII. The Production of Lobar Pneumonia.
- (6) Wadsworth, Augustus, *Am. J. M. Sc.*, 1904, cxxvii, 851. Experimental Studies on the Etiology of Acute Pneumonitis.
- (7) Gaskell, J. F., *J. Path. and Bact.*, 1925, xxviii, 427. Experimental Pneumococcal Infections of the Lung.
- (8) Robertson, O. H., and Sia, R. H. P., *J. Exper. Med.*, 1924, xxxix, 219. Studies on Pneumococcus Growth Inhibition. II. A Method for Demonstrating the Growth-Inhibitory and Bactericidal Action of Normal Serum-Leucocyte Mixtures.
- (9) Woo, S. T., *J. Exper. Med.*, 1926, xliii, 623. Studies on Pneumococcus Growth Inhibition. V. The Relation of Virulence to the Pneumococidal Activity of Normal Rabbit Serum-Leucocyte Mixtures.
- (10) Robertson, O. H., Terrell, E. E., Graeser, J. B., and Cornwell, M. A., *J. Exper. Med.*, 1930, lii, 421. The Relation of Natural Humoral Anti-pneumococcal Immunity to the Inception of Lobar Pneumonia.
- (11) Terrell, E. E., *J. Exper. Med.*, 1930, li, 425. Changes in Humoral Immunity Occurring during the Early Stages of Experimental Pneumococcus Infection.
- (12) Wu, Ching, *Radiology*, 1932, xix, 215. Visceral Displacement in Pneumonia: A Roentgenologic and Experimental Study.