

Benign Familial Hematuria due to Mutation of the Type IV Collagen $\alpha 4$ Gene

Henny H. Lemmink,* Willy N. Nillesen,[†] Toshio Mochizuki,[§] Cornelis H. Schröder,* Han G. Brunner,[‡] Bernard A. van Oost,^{||} Leo A.H. Monnens,* and Hubert J.M. Smeets^{‡¶}

Departments of *Pediatrics and [†]Human Genetics, University Hospital Nijmegen, 6500 HB Nijmegen, The Netherlands; [§]Department of Medicine, Division of Nephrology, Albert Einstein College of Medicine, Bronx, New York; ^{||}Department of Clinical Sciences of Companion Animals, University of Utrecht, Utrecht, The Netherlands; and [‡]Division of Genetics, University of Limburg, Maastricht, The Netherlands

Abstract

Benign familial hematuria (BFH) is characterized by autosomal dominant inheritance, thinning of the glomerular basement membrane (GBM) and normal renal function. It is frequent in patients with persistent microscopic hematuria, but cannot be clinically differentiated from the initial stages of Alport syndrome, a severe GBM disorder which progresses to renal failure. We present here linkage of benign familial hematuria with the *COL4A3* and *COL4A4* genes at 2q35-37 ($Z_{\max} = 3.58$ at $\Theta = 0.0$). Subsequently, a glycine to glutamic acid substitution was identified in the collagenous region of the *COL4A4* gene. We conclude that type IV collagen defects cause both benign hematuria and Alport syndrome. Furthermore, our data suggest that BFH patients can be carriers of autosomal recessive Alport syndrome. (*J. Clin. Invest.* 1996. 98:1114–1118.) Key words: hematuria • Alport syndrome • basement membrane • collagen • mutation analysis

Introduction

Hematuria is the presenting symptom in a large number of renal disorders. If the hematuria occurs in childhood, is isolated and is of glomerular origin, the diagnosis is difficult to reach. Benign hematuria, Alport syndrome and IgA-nephropathy all present with persistent hematuria. Particularly, differentiation between Alport syndrome, which is a severe renal disorder, progressing to renal failure in most cases, and benign hematuria is mandatory for correct prediction of prognosis and genetic counseling. In benign hematuria electron microscopic analysis of renal biopsies shows thinning of the glomerular basement membrane (GBM)¹ (1–3), while in Alport syndrome

renal biopsies are characterized by irregular thickening and multilamination of the GBM (4). However, thinning of the GBM may be the only microscopic abnormality in younger Alport patients (5–7), which hampers the differentiation between the two disorders in childhood. Renal biopsies of 65 children with isolated hematuria persisting for at least one year revealed histological abnormalities consistent with Alport syndrome in eight cases and consistent with benign hematuria in 33 cases (3). A positive family history was detected in 23 of the 33 cases.

The major structural component of the GBM is formed by a type IV collagen network. As yet, six different type IV collagen chains have been identified and the respective genes were cloned. Mutations were detected in three type IV collagen genes in Alport syndrome. The majority was present in the X-linked type IV collagen $\alpha 5$ (*COL4A5*) gene, but recently mutations in the type IV collagen $\alpha 3$ and $\alpha 4$ (*COL4A3/A4*) genes have been reported in patients with the autosomal recessive form of this disease (8, 9). These latter two collagen genes are localized head to head on the tip of the long arm of chromosome 2 (10). Considering the similarities in GBM abnormalities, autosomal Alport syndrome and BFH could be the severe and mild forms of different molecular genetic defects in the same genes. Here we report linkage of the *COL4A3/A4* locus to BFH in a large Dutch family (11) and the identification of a pathogenic mutation in the *COL4A4* gene.

Methods

Patients. The index patient (III:10; see Fig. 1) presented with hematuria at the age of 5 years. There were no concomitant abnormalities, i.e., glomerular filtration rate was normal and hypercalciuria was absent. There was also no hypertension. The morphology of the erythrocytes in the urinary sediment indicated a glomerular origin of the cells. Audiography and fundoscopy revealed no abnormalities. Family history was negative for renal failure and deafness. One year later a renal biopsy was performed. Electron microscopy of the biopsy specimen showed regions with malformations of the glomerular basement membrane, typical for Alport syndrome, and regions which were thin. Further investigation of the family showed microscopic hematuria in both parents and his younger brother (III:11), but no other symptoms suggestive for Alport syndrome. Renal function was normal in the parents (II:7 and II:8; normal serum creatinine concentration). Microscopic hematuria was present in three sisters of the father (II:7) and in half of their off-spring, as well as in the grandfather (I:1; Fig. 1). Particularly important is that this 75-yr-old man had a normal serum creatinine concentration. In the family of the mother (II:8) hematuria was also widely present. Her 76-yr-old father had hematuria and a normal creatinine level, her mother was healthy. It was con-

Address correspondence to Hubert J.M. Smeets, Ph.D., Division of Genetics, University of Limburg, P.O. Box 1475, NL-6201 BL Maastricht, The Netherlands. Phone: 31-43-3875843; FAX: 31-43-3877877.

Received for publication 1 May 1996 and accepted in revised form 8 July 1996.

1. Abbreviations used in this paper: BFH, benign familial hematuria; GBM, glomerular basement membrane.

J. Clin. Invest.

© The American Society for Clinical Investigation, Inc.

0021-9738/96/09/1114/05 \$2.00

Volume 98, Number 5, September 1996, 1114–1118

cluded that the family history on both sides strongly supported the diagnosis BFH. The index patient might have inherited the disorder from both parents, which could explain the aberrant morphology of the biopsy specimen. He is presently 16 years old and symptoms are hematuria and recently developed proteinuria (0.5 grams/liter). Hematuria was defined as a condition with 10 or more erythrocytes per mm³ urine, established by the quantitative sediment method of Gadeholt (12). Individuals with borderline values were repeatedly analyzed. All family members could unambiguously be scored as either affected or unaffected.

Linkage analysis. Blood samples were collected from family members and genomic DNA was isolated by a salting out procedure (13). The *COL4A3/COL4A4* CA repeat was PCR amplified using 125 ng of primers CA11F (5'-ATC TCT CAG GGT GCG TGC-3') and CA11R (5'-CTC ATT GAT ACA CAC AAA TGC A-3') and 50-100 ng DNA template in a standard Cetus buffer with 2 mM MgCl₂. After 3 min at 94°C, four initial cycles were performed of 1 min at 94°C, 1 min at 58°C and 1 min at 72°C followed by 30 cycles of 1 min at 94°C, 1 min at 55°C and 1 min at 72°C. One of the primers was fluorescently labeled and the PCR product was analyzed on an ABI 373A Automated Sequencer using the Genescan software package (Applied Biosystems, Foster City, CA). A *COL4A4* HaeIII RFLP was identified by SSCP and subsequent sequence analysis and is caused by a neutral mutation at the 1198 glycine residue of the *COL4A4* gene. PCR was performed on 100 ng genomic DNA using 100 ng of intronic oligonucleotides A4IF10 (5'-AGGCACTATAAC-AGGGACAAGA-3') (9) and 714 (5'-CCTCATTGCATTGGAAGGT-3'), 200 μM dNTPs, 5% DMSO in Ampli-Taq buffer containing 67 mM Tris-HCl (pH = 8.8), 16.6 mM (NH₂)SO₄, 6.7 mM MgCl₂, 0.17 mg/ml BSA (Boehringer Mannheim, Germany) to a total volume of 25 μl. The sequence of oligo 714 is the reverse of oligonucleotide A4IF9 (9). After 5 min of denaturation at 96°C 1 U Ampli-Taq DNA polymerase (Perkin-Elmer, Norwalk, CT) was added and 30 cycles of PCR were started (denaturation at 94°C for 1 min, annealing at 62°C for 1 min and extension at 72°C for 1 min and 30 s). If the HaeIII site is present, digestion of the PCR fragment (260 bp) gives two bands of 182 and 78 bp (data not shown).

Two point and multi-point lod scores were calculated using the MLINK and LINKMAP options of the LINKAGE package com-

puter program (version 5.03) (14). BFH was defined as an autosomal dominant disorder with complete penetrance. The disease frequency was estimated to be 0.0001.

Mutation analysis. RNA was isolated from peripheral blood lymphocytes (PBL) or EBV transformed PBL from affected and normal individuals by RNazol extraction (15). *COL4A3* and *COL4A4* cDNA fragments were generated by RT-PCR analysis as described before (8, 16). Oligonucleotides were designed to amplify *COL4A3* and *COL4A4* cDNA by multiple overlapping cDNA fragments. DNA fragments were sequenced on an ABI 373A automated sequencer. Reaction conditions using dyedeoxyTM-terminators were according to a protocol provided by the manufacturer (Applied Biosystems, Foster City, CA). The Gly897Glu mutation was identified in the PCR fragment, flanked by outer primers 945 (5'-GCGAAG-GGTGACATGGTTGTATCA-3') starting at position 1871 and 946 (5'-CCTCTCAGAAGGTCAACACTCCAG-3') starting at position 4074 (17) in a first round of 35 cycles; denaturation for 1 min at 92°C, 1 min 30 s of annealing at 60°C and extension for 3 min at 72°C. Two microliters out of the first PCR reaction was used as template for a second round of 35 cycles using inner primers F100 (5'-AAGGCC-TCCCCGACTCCCA-3') at position 2750 and R101 (5'-CGGGAG-GTCCTATGGCTC-3') at position 3017 (17); denaturation for 1 min at 92°C, 1 min 30 s of annealing at 55°C and extension for 2 min at 72°C. The Gly897Glu mutation created an AluI restriction site and was screened at the genomic DNA level by PCR amplification using oligonucleotides F100 (5'-AAGGCCCTCCCCGACTCCCA-3') and 1106 (5'-ACCTGGAGGACCAGGTAGC-3') and digestion with AluI restriction enzyme (GIBCO BRL, Gaithersburg, MD). If the mutation is present the 104-bp PCR fragment is cleaved in two fragments of 86 and 18 bp. The smallest fragment is not visible.

Results

Linkage analysis. Linkage analysis was performed with two novel polymorphic markers from the *COL4A3/COL4A4* locus. The most informative marker was a CA repeat, isolated from a YAC clone with an insert of 540 kb, containing both *COL4A3* and *COL4A4* genes (18). The other marker was a

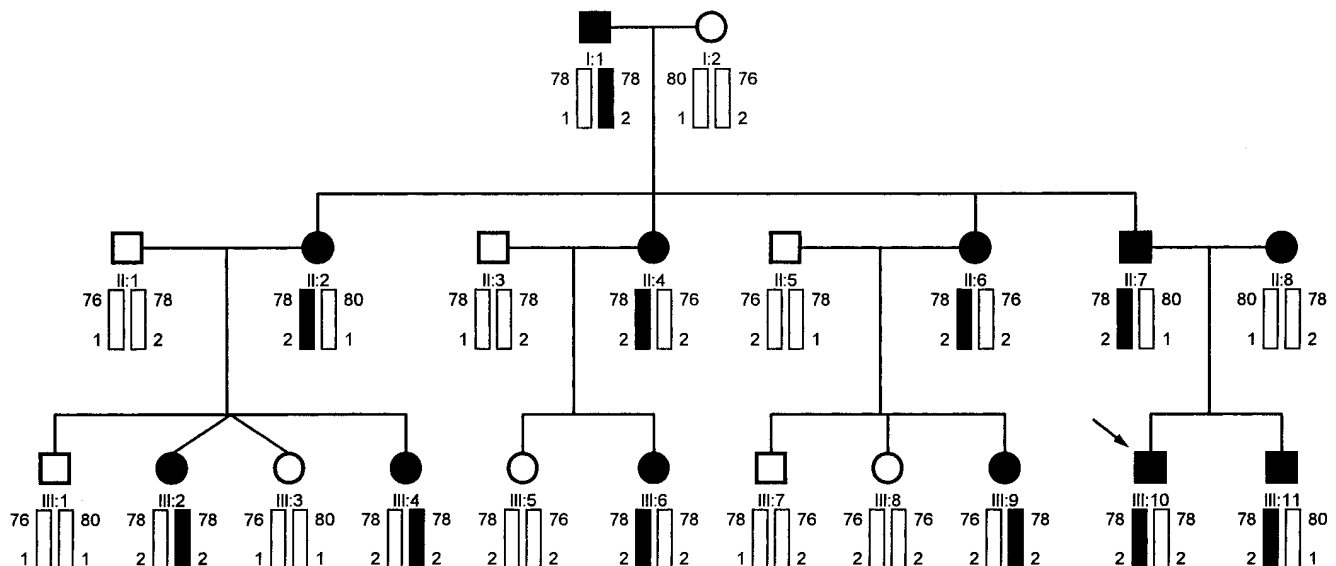


Figure 1. Segregation analysis of type IV collagen $\alpha 3$ and $\alpha 4$ markers in the BFH family. Haplotypes were constructed for the type IV collagen $\alpha 3/\alpha 4$ CA repeat and the type IV collagen $\alpha 4$ HaeIII RFLP. Type IV collagen $\alpha 3/\alpha 4$ CA repeat fragments are indicated as the length of the PCR fragment in basepairs (76, 78, and 80 bp). The HaeIII RFLP alleles are represented by 1 (HaeIII site absent) and 2 (HaeIII site present). The haplotype [78, 2], shown as black bars, cosegregates with BFH. Filled symbols indicate individuals with hematuria. Arrow indicates index patient (III-10).

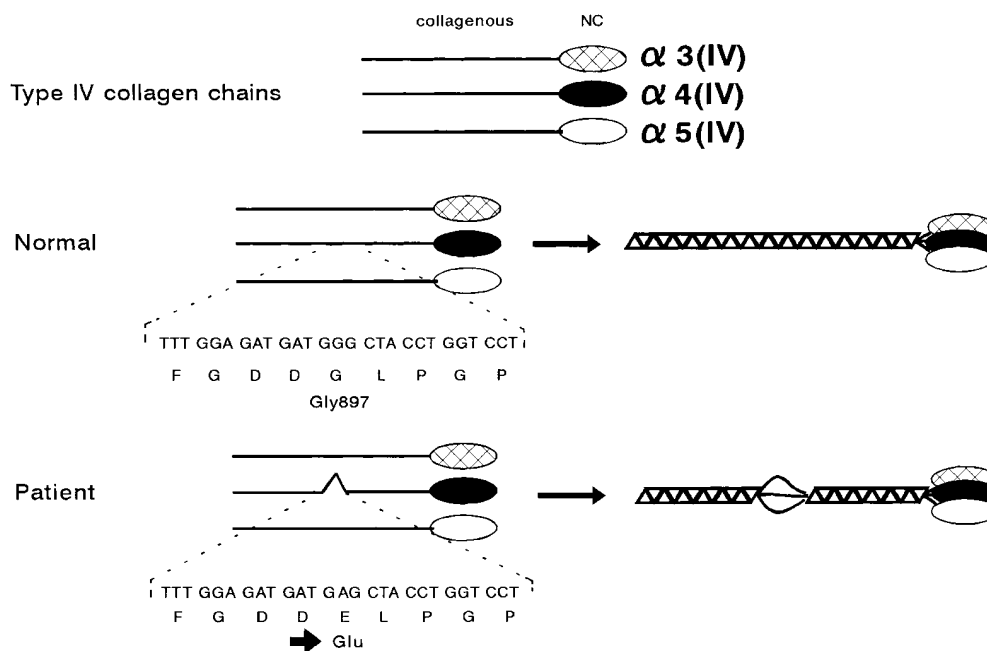


Figure 2. Gly897Glu substitution in the type IV collagen $\alpha 4$ chain in BFH. Sequence analysis of type IV collagen $\alpha 4$ cDNA of the index patient and a normal control. The mutation, which changes the glycine (G) codon 897 GGG into the glutamic acid (E) codon GAG is indicated by an arrow. Type IV collagen chains consist of collagenous and non-collagenous (NC) domains. Three type IV collagen chains form a triple helix, which is interrupted by the substitution of a conserved glycine residue.

HaeIII RFLP in one of the exons of the *COL4A4* gene. Because the genomic structure of *COL4A4* is not clarified yet, the exact numbering of exons is unknown, but most likely exon 8 is involved (counting from the 3' end). The RFLP is caused

by a polymorphism, a neutral G to A nucleotide substitution at Glycine1198 (GGG into GGA) (17). The allele frequencies of this polymorphism were 0.5/0.5 (70 unrelated individuals tested).

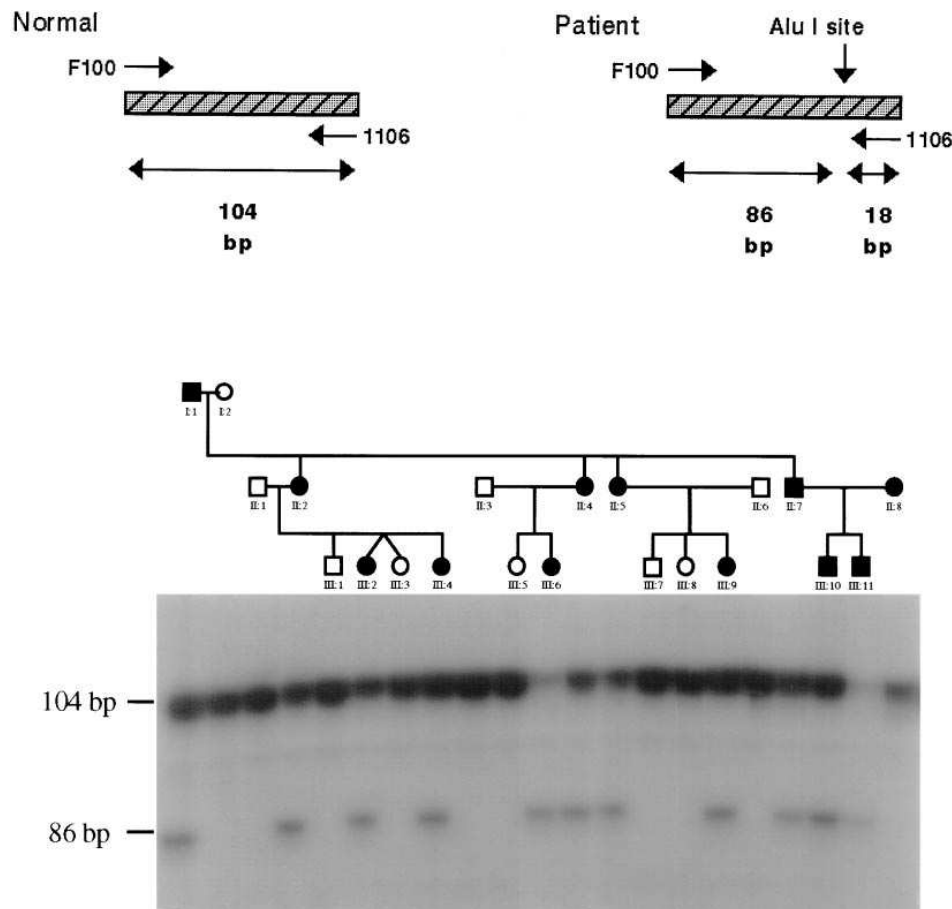


Figure 3. Segregation of Gly897Glu mutation in the BFH family. The presence of the mutation creates an additional AluI restriction site. Cleavage of the 104 bp PCR fragment in two shorter fragments of 86 and 18 basepairs is indicative for the presence of the mutation. Only the affected family members (filled symbols) show the shorter DNA fragment (86 bp), the smallest fragment of 18 bp is not visible. DNA fragment lengths are indicated in basepairs (bp).

Linkage analysis was performed in the paternal (II:7) side of the pedigree (Fig. 1). The mother (II:8) and her two sons, III:10 and III:11 (Fig. 1), were not included in the linkage studies, because BFH segregated also in the maternal line. The maternal relatives were not available for linkage analysis. A maximum lod score (Z_{\max}) of 3.01 was obtained in the paternal (II:7; Fig. 1) line with the *COL4A3/COL4A4* CA repeat at recombination fraction (Θ) of 0.0 in our family. The Z_{\max} obtained with the intragenic *COL4A4* RFLP is 1.51 at $\Theta = 0.0$. All affected individuals share the haplotype [78, 2] for both markers (Fig. 1). This haplotype was linked to BFH with a Z_{\max} of 3.58 at $\Theta = 0.0$.

Mutation analysis. RT-PCR was performed on total lymphocyte RNA followed by direct sequence analysis of amplified *COL4A3* and *COL4A4* cDNA fragments. A heterozygous G to A nucleotide substitution was identified at position 2898 of the *COL4A4* gene in the patients III:10 and III:11 and in their father II:7, but not in their mother II:8. The glycine codon GGG at position 897 was changed into GAG, encoding a glutamic acid residue (Fig. 2). The mutation introduced a novel site for the restriction enzyme *AluI* and the other family members and controls were screened for the presence of this site. If the *AluI* site is present, a 104 bp PCR fragment will be cleaved in two smaller fragments of 86 and 18 bp (Fig. 2). All affected family members were heterozygous for the mutation (Fig. 3) and the mutation was not detected in the unaffected family members and 50 unrelated controls (data not shown).

Discussion

For several reasons, the Gly897Glu mutation in the type IV collagen $\alpha 4$ chain is likely to be the pathogenic mutation in the BFH family. First, the mutation changes a glycine in a conserved collagenous triple helical domain in the type IV collagen $\alpha 4$ chain (17). Every third amino acid is a glycine, because it is the only residue small enough to fit into the center of the triple helical molecule (19). If glycine residues are substituted by bulkier amino acids such as glutamic acid the triple helix structure will be distorted (Fig. 2). Unlike fibrillar collagens, type IV collagen triple helices contain 21–26 interruptions, which are assumed to provide flexibility to the molecule. However, the positions of these interruptions are highly conserved during evolution and the generation of an additional interruption may interfere with correct folding of the intricate type IV collagen trimers, consisting of type IV collagen $\alpha 3$, $\alpha 4$, and $\alpha 5$ chains. Substitutions for glycines in the collagenous triple helical domain are also a common cause of other collagen disorders, like osteogenesis imperfecta and Ehlers Danlos syndrome (20). Furthermore, the mutation cosegregates with BFH in our family and, finally, the mutation is absent from a control group of 50 individuals, which provides additional evidence for the pathogenicity of the defect.

In 1994, homozygous mutations in the type IV collagen $\alpha 3$ and $\alpha 4$ genes have been identified in patients with autosomal recessive Alport syndrome (8, 9). Two different mutations were reported in the type IV collagen $\alpha 4$ gene: a glycine to serine substitution and a serine to stop mutation (9). Similar to the Gly897Glu mutation in the BFH family presented here, the glycine is substituted in the triple helical domain of the type IV collagen $\alpha 4$ chain. Our data suggest that BFH patients can be manifesting carriers of autosomal recessive Alport syn-

drome. This is in line with the histological examination of the kidney biopsy and the presence of proteinuria in the index patient, who is a suspected compound BFH heterozygote. The definite proof awaits the detection of the second maternal BFH mutation and the progression of his renal disease.

In conclusion, this is the first report on a genetic defect explaining benign hematuria. The identification of type IV collagen defects, similar to those found in Alport syndrome, is important for genetic counseling and prognostic prediction. As yet, this prediction can not be based on the mutation only, but needs a complete investigation of family history, follow-up examination and renal biopsy. In a recent report linkage of the rare autosomal dominant form of Alport syndrome to the type IV collagen $\alpha 3$ and $\alpha 4$ locus was demonstrated in a large Northern-Irish family (Jefferson, J.A., A.P. Maxwell, A.E. Hughes, C.M. Hill, C.C. Doherty, and N.C. Nevin. Autosomal dominant Alport syndrome linked to the type IV collagen $\alpha 3$ and $\alpha 4$ genes (*COL4A3* and *COL4A4*), manuscript submitted for publication). It is obvious that the type IV collagen $\alpha 3$ and $\alpha 4$ genes are strong candidates for the autosomal dominant form of Alport syndrome as well. This would complete the spectrum of phenotypes of type IV collagen $\alpha 3$ and $\alpha 4$ defects, ranging from neutral amino acid substitutions (8) and benign hematuria to mild autosomal dominant and severe recessive Alport syndrome. In this way, the type IV collagen mutations fit within the rule of extreme clinical and genetic variability of collagen disorders (21).

Acknowledgments

This study is supported by a grant from the Dutch Kidney Foundation project no. C90.1022. We thank Marcy Speer (Duke University Medical Center, Durham, NC) for help in linkage analysis.

References

- Gauthier, B., H. Trachtman, R. Frank, and E. Valderrama. 1989. Familial thin basement membrane nephropathy in children with asymptomatic microhematuria. *Nephron*. 51:502–508.
- Piel, C.F., C.G. Biava, and J.R. Goodman. 1982. Glomerular basement membrane attenuation in familial nephritis and 'benign hematuria.' *J. Pediatr.* 101:358–365.
- Schröder, C.H., C.M. Bontemps, J.M. Foidart, L.A.H. Monnens, and J.H. Veerkamp. 1991. Renal biopsy findings and family studies in 65 children with isolated hematuria. *Acta Paediatr. Scand.* 79:630–636.
- Spear, G.S., and R.J. Slusser. 1972. Alport's syndrome. Emphasizing electron microscopic studies of the glomerulus. *Am. J. Path.* 69:213–220.
- Rumpelt, H.J., K.H. Langer, K. Scharer, E. Straub, and W. Thones. 1974. Split and extremely thin glomerular basement membranes in hereditary nephropathy (Alport's syndrome). *Virchows Arch. Path. Anat. Hist.* 364:225–233.
- Gubler, M.C., G. Gonzalez-Burchard, C. Monnier, and R. Habib. 1976. Alport's syndrome: Natural history and ultrastructural lesions of glomerular and tubular basement membranes. *Contr. Nephrol.* 2:163–169.
- Rumpelt, H.-J. 1980. Hereditary nephropathy (Alport syndrome): correlation of clinical data with glomerular basement membrane alterations. *Clin. Nephrol.* 13:203–207.
- Lemmink, H.H., T. Mochizuki, L.P.W.J. van den Heuvel, C.H. Schröder, A. Barrientos, L.A.H. Monnens, B.A. Van Oost, H.G. Brunner, S.T. Reeders, and H.J.M. Smeets. 1994. Mutations in the type IV collagen $\alpha 3$ (*COL4A3*) gene in autosomal recessive Alport syndrome. *Hum. Mol. Genet.* 3:1269–1273.
- Mochizuki, T., H.H. Lemmink, M. Mariyama, C. Antignac, M.C. Gubler, Y. Pirson, C. Verellen-Dumoulin, B. Chan, C.H. Schröder, H.J.M. Smeets, and S.T. Reeders. 1994. Identification of mutations in the $\alpha 3$ (IV) and $\alpha 4$ (IV) collagen genes in autosomal recessive Alport syndrome. *Nat. Genet.* 8:77–82.
- Mariyama, M., K. Zheng, T.L. Yang-Feng, and S.T. Reeders. 1992. Colocalization of the genes for the $\alpha 3$ (IV) and $\alpha 4$ (IV) chains of type IV collagen to chromosomes 2 bands q35–37. *Genomics*. 13:809–813.
- Schröder, C.H., H.G. Brunner, and L.A.H. Monnens. 1990. Genetic features of Alport syndrome. *Contr. Nephrol.* 80:3–8.
- Gadeholt, H. 1968. Quantitative estimation of cells in urine. *Acta Med.*

Scand. 183:369–374.

13. Miller, S.A., D.D. Dykes, and H.F. Polesky. 1988. A simple salting out procedure for extracting DNA from human nucleated cells. *Nucl. Acids Res.* 16:1215.

14. Lathrop, G.M., J.M. Lalouel, C. Julien, and J. Ott. 1988. Multilocus linkage analysis in humans: detection of linkage and estimation of recombination. *Am. J. Hum. Genet.* 37:482–498.

15. Chomczynski, P., and N. Sacchi. 1987. Single-step method of RNA isolation by acid guanidinium thiocyanate-phenol-chloroform extraction. *Anal. Biochem.* 162:156–159.

16. Lemmink, H.H., L.A.J. Kluijtmans, H.G. Brunner, C.H. Schröder, B. Knebelmann, E. Jelinkova, B.A. Van Oost, L.A.H. Monnens, and H.J.M. Smeets. 1994. Aberrant splicing of the COL4A5 gene in patients with Alport syndrome. *Hum. Mol. Genet.* 3:317–322.

17. Leinonen, A., M. Mariyama, T. Mochizuki, K. Tryggvason, and S.T. Reenders. 1994. Complete primary structure of the human type IV collagen $\alpha 4(\text{IV})$ chain. *J. Biol. Chem.* 269:26172–26177.

18. Mariyama, M., A. Leinonen, T. Mochizuki, K. Tryggvason, and S.T. Reenders. 1994. Complete primary structure of the human $\alpha 3(\text{IV})$ collagen chain. Coexpression of the $\alpha 3(\text{IV})$ and $\alpha 4(\text{IV})$ collagen chains in human tissues. *J. Biol. Chem.* 269:23013–23017.

19. Prockop, D.J. 1990. Mutations that alter the primary structure of type I collagen. *J. Biol. Chem.* 265:15349–15352.

20. Kuivaniemi, H., G. Tromp, and D.J. Prockop. 1991. Mutations in collagen genes: causes of rare and some common diseases in humans. *FASEB J.* 5: 2052–2060.

21. Francomano, C.A. 1995. Key role for a minor collagen. *Nat. Genet.* 9:6–8.