

## Eosinophils in chronically inflamed human upper airway tissues express transforming growth factor beta 1 gene (TGF beta 1).

I Ohno, ... , J Gauldie, M Jordana

*J Clin Invest.* 1992;**89**(5):1662-1668. <https://doi.org/10.1172/JCI115764>.

### Research Article

Transforming growth factor beta (TGF beta) is a multifunctional protein which has been suggested to play a central role in the pathogenesis of chronic inflammation and fibrosis. Nasal polyposis is a condition affecting the upper airways characterized by the presence of chronic inflammation and varying degrees of fibrosis. To examine the potential role of TGF beta in the pathogenesis of this condition, we investigated gene expression and cytokine production in nasal polyp tissues as well as in the normal nasal mucosa. By Northern blot analysis using a porcine TGF beta 1 cDNA probe, we detected TGF beta 1-specific mRNA in nasal polyp tissues, as well as in the tissue from a patient with allergic rhinitis, but not in the normal nasal mucosa. By the combination of tissue section staining with chromotrope 2R with in situ hybridization using the same TGF beta 1 probe, we found that approximately 50% of the eosinophils infiltrating the polyp tissue express the TGF beta 1 gene. In addition, immunohistochemical localization of TGF beta 1 was detected associated with extracellular matrix as well as in cells in the stroma. These results suggest that in nasal polyposis where eosinophils are the most prevalent inflammatory cell, TGF beta 1 synthesized by these cells may contribute to the structural abnormalities such as stromal fibrosis and basement membrane thickening which [...]

**Find the latest version:**

<https://jci.me/115764/pdf>



## Eosinophils in Chronically Inflamed Human Upper Airway Tissues Express Transforming Growth Factor $\beta$ 1 Gene (TGF $\beta$ 1)

I. Ohno,\* R. G. Lea,\* K. C. Flanders,<sup>§</sup> D. A. Clark,\* D. Banwatt,\* J. Dolovich,<sup>||</sup> J. Denburg,\* C. B. Harley,\* J. Gauldie,\* and M. Jordana\*

\*Departments of Pathology, \*Medicine, <sup>||</sup>Pediatrics, and <sup>§</sup>Biochemistry, McMaster University, Hamilton, Ontario L8N-3Z5 Canada; and

<sup>§</sup>Laboratory of Chemoprevention, National Cancer Institute, National Institutes of Health, Bethesda, Maryland 20892

### Abstract

Transforming growth factor  $\beta$  (TGF $\beta$ ) is a multifunctional protein which has been suggested to play a central role in the pathogenesis of chronic inflammation and fibrosis. Nasal polyposis is a condition affecting the upper airways characterized by the presence of chronic inflammation and varying degrees of fibrosis. To examine the potential role of TGF $\beta$  in the pathogenesis of this condition, we investigated gene expression and cytokine production in nasal polyp tissues as well as in the normal nasal mucosa. By Northern blot analysis using a porcine TGF $\beta$ 1 cDNA probe, we detected TGF $\beta$ 1-specific mRNA in nasal polyp tissues, as well as in the tissue from a patient with allergic rhinitis, but not in the normal nasal mucosa. By the combination of tissue section staining with chromotrope 2R with in situ hybridization using the same TGF $\beta$ 1 probe, we found that ~ 50% of the eosinophils infiltrating the polyp tissue express the TGF $\beta$ 1 gene. In addition, immunohistochemical localization of TGF $\beta$ 1 was detected associated with extracellular matrix as well as in cells in the stroma. These results suggest that in nasal polyposis where eosinophils are the most prevalent inflammatory cell, TGF $\beta$ 1 synthesized by these cells may contribute to the structural abnormalities such as stromal fibrosis and basement membrane thickening which characterize this disease. (*J. Clin. Invest.* 1992. 89:1662-1668.) **Key words:** nasal polyposis • inflammation • cytokines • histochemistry • in situ hybridization

### Introduction

Nasal polyps are grapelike structures of unknown etiology which arise from the posterior and sphenoid sinus mucosae and eventually occlude the nares. Nasal polyposis occurs as frequently in patients with atopy as in the general population. Polyp tissue is characterized by the presence of chronic inflammation in which eosinophils represent the most prevalent infil-

trating inflammatory cell (1). Additional features of nasal polyps include varying degrees of basement membrane thickening and fibrosis in the stroma (2, 3) which are similar to those recently described in asthma (4). The mechanism underlying these structural abnormalities is not yet known.

Transforming growth factor  $\beta$  (TGF $\beta$ )<sup>1</sup> is a 25-kD homodimeric or heterodimeric protein that can mediate a broad spectrum of biological activities (5). TGF $\beta$  was initially recognized by its ability to transform normal rat fibroblasts in vitro (6, 7). It has been subsequently shown that this factor is a chemoattractant for fibroblasts (8), stimulates fibroblast proliferation (9), and enhances fibroblast collagen and fibronectin synthesis (10, 11), while inhibiting collagenase gene expression (12), in vitro. Furthermore, the subcutaneous injection of TGF $\beta$  into mice causes rapid granulation and angiogenesis at the local site (13), and the association between TGF $\beta$  gene expression detected by in situ hybridization and either collagen gene expression or collagen accumulation in the tissue has been documented in bleomycin-induced pulmonary fibrosis (14), experimental hepatic fibrosis (15), and systemic sclerosis (16). The purpose of this study was to investigate whether nasal polyp tissues contained cells which express the gene for TGF $\beta$  and to detect the localization of TGF $\beta$  gene product in these tissues.

### Methods

**Tissues.** Nasal polyp tissues were obtained from seven subjects undergoing polypectomy for nasal obstruction. In addition, four inferior turbinate tissues were obtained at the time of surgery for submucosal resection; one of these patients had allergic rhinitis. Upon arrival at the lab, tissues were rinsed three times with Ham's F12 medium. A section of the tissue was dissected out, frozen in liquid nitrogen, and stored at -70°C for subsequent RNA isolation. For in situ hybridization, a small piece of tissue (20-30 mg) was fixed in 4% paraformaldehyde in 0.01 M PBS (pH 7.4) for 15 min at room temperature followed by 70% ethanol and embedded in paraffin. For immunohistochemistry, tissues were fixed in periodate-lysine-paraformaldehyde (10 mM NaIO<sub>4</sub>, 75 mM lysine, and 2% paraformaldehyde in 37.5 mM phosphate buffer pH 6.2) overnight at 4°C and then dehydrated through a sucrose gradient. Tissues were frozen in liquid nitrogen, cut in 5- $\mu$ m thick sections, and placed onto slides which were then kept at -20°C until warmed up to room temperature for processing immunohistochemistry.

**Probe construction and labeling.** Plasmid pTGF $\beta$ 33 which contains a porcine TGF $\beta$ 1 (pTGF $\beta$ 1) cDNA insert in the vector pCDV1 was kindly provided by Drs. P. Kondaiah and K. Flanders (National Institutes of Health, Bethesda, MD) (17). A 640-bp SacI/PvuII fragment

Address correspondence to Manel Jordana, M.D., Ph.D., Department of Pathology, Room 4H-17A, McMaster University, 1200 Main Street West, Hamilton, Ontario L8N-3Z5, Canada.

Received for publication 5 September 1991 and in revised form 11 December 1991.

*J. Clin. Invest.*

© The American Society for Clinical Investigation, Inc.

0021-9738/92/05/1662/07 \$2.00

Volume 89, May 1992, 1662-1668

1. Abbreviation used in this paper: TGF $\beta$ 1, transforming growth factor  $\beta$ 1.

was cut and used as pTGF $\beta$ 1 cDNA probe. This probe does not cross-react with either TGF $\beta$ 2 or TGF $\beta$ 3 (Dr. K. Flanders, personal communication). For Northern hybridization, labeling of the pTGF $\beta$ 1 cDNA probe was carried out by random priming using an oligo-labeling kit (Pharmacia, Uppsala, Sweden) with [ $\alpha$ - $^{32}$ P]dCTP (New England Nuclear, Boston, MA). For in situ hybridization, the pTGF $\beta$ 1 probe and a DNA 1-kb ladder (Bethesda Research Laboratories, Gaithersburg, MD) as negative control, were labeled using the same kit with  $^{32}$ S-dCTP (New England Nuclear).

**RNA isolation and Northern blot analysis.** Frozen tissues were homogenized in 4 M guanidinium isothiocyanate solution (1 ml/0.1 g wet tissue), and total RNA was extracted from the solution by phenol-chloroform extraction (18). 10  $\mu$ g of total RNA from each tissue and from cultured human lung fibroblasts stimulated with IL-1 $\alpha$  were electrophoresed through 1% agarose gels containing 6% formaldehyde and 0.5  $\mu$ g/ml of ethidium bromide, and transferred onto nitrocellulose (Schleicher & Schuell Inc., Keene, NH) by capillary blotting. Filters were incubated in prehybridization solution (40% formamide, 0.1% SDS, 2X standard saline citrate (SSC) [1XSSC = 150 mM NaCl, 15 mM tri-sodium citrate, pH 7.0], 5X Denhardt's solution [50X Denhardt's solution = Ficoll 5 g, polyvinylpyrrolidone 5 g, and BSA 5 g in 500 ml of H $_2$ O], 1 mM sodium pyrophosphate, 10 mM Tris-HCl [pH 7.5], and 0.1 mg/ml of denatured salmon sperm DNA) at 42°C for 4–6 h followed by hybridization in the same solution containing 10<sup>6</sup> cpm/ml of labeled pTGF $\beta$ 1 probe at 42°C for 16–18 h. After hybridization, filters were washed four times in 2XSSC and 0.1% SDS at room temperature for 5 min, twice in 0.1XSSC and 0.1% SDS at 55°C for 30 min. Then, Kodak x-ray film (Eastman Kodak Co., Rochester, NY) was exposed to filters at –70°C with intensifying screens.

Poly(A)<sup>+</sup> RNA was purified by oligo (dT)-cellulose (Pharmacia) chromatography from total RNA isolated from one allergic rhinitis tissue and one nasal polyp tissues by the lithium chloride method (19), and electrophoresed and hybridized as described above. We could not isolate poly(A)<sup>+</sup> RNA from normal nasal mucosa because normal mucosa was so small that we could not get total RNA enough to isolate poly(A)<sup>+</sup> RNA by this method.

**In situ hybridization.** In situ hybridization was performed as described by Tron et al. (20). Sections 2–3  $\mu$ m thick were cut and floated onto 3-aminopropyl triethoxysilane coated slides. They were dewaxed through xylene, rehydrated through an ethanol series, and pretreated with carbol chromotrope (1.25% chromotrope 2R in 1% phenol) for 30 min at room temperature. Slides were then immersed in a freshly prepared solution of 0.25% acetic anhydride in 0.1 M triethanolamine buffer (pH 8.0) at room temperature for 10 min followed by 10 min in 0.1 M glycine in 0.1 M Tris-HCl (pH 7.4), and dehydrated through an ethanol series. The hybridization solution contained the following:  $^{32}$ S-labeled pTGF $\beta$ 1 cDNA probe or DNA ladder (5X10<sup>5</sup> cpm/30 $\mu$ l), 0.2XSSC, 50% formamide, 0.5X Denhardt's solution, 10 mM dithiothreitol, salmon sperm DNA (1 mg/ml) and *Escherichia coli* tRNA (0.1 mg/ml). 30  $\mu$ l of this solution was applied to each slide, overlaid with a cover slip, and sealed with rubber cement. After incubation in a humidified chamber at 42°C for 14–16 h the cover slips were removed and the slides were washed at 42°C in 1XSSC/50% formamide for 30 min followed by washes in 0.1XSSC at room temperature for 10 min. Before autoradiography, slides were immersed in carbol chromotrope for 30 min to stain eosinophils (21). For autoradiography, slides were dipped in emulsion (Kodak NTB-2; Eastman Kodak, Rochester, NY) diluted 1:1 with distilled water and exposed at 4°C for 12–14 d. They were then developed (Kodak developer; Kodak Canada, Toronto, Canada), fixed (Kodak fixer; Kodak Canada) and counterstained with hematoxylin or hematoxylin/eosin.

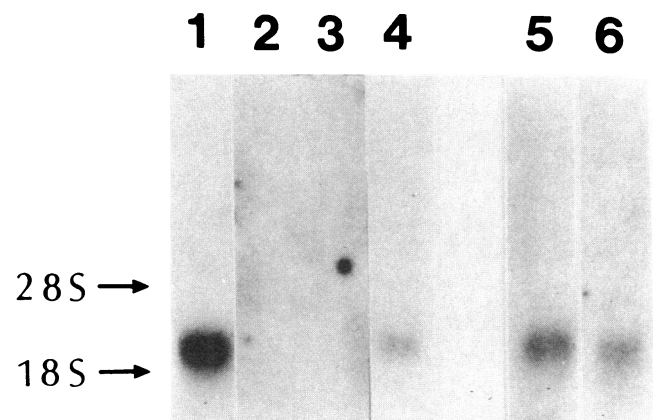
**Immunohistochemistry.** To examine the distribution of TGF $\beta$ 1 gene product in nasal polyp tissues, specific antibodies for TGF $\beta$ 1 and the avidin-biotin peroxidase technique were used as previously described (22). Briefly, after blocking of endogenous peroxidase in hydrogen peroxide/methanol, permeabilization with hyaluronidase and blocking with normal goat IgG, sections were incubated with a rabbit

antibody raised to a peptide corresponding to the first 30 amino acids of mature TGF $\beta$ 1 (LC 1-30) which was affinity purified against TGF $\beta$ 1. Then, sections were extensively washed and applied with biotinylated goat anti-rabbit IgG and avidin-peroxidase complex followed by visualization with 3,3' diaminobenzidine (Sigma Chemical Co., St. Louis, MO) and hydrogen peroxide and counterstaining with Mayer's hematoxylin. Controls included replacing the primary antibody with normal rabbit IgG at an equivalent concentration.

## Results

Fig. 1 illustrates a Northern blot probed with a porcine TGF $\beta$ 1 cDNA probe. Lane 1 was loaded with total RNA extracted from a human lung fibroblast culture stimulated with IL-1 $\alpha$  in vitro. A single 2.5-kb transcript was detected characteristic of TGF $\beta$ , subtype 1 (17, 23). No signal could be detected in total RNA extracted from normal nasal tissues (lanes 2 and 3). However, a positive signal at the 2.5-kb size was identified in total RNA from nasal polyp tissue (lane 4). In addition, the same 2.5-kb signal was seen in poly A<sup>+</sup> RNA from a second polyp specimen (lane 5) as well as from allergic rhinitis tissue (lane 6). Thus, we could visualize TGF $\beta$ 1 mRNA by Northern blot analysis in chronically inflamed tissues but not in normal nasal tissues.

To detect the presence of TGF $\beta$ 1 expressing cells in the normal nasal mucosa and in nasal polyps, tissue sections were subjected to in situ hybridization with the same TGF $\beta$ 1 cDNA probe used in the Northern analysis. Fig. 2 shows representative fields of nasal tissues. No positive cells could be seen with either the cDNA probe (Fig. 2 A) or a control DNA ladder (Fig. 2 B) in the normal nasal mucosa. In contrast, numerous cells with distinct clusters of silver grains indicating presence of



**Figure 1.** Northern blot analysis of RNA from nasal tissues with a porcine TGF $\beta$ 1 cDNA probe. 10  $\mu$ g of total RNA was loaded to lanes 1, 2, 3, and 4, and poly A<sup>+</sup> RNA isolated from 200  $\mu$ g of total RNA was loaded in lanes 5 and 6. An equal amount of RNA in lanes 1–4 was confirmed with the assessment of 28S and 18S ribosomal RNA stained with ethidium bromide after electrophoresis. RNA from cultured human lung fibroblasts stimulated with interleukin-1 $\alpha$  was used as a positive control (lane 1). Lanes 2 and 3 were loaded with RNA from normal nasal tissues. Lane 4 was loaded with RNA from a nasal polyp tissue. Lanes 5 and 6 were loaded with RNA from another nasal polyp and an allergic rhinitis tissue, respectively. A single 2.5-kb size transcript, characteristic of TGF $\beta$ 1 was detected in lanes 1, 4, 5, and 6, but not in lanes 2 and 3.



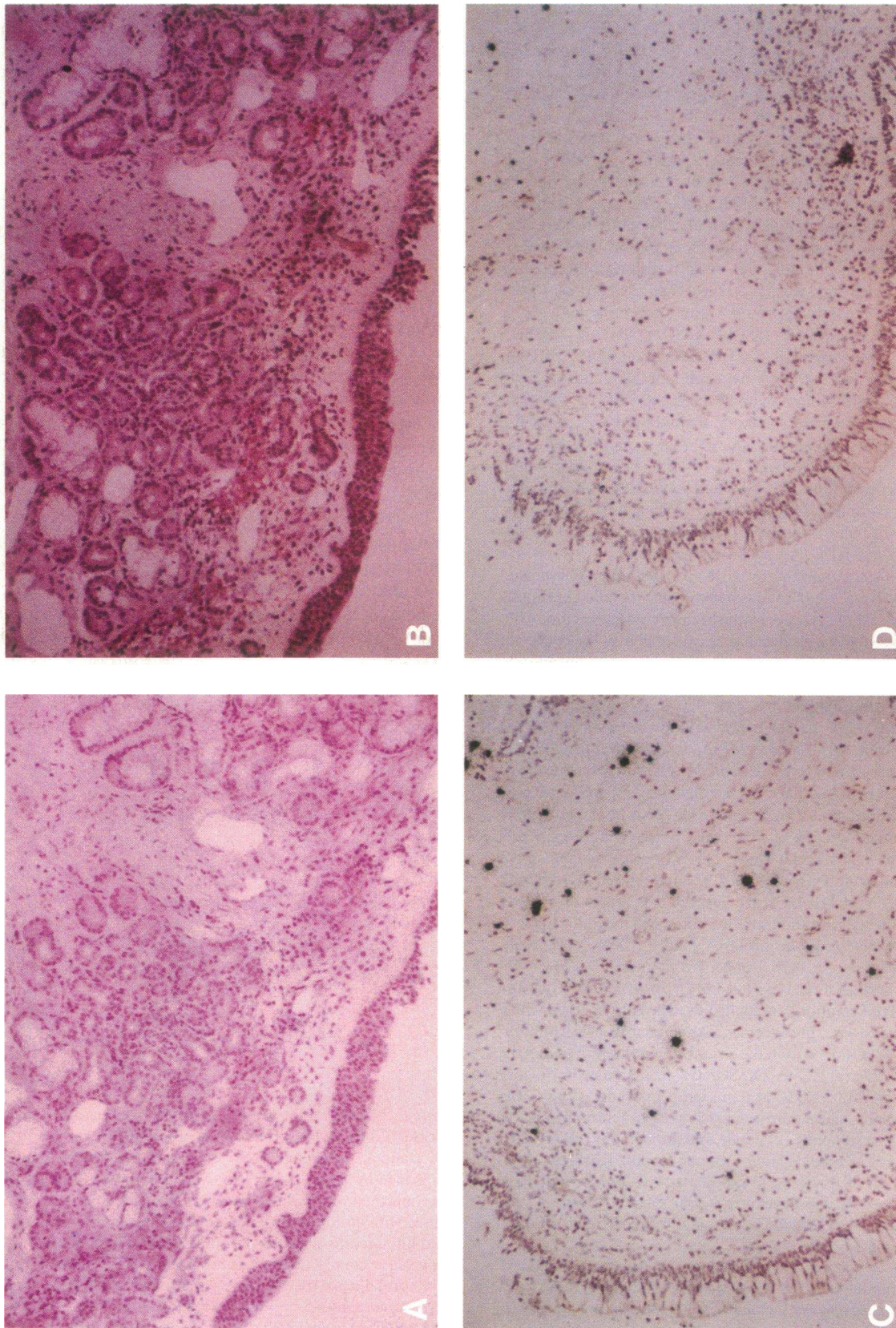


Figure 2. Autoradiogram of sections from a normal nasal tissue (A-B) and from a nasal polyp tissue (C-D). Sections were hybridized with a DNA ladder (B-D) or with porcine TGFβ1 cDNA probe (A-C). Note that a strong hybridization signal is seen only in C (polyp tissue hybridized with the TGFβ1 probe). (Magnification, 100).



TGF $\beta$ 1 mRNA transcripts were found in nasal polyp tissues hybridized with the TGF  $\beta$ 1 cDNA probe (Fig. 2 C) but not with the DNA ladder (Fig. 2 D). Similar observations were made in a nasal tissue obtained from a patient with allergic rhinitis (data not shown). Binding of the TGF $\beta$ 1 probe to these tissues was specific because pretreatment with chromotrope 2R, which has been shown to prevent nonspecific binding of DNA to cells, specifically eosinophils (24), blocked binding of the ladder but not of the TGF $\beta$ 1 probe.

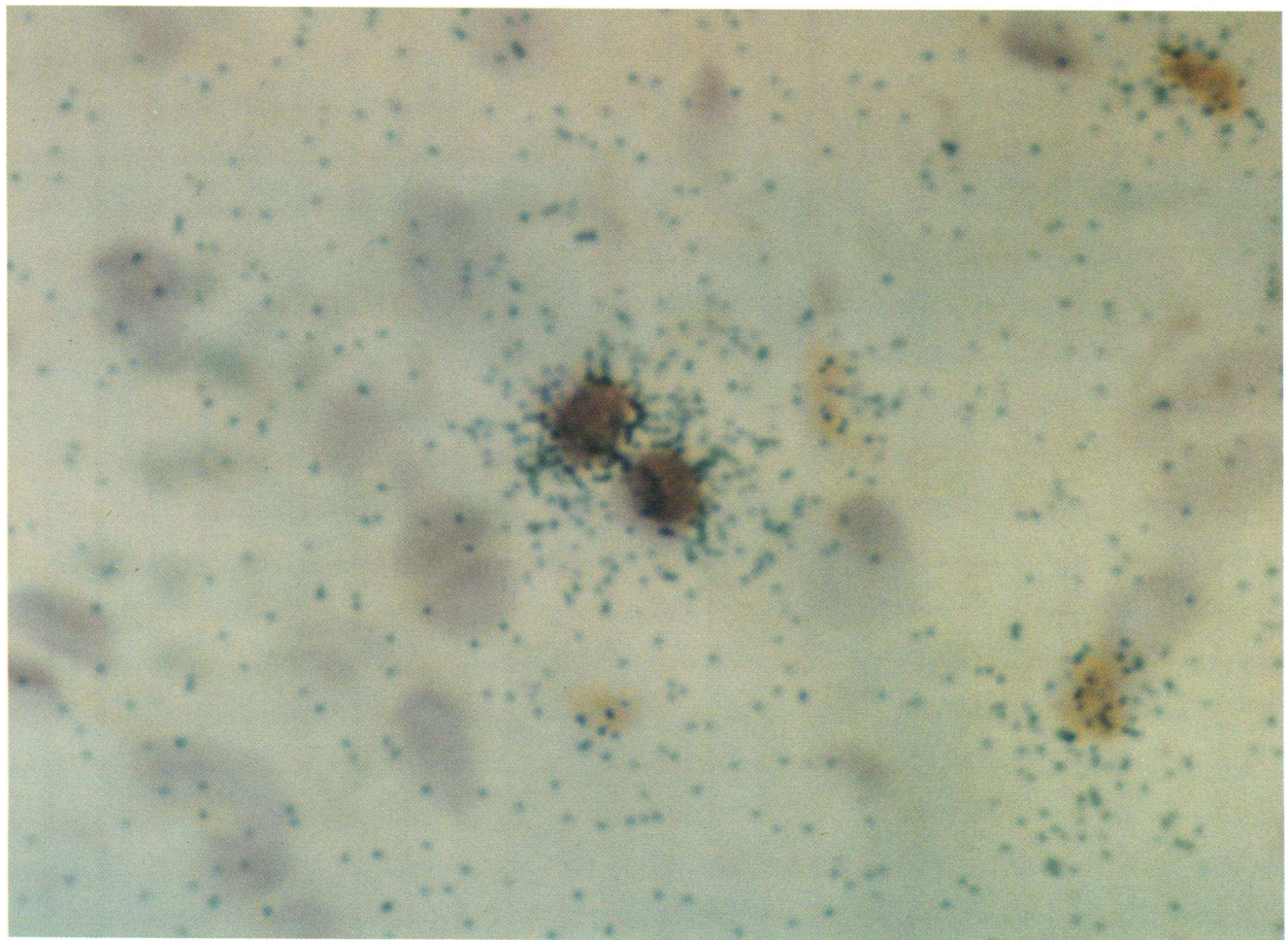
The distribution of TGF $\beta$ 1 expressing cells in nasal polyp tissues was reminiscent of the eosinophil distribution characteristic of these tissues. Therefore, it was reasonable to ask whether the cells expressing the TGF $\beta$ 1 gene in the polyp tissues were in fact eosinophils. To this end, we performed in situ hybridization in nasal polyp tissue sections stained, before autoradiography, with chromotrope 2R, a specific stain for eosinophils (21). As Fig. 3 shows most, if not all, positive cells for TGF $\beta$ 1 mRNA, were also stained with the chromotrope 2R. Conversely,  $\sim$  50% of the cells stained with the chromotrope 2R, were positive with in situ hybridization for TGF $\beta$ 1 mRNA.

Since the presence of TGF $\beta$ 1 mRNA in cells does not neces-

sarily indicate that TGF $\beta$ 1 protein is being released in situ, we also stained tissue sections with antibody raised against TGF $\beta$ 1 peptides. This antibody reacts with active TGF $\beta$ 1 but not with inactive precursor molecule. As shown in Fig. 4 A, anti-TGF $\beta$ 1 minimally stained normal nasal mucosa. In contrast, strong staining with this antibody was visualized in nasal polyp tissue (Fig. 4 C), and slight staining was seen when these tissues were stained with the control antibody (Fig. 4 B). In addition to localization in cells, substantial TGF $\beta$ 1 staining was noted in association with extracellular matrix structures (Fig. 4 D).

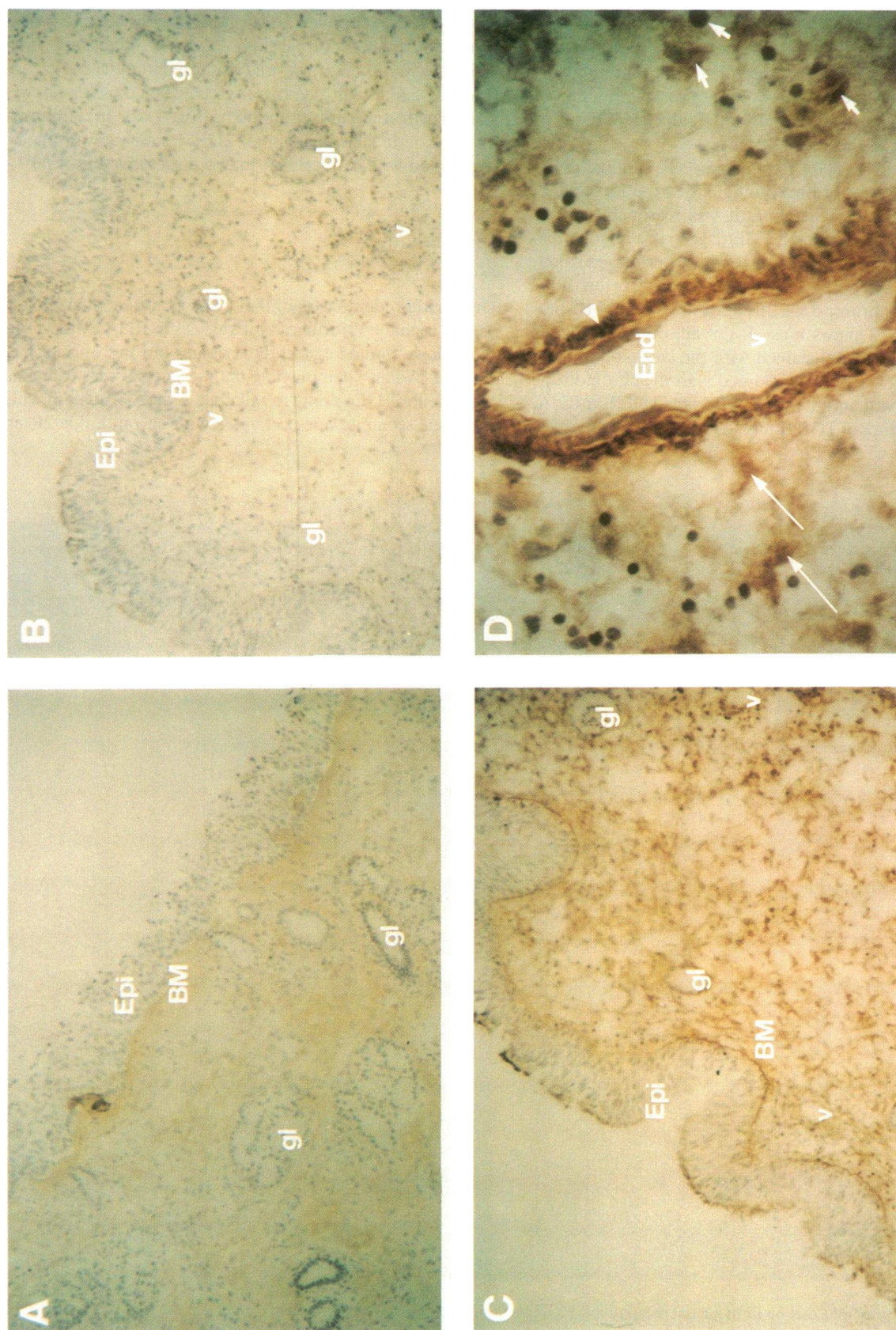
## Discussion

Our studies demonstrate the presence of a characteristic TGF $\beta$ 1 signal by Northern blot analysis in RNA extracts from nasal polyp and allergic rhinitis tissues but not normal nasal mucosa. We also demonstrate the presence of cells expressing the gene for TGF $\beta$ 1 only in inflamed tissues. Studies in which the tissue sections were pretreated with chromotrope 2R and



**Figure 3.** Autoradiogram of a section from a nasal polyp tissue. Example of sections which were pretreated with chromotrope 2R, hybridized with the TGF $\beta$ 1 cDNA probe, and counterstained with chromotrope 2R. Note a positive hybridization signal only on positively counterstained cells (eosinophils). (Magnification, 1,000).





**Figure 4.** Immunolocalization of TGFβ1 in nasal tissues. (A) A normal nasal mucosa stained with anti-TGFβ1 antibody. (B) A nasal polyp tissue stained with anti-TGFβ1 antibody. (C) The same tissue as in (B) with anti-TGFβ1 antibody. (D) High magnification of (C). Note the localization of immunoreactive TGFβ1 on basement membrane (Epi), perivascular extracellular matrix (arrow head) beneath endothelial cells (End) of a vessel (V), and extracellular matrix (long arrow) and infiltrating cells (short arrow) in the stroma in C and D. (gl, gland). (Magnification, 100 for A-C, 400 for D).



counterstained, after hybridization, with chromotrope 2R indicate that the TGF $\beta$ 1 probe bound almost exclusively to eosinophils. Approximately 50% of the eosinophils infiltrating the inflamed tissues were shown to express the TGF $\beta$ 1 gene. While macrophages, fibroblasts, and endothelial cells have been shown to produce TGF $\beta$ 1 in vitro, we could not detect TGF $\beta$ 1 gene expression in cells other than eosinophils in the tissues we studied. Whether this is indeed the case or, alternatively, the level of expression of the TGF $\beta$ 1 gene in these cells is below the level of detection of the technique currently used is uncertain.

Immunohistochemistry studies demonstrate that TGF $\beta$ 1 protein is produced in situ in nasal polyp tissues. It is interesting that in addition to localization in cells, a great deal of TGF $\beta$ 1 appears to be associated with the extracellular matrix. This pattern of distribution is similar to that recently described by Broekelmann et al. in lung tissue from patients with idiopathic pulmonary fibrosis, in which TGF $\beta$  was distinctly localized in macrophages by in situ hybridization while immunohistochemical studies demonstrated marked localization of the protein in the lung matrix (25). Our findings and those of Limper are consistent with the concepts recently described by Nathan and Sporn regarding cytokine/matrix relationships (26).

A feature of both nasal polyposis and idiopathic pulmonary fibrosis is the presence of varying degrees of fibrosis in the stroma as well as basement membrane thickening. It is thus tempting to suggest that TGF $\beta$  species might be directly involved in the development of these structural alterations. However, it must be emphasized that the ability of TGF $\beta$  to stimulate collagen deposition may be affected by the presence of other cytokines (27, 28). Hence, the presence of TGF $\beta$ , while probably necessary, may not be sufficient and further studies need be carried out to fully describe the cytokine profile in these tissues. In addition to its role in the regulation of extracellular matrix proteins production, TGF $\beta$  has a broad spectrum of inhibitory effects on lymphocytes (5), macrophages (29), neutrophils (30), and mast cells (31). Thus, our data pose interesting questions in regard to the role of eosinophil-derived TGF $\beta$ 1 in the regulation of the inflammatory response.

Production of cytokines represents a novel and important property of eosinophils. In addition to our data on TGF $\beta$ 1, Wong et al. have shown that eosinophils infiltrating colonic malignant tissues as well as peripheral blood eosinophils from patients with hypereosinophilic syndrome produce TGF $\alpha$  (32). We have recently had the opportunity to examine peripheral blood eosinophils from a patient with hypereosinophilic syndrome and have shown that they specifically hybridize with our TGF $\beta$ 1 cDNA probe but not with the DNA ladder (unpublished data). Furthermore, we have obtained evidence that eosinophils in nasal polyp tissues also express the gene for granulocyte macrophage-colony-stimulating factor (33). Therefore, the ability to release cytokines represents a new way by which eosinophils may contribute to the regulation of inflammatory and immunologic responses in airways tissues such as nasal polyposis, allergic rhinitis and, by extension, asthma.

## Acknowledgments

We are indebted to Drs. D. Hitch and P. Lapp from the ENT Department, Chedoke-McMaster Hospital, who provided us with tissues for study.

This work was supported by grants from the Medical Research Council of Canada (MT 6447 and MA 11015).

## References

- Connell, J. T. 1979. Nasal hypersensitivity. In *Comprehensive Immunology*. S. Gupta and R. A. Good, editors. Vol. 6. Plenum Publishing Corp., New York.
- Cauna, N., K. H. Hinderer, G. W. Manzetti, and E. W. Swanson. 1972. Fine structure of nasal polyps. *Ann. Otol. Rhinol. & Laryngol.* 81:41-58.
- Kakoi, H., and F. Hiraide. 1987. Histological study of formation and growth of nasal polyps. *Acta Otolaryngol.* 103:137-144.
- Roche, W. R., J. H. Williams, R. Beasley, and S. T. Holgate. 1989. Subepithelial fibrosis in the bronchi of asthmatics. *Lancet*. i:520-524.
- Barnard, J. A., R. M. Lyons, and H. L. Moses. 1990. The cell biology of transforming growth factor  $\beta$ . *Biochim. Biophys. Acta*. 1032:79-87.
- Moses, H. L., E. L. Branum, J. A. Proper, and R. A. Robinson. 1981. Transforming growth factor production by chemically transformed cells. *Cancer Res.* 41:2842-2848.
- Roberts, A. B., M. A. Anzano, L. C. Lamb, J. M. Smith, and M. B. Sporn. 1981. New class of transforming growth factors potentiated by epidermal growth factor: isolation from non-neoplastic tissues. *Proc. Natl. Acad. Sci. USA*. 78:5339-5343.
- Postlethwaite, A. E., J. Keski-Oja, H. I. Moses, and A. H. Kang. 1987. Stimulation of the chemotactic migration of human fibroblasts by transforming growth factor  $\beta$ . *J. Exp. Med.* 165:251-256.
- Hill, D. J., A. J. Strain, S. F. Elstow, I. Swenne, and R. D. G. Milner. 1986. Bi-functional action of transforming growth factor- $\beta$  on DNA synthesis in early passage human fetal fibroblasts. *J. Cell. Physiol.* 128:322-328.
- Ignatz, R. A., and J. Massague. 1986. Transforming growth factor- $\beta$  stimulates the expression of fibronectin and collagen and their incorporation into the extracellular matrix. *J. Biol. Chem.* 261:4337-4345.
- Ignatz, R. A., T. Endo, and J. Massague. 1987. Regulation of fibronectin and type I collagen mRNA levels by transforming growth factor- $\beta$ . *J. Biol. Chem.* 262:6443-6446.
- Edwards, R. E., G. Murphy, J. J. Reynolds, S. E. Whitham, A. J. P. Docherty, P. Angel, and J. K. Heath. 1987. Transforming growth factor beta modulates the expression of collagenase and metalloproteinase inhibitor. *EMBO (Eur. Mol. Biol. Organ.) J.* 6:1899-1904.
- Roberts, A. B., M. B. Sporn, R. K. Assoian, J. M. Smith, N. S. Roche, L. M. Wakefield, U. I. Heine, L. A. Liotta, V. Falanga, J. H. Kehrl, and A. S. Fauci. 1986. Transforming growth factor type  $\beta$ : rapid induction of fibrosis and angiogenesis in vivo and stimulation of collagen formation in vitro. *Proc. Natl. Acad. Sci. USA*. 83:4167-4171.
- Khalil, N., O. Berezney, M. Sporn, and A. H. Greenberg. 1989. Macrophage production of transforming growth factor  $\beta$  and fibroblast collagen synthesis in chronic pulmonary inflammation. *J. Exp. Med.* 170:727-737.
- Nakatsukasa, H., R. P. Everts, C. Hsia, and S. S. Thorgeirsson. 1990. Transforming growth factor- $\beta$ 1 and type I procollagen transcripts during regeneration and early fibrosis of rat liver. *Lab. Invest.* 63:171-180.
- Kulozik, M., A. Hogg, B. Lankat-Buttgereit, and T. Krieg. 1990. Co-localization of transforming growth factor  $\beta$ 2 with  $\alpha$ 1(I) procollagen mRNA in tissue sections of patients with systemic sclerosis. *J. Clin. Invest.* 86:917-922.
- Kondaiah, P., E. Van Obberghen-Schilling, R. L. Ludwig, R. Dhar, M. B. Sporn, and A. B. Roberts. 1988. cDNA cloning of porcine transforming growth factor- $\beta$ 1 mRNAs: evidence for alternate splicing and polyadenylation. *J. Biol. Chem.* 263:18313-18317.
- Chomczynski, P., and N. Sacchi. 1987. Single-step method of RNA isolation by acid guanidinium thiocyanate-phenol-chloroform extraction. *Anal. Biochem.* 162:156-159.
- Auffray, C., and F. Rougeon. 1980. Purification of mouse immunoglobulin heavy-chain messenger RNAs from total myeloma tumor RNA. *Eur. J. Biochem.* 107:303-314.
- Tron, V. A., C. B. Harley, D. Caussy, and D. N. Sauder. 1988. In situ detection of interleukin-1 mRNA in human monocytes. *Mol. Immunol.* 25:439-445.
- Lendrum, A. C. 1944. The staining of eosinophil polymorphs and enterochromaffin cells in histological sections. *J. Pathol. Bacteriol.* 56:441.
- Flanders, K. C., N. L. Thompson, D. S. Cissel, E. Van Obberghen-Schilling, C. C. Baker, M. E. Kass, L. R. Ellingsworth, A. R. Roberts, and M. B. Sporn. 1989. Transforming growth factor- $\beta$ 1: histochemical localization with antibodies to different epitopes. *J. Cell Biol.* 108:653-660.
- Barrett-Lee, P., M. Travers, Y. Luqmani, and R. C. Coombes. 1990. Transcripts for transforming growth factors in human breast cancer: clinical correlates. *Br. J. Cancer*. 61:612-617.
- Patterson, S., J. Gross, and A. D. B. Webster. 1989. DNA probes bind non-specifically to eosinophils during in situ hybridization: carbol chromotrope blocks binding to eosinophils but does not inhibit hybridization to specific nucleotide sequences. *J. Virol. Methods*. 23:105-109.

25. Broekelmann, T. J., A. H. Limper, T. V. Colby, and J. A. McDonald. 1991. Transforming growth factor  $\beta_1$  is present at sites of extracellular matrix gene expression in human pulmonary fibrosis. *Proc. Natl. Acad. Sci. USA*. 88:6642-6646.
26. Nathan, C., and M. Sporn. 1991. Cytokines in context. *J. Cell Biol.* 113:981-986.
27. Kahari, V., Y. Q. Chen, M. W. Su, F. Ramirez, and J. Uitto. 1990. Tumor necrosis factor- $\alpha$  and interferon- $\gamma$  suppress the activation of human type I collagen gene expression by transforming growth factor- $\beta_1$ : evidence for two distinct mechanisms of inhibition at the transcriptional and posttranscriptional levels. *J. Clin. Invest.* 86:1489-1495.
28. Narayanan, A. S., R. C. Page, and J. Swanson. 1989. Collagen synthesis by human fibroblasts: regulation by transforming growth factor- $\beta$  in the presence of other inflammatory mediators. *Biochem. J.* 260:463-469.
29. Nelson, B. J., P. Ralph, S. J. Green, and C. A. Nacy. 1991. Differential susceptibility of activated macrophage cytotoxic effector reactions to the suppressive effects of transforming growth factor- $\beta_1$ . *J. Immunol.* 146:1849-1857.
30. Gamble, J. R., and M. A. Vadas. 1988. Endothelial adhesiveness for blood neutrophils is inhibited by transforming growth factor- $\beta$ . *Science (Wash. DC)*. 242:97-99.
31. Broide, D. H., S. I. Wasserman, J. Alvaro-Gracia, N. J. Zvaifler, and G. S. Firestein. 1989. Transforming growth factor- $\beta_1$  selectively inhibits IL-3-dependent mast cell proliferation without affecting mast cell function or differentiation. *J. Immunol.* 143:1591-1597.
32. Wong, D. T. W., P. F. Weller, S. J. Galli, A. Elovic, T. H. Rand, G. T. Gallagher, T. Chaing, M. Y. Chou, K. Matossian, J. McBride, and R. Todd. 1990. Human eosinophils express transforming growth factor  $\alpha$ . *J. Exp. Med.* 172:673-681.
33. Ohno, I., R. Lea, S. Finotto, J. Marshall, J. Denburg, J. Dolovich, J. Gauldie, and M. Jordana. 1991. Granulocyte/macrophage colony-stimulating factor (GM-CSF) gene expression by eosinophils in nasal polyposis. *Am. J. Respir. Cell Mol. Biol.* 5:505-510.