

Peroxisomal bifunctional enzyme deficiency.

P A Watkins, ... , A B Moser, M E Beard

J Clin Invest. 1989;**83**(3):771-777. <https://doi.org/10.1172/JCI113956>.

Research Article

Peroxisomal function was evaluated in a male infant with clinical features of neonatal adrenoleukodystrophy. Very long chain fatty acid levels were elevated in both plasma and fibroblasts, and beta-oxidation of very long chain fatty acids in cultured fibroblasts was significantly impaired. Although the level of the bile acid intermediate trihydroxycoprostanic acid was slightly elevated in plasma, phytanic acid and L-pipecolic acid levels were normal, as was plasmalogen synthesis in cultured fibroblasts. The latter three parameters distinguish this case from classical neonatal adrenoleukodystrophy. In addition, electron microscopy and catalase subcellular distribution studies revealed that, in contrast to neonatal adrenoleukodystrophy, peroxisomes were present in the patient's tissues. Immunoblot studies of peroxisomal beta-oxidation enzymes revealed that the bifunctional enzyme (enoyl-CoA hydratase/3-hydroxyacyl-CoA dehydrogenase) was deficient in postmortem liver samples, whereas acyl-CoA oxidase and the mature form of beta-ketothiolase were present. Density gradient centrifugation of fibroblast homogenates confirmed that intact peroxisomes were present. Immunoblots of fibroblasts peroxisomal fractions showed that they contained acyl-CoA oxidase and beta-ketothiolase, but bifunctional enzyme was not detected. Northern analysis, however, revealed that mRNA coding for the bifunctional enzyme was present in the patient's fibroblasts. These results indicate that the primary biochemical defect in this patient is a deficiency of peroxisomal bifunctional enzyme. It is of interest that the phenotype of this patient resembled neonatal adrenoleukodystrophy and would not have been [...]

Find the latest version:

<https://jci.me/113956/pdf>



Peroxisomal Bifunctional Enzyme Deficiency

Paul A. Watkins,* Winston W. Chen,* Catharine J. Harris,† Gerald Hoefler,* Sigrid Hoefler,* Daniel C. Blake, Jr.,* Alan Balfe,* Richard I. Kelley,* Ann B. Moser,* Margaret E. Beard,‡ and Hugo W. Moser*

*The Kennedy Institute for Handicapped Children and Department of Neurology, Johns Hopkins University School of Medicine, Baltimore, Maryland 21205; †Cook County Hospital, Chicago, Illinois 60612; and ‡Department of Biological Sciences, Columbia University, New York, New York 10027

Abstract

Peroxisomal function was evaluated in a male infant with clinical features of neonatal adrenoleukodystrophy. Very long chain fatty acid levels were elevated in both plasma and fibroblasts, and beta-oxidation of very long chain fatty acids in cultured fibroblasts was significantly impaired. Although the level of the bile acid intermediate trihydroxycoprostanic acid was slightly elevated in plasma, phytanic acid and L-pipecolic acid levels were normal, as was plasmalogen synthesis in cultured fibroblasts. The latter three parameters distinguish this case from classical neonatal adrenoleukodystrophy. In addition, electron microscopy and catalase subcellular distribution studies revealed that, in contrast to neonatal adrenoleukodystrophy, peroxisomes were present in the patient's tissues.

Immunoblot studies of peroxisomal beta-oxidation enzymes revealed that the bifunctional enzyme (enoyl-CoA hydratase/3-hydroxyacyl-CoA dehydrogenase) was deficient in postmortem liver samples, whereas acyl-CoA oxidase and the mature form of beta-ketothiolase were present. Density gradient centrifugation of fibroblast homogenates confirmed that intact peroxisomes were present. Immunoblots of fibroblast peroxisomal fractions showed that they contained acyl-CoA oxidase and beta-ketothiolase, but bifunctional enzyme was not detected. Northern analysis, however, revealed that mRNA coding for the bifunctional enzyme was present in the patient's fibroblasts.

These results indicate that the primary biochemical defect in this patient is a deficiency of peroxisomal bifunctional enzyme. It is of interest that the phenotype of this patient resembled neonatal adrenoleukodystrophy and would not have been distinguished from this disorder by clinical study alone.

Introduction

Diseases such as the Zellweger cerebro-hepato-renal syndrome (1, 2), neonatal adrenoleukodystrophy (ALD; 3)¹, and infantile phytanic acid storage disease (4, 5), are characterized by a

Address all correspondence to Dr. Paul Watkins, Kennedy Institute, 707 N. Broadway, Baltimore, MD 21205.

Received for publication 8 August 1988 and in revised form 11 October 1988.

1. Abbreviations used in this paper: ALD, adrenoleukodystrophy; THCA, trihydroxycoprostanic acid; VLCFA, very long chain fatty acid.

J. Clin. Invest.

© The American Society for Clinical Investigation, Inc.

0021-9738/89/03/0771/07 \$2.00

Volume 83, March 1989, 771-777

decreased number or absence of peroxisomes in liver and other tissues. This group of diseases is referred to as disorders of peroxisome biogenesis. Multiple biochemical abnormalities, including impaired beta-oxidation of very long chain fatty acids (VLCFA) (6), impaired oxidation of phytanic acid (7) and pipecolic acid (8), decreased plasmalogen synthesis (9), and abnormal bile acid metabolism (10) are observed in these generalized peroxisomal disorders. Clinically, infants with these disorders are characterized by severe hypotonia, early onset of seizures, and psychomotor retardation (2-5, 11). Dysmorphic features, visual abnormalities, and hepatomegaly also are usually present. While neuronal migrational defects are present to varying degrees in most patients with generalized peroxisomal disorders, adrenal atrophy is more common in neonatal ALD, whereas renal microcysts and chondrodysplasia punctata are more characteristic of the Zellweger syndrome (2, 3).

Peroxisomal beta-oxidation of fatty acids, originally described by Lazarow and deDuve (12), is catalyzed by three enzymes that are immunologically distinct from the analogous mitochondrial enzymes (13). These enzymes (acyl-CoA oxidase, enoyl-CoA hydratase/3-hydroxyacyl-CoA dehydrogenase bifunctional enzyme, and peroxisomal beta-ketothiolase) catalyze the chain shortening of a variety of different fatty acyl-CoAs (14). This peroxisomal beta-oxidation system appears to be active toward saturated VLCFA (15, 16), and it is likely that impairment of this pathway is responsible for the elevated plasma and tissue VLCFA levels seen in these patients (15).

Recently several cases have been described in which peroxisomes were present in apparently normal numbers in tissues from patients originally given the diagnosis of either Zellweger syndrome or neonatal ALD. Goldfischer et al. (17) reported a case in which peroxisomal beta-oxidation and bile acid metabolism were abnormal while peroxisome abundance, plasmalogen synthesis, and phytanic acid oxidation were normal. Subsequently, evidence was found for a deficiency of the peroxisomal beta-ketothiolase in postmortem liver from this patient (18). Poll-The et al. (19) described two siblings with abundant, enlarged peroxisomes, abnormal VLCFA oxidation, and deficient acyl-CoA oxidase activity. We recently described a female infant of normal karyotype who exhibited decreased VLCFA oxidation, although peroxisomes were present and all other peroxisomal functions appeared to be normal (20). Immunoblot analysis of postmortem liver from this patient showed that all three peroxisomal beta-oxidation enzyme proteins were present in normal amount and molecular weight (20). We now describe another patient, originally diagnosed as neonatal ALD, whose tissues show a marked but isolated deficiency of bifunctional enzyme in the presence of apparently intact peroxisomes.

Methods

Clinical history

The patient was a 2,700-g (10th %ile) male infant born to a 19-yr-old black gravida 1, para 0 mother from the Bahamas after a 41-wk, uncomplicated pregnancy. The father was of American black ancestry and was not known to be related to the mother. The remainder of the family history was unremarkable. Birth by cesarian section for a double footling breech presentation was difficult due to an arrest of the head. Apgar scores were 4 and 7 at 1 and 5 min, respectively. At birth he was found to be hypotonic and macrocephalic (head circumference 37 cm = 90th %ile; length 47.5 cm = 50th %ile). At 2½ h of age the baby developed lip smacking, followed by twitching of the right eye and clonic movements of his upper extremities. The seizures were only poorly controlled with phenobarbital and dilantin. He was listless and hypotonic, with minimal spontaneous movement and depressed reflexes. An electroencephalogram showed frequent multifocal spikes. He required transient ventilatory support for the first 4 d of life.

By 6 wk he had made no developmental progress, continued to seize, remained hypotonic and macrocephalic (head circumference, 90th %ile; weight, 5th %ile), and was poorly responsive to stimuli. Fontanels were large and the metopic suture was split. Funduscopic examination was normal. The patient was not dysmorphic and showed no hepatosplenomegaly. Testicles were descended. Laboratory studies showed normal glucose, electrolytes, and acid-base status. Concentrations of lactate and pyruvate in blood were slightly elevated at 13 mg/dl (normal, 7–12) and 0.8 mg/dl (normal, 0.2–0.7), respectively. Levels of IgM, ammonia, insulin, growth hormone, TORCH titers, and cerebrospinal fluid protein were normal. Plasma amino acids, serum glutamic oxaloacetic transaminase, and serum glutamic pyruvic transaminase were normal. A random cortisol level was normal; adrenal stimulation tests were not performed. Serum iron and iron binding capacity were not measured. The visual evoked response and brainstem auditory evoked response tests were grossly abnormal. Muscle biopsy, nerve conduction velocity, electromyogram, CAT scan of the head, and skull x ray were all normal. A skeletal survey and renal ultrasound were also found to be normal. A brain biopsy at 6 wk revealed polymicrogyria. The convolutional gray matter had a wide first layer and the remainder of the cerebral cortex showed a paucity of nerve cells in a relatively normal distribution. The arcuate fibers showed no evidence of myelin; however, this finding may be age related. There was an unusually large number of ectopic neurons in the white matter. There were no cystic formations and no evidence of Rosenthal fibers.

Plasma VLCFA were measured at 3 mo and found to be markedly elevated (Table I). Urinary dicarboxylic acids were normal. His neurologic status remained unchanged and his seizures continued to be poorly controlled. He remained macrocephalic (75th %ile), with weight and length at the 5th %ile. Because of his severely depressed neurologic status, a feeding gastrostomy was placed. At 3½ mo he was found to have a fracture of his right femur without any history of antecedent trauma. A skeletal survey revealed generalized osteopenia and delayed bone maturation.

By 5 mo his neurologic status was still unchanged. There was no developmental progress and seizures remained frequent and difficult to control. A repeat funduscopic examination revealed none of the retinal changes characteristic of neonatal ALD and the Zellweger syndrome. At 5½ mo he developed fever and diarrhea and was found to be severely dehydrated. Soon after this he developed radiologic evidence of necrotizing enterocolitis with free air in the peritoneal cavity, air in the intestinal wall, and air in the biliary tree; he expired within 24 h.

Experimental procedures

Materials and general methods. Nycodenz and Maxidens were purchased from Accurate Chemical & Scientific Corp. (Westbury, NY). Cell culture reagents were from Gibco Laboratories (Grand Island, NY). [1-¹⁴C]Lignoceric acid (46 mCi/mmol) was purchased from Research Products International Corp. (Mt. Prospect, IL); [1-¹⁴C]palmitic acid (58 mCi/mmol) was from New England Nuclear (Boston, MA); [1-¹⁴C]phytanic acid (55 mCi/mmol), [1-¹⁴C]hexadecanol (11.4 mCi/mmol), and [¹²⁵I]iodine (30 mCi/ml) were from Amersham Corp. (Arlington Heights, IL); and [9,10-³H]-sn-hexadecylglycerol (5.5 mCi/mmol) was kindly provided by Dr. F. Paltauf, Technical University of Graz (Graz, Austria). Perdeuterated DL-pipecolic acid was purchased from MSD Isotopes Div. (Montreal, Quebec). All other reagents were of analytical grade and were obtained from commercial sources.

Antibodies against purified rat liver peroxisomal acyl-CoA oxidase, bifunctional enzyme, and beta-ketothiolase were the generous gift of Dr. Takashi Hashimoto, Shinshu University, Japan. Protein A was labeled with ¹²⁵I according to the procedure of Greenwood et al. (21). Catalase was assayed by the method of Peters et al. (22). Succinate dehydrogenase activity was measured by the method of Pennington (23). Protein was determined by the method of Lowry et al. (24) or by the method of Bradford (25).

Catalase cytochemistry. Slices of postmortem liver or confluent monolayers of cultured fibroblasts were fixed in 2.5% glutaraldehyde in 0.1 M sodium cacodylate, pH 7.4, washed with 0.1 M sodium cacodylate buffer containing 5% sucrose, and kept in this solution until cytochemical staining was performed. Sites of catalase activity were demonstrated using an alkaline diaminobenzidine method (26). Tissues were postfixated in 2% osmium tetroxide in water, dehydrated through a series of graded ethanols to propylene oxide, and embedded in epoxy resin (LX112; Ladd Research Industries, Inc., Burlington, VT). 50–70-nm sections were examined in an electron microscope (model 201; Philips Electronic Instruments, Inc., Mahwah, NJ) operating at 60–80 kV, either without further contrast staining or after staining with lead citrate.

VLCFA. Concentrations of VLCFA in fibroblasts and plasma were measured by gas-liquid chromatography as previously described (27, 28). Oxidation of [1-¹⁴C]lignoceric acid and [1-¹⁴C]palmitic acid to water-soluble products by cell suspensions was measured as described previously (29). The cholesterol ester fraction of postmortem brain and adrenal tissue was prepared as described by Jaffe et al. (30).

Biochemical assays of peroxisomal function. The subcellular distribution of catalase was measured in digitonin-treated fibroblasts as

Table I. Plasma and Fibroblast VLCFA Levels and Oxidation Rate

	Plasma		Fibroblast		VLCFA oxidation % of control
	C26:0 µg/ml	C26:0/C22:0 (1,900)*	C26:0 µg/mg protein	C26:0/C22:0 (525)	
Control	0.33±0.18 (1,900)*	0.01±0.01 (1,900)	0.07±0.04 (525)	0.08±0.03 (525)	(100) (8)
Patient T.C.	2.70†	0.22	0.45	1.63	12
Zellweger	3.61±1.38 (77)	0.49±0.14 (77)	0.53±0.28 (37)	1.34±0.72 (16)	<10 (3)
Neonatal ALD	2.14±0.71 (27)	0.30±0.14 (27)	0.40±0.15 (26)	1.05±0.46 (18)	<10 (10)

* Mean±SD; number of determinations in parentheses. † Mean of duplicate determinations.

previously described (31). Alpha-oxidation of [$1-^{14}\text{C}$]phytanic acid by cultured fibroblasts was measured by $^{14}\text{CO}_2$ production as previously described (31). The peroxisomal steps of plasmalogen biosynthesis were assessed by the double-label, double-substrate method of Roscher et al. (32). Trihydroxycoprostanic acid (THCA) concentration was determined by the method of Bjorkhem and Falk (33). L-Pipecolic acid levels were measured as described by Van den Berg et al. (34).

Subcellular fractionation of cultured fibroblasts. Skin fibroblasts were maintained in culture as previously described (28). For subcellular fractionation studies, confluent cells (6–8 100-mm culture dishes) were harvested by gentle trypsinization and collected by centrifugation. Harvested cells were washed once with PBS and once with 0.25 M sucrose containing 1 mM Tris(Cl^-), pH 7.0, and 0.1 mM EDTA. Cells were resuspended in this buffer, protease inhibitors were added, and cells were homogenized in a precision ball bearing homogenizer (35) using 10 passes. Protease inhibitors included (final concentrations) 100 μM benzamidine, 0.7 $\mu\text{g}/\text{ml}$ pepstatin, and 0.4 $\mu\text{g}/\text{ml}$ leupeptin. Homogenates (1.2–1.4 ml) were loaded directly onto a linear gradient (10 ml) of increasing Nycodenz concentration (15–40%) and decreasing sucrose concentration (0.25–0 M) that contained 1 mM Tris(Cl^-), pH 7.0, 0.1 mM EDTA, and the same protease inhibitors. A cushion (1.5 ml) of Maxidens was at the bottom of the tube. Gradients were centrifuged in a vertical ultracentrifuge rotor for 35 min at an average of 74,300 g_{avg} . Fractions of ~ 0.8 ml were collected from the bottom of the tube and assayed for marker enzyme activity.

Immunoblot analysis and RNA blot analysis. SDS-PAGE, immunoblot analysis, and autoradiography of postmortem liver samples were performed as described (29, 36). Fibroblast subcellular fractions were treated with ice-cold TCA to a final concentration of 10%. Fractions were diluted fivefold with additional 10% TCA and kept at 4°C overnight. Precipitates were collected by centrifugation, washed twice with diethyl ether, and solubilized for 5 min at 100°C in 80–160 μl of 67.5 mM Tris(Cl^-), pH 6.8, containing 1% SDS and 50 mM DTT. PAGE and immunoblot analysis were then carried out as for liver samples. RNA blot (Northern) analysis was performed on fibroblast cellular RNA using cDNA coding for the peroxisomal bifunctional enzyme as previously described (36).

Results

Autopsy findings. Postmortem examination revealed the cause of death to be bronchopneumonia and enteritis with patchy necrosis of the small bowel. The brain weighed 700 g (normal for body weight, 500 g). Examination of the brain revealed polymicrogyria, demyelination of the white matter in the cerebrum, focal areas of cortical heterotopia, a few foamy macrophages in the perivascular spaces, and cystic degeneration of the periventricular zones. The cerebellum appeared normal. The spinal cord showed mild demyelination of the cortico-spinal tracts. The eyes were not studied. The adrenal glands were small, having a combined weight of 0.5 g (normal, 3 g). Sections of the adrenal gland showed a normal medulla, loss of all three zones of the cortex, and replacement by one type of lipid-containing balloon cell. The thymus was notable only for the presence of small clusters of large lipid-laden macrophages in the cortex. The kidneys were normal size and had no gross cysts, but microscopically minute, glomerular cysts were present. The liver was mildly enlarged and revealed mild fibrosis in the portal area. No dysplastic bile canaliculi were noted. The remainder of the examination was unremarkable.

VLCFA. VLCFA levels were markedly elevated both in plasma and cultured fibroblasts from this patient (Table I). The C26:0 level and the C26:0/C22:0 ratio were 6- to 20-fold higher than age-matched controls and were in the range of patients with neonatal ALD and the Zellweger syndrome. The

Table II. Cholesterol Ester Fatty Acids in Postmortem Brain and Adrenal

	Brain			Adrenal		
	Patient T.C.	Control (n = 5)	Neonatal ALD (n = 4)	Patient T.C.	Control (n = 4)	Neonatal ALD (n = 4)
	% of total fatty acids					
C16:0	4.5*	16.1 \pm 7.5 \ddagger	8.0 \pm 6.8	13.5	14 \pm 10	13 \pm 16
C18:1	19.0	20.9 \pm 20.8	20.2 \pm 12.2	37.9	32 \pm 10	16 \pm 10
C24:0	4.7	4.8 \pm 5.1	6.9 \pm 4.1	11.0	0.20 \pm 0.12	16 \pm 10
C24:1	1.6	1.9 \pm 1.2	7.2 \pm 1.4	1.0	0.67 \pm 0.48	4.2 \pm 0.4
C26:0	11.3	0.81 \pm 0.85	4.2 \pm 1.8	12.5	0.03 \pm 0.02	26 \pm 14
C26:1	2.4	0.77 \pm 0.85	4.0 \pm 1.4	1.7	0.08 \pm 0.04	2.2 \pm 0.4

* Mean of duplicate determinations.

\ddagger Mean \pm SD.

plasma C26:1 level and the C26:1/C22:0 ratio were also elevated at 3.34 $\mu\text{g}/\text{ml}$ (normal, 0.29 \pm 0.19) and 0.22 (normal, 0.01 \pm 0.01), respectively. Beta-oxidation of VLCFA in cultured fibroblasts was significantly decreased, in agreement with the elevated plasma and fibroblast VLCFA levels (Table I). VLCFA accumulated in the cholesterol esters of brain and adrenal (Table II); this finding is similar to that observed in patients with neonatal ALD.

Peroxisomal structure. The subcellular distribution of catalase in digitonin-treated fibroblasts from this patient was normal, indicating that peroxisomal structure was intact (Table III). This finding was confirmed by density gradient fractionation studies (see below) and catalase cytochemistry studies. Peroxisomes were identified both in postmortem liver slices and in cultured fibroblasts from the patient by virtue of their catalase reactivity with diaminobenzidine (data not shown).

Biochemical assessment of other peroxisomal functions. Plasmalogen synthesis in cultured fibroblasts was normal (Table III). Although the oxidation of phytanic acid was somewhat decreased (Table III), it was significantly higher than that observed in typical neonatal ALD and the Zellweger syndrome, and the plasma phytanic acid level (measured at 3 mo) was normal at < 0.4 $\mu\text{g}/\text{ml}$. The plasma L-pipecolic acid level (measured at 4 mo) was normal (Table III). However, the level of the bile acid intermediate, THCA, was significantly elevated (Table III), suggesting that bile acid side chain oxidation in this patient was abnormal. As will be discussed below, this finding may be related to the abnormal VLCFA metabolism.

Immunoblot analysis of liver. Postmortem liver samples from this patient were analyzed using antibodies raised against the purified peroxisomal beta-oxidation enzymes. The bifunctional enzyme was not detectable in samples from this patient (Fig. 1). Both subunits of acyl-CoA oxidase were present in amount and size that was similar to normal controls (Fig. 1). Similarly, the peroxisomal beta-ketothiolase was detected in its mature form² both in control liver and in this patient (Fig. 1).

2. Peroxisomal beta-ketothiolase is synthesized as a 44-kD precursor that is proteolytically processed to form the mature 41-kD enzyme (37).

Table III. Biochemical Assessment of Peroxisomal Function

	Fibroblast			Plasma	
	Catalase subcellular distribution	Plasmalogen synthesis ($^3\text{H}/^{14}\text{C}$)	Phytanic acid oxidation	Pipecolic acid	THCA
	% soluble		% of control	μM	μM
Control	10 \pm 3 (5)*	0.62 \pm 0.16 (28)	100 (10)	2.0 \pm 0.8 (114)	Not detectable
Patient T.C.	13 [†]	0.70	36	2.3	8.8
Zellweger	90 \pm 7 (21)	10.4 \pm 2.8 (6)	1.4 \pm 1.3 (11)	9.7 \pm 3.1 (9)	11.4 \pm 5.2 (5)
Neonatal ALD	87 \pm 8 (16)	4.66 \pm 1.63 (10)	4.6 \pm 4.8 (5)	65 \pm 63 (19)	10.9 \pm 14.6 (11)

Fibroblast catalase subcellular distribution, plasmalogen synthesis, and phytanic acid oxidation, and plasma pipecolic acid and THCA levels were measured as described in Methods. For plasmalogen synthesis, a high ratio of $^3\text{H}/^{14}\text{C}$ indicates defective peroxisomal enzyme(s).

* Mean \pm SD; number of determinations in parentheses. [†] Mean of duplicate determinations.

Thus, it is likely that a lack of bifunctional enzyme is responsible for defective VLCFA oxidation in this patient.

Subcellular fractionation of fibroblasts. To verify that the absence of bifunctional enzyme in liver was not an artifact of postmortem autolysis, fibroblasts were fractionated on continuous Nycodenz gradients and analyzed by immunoblot. Total fibroblast homogenates rather than postnuclear supernates were loaded onto the gradients to minimize loss of enzyme protein. Peroxisomes and mitochondria were resolved well on the gradients, as indicated by the separation of the activities of marker enzymes catalase (peroxisomes) and succinate dehydrogenase (mitochondria; Fig. 2). Little catalase activity was observed at the top (fractions 13 and 14) of gradients, indicating that peroxisomes were intact both in the patient's cells and in control fibroblasts.

Immunoblot analysis of fractionated fibroblasts from the patient revealed that two of the peroxisomal beta-oxidation enzymes, acyl-CoA oxidase and beta-ketothiolase, were present in subcellular fractions enriched in catalase activity (Fig. 3). Similarly, these enzymes were present in peroxisome-rich

fractions of control fibroblasts (data not shown). In agreement with the liver findings, bifunctional enzyme protein in the patient's fibroblasts was below the limit of detection of the immunoblot analysis, whereas this enzyme was clearly present in peroxisomal fractions of control fibroblasts (Fig. 3).

RNA blot analysis. To determine if the absence of bifunctional enzyme in liver samples and in fibroblast peroxisomal fractions were due to a defect in transcription, RNA blot analysis was performed. Bifunctional enzyme mRNA was detected in total cellular RNA preparations from this patient using a 2.3-kb rat bifunctional enzyme cDNA as a probe (Fig. 4). The size and amount of mRNA in fibroblasts from the patient were the same as in control cells (Fig. 4), which is similar to that previously reported for neonatal ALD (36).

Discussion

The original clinical diagnosis of neonatal ALD in this patient was supported by elevated plasma VLCFA levels. However, this case differs from classical neonatal ALD because results of microscopic examination and subcellular distribution of catalase indicate that peroxisomal structure was intact. Furthermore, unlike neonatal ALD, there was no abnormality of

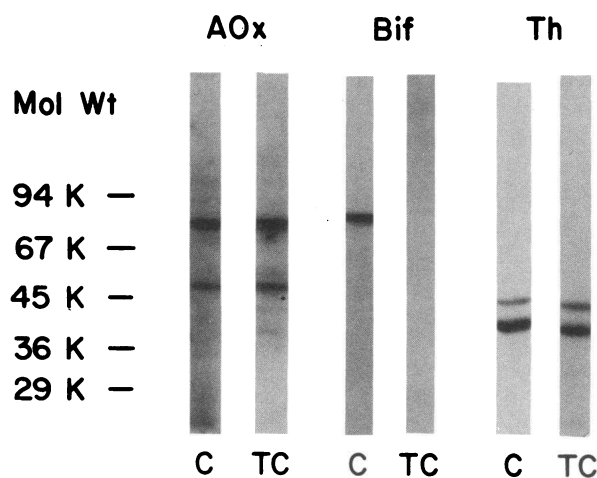


Figure 1. Immunoblot analysis of postmortem liver for peroxisomal beta-oxidation enzymes. Postmortem liver samples, stored at -70°C , were analyzed for the presence of the peroxisomal beta-oxidation enzymes acyl-CoA oxidase (AOx), bifunctional enzyme (Bif), and beta-ketothiolase (Th) using antibodies raised against the purified rat liver enzymes. C, normal control liver; TC, liver from patient T.C. The positions of molecular weight markers are at left.

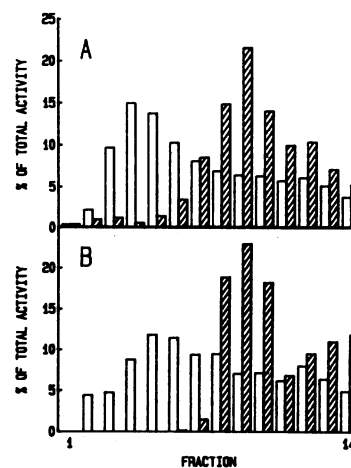


Figure 2. Subcellular fractionation of fibroblasts on Nycodenz-sucrose gradients. Fibroblast homogenates were fractionated as described in Methods. Fractions of 0.8 ml were collected from the bottom of the tube and analyzed for activity of the marker enzymes catalase (open bars) and succinate dehydrogenase (hatched bars). Activities are expressed as percent of total activity across the gradient. (A) control fibroblasts; (B) fibroblasts from patient T.C.

Fractions enriched in catalase activity (peroxisomes) were well separated from those enriched in succinate dehydrogenase activity (mitochondria) in gradients of both control cells and the patient's cells.

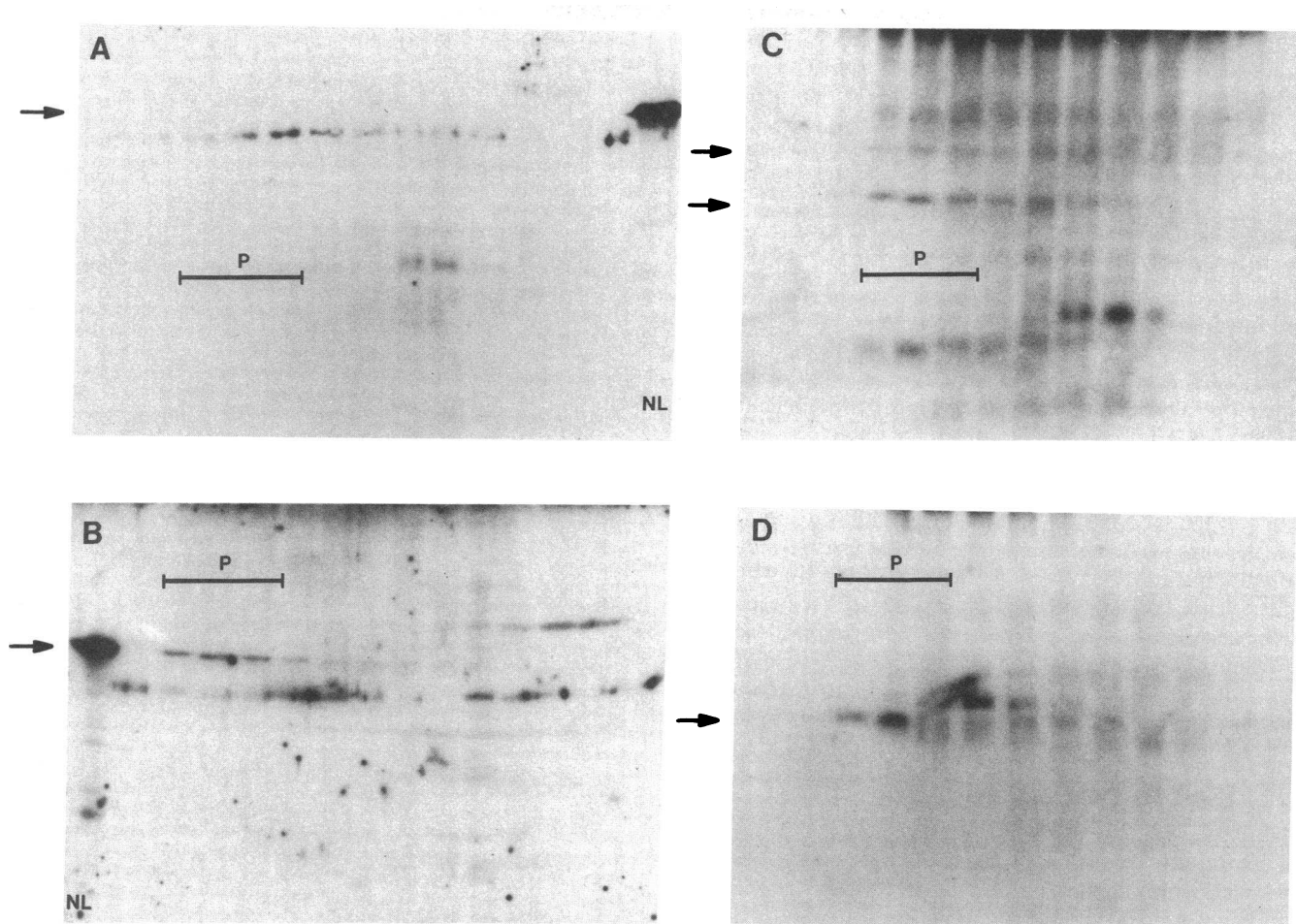


Figure 3. Immunoblot analysis of fibroblast fractions. Fibroblasts from the patient (T.C.) and a normal control were fractionated as in Fig. 2 and subjected to immunoblot analysis as described in Methods. (A) patient T.C. fibroblast bifunctional enzyme; (B) control fibroblast bifunctional enzyme; (C) patient T.C. acyl-CoA oxidase; (D) patient T.C. beta-ketothiolase. Arrows at left indicate the positions of each enzyme. The bar labeled P indicates fractions enriched in the peroxisomal marker enzyme catalase. Samples of normal human liver (NL) were included in A and B as reference standards. A was a 12.5% polyacrylamide gel; B, C, and D were 10% gels.

plasmalogen, phytanic acid, or pipecolic acid metabolism. Of greatest interest is the finding that immunoblot studies showed the absence of only one of the peroxisomal beta-oxidation enzymes, bifunctional enzyme, while the other two enzymes were present in apparently normal quantity. Unlike Zellweger

syndrome and neonatal ALD, peroxisomal beta-ketothiolase was present in mature form.

Although the bifunctional enzyme protein was not detectable in liver and fibroblasts, bifunctional enzyme mRNA was clearly present in cellular RNA preparations. This result is similar to our previous observations about fibroblasts from classical neonatal ALD patients (36). However, in the latter disorder peroxisome structure is defective and patients exhibit multiple biochemical defects (3, 38); it is unlikely, therefore, that bifunctional enzyme deficiency would be a primary defect in neonatal ALD. For the present case our results suggest that bifunctional enzyme protein deficiency is caused either by defective translation of the mRNA or by abnormal posttranslational enzyme processing. It has been established that most peroxisomal enzymes, including bifunctional enzyme, are synthesized in the cytosol on free polyribosomes (39), after which they enter peroxisomes by an unknown mechanism. Absence of the enzyme protein could thus result from a defect in one of these steps.

Peroxisomal functions other than VLCFA oxidation appeared to be intact in this patient, with the exception of an elevated THCA level. The level of this bile acid intermediate was increased to the same extent as that observed in both the

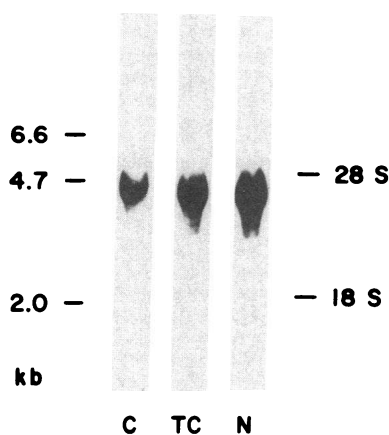


Figure 4. RNA blot (Northern) analysis of fibroblasts. RNA blot analysis was performed using cellular RNA from control fibroblasts and cells from patient T.C. as described in Methods. C, control fibroblasts; TC, fibroblasts from patient T.C.; N, neonatal ALD fibroblasts. Molecular size markers (kb) are on the left and sedimentation coefficients are on the right.

Zellweger syndrome and neonatal ALD. Conversion of THCA to the bile acid, cholic acid, requires the processing of the steroid side chain via a peroxisomal pathway that is homologous to, and perhaps identical to, the beta-oxidation pathway (40, 41). Thus, a deficiency of one of the peroxisomal beta-oxidation enzymes might be expected to result in elevated THCA levels. Oxidation of phytanic acid was also somewhat decreased in this patient. However, this decrease was apparently insufficient to produce increased plasma phytanate levels. Furthermore, the rate of phytanic acid oxidation was significantly higher than the 1–5% of control observed in neonatal ALD and Zellweger syndrome.

It is instructive to compare the clinical and morphological features of this case with those of Zellweger syndrome and neonatal ALD, since certain features (e.g., brain alterations and renal microcysts) are more often associated with the former, whereas other signs (e.g., severe adrenal atrophy) are more characteristic of the latter. The adrenal involvement was similar to that observed in both X-linked and neonatal forms of ALD. This is not surprising since adrenal insufficiency was probably caused directly by the accumulation of VLCFA, which is common to all three disorders. Unlike Zellweger syndrome and neonatal ALD, there were no dysmorphic features, no demonstrable ocular involvement, and no liver dysfunction. Unlike most cases of Zellweger syndrome, there was no aberrant calcification, and renal cystic changes were minimal. The relative sparing of these organ systems may reflect the more restricted biochemical defect in this patient than in the disorders of peroxisome biogenesis. In sharp contrast to the relative sparing of these organs is the profound involvement of the central nervous system. The patient suffered from intractable seizures throughout life, failed to achieve any psychomotor milestones, and showed a striking defect in neuronal migration. These central nervous system abnormalities, which are equal in severity to those of Zellweger syndrome, suggest that an isolated defect in fatty acid metabolism plays a role in the etiology of these serious systemic defects. This possibility is supported by the existence of similar severe nervous system developmental dysfunction in other single-enzyme defects of peroxisomal VLCFA metabolism, namely, beta-ketothiolase deficiency (17, 18) and acyl-CoA oxidase deficiency (19), and in a female patient with an unidentified defect of VLCFA oxidation (20).

Acknowledgments

The authors wish to thank Dr. Takashi Hashimoto for his generous gift of antibodies to acyl-CoA oxidase, bifunctional enzyme, and beta-ketothiolase; Dr. F. Paltauf for his generous gift of [9,10-³H]-sn-hexadecylglycerol; and Dr. Ingemar Bjorkhem for measurement of plasma THCA levels.

This work was supported in part by grant HD-10981 from the U. S. Public Health Service. Dr. Hoefler is supported by the Fonds zur Foerderung der Wissenschaftlichen Forschung, project J0145M, Dr. Hoefler by a Fulbright Scholarship, and Dr. Balfe by International Research Fellowship TW03908 from the Fogarty International Center, National Institutes of Health.

References

- Goldfischer, S., C. L. Moore, A. B. Johnson, A. J. Spiro, M. P. Valsamis, H. K. Wisniewski, R. H. Ritch, W. T. Norton, I. Rapin, and L. M. Gartner. 1973. Peroxisomal and mitochondrial defects in the cerebro-hepato-renal syndrome. *Science (Wash. DC)*. 182:62–64.
- Kelley, R. I. 1983. The cerebro-hepato-renal syndrome of Zellweger: morphologic and metabolic aspects. *Am. J. Med. Genet.* 16:503–517.
- Kelley, R. I., N. S. Datta, W. B. Dobyns, A. K. Moser, M. J. Noetzel, E. H. Zackai, and H. W. Moser. 1986. Neonatal adrenoleukodystrophy: new cases, biochemical studies, and differentiation from Zellweger and related peroxisomal polydystrophy syndromes. *Am. J. Med. Genet.* 23:869–901.
- Scotto, J. M., M. Hadchouel, M. Odievre, M. H. Laudat, J. M. Saudubray, O. Dulac, I. Beucler, and F. Beaune. 1982. Infantile phytanic acid storage disease, a possible variant of Refsum's disease: three cases, including studies of the liver. *J. Inherited Metab. Dis.* 5:83–90.
- Poll-The, B. T., J. M. Saudubray, H. Ogier, R. B. H. Schutgens, R. J. A. Wanders, G. Schrakamp, H. van den Bosch, J. M. F. Trybels, A. Poulos, H. W. Moser, J. van Eldere, and H. J. Eyssen. 1986. Infantile Refsum's disease: biochemical findings suggesting multiple peroxisomal dysfunction. *J. Inherited Metab. Dis.* 9:169–174.
- Moser, A. E., I. Singh, F. R. Brown III, G. I. Solish, R. I. Kelley, P. J. Benke, and H. W. Moser. 1984. The cerebro-hepato-renal (Zellweger) syndrome: increased levels and impaired degradation of very-long-chain fatty acids and their use in prenatal diagnosis. *N. Engl. J. Med.* 310:1141–1146.
- Poulos, A., P. Sharp, A. J. Fellenberg, and D. M. Danks. 1985. Cerebro-hepato-renal (Zellweger) syndrome, adrenoleukodystrophy and Refsum's disease: plasma changes and skin fibroblast phytanic acid oxidase. *Hum. Genet.* 70:172–177.
- Danks, D. M., P. Tippett, C. Adams, and P. Campbell. 1975. Cerebro-hepato-renal syndrome of Zellweger: a report of eight cases with comments upon the incidence, the liver lesion, and a fault in pipecolic acid metabolism. *J. Pediatr.* 86:382–387.
- Datta, N. S., G. N. Wilson, and A. K. Hajra. 1984. Deficiency of enzymes catalyzing the biosynthesis of glycerol-ether lipids in Zellweger syndrome: a new category of metabolic disease involving the absence of peroxisomes. *N. Engl. J. Med.* 311:1080–1083.
- Monnens, L., J. Bakkeren, G. Parmetier, G. Jaussen, U. van Haelst, F. Trijbels, and H. Eyssen. 1980. Disturbances in bile acid metabolism of infants with the Zellweger (cerebro-hepato-renal) syndrome. *Eur. J. Pediatr.* 133:31–35.
- Moser, H. W. 1987. New approaches in peroxisomal disorders. *Dev. Neurosci.* 9:1–18.
- Lazarow, P. B., and C. deDuve. 1976. A fatty acyl-CoA oxidizing system in rat liver peroxisomes: enhancement by clofibrate, a hypolipidemic drug. *Proc. Natl. Acad. Sci. USA.* 73:2043–2046.
- Hashimoto, T. 1982. Individual peroxisomal beta-oxidation enzymes. *Ann. NY Acad. Sci.* 386:5–12.
- Lazarow, P. B. 1978. Rat liver peroxisomes catalyze the beta-oxidation of fatty acids. *J. Biol. Chem.* 253:1522–1528.
- Singh, I., A. E. Moser, S. Goldfischer, and H. W. Moser. 1984. Lignoceric acid is oxidized in the peroxisome: implications for the Zellweger cerebro-hepato-renal syndrome and adrenoleukodystrophy. *Proc. Natl. Acad. Sci. USA.* 81:4203–4207.
- Singh, H., N. Derwas, and A. Poulos. 1987. Very long chain fatty acid beta-oxidation by rat liver mitochondria and peroxisomes. *Arch. Biochem. Biophys.* 259:382–390.
- Goldfischer, S. L., J. Collins, I. Rapin, P. Neumann, W. Neglia, A. J. Spiro, T. Ishii, F. Roels, F. Vamecq, J. Vamecq, and F. Van Hoof. 1986. Deficiencies in several peroxisomal oxidative activities. *J. Pediatr.* 108:25–32.
- Schram, A. W., S. Goldfischer, C. W. T. van Roermund, E. M. Brouwer-Kelder, J. Collins, T. Hashimoto, H. S. A. Heymans, H. van den Bosch, R. B. H. Schutgens, J. M. Tager, and R. J. A. Wanders. 1987. Human peroxisomal 3-oxoacyl-coenzyme A thiolase deficiency. *Proc. Natl. Acad. Sci. USA.* 84:2494–2496.
- Poll-The, B. T., F. Roels, H. Ogier, J. Scotto, J. Vamecq, R. B. H. Schutgens, R. J. A. Wanders, C. W. T. van Roermund, M. J. A. van Wijland, A. W. Schram, J. M. Tager, and J. M. Saudubray. 1988. A new peroxisomal disorder with enlarged peroxisomes and a specific deficiency of acyl-CoA oxidase (pseudo-neonatal adrenoleukodystrophy). *Am. J. Hum. Genet.* 42:422–434.

20. Naidu, S., G. Hoefler, P. A. Watkins, W. W. Chen, A. B. Moser, S. Hoefler, N. E. Rance, J. M. Powers, M. Beard, W. R. Green, T. Hashimoto, and H. W. Moser. 1988. Neonatal seizures and retardation in a female with biochemical features of X-linked adrenoleukodystrophy: a possible new peroxisomal disease entity. *Neurology*. 38:1100-1107.
21. Greenwood, F. C., W. M. Hunter, and J. S. Glover. 1963. The preparation of ¹³¹I-labelled human growth hormone of high specific radioactivity. *Biochem. J.* 89:114-123.
22. Peters, T. J., M. Muller, and C. de Duve. 1972. Lysosomes of the arterial wall. I. Isolation and subcellular fractionation of cells from normal rabbit aorta. *J. Exp. Med.* 136:1117-1139.
23. Pennington, R. J. 1961. Biochemistry of dystrophic muscle: mitochondrial succinate-tetrazolium reductase and adenosine triphosphatase. *Biochem. J.* 80:649-654.
24. Lowry, O. H., N. J. Rosebrough, A. L. Farr, and R. J. Randall. 1951. Protein measurement with the Folin phenol reagent. *J. Biol. Chem.* 193:265-275.
25. Bradford, M. M. 1976. A rapid and sensitive method for the quantitation of microgram quantities of protein using the principle of protein-dye binding. *Anal. Biochem.* 72:248-254.
26. Beard, M. E., A. B. Moser, V. Sapirstein, and E. Holtzman. 1986. Peroxisomes in infantile phytanic acid storage disease. *J. Inherited Metab. Dis.* 9:321-334.
27. Moser, H. W., A. B. Moser, K. K. Frayer, W. Chen, J. D. Schulman, B. P. O'Neill, and Y. Kishimoto. 1981. Adrenoleukodystrophy: increased plasma content of saturated very long chain fatty acids. *Neurology*. 31:1241-1249.
28. Moser, H. W., A. B. Moser, N. Kawamura, J. Murphy, K. Suzuki, H. Schaumburg, Y. Kishimoto, and A. Milunsky. 1980. Adrenoleukodystrophy: elevated C26 fatty acid in cultured skin fibroblasts. *Ann. Neurol.* 7:542-549.
29. Hoefler, G., S. Hoefler, P. A. Watkins, W. W. Chen, A. Moser, V. Baldwin, B. McGillivray, J. Charrow, J. M. Friedman, L. Rutledge, T. Hashimoto, and H. W. Moser. 1988. Biochemical abnormalities in rhizomelic chondrodysplasia punctata. *J. Pediatr.* 112:726-733.
30. Jaffe, R., P. Crumrine, Y. Hashida, and H. W. Moser. 1982. Neonatal adrenoleukodystrophy: clinical, pathologic, and biochemical delineation of a syndrome affecting both males and females. *Am. J. Pathol.* 108:100-111.
31. Lazarow, P. B., Y. Fujika, G. M. Small, P. Watkins, and H. Moser. 1986. Presence of the peroxisomal 22-k Da integral membrane protein in the liver of a person lacking recognizable peroxisomes (Zellweger syndrome). *Proc. Natl. Acad. Sci. USA.* 87:9193-9197.
32. Roscher, A., B. Molzer, H. Bernheimer, S. Stockler, I. Mutz, and F. Paltauf. 1985. The cerebro-hepato-renal (Zellweger) syndrome: an improved method for the biochemical diagnosis and its potential for prenatal diagnosis. *Pediatr. Res.* 19:930-933.
33. Bjorkhem, I., and O. Falk. 1983. Assay of the major bile acids in serum by isotope dilution—mass spectrometry. *Scand. J. Clin. Lab. Invest.* 43:163-170.
34. Van den Berg, C. A., H. Breukelman, H. Elzinga, J. M. F. Trijbels, L. A. H. Monnens, and F. A. J. Muskiet. 1986. Determination of pipercolic acid in urine and plasma by isotope dilution mass fragmentography. *Clin. Chim. Acta.* 159:229-237.
35. Balch, W. E., and J. E. Rothman. 1985. Characterization of protein transport between successive compartments of the Golgi apparatus: asymmetric properties of donor and acceptor activities in a cell-free system. *Arch. Biochem. Biophys.* 240:413-425.
36. Chen, W. W., P. A. Watkins, T. Hashimoto, and H. W. Moser. 1987. Peroxisomal beta-oxidation enzymes in adrenoleukodystrophy. *Proc. Natl. Acad. Sci. USA.* 84:1425-1428.
37. Miura, S., M. Mori, M. Takiguchi, M. Tatibana, S. Furuta, S. Miyazawa, and T. Hashimoto. 1984. Biosynthesis and intracellular transport of enzymes of peroxisomal beta-oxidation. *J. Biol. Chem.* 259:6397-6402.
38. Goldfischer, S., J. Collins, I. Rapin, B. Coltoff-Schiller, C. H. Chang, M. Nigro, V. H. Black, N. B. Javitt, H. W. Moser, and P. B. Lazarow. 1985. Peroxisomal defects in neonatal onset and X-linked adrenoleukodystrophies. *Science (Wash. DC).* 227:67-70.
39. Rachubinski, R. A., Y. Fujiki, R. M. Mortensen, and P. B. Lazarow. 1984. Acyl-CoA oxidase and hydratasedehydrogenase, two enzymes of the peroxisomal beta-oxidation system, are synthesized on free polysomes of clofibrate-treated rat liver. *J. Cell Biol.* 99:2141-2146.
40. Kase, F., I. Bjorkhem, and J. I. Pedersen. 1983. Formation of cholic acid from 3a, 7a, 12a-thihydroxy-5B-cholestanic acid by rat liver peroxisomes. *J. Lipid Res.* 24:1560-1567.
41. Hayashi, H., K. Fukui, and F. Yamasaki. 1984. Association of the liver peroxisomal fatty acyl-CoA B-oxidation system with the synthesis of bile acids. *J. Biochem. (Tokyo).* 96:1713-1719.