

## **Hypobetalipoproteinemia with accumulation of an apoprotein B-like protein in intestinal cells. Immunoenzymatic and biochemical characterization of seven cases of Anderson's disease.**

M E Bouma, ... , R Infante, J Schmitz

*J Clin Invest.* 1986;**78**(2):398-410. <https://doi.org/10.1172/JCI112590>.

### **Research Article**

We describe here seven cases (from five kindreds) of Anderson's disease, which is characterized by diarrhea, steatorrhea, hypobetalipoproteinemia with low levels of cholesterol, triglycerides, and phospholipids, and failure to secrete chylomicrons after a fat meal. Enterocytes isolated from intestinal biopsies of patients after overnight fast showed numerous fat droplets, a histological picture resembling that of abetalipoproteinemia. Immunoenzymatic staining of the enterocytes demonstrated large amounts of material that reacted with a polyclonal antiserum to apolipoprotein B. Further, the immunoreactive material was found to react with several different monoclonal antibodies capable of recognizing both the B100 and B48 forms of apoprotein B, but not with any of several monoclonal antibodies capable of recognizing only B100. This suggests that the material in the enterocytes is the B48 form of apoprotein B or a fragment thereof. Additional findings included decreased low density lipoprotein levels with an abnormal chemical composition, abnormal high density lipoprotein<sub>2</sub> (HDL<sub>2</sub>) and HDL<sub>3</sub> particle size distributions, and an abnormal HDL apoprotein composition. Increased amounts of proteins having electrophoretic mobilities similar to apo E and the E-AII complex were present. Finally, some cases exhibited additional protein components of apparent molecular weights between 17,000 and 28,000, which was similar to some cases of abetalipoproteinemia. These findings demonstrate that Anderson's disease is not due to the absence of synthesis of intestinal apo B and [...]

**Find the latest version:**

<https://jci.me/112590/pdf>



# Hypobetalipoproteinemia with Accumulation of an Apoprotein B-like Protein in Intestinal Cells

## Immunoenzymatic and Biochemical Characterization of Seven Cases of Anderson's Disease

Marie-Elisabeth Bouma, Isabel Beucler,\* Lawrence-Paul Aggerbeck,‡ Recaredo Infante, and Jacques Schmitz§

*Institut National de la Santé et de la Recherche Médicale, U9, Hôpital Saint-Antoine, 75012; \*Centre National de la Recherche*

*Scientifique UA 524; ‡Centre de Génétique Moléculaire, Centre National de la Recherche Scientifique; and §Service de Gastroentérologie Pédiatrique, Département de Pédiatrie, Hôpital des Enfants Malades, 75015 Paris, France*

### Abstract

We describe here seven cases (from five kindreds) of Anderson's disease, which is characterized by diarrhea, steatorrhea, hypobetalipoproteinemia with low levels of cholesterol, triglycerides, and phospholipids, and failure to secrete chylomicrons after a fat meal. Enterocytes isolated from intestinal biopsies of patients after overnight fast showed numerous fat droplets, a histological picture resembling that of abetalipoproteinemia. Immunoenzymatic staining of the enterocytes demonstrated large amounts of material that reacted with a polyclonal antiserum to apolipoprotein B. Further, the immunoreactive material was found to react with several different monoclonal antibodies capable of recognizing both the B100 and B48 forms of apoprotein B, but not with any of several monoclonal antibodies capable of recognizing only B100. This suggests that the material in the enterocytes is the B48 form of apoprotein B or a fragment thereof. Additional findings included decreased low density lipoprotein levels with an abnormal chemical composition, abnormal high density lipoprotein<sub>2</sub> (HDL<sub>2</sub>) and HDL<sub>3</sub> particle size distributions, and an abnormal HDL apoprotein composition. Increased amounts of proteins having electrophoretic mobilities similar to apo E and the E-AII complex were present. Finally, some cases exhibited additional protein components of apparent molecular weights between 17,000 and 28,000, which was similar to some cases of abetalipoproteinemia. These findings demonstrate that Anderson's disease is not due to the absence of synthesis of intestinal apo B and suggest that it is more complex than previously thought, affecting all the lipoprotein classes.

### Introduction

In 1961, Anderson et al. (1) described the case of a 7-mo-old girl who exhibited a defect in fat transport in the intestinal mucosa. The clinical features included persistent diarrhea with ste-

atorrhea and failure to thrive. Macroscopic observation of the mucosal surface of a jejunal biopsy showed a "white stipplinglike hoar frosting." By light microscopy, villi were present in normal number and length but the intestinal cells were filled with lipid droplets. Plasma levels of carotenoids, vitamins A and E were decreased. Plasma levels of total lipids, cholesterol, phospholipids, and triglycerides were very low, and serum alpha and betalipoprotein levels were 50% of normal. No chylomicrons were noted in the circulation after a fat meal. Although the clinical picture and intestinal biopsy findings closely resembled those of a patient described by Salt et al. (2) with abetalipoproteinemia, Anderson's patient did not have acanthocytosis, retinitis pigmentosa, or neurological abnormalities, and did have betalipoproteins in her plasma, although in reduced amounts. Anderson suggested that the primary defect in this syndrome was related to the synthesis of chylomicrons within the intestinal cells.

Subsequently, several other cases were described (3-8). The disease is characterized by diarrhea with steatorrhea, typical macroscopic and histological findings in the intestinal biopsy after an overnight fast, and decreased amounts of cholesterol in the plasma. The digestive symptoms are alleviated with resumption of normal growth by institution of a low-fat diet supplemented with liposoluble vitamins and essential fatty acids. The frequency of this disease among siblings and consanguineous relationships in the family of affected individuals suggests an autosomal recessive mode of inheritance.

The etiology of the disease is as yet unknown. In abetalipoproteinemia and homozygous hypobetalipoproteinemia, involving hepatic and intestinal apoprotein B (apo B)<sup>1</sup> genetic defects, fat malabsorption is always present and chylomicrons are absent from postprandial serum, suggesting that apo B synthesis is necessary for production and export of chylomicrons. A new mutant of abetalipoproteinemia (normotriglyceridemic abetalipoproteinemia) has been recently reported (9, 10). In these patients, only the hepatic form of apo B (B100) synthesis is impaired and, thus, intestinal fat absorption and chylomicron production is normal, including the appearance of the intestinal form of apo B (B48) in the plasma after a fatty meal. Since these interesting observations suggest a separate genetic control of the intestinal and hepatic forms of apo B, the existence of an isolated defect of apo B production by the intestine which must result in fat malabsorption and lack of chylomicron secretion may be predicted.

Parts of this study have been presented at the XVI Annual Meeting of the European Society for Paediatric Gastroenterology and Nutrition, May 1983, Graz, Austria (*Pediatr. Res.* 1983. 17:431. [Abstr.]), and at the American Gastroenterological Association, May 1985, New York City (*Gastroenterology*. 1985. 88:1333. [Abstr.]).

Address reprint requests to Mrs. M. E. Bouma, Institut National de la Santé et de la Recherche Médicale, U9, Hôpital Saint-Antoine, 75012 Paris, France.

Received for publication 12 August 1985 and in revised form 24 February 1986.

J. Clin. Invest.

© The American Society for Clinical Investigation, Inc.

0021-9738/86/08/0398/13 \$1.00

Volume 78, August 1986, 398-410

1. Abbreviations used in this paper: apo, apoprotein; B48, intestinal form of apo B; B100, hepatic form of apo B; VHDL, very high density lipoprotein.

The aim of this study in a new series of seven patients from five kindreds with Anderson's disease is to gain further information on the primary defect responsible for the impaired fat transport in the intestinal mucosa. This defect could result from a deletion of apo B or from translational or posttranslational abnormalities in the protein structure, or from a block in the cellular transport of chylomicrons. Recently, some patients with hypobetalipoproteinemia and a coeliaclike syndrome have been reported (11, 12) who resemble the Anderson's disease patients' described in this paper. Our immunocytochemical studies using polyclonal and monoclonal antibodies to low density lipoprotein (LDL) clearly show that although there are no circulating chylomicrons even after a fat meal, there are large amounts of immunoreactive apo B-like material present in the patients' enterocytes, and that this material resembles the B48 as opposed to the B100 form of apo B. Further, the physical and chemical characterization of the circulating lipoproteins and their apoproteins reveal several additional abnormalities, some of which resemble those found in abetalipoproteinemia.

## Methods

**Description of the patients.** M.K., born 9/26/68, was the 9th child in a sibship of 12; his Algerian parents were cousins. Diarrhea began at 4 mo; at 10 mo of age, coeliac disease was suspected and a gluten-free diet was started without any beneficial effect. When he was admitted to the hospital for the first time at 3 yr and 3 mo, he presented with growth retardation (89 cm, 10.800 kg), a distended abdomen, and loose stools. Hypocholesterolemia (total plasma cholesterol, 77 mg/dl) and an important steatorrhea (17.5 g/d) were present. An intestinal biopsy showed fat-loaded enterocytes in an otherwise normal mucosa. In the absence of acanthocytosis and neurological signs, the diagnosis of Anderson's disease was made and M.K. was put on lipid-free diet. After a 1-yr period of strict adherence to the diet leading to the disappearance of the digestive symptoms and to catch-up growth, the diet was irregularly followed and symptoms recurred.

A.B., born 6/23/76, was the fourth of four children from Algerian parents. As cows' milk was introduced into her diet at 17 d, she began to vomit, but her stool remained normal. At 4 mo of age, when first seen at the hospital, she was malnourished (63 cm, 4.430 kg) and had a grossly distended abdomen. Hirschsprung disease, cystic fibrosis, and cows' milk protein intolerance were suspected and refuted. The latter diagnosis led to an intestinal biopsy that showed typical fat-loaded enterocytes. Hypocholesterolemia (116 mg/dl) and steatorrhea (5.6 g/d) were, thus, easily explained. A lipid-free diet was started. It has been strictly followed since then and A.B. is now a healthy young girl with a normal neurological examination.

S.Z., born 1/21/79, was the 11th child in a sibship of 12 from Algerian parents related at the sixth generation. The major symptom was intermittent diarrhea, which began at 2 mo of age, and was soon associated with failure to thrive. S.Z. was first admitted to the hospital at 13 mo of age with growth retardation (66.5 cm, 6.650 kg), malnutrition, and liquid or loose stools. Fat malabsorption was not major (3.9 g/d) but hypolipemia was clearcut: total plasma cholesterol was 66 mg/dl. The presence of fat-loaded enterocytes in the intestinal biopsy led to the diagnosis of Anderson's disease and to the prescription of a lipid-free diet. Strict adherence to the diet resulted in a year of catch-up growth, and now S.Z. is growing normally.

K. and Y.Z., born 9/24/67 and 3/26/70, respectively, are two of S.Z.'s older brothers, the seventh and eighth children of the family. Both had frequent episodes of diarrhea and retarded growth during their childhood. When Anderson's disease was diagnosed in S.Z., their father brought K. and Y.Z. to the hospital. They were first seen at 12 yr, and at 10 yr and 5 mo of age, respectively, with short statures (129 cm, 29 kg, and 120 cm, 24 kg, respectively) and loose stools. Both were hypo-

lipemic; total plasma cholesterol was 47 and 33 mg/dl, respectively, and exhibited the typical fat-loaded enterocytes on small bowel biopsy. With lipid-free diets maintained until now, their stools have become normal, but catch-up growth is undisputable only in the case of Y.Z.

M.B. was born 4/18/78 from healthy Tunisian parents related to an unknown degree. He had 10 sibs. Among them, an older brother and an older sister had chronic diarrhea and short statures; the latter had low cholesterol (70 mg/dl) and steatorrhea (12 g/d). Diarrhea started during the first year of life of M.B. At four-and-a-half years, coeliac disease was suspected and he followed a gluten-free diet for 2 yr without any beneficial effect. When first admitted to the hospital at 6 yr and 5 mo of age, M.B. presented with growth retardation (101 cm, 14.8 kg), a severely distended abdomen, and abundant, loose, greasy stools. Total plasma cholesterol was low (92 mg/dl) and steatorrhea was high (18.5 g/d). An intestinal biopsy revealed fat-loaded enterocytes lining a mucosa presenting partial villous atrophy. A lipid-free diet (>10 g/d of long-chain triglycerides) supplemented with fat soluble vitamins and essential fatty acids was started. M.B. returned to Tunisia 15 d after his admission. Follow-up has been too short for any clinical or biological evolution to be appreciated. The last patient, A.H., born on 9/10/68, has been described previously (6), and since that time he has followed a low-fat diet and has developed normally.

Sera and an intestinal biopsy from A.H. were kindly provided by Prof. C. Polonovski (Hospital Trousseau, Paris, France); sera and intestinal biopsies from two patients with abetalipoproteinemia (S.L. and M.P.) were obtained by Dr. B. Leluyer (Charles Nicolle Hospital, Rouen, France) and Dr. Schmitz.

**Isolation of intestinal epithelial cells and immunoenzymatic techniques.** After a 12-h fast, intestinal mucosa biopsies were obtained from six patients (M.K., A.B., S.Z., Y.Z., M.B., and A.H.) at the duodenojejunal junction with a pediatric Crosby capsule under fluoroscopic control. Control fasted specimens were halves of biopsies taken for diagnostic purposes and judged to be normal upon histological examination. Informed consent was obtained from the parents of all subjects. Biopsy specimens were immediately placed in cold phosphate-buffered saline, pH 7.4, and isolated intestinal epithelial cells were prepared, as described by Glickman et al. (13, 14) based upon the method of Weiser (15) using a citrate solution to dissociate the cells. Successive incubations and washes with 0.13 M NaCl solution provided a sequential fractionation of isolated epithelial cells starting from the villus tip (elongated cells) to the lower villus and crypt area (round cells). Since triglyceride absorption occurs mostly in the cells of the upper third of the villus, we preferentially isolated the cells from this area. In control subjects these cells have 210% higher ( $n = 8$ ,  $P < 0.02$ ) sucrose activity (an activity specific for villus cells) as compared with the residual cells. The isolated cells were spread on glass slides and air dried. Normal human enterocytes, isolated by a modification of Weiser's technique (16), were kindly provided by Dr. M. Pessah and Mrs. C. Salvat. Normal human hepatocytes were isolated as previously described (17) from peroperative liver biopsies, which were obtained for diagnostic purposes. The Hep G2 cell line was a gift from Drs. B. Knowles and D. Aden (Wistar Institute, Philadelphia, PA).

Lipid staining with Oil red O was carried out on cells without fixation. Immunoenzymatic localization of apo B and apo C within cells was carried out on duplicate slides as follows. Cells were fixed by one of the following two methods: method A: cold methanol ( $-20^{\circ}\text{C}$  for 4 min) followed by acetone ( $-20^{\circ}\text{C}$  for 2 min) as described by Glickman et al. (13); method B: 3% paraformaldehyde for 30 min. After fixation, the cells were overlaid with one of the rabbit polyclonal antibodies and with seven murine monoclonal antibodies, as in the cases of A.H. and M.B., as previously described (18). After incubation and washing, peroxidase-labeled sheep or goat IgG directed against rabbit or murine IgG, respectively, were applied and the slides incubated for 2 h at room temperature. After washing with phosphate-buffered saline, peroxidase activity was revealed by the Graham-Karnovsky reaction (19). The following controls were tested in parallel: (a) cells incubated with peroxidase-labeled antibody-alone; (b) cells incubated with polyclonal antibody absorbed with apoproteins; (c) cells incubated with rabbit or mouse nonimmune serum

or mouse monoclonal antibody to paramecium surface antigen (kindly provided by Drs. Y Cappdeville and F. Caron, Centre de Génétique Moléculaire, Centre Nationale de La Recherche Scientifique, France) followed by peroxidase-labeled antiserum to rabbit or mouse immunoglobulin; and (d) Graham-Karnovski reaction alone to determine endogenous peroxidase.

Two series of monoclonal antibody-producing hybridoma cell lines, L3, L5, L7, L9 (developed by the Clin Midy Research Center, Montpellier, France), and SC2, SC3, SC10, were obtained by fusion of NSI and SP20 myeloma cells, respectively, with spleens from BALB/c mice immunized with human serum LDL (density 1.024–1.050 g/ml). The preparation and many of the characteristics of these antibodies have already been described (20, 21); rabbit polyclonal antibodies to LDL and to total apo C and apo CIII were prepared a previously described (22). The specificity of the antibodies with respect to the various forms of apo B (according to the nomenclature of Kane et al. [23]) were determined by enzymeimmunoassay (Goldstein, S., unpublished results) and by immunoblotting of sodium dodecyl sulfate (SDS) polyacrylamide gels of chylomicrons, very low density lipoprotein (VLDL), and LDL according to Salmon et al. (20) and are summarized in Table I. One group of antibodies was capable of recognizing both the B100 and B48 forms of apo B as illustrated in Fig. 1 by the rabbit polyclonal and the L9 and SC3 as SC10 (data not shown) monoclonal antibodies. The other group, illustrated by L7 and SC2 in the figure and L3, (L5 not presented), recognized the B100 but not the B48 form of apo B. For the studies described here the L3, L5, L7, and L9 antibodies were used in the form of purified immunoglobulins, while the SC2, SC3 and SC10 antibodies were used in the form of murine ascitic fluid.

**Ultracentrifugal fractionation of serum lipoproteins.** Blood samples were obtained from subjects fasting (12 h) or 3 h after a fat meal (50 g lipid). Serum was separated from the blood clot by centrifugation at 3,000 g, 4°C, for 15 min. The serum was then added with EDTA (1 mM) pH 8.6 and sodium azide (0.05%). Sequential separation of lipoproteins was begun immediately as described by Havel et al. (24) using a Beckman L3 50 ultracentrifuge at 10°C and a 50.3 titanium rotor to obtain the following fractions: VLDL, density < 1.006 g/ml (155,000 g

Table I. Specificities of the Monoclonal Antibodies toward the Various Forms of Apo B\*

Antibody	Apo B			
	B100	B74	B26	B48
L3	+	—	—	±
L5	+	—	—	—
L7	+	+	—	—
L9	+	+	—	+
SC2	+	+	—	—
SC3	+	+	—	+
SC10	+	+	—	+

\* According to the nomenclature of Kane et al. (21).

for 14 h), LDL, density 1.006–1.063 g/ml (115,000 g for 16 h), high density lipoprotein<sub>1</sub> (HDL<sub>1</sub>), density 1.063–1.085 g/ml (115,000 g for 18 h), HDL<sub>2</sub>, density 1.085–1.125 g/ml (180,000 g for 22 h), HDL<sub>3</sub>, density 1.125–1.21 g/ml (180,000 g for 24 h), and very high density lipoprotein (VHDL), density 1.21–1.25 g/ml (180,000 g for 24 h). Lipoprotein fractions were dialyzed against several changes of 2 mM sodium phosphate buffer, pH 7.5, containing 0.5 mM EDTA and 3 mM sodium azide. After dialysis, fractions were stored at 4°C and analyses were performed within 24 h of preparation.

**Lipoprotein analysis.** Total cholesterol (25), triglycerides (26), and phospholipids (27) were directly measured in serum using enzymatic techniques in an autoanalyzer (Corona, Clinicon-Boehringer, Meylan, France). Serum apo A1 (28) and apo B (29) were determined by electroimmunoassay using monospecific antisera (30). Lipoprotein fractions were delipidated as described by Brown et al. (31) and total cholesterol, triglycerides, and phospholipids were measured as described above. Free fatty acids and cholesterol ester fatty acyl groups were not measured. Protein was assayed according to Peterson (32).

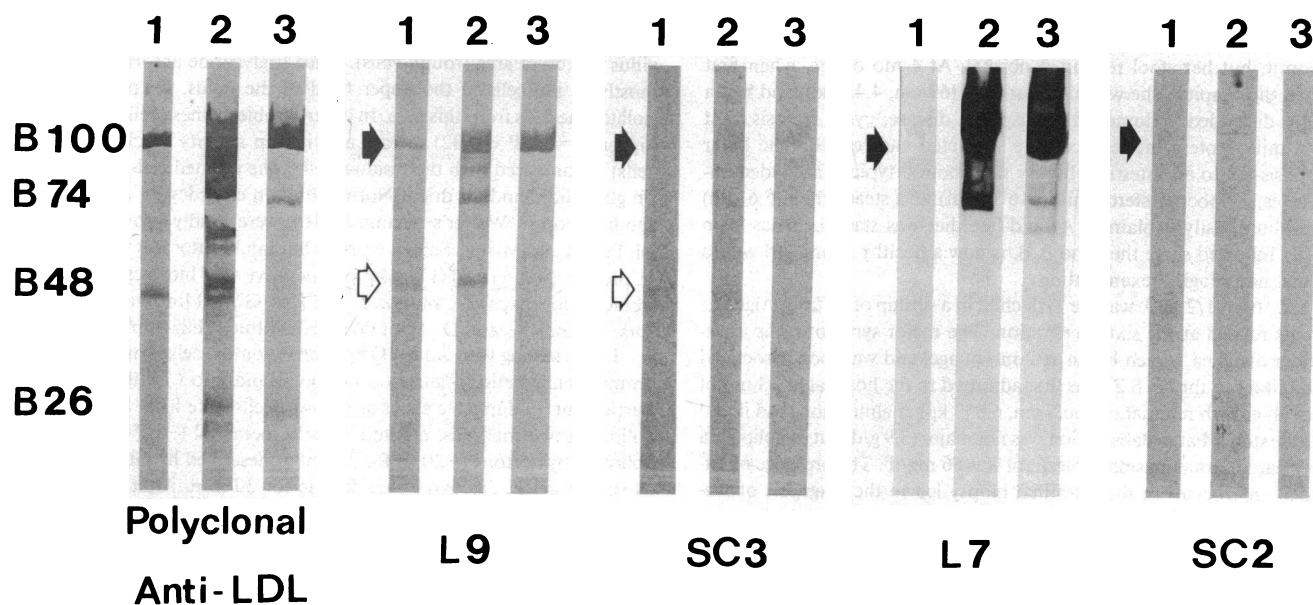


Figure 1. Western blots illustrating the specificities of representative antibodies (~20 µg IgG/ml) towards the various forms of apo B: B100, B76, B48, and B26. Lane 1, chylomicrons (60 µg protein); 2, VLDL (30 µg protein); 3, LDL (10 µg protein). Some antibodies, as illustrated by the rabbit polyclonal and the L9 and SC3 monoclonal

antibodies, recognize both the B100 (●) and B48 (◊) forms of apo B. Other antibodies, illustrated by L7 and SC2, recognize only the B100 form. The fainter band corresponding to B48 in chylomicrons as compared with that obtained with VLDL is due to the smaller amount of apo B loaded on the gels.

The morphology of the lipoproteins in isolated fractions was investigated by negative staining with 2% sodium phosphotungstate of samples in 10 mM sodium phosphate buffer, pH 7, using a Phillips 301 electron microscope (33). The resolution of the microscope was determined using potassium chloroplatinate crystals and graphite and was found to be  $>0.4$  nm. Low magnification calibration (to about  $\times 10,000$ ) was performed with a grating replica (54,864 lines/in.) and intermediate magnifications (to about  $\times 50,000$ ) with glutaraldehyde-fixed, negatively stained catalase crystals (34). Photographic enlargements were calibrated by comparing particle sizes on the negative with those on the paper.

**Apolipoproteins analysis.** Apolipoproteins were analyzed by isoelectric focusing in a pH 4–6.5 ampholine gradient (35) and by SDS polyacrylamide gel electrophoresis: 4% polyacrylamide gels for apo B-containing fractions and 15% polyacrylamide gels for apo A-containing fractions (36).

Isoelectric focusing gels were stained with Coomassie Blue G250. SDS polyacrylamide gels were stained with Coomassie Blue R-250 according to Fairbanks et al. (37) or with silver according to Oakley et al. (38). Approximately 20  $\mu$ g protein was applied to the gels for analysis of apo B (Coomassie staining). In the case of HDL apoproteins, either 75  $\mu$ g (for Coomassie staining) or 200–300 ng (for silver staining) were applied to the gels. Duplicate samples were prepared nonreduced and reduced by addition of an excess of  $\beta$ -mercaptoethanol.

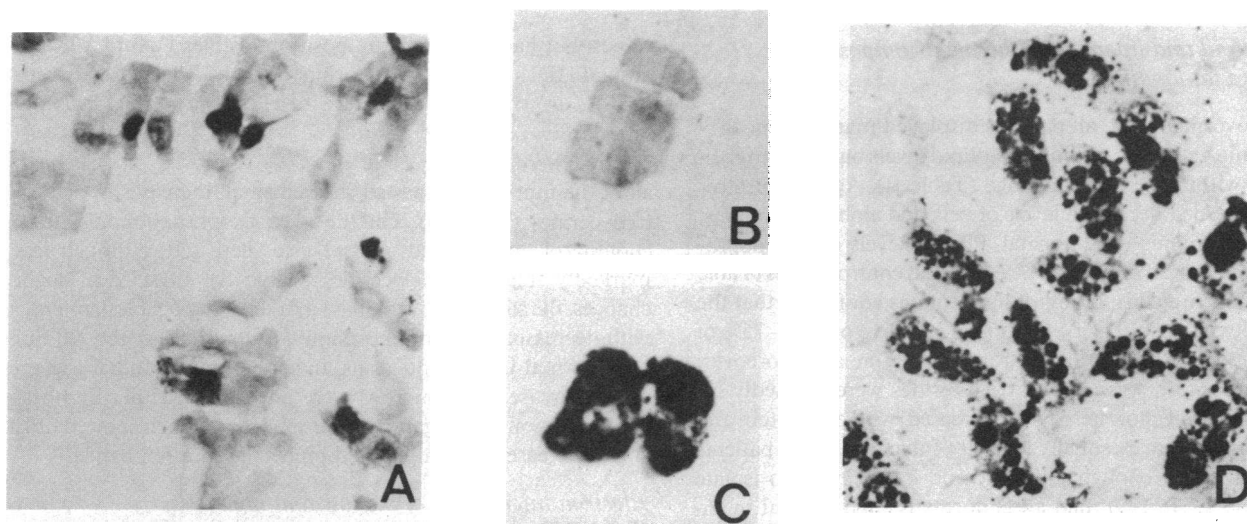
## Results

### *Histochemical and immunoenzymatic staining of isolated enterocytes*

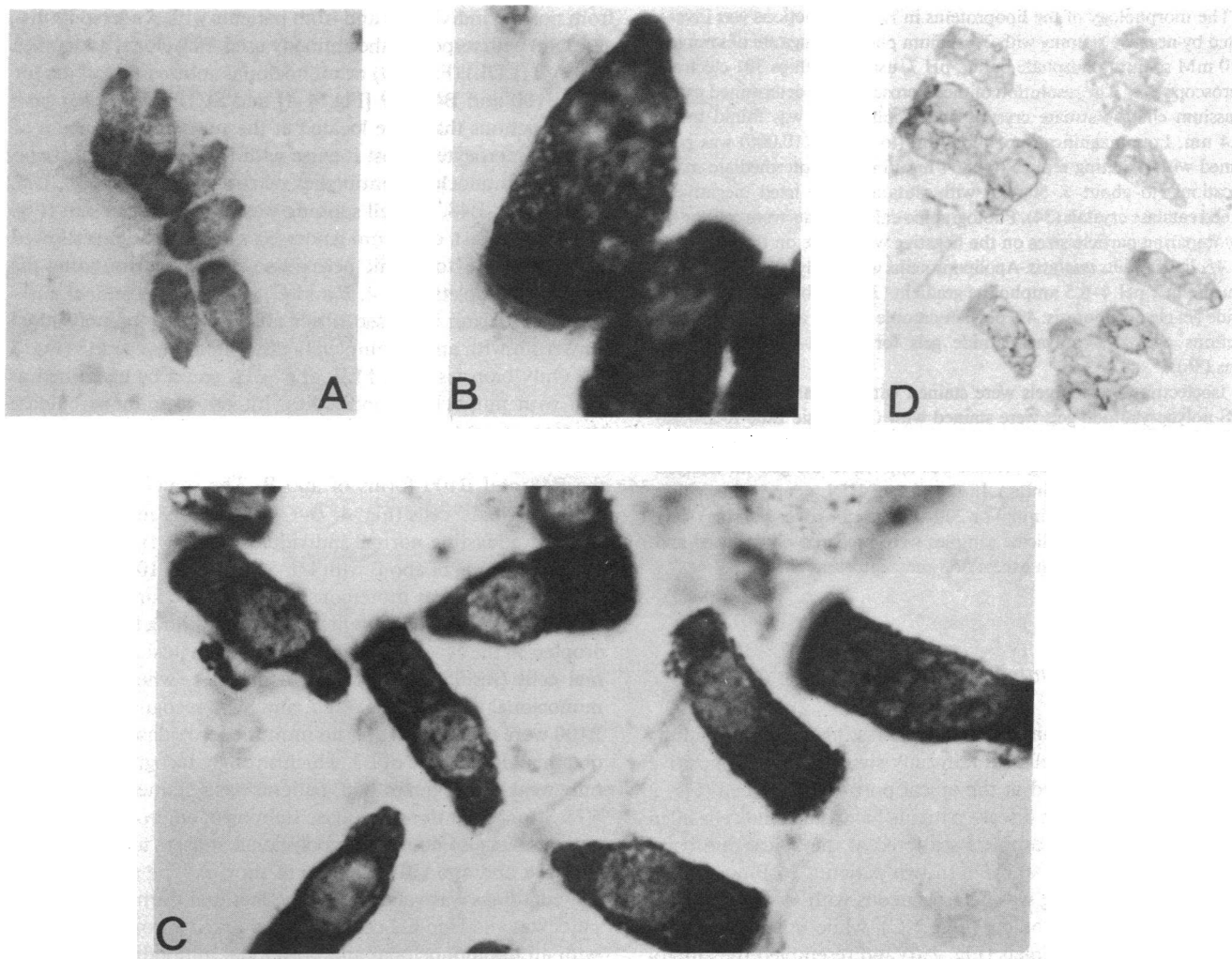
**Oil red staining.** In contrast to normal fasting children or adults in whom intestinal cells contain only small Oil red O-positive lipid droplets localized at the apical portion of the cell (Fig. 2 *A*), fasting Anderson's disease patients have intestinal cells filled with numerous lipid droplets scattered at the apical and basal cell regions (Fig. 2, *C* and *D*). In two patients, M.B. and A.H., the Oil red O staining was heterogeneous with some cells being distended with fat droplets (Fig. 2 *C*), while others were long and without lipid droplets (Fig. 2 *B*) and resembled the enterocytes from normal fasting individuals.

**Immunoenzymatic staining.** Immunoenzymatic staining for apo B also showed marked differences among intestinal cells

from normal individuals and from patients with Anderson's disease, and with respect to the antibody used. Polyclonal antibodies to apo B (LDL) (Fig. 3 *A*) or monoclonal antibodies specific for both B100 and B48 (L9 [Fig. 4 *A*] and SC10 [Fig. 4 *B*]) gave weak reactions that were located at the supranuclear region of normal enterocytes (most intense with the polyclonal anti apo B). Using monoclonal antibodies reacting with B100 (L5, L7), but not with B48, the cell staining was minimal or absent (Fig. 4 *C*). In contrast, cells from Anderson's disease patients showed strong brown cytoplasmic peroxidase staining surrounding the large lipid droplets (Fig. 4, *B* and *C*) when the polyclonal anti-apo B antiserum was used. Prior absorption of the polyclonal antiserum with apo B completely prevented the reaction (Fig. 3 *D*). Only biopsies from M.B. and A.H. could be examined as well with monoclonal antibodies. Intense immunoperoxidase staining of intestinal cells was obtained with three different monoclonal antibodies (L9, SC3, and SC10), recognizing both the B48 and B100 forms of apo B. The material reacting in fasting patients' cells (Fig. 4, *D*–*G*) was clearly more abundant than in the fasting normal individuals (Fig. 4 *A*). Immunoperoxidase staining of apo B with L9, SC3, and SC10, in cells from M.B. and A.H., was more conspicuous in the larger fat-loaded cells (Fig. 4, *D*–*G*) than in enterocytes containing few or no lipid droplets in the cytoplasm, which are indistinguishable from normal cells (results not shown). In contrast, when three other monoclonal antibodies (L5, L7, and SC2) recognizing only apo B100 were used (Fig. 4 *H*), no immunoperoxidase reaction was obtained. In the case of L3, which strongly recognizes B100 but only weakly recognizes B48, patients' cells stained weakly (Fig. 4 *I*). Strong immunoperoxidase staining of enterocytes from the patients was also noted using polyclonal antisera to apo C (total), apo CII, and apo CIII (results not shown). The significance of these findings was validated by the fact that normal human hepatocytes and Hep-G2 cells showed marked peroxidase staining with all the monoclonal and polyclonal antibodies (results not shown). Furthermore, the control reactions including those using a monoclonal antibody against parametia surface antigen (Fig. 4 *J*) or the peroxidase label alone (Fig. 4 *K*) were negative.



**Figure 2.** Histochemical staining of fat droplets in isolated enterocytes. Oil red O staining shows small lipid droplets in the apical portion of enterocytes from normal fasted individuals (*A*) while enterocytes from patients with Anderson's disease are heavily fat laden (*C* and *D*). Some enterocytes from patients are long and without lipid droplets (*B*).  $\times 500$ .



**Figure 3.** Immunoenzymatic localization in isolated enterocytes of apo B with polyclonal antibodies against LDL. Enterocytes from normal fasted individuals show light brown immunoperoxidase staining of the supranuclear regions (A), while enterocytes from patients M.B.

(B) and A.H. (C) with Anderson's disease show intense brown cytoplasmic staining surrounding large lipid droplets. Staining is absent when the antiserum had been absorbed with apo B (D). Magnification  $\times 500$  for A and D,  $\times 1,300$  for B and C.

#### *Plasma lipid and lipoprotein chemical composition: response to fat loading*

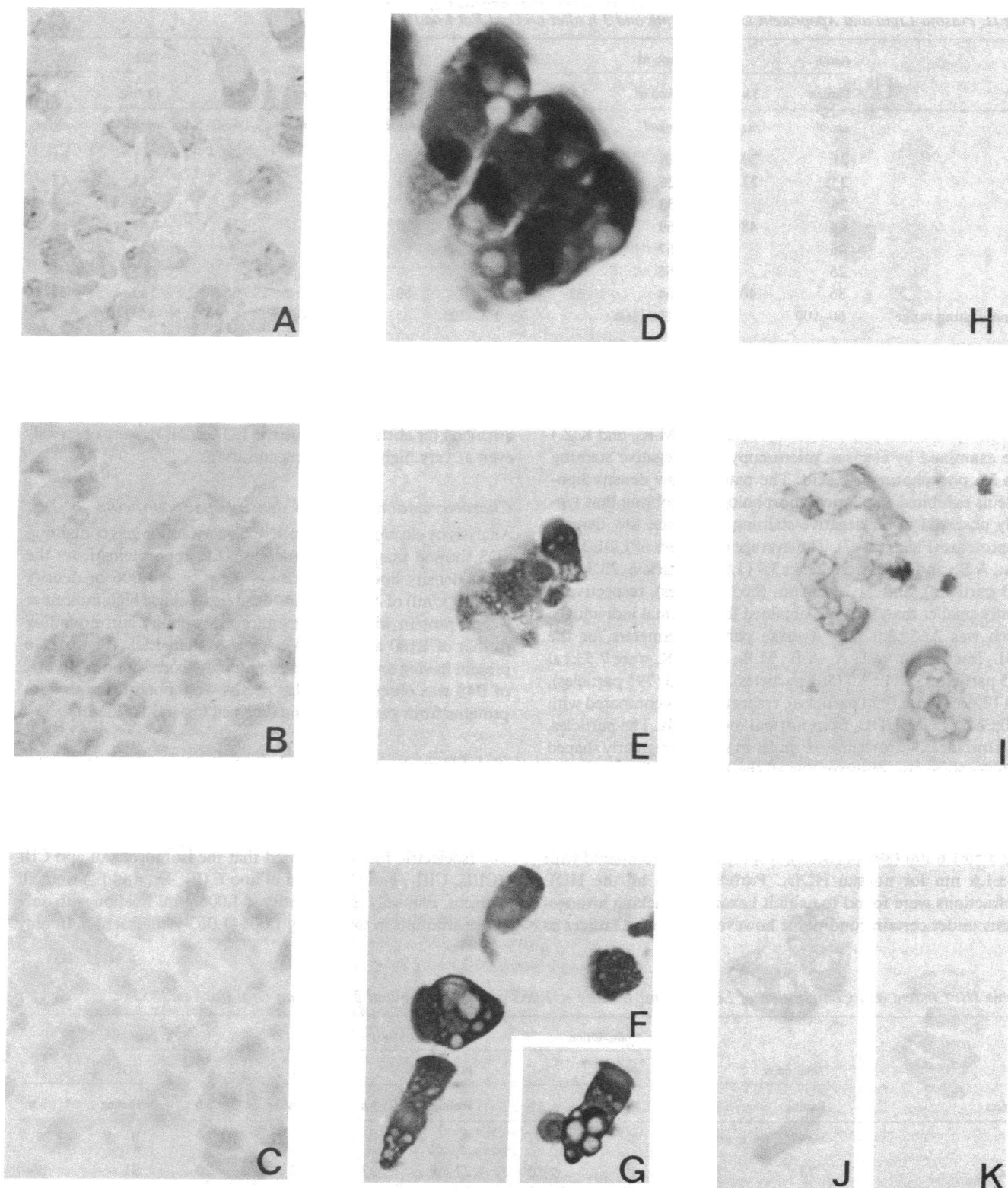
After an overnight fast, all patients displayed marked hypocholesterolemia and decreased phospholipid levels but had a triglyceridemia within the normal range (Table II). Agarose electrophoresis revealed decreased levels of beta and alpha lipoproteins; prebetalipoproteins were normal. Plasma levels of apolipoproteins AI and B were only 20–70% of normal control values (Table II). Ultracentrifugal isolation of lipoproteins confirmed that the low density classes (density  $< 1.063$  g/ml) were only 30–75% of the levels found in normal children of the same age; moreover, their composition was altered; triglycerides were markedly increased and total cholesterol was decreased, whereas protein and phospholipids were essentially normal (Table III). In two patients (A.B. and A.H.), enough plasma could be obtained to isolate VLDL and LDL. LDL had an abnormally high content in triglycerides and phospholipids relative to cholesterol (triglycerides, 18%, cholesterol, 25%, protein, 20%, and phospholipids, 37%). HDL were also markedly decreased, only 20–30% of normal

values, but had a normal composition (Tables IV and V). The ratio of HDL<sub>2</sub> to HDL<sub>3</sub> was normal or slightly decreased except in A.B., in whom the total mass of HDL<sub>2</sub> and HDL<sub>3</sub> was the same. In two cases (M.K. and K.Z.), the HDL<sub>1</sub> level and composition were normal. 3 h after a 50-g sunflower oil test meal, all of the four subjects tested showed small increases in plasma triglycerides (Table II). On the average, phospholipids, total cholesterol, apo B, and apo AI also increased, although less markedly than the triglycerides (Table II). In spite of slight changes, the subjects all remained markedly hypocholesterolemic with decreased levels of phospholipids, apo B, and apo AI, but with normal triglyceride levels. In spite of postprandial triglyceride increase, chylomicrons were not evident either by ultracentrifugation or by agarose electrophoresis, which showed only slight increase in the alpha and prebetalipoprotein bands.

#### *Electron microscopy of the low and high density lipoproteins*

Low density lipoproteins from three patients (H.A., A.B., and M.B.), HDL<sub>2</sub> from four patients (H.A., A.B., M.B., and M.K.)





**Figure 4.** Immunoenzymatic localization in isolated enterocytes of apo B with monoclonal antibodies against LDL. Enterocytes from normal fasted individuals show light supranuclear immunoperoxidase staining when antibodies specific for both B100 and B48 were used, L9 (A) or SC10 (B). Only minimal staining is observed with an antibody specific for only B100, L5 (C). Intense cytoplasmic staining around lipid droplets is seen in enterocytes from patients when antibodies specific for both B100 and B48 are used: patient (M.B.), anti-

body L9 (D); patient (M.B.), antibody L9 (E); patient (M.B.), antibody SC10 (F); and patient (M.B.), antibody SC3 (G). In contrast, minimal or no staining of enterocytes from patients is seen when antibodies specific for only B100 are used: patient (M.B.), antibody L5 (H); and patient (M.B.), antibody L3 (I). Controls, enterocytes from patients with monoclonal antibody to paramecium surface antigen (J) or with peroxidase-labeled antiserum alone (K), show no staining. Magnification  $\times 500$  except D,  $\times 1,300$ .

Table II. Plasma Lipid and Apoprotein Levels Fasting and 3 h after an Oral Fat Load\*

Subject	Apo B		Apo AI		PL‡		C‡		TG‡	
	Fasting	3 h	Fasting	3 h	Fasting	3 h	Fasting	3 h	Fasting	3 h
	mg/dl	mg/dl	mg/dl	mg/dl	mg/dl	mg/dl	mg/dl	mg/dl	mg/dl	mg/dl
K.Z	21	20	26	26	38	40	40	40	43	44
Y.Z.	23	23	26	26	34	33	36	35	43	47
S.Z.	26		53		ND§		69		133	
A.B.	44	48	69	77	67	70	69	72	59	68
A.H.	46		67		ND§		87		123	
M.B.	25		66		ND§		70		67	
M.K.	36	40	64	62	67	69	60	65	53	65
Normal fasting range	60–100		120–160		150–225		116–195		45–110	

\* 50-g fat load. ‡ PL, total phospholipid; C, free plus esterified cholesterol; and TG, triglycerides. § ND, Not enough material for determination.

and HDL<sub>3</sub> from five patients (H.A., A.B., M.B., M.K., and K.Z.) were examined by electron microscopy after negative staining with 2% phosphotungstic acid. The patients' low density lipoproteins exhibited a spherical morphology resembling that typically observed upon negative staining of normal low density lipoproteins (Fig. 5, A–C). The average diameters of LDL from H.A., A.B., and M.B. were  $23.8 \pm 3.9$  (1,018 particles),  $23.3 \pm 5.3$  (573 particles), and  $21.7 \pm 1.8$  nm (665 particles), respectively, slightly smaller than for LDL obtained from normal individuals, which was  $2.65 \pm 2.0$  nm. Average particle diameters for the HDL<sub>2</sub> fractions from H.A., A.B., M.B., and M.K. were  $7.5 \pm 1.0$  (795 particles),  $11.1 \pm 2.0$  (502 particles),  $7.1 \pm 1.3$  (795 particles), and  $12.4 \pm 2.9$  nm (950 particles), respectively, as compared with  $10.0 \pm 2.0$  nm for HDL<sub>2</sub> from normal individuals. The particles, in all instances, were slightly irregular in shape. Irregularly shaped particles were also observed for all the HDL<sub>3</sub> subfractions (Fig. 5, H–L). The average particles diameters of HDL<sub>3</sub> from H.A., A.B., M.B., M.K., and K.Z. were  $8.4 \pm 1.6$  (540 particles),  $8.8 \pm 1.5$  (704 particles),  $6.9 \pm 1.5$  (608 particles),  $14.4 \pm 3.9$  (648 particles), and  $8.5 \pm 1.6$  nm (891 particles), respectively, as compared with  $8.8 \pm 1.6$  nm for normal HDL<sub>3</sub>. Particles from all the HDL subfractions were found to exhibit hexagonal packing arrangements under certain conditions; however, no square lattices as

described for abetalipoproteinemic LDL or HDL were observed, even at very high particle concentrations.

#### Characterization of the low density apolipoprotein

Analysis by electrophoresis on 4% polyacrylamide gels containing SDS showed that, after delipidation, the apoproteins from the lower density lipoproteins classes (density < 1.006 or density < 1.063 g/ml) of A.B. and H.A. exhibited a single high molecular weight protein with an electrophoretic mobility corresponding to that of B100 as found in normal human LDL (Fig. 6). No protein having an electrophoretic mobility corresponding to that of B48 was observed. Similar results were obtained with apoproteins from patients having received an oral fat load.

#### Soluble apolipoproteins

Electrophoresis in 15% polyacrylamide gels in SDS of the soluble apoproteins from lipoproteins of density < 1.006 g/ml or < 1.063 g/ml showed the presence of CII, CIII, and E apoproteins.

Isoelectric focusing showed that the isomorphs of apo CIII (CIII<sub>0</sub>, CIII<sub>1</sub>, and CIII<sub>2</sub>) and of apo E (E<sub>2</sub>, E<sub>3</sub>, and E<sub>4</sub>) were all present, primarily in the density < 1.006-g/ml fraction with only trace amounts in the density 1.006–1.063-g/ml fraction. In only

Table III. Content and Composition of Lipoproteins: Density < 1.063 g/cm<sup>3</sup> Fasting and 3 h after an Oral Fat Load\*

Subject	Total mass		Composition							
	Fasting	3 h	P‡		PL‡		C‡		TG‡	
	mg/dl	mg/dl	Fasting	3 h	Fasting	3 h	Fasting	3 h	Fasting	3 h
			%	%	%	%	%	%	%	%
K.Z	73	82	20	20	27	27	22	20	31	33
Y.Z.	70	92	23	19	20	16	23	22	34	42
A.B.	175	193	21	22	35	33	23	23	21	22
A.H.	250		19		22		19		40	
M.B.	127		19		25		24		32	
M.K.	107	137	21	20	19	19	24	21	36	40
Normal fasting range	250–350		23–25		25–30		31–35		15–18	

\* 50-g fat load. ‡ PL, protein; PL, total phospholipids; C, free plus esterified cholesterol; and TG, triglycerides.



Table IV. Content and Composition of HDL<sub>2</sub>\* Fasting and 3 h after an Oral Load†

Subject	Total mass		Composition							
			P§		PL§		C§		TG§	
	Fasting	3 h	Fasting	3 h	Fasting	3 h	Fasting	3 h	Fasting	3 h
	mg/dl	mg/dl	%	%	%	%	%	%	%	%
K.Z.	17	20	50	50	22	25	17	20	11	5
Y.Z.	16	20	50	50	31	25	13	15	6	10
A.B.	63	67	44	45	32	31	18	17	6	7
A.H.	43		35		37		20		8	
M.B.	18		50		28		17		5	
M.K.	28	39	46	46	29	28	18	18	7	8
Normal fasting range	100–115		48–52		25–27		15–17		6–8	

\* Density 1.085–1.125 g/cm<sup>3</sup>. ‡ 50-g fat load. § P, protein; PL, phospholipids; C, free plus esterified cholesterol; and TG, triglycerides.

one case, M.K., were all four isomorphs of apo AI (AI<sub>1</sub>, AI<sub>2</sub>, AI<sub>3</sub>, and AI<sub>4</sub>) present with the amounts of AI<sub>1</sub> and AI<sub>2</sub> being larger than AI<sub>3</sub> and AI<sub>4</sub> (results not shown).

After 15% polyacrylamide electrophoresis, both HDL<sub>2</sub> and HDL<sub>3</sub> from two patients with Anderson's disease (H.A. and A.B.) had apoprotein patterns close to that of normal HDL<sub>3</sub> (Fig. 7, A, B, E, and F) which contained, principally, apo AI, apo AII, apo C7, and an unidentified protein band (labeled 3 in Fig. 7) with mobility slightly slower than apo AII. In addition, the patients' HDL contained higher amounts of apo E, E–AII complex, and some nonidentified high molecular weight bands (apparent molecular weight > 46,000). In normal apo HDL, the major protein band with electrophoretic mobility intermediate between AI and AII migrates closer to AI (labeled 1 in Fig. 7).

In contrast, the apo HDL<sub>2</sub> (not shown) and apo HDL<sub>3</sub> of M.K., Y.Z., and K.Z. (Fig. 7 C) were characterized by larger amounts of apo E–AII complex, apo E, nonidentified high molecular weight material, and by the presence of an additional protein band of intermediary mobility between AI and AII (labeled 2 in Fig. 7). Upon reduction with  $\beta$ -mercaptoethanol, the E–AII complex dissociated, but the mobility of the protein bands situated between AI and AII was not modified (Fig. 7 G); HDL<sub>2</sub>

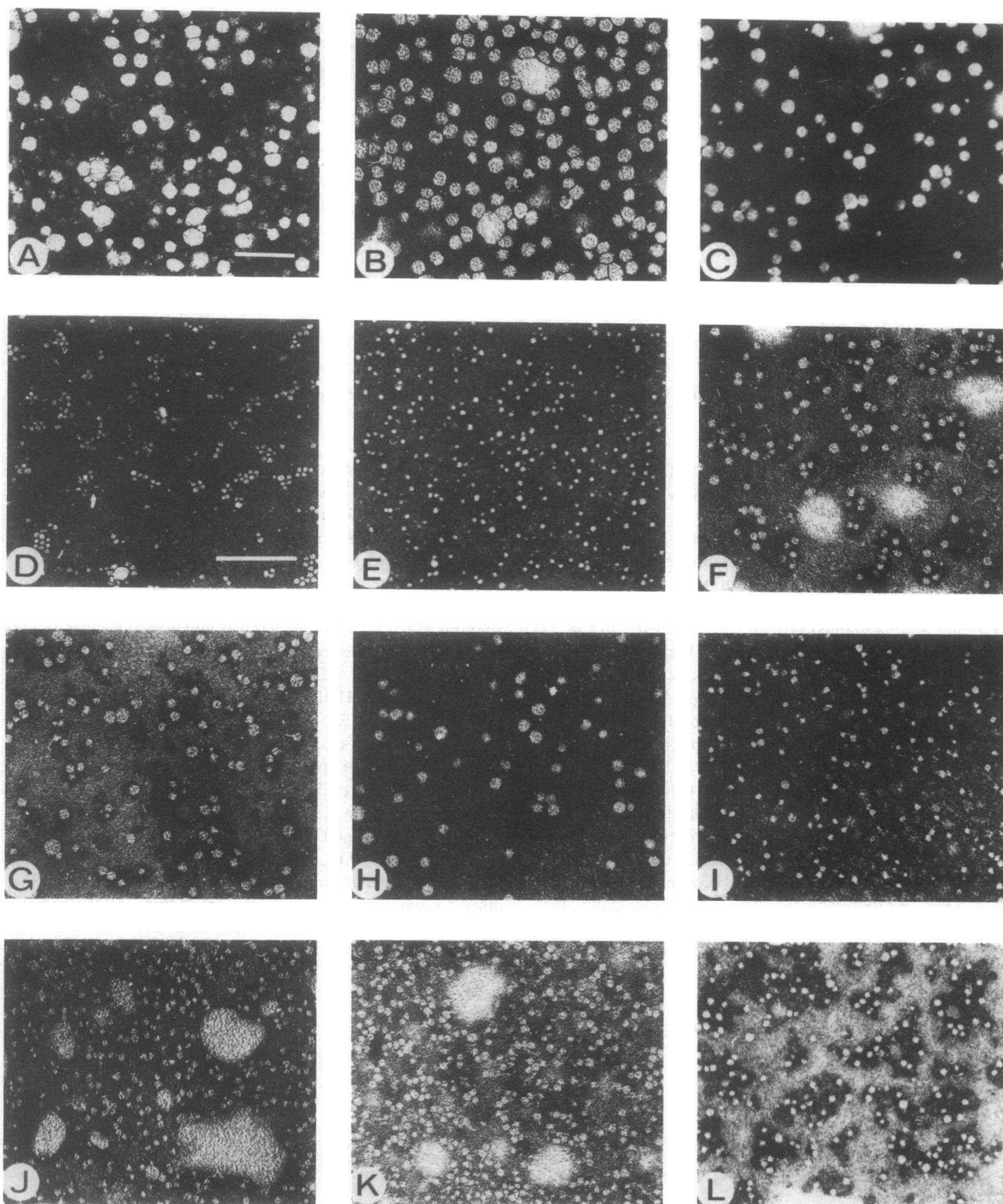
and HDL<sub>3</sub> obtained from patients after an oral fat load gave similar apoproteins electrophoretic patterns. The unusual apo HDL electrophoretic pattern of M.K., Y.Z., and K.Z. resembled that of apo HDL<sub>2</sub> and apo HDL<sub>3</sub> from two patients, S.L. and M.P. (not shown), with abetalipoproteinemia (Fig. 7 D and H), who also exhibited other protein bands with electrophoretic mobilities between those of AI and AII, as well as the increased amounts of apo E and E–AII complex and high molecular weight bands. By isoelectric focusing, the apoproteins from the HDL subfractions (HDL<sub>1</sub>, HDL<sub>2</sub>, and HDL<sub>3</sub>) of A.B., Y.Z., and K.Z. resembled normal HDL apoproteins having the major apo E isomorphs (E<sub>2</sub>, E<sub>3</sub>, E<sub>4</sub>), the four major apo AI isomorphs (AI<sub>1</sub>, AI<sub>2</sub>, AI<sub>3</sub>, and AI<sub>4</sub>), plus a weak additional band in the acidic range, two bands for apo AII (the most intense being the most basic one), the three CIII isomorphs (CIII<sub>0</sub>, CIII<sub>1</sub>, and CIII<sub>2</sub>), and CII, although in decreased amounts relative to normal apo HDL (Fig. 8, A, B, and D).

One subject, M.K., had an apo HDL isoelectric focusing pattern that differed from those of normal individuals and the other Anderson's disease patients. In addition to the protein bands previously described, the apo HDL (apo HDL<sub>1</sub>, as well as apo HDL<sub>2</sub> and apo HDL<sub>3</sub>) from this patient had three ad-

Table V. Content and Composition of HDL<sub>3</sub>\* Fasting and 3 h after an Oral Load†

Subject	Total mass		Composition							
			P§		PL§		C§		TG§	
	Fasting	3 h	Fasting	3 h	Fasting	3 h	Fasting	3 h	Fasting	3 h
	mg/dl	mg/dl	%	%	%	%	%	%	%	%
K.Z.	58	44	50	50	26	27	15	14	9	9
Y.Z.	35	47	54	53	26	28	11	13	9	6
A.B.	64	87	53	52	28	29	14	14	5	6
A.H.	63		67		19		10		4	
M.B.	39		51		31		15		3	
M.K.	58	57	52	51	28	28	15	16	5	5
Normal fasting range	200		51–53		27–29		14–16		5–7	

\* Density 1.125–1.21 g/cm<sup>3</sup>. ‡ 50-g/fat load. § P, protein; PL, phospholipids; C, free plus esterified cholesterol; and TG, triglycerides.



**Figure 5.** Electron microscopy of isolated lipoproteins. Negative staining with 2% phosphotungstic acid of LDL from A.B. (A), H.A. (B), and M.B. (C); of HDL<sub>2</sub> from H.A. (D), M.B. (E), A.B. (F), and M.K. (G); and of HDL<sub>3</sub> from M.K. (H), M.B. (I), A.B. (J), H.A. (K), and

K.Z. (L). The scale for A, B, and C is denoted by the bar in A which represents 100 nm. The scale for D–L is denoted by the bar in D, which also represents 100 nm.

ditional protein bands, two slightly more acidic than the apo E<sub>2</sub> and E<sub>3</sub> isomorphs, respectively, and one present between the strongest AII isomorph and the most acidic AI isomorph (Fig.

8, C and E). This pattern resembled that of apo HDL from a patient with abetalipoproteinemia (S.L.) (Fig. 8 F). Similar patterns were obtained after an oral fat load.

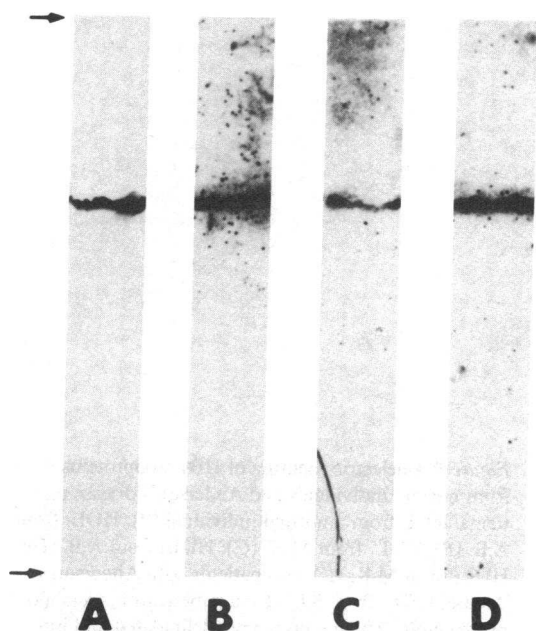


Figure 6. Polyacrylamide (4%) gel electrophoresis in SDS of apo B (10 µg) of VLDL and total LDL from Anderson's disease patients. LDL from a normal individual (A), VLDL from H.A. (B), and total LDL density < 1.063 g/cm<sup>3</sup> from A.B., before (C), and 3 h after an oral fat load (D). The arrows denote the top of the gel and the position of the tracking dye at the bottom of the gel.

## Discussion

The seven patients with intestinal malabsorption described here all exhibit features typical of Anderson's disease: diarrhea, steatorrhea, decreased serum cholesterol and phospholipids, decreased serum  $\alpha$ - and  $\beta$ -lipoproteins, absence of chylomicrons postprandially, and intestinal cells filled with lipid droplets. The presence of serum LDL and the absence of acanthocytosis, retinitis pigmentosa, and ataxia, distinguishes the disease from abetalipoproteinemia, and the presence of heavily fat-laden enterocytes distinguishes Anderson's disease from hypobetalipoproteinemia. The numerous Oil red O-positive lipid droplets in

the jejunal mucosa suggest that absorption of fatty acids into the intestinal cells and subsequent esterification into triglycerides does indeed take place. However, a block in the normal exit of lipids from these cells is attested to by the absence of chylomicrons and intestinal VLDL after a fat load. Given the well-established role for apolipoproteins in intestinal fat absorption, one possible etiology for Anderson's disease could be the absence of B48. The results of the present study demonstrate that although B48 is apparently absent from the plasma, large amounts of material that react with a polyclonal antibody to apo B is nevertheless present in the enterocytes of patients with Anderson's disease. Compared with enterocytes from normal fasting individuals in which the immunoperoxidase staining is localized primarily in the supranuclear region corresponding to the Golgi apparatus, the reactive material of the enterocytes from fasting patients was markedly increased throughout the cytoplasm. This distribution resembles much more that seen in the cells of normal individuals after a fat meal and is consistent with an increased process of apoprotein synthesis and chylomicron formation (14, 39). Another very interesting observation is the heterogeneity observed among the enterocytes from patients with Anderson's disease. Some were long and without lipid droplets with little anti-apo B peroxidase staining, and resembled enterocytes from normal fasting individuals, while others (from the same individual) were large and fat loaded and heavily anti-apo B peroxidase stained. This is not due to contamination of villus cells by crypt cells or by immature cells originating from the lower two-thirds of the villus, since intact biopsy sections show oil Red staining of one side but not the other of the upper one-third of some villi.

The nature of the immunoreactive material in the enterocytes of two patients was further defined using several different monoclonal antibodies, some of which recognize only the B100 form of apo B while others recognize both the B100 and B48 forms. The former antibody strongly reacted with liver cells, whereas the later ones reacted with normal and Anderson's patients' enterocytes, normal hepatocytes and Hep G2 cells. However, the B100-specific monoclonal antibodies strongly react with normal hepatocytes or Hep G2 cells, but not with enterocytes. All these results suggest that the immunoreactive material stored in the patients enterocytes is related to B48. Therefore, the etiology of

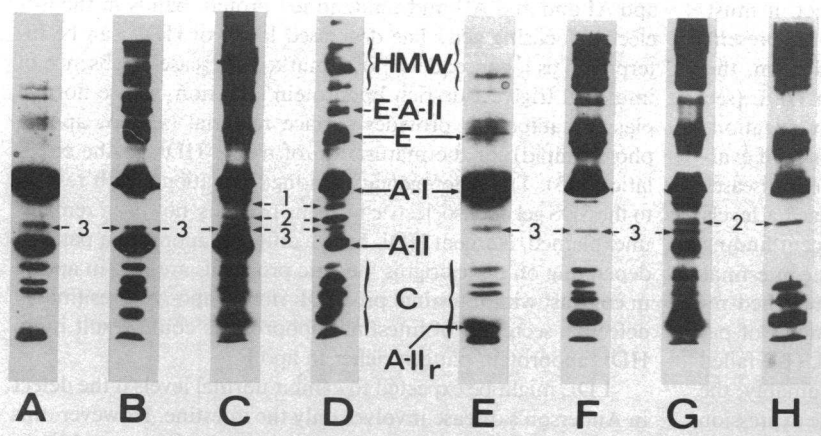
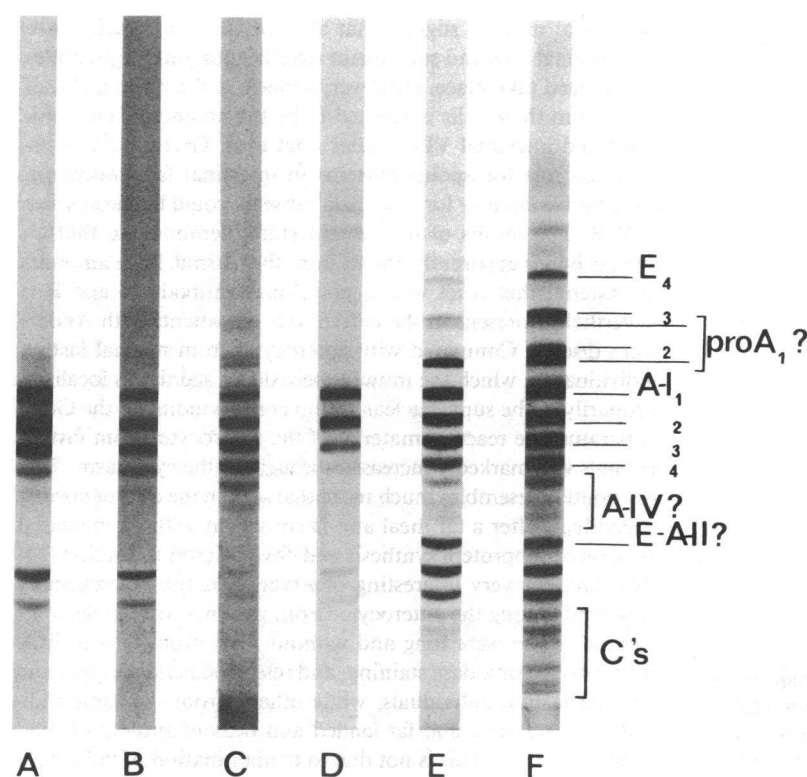


Figure 7. Polyacrylamide gel electrophoresis in SDS of HDL apoproteins from normal individuals and Anderson's disease patients. HDL<sub>3</sub> came from a normal individual, A and E; HDL<sub>3</sub> from A.B., B and F; HDL<sub>3</sub> from K.Z., C and G; Anderson's disease patients and HDL<sub>3</sub> from S.L., D and H. A patient with abetalipoproteinemia was delipidated and the apoproteins separated on a 15% polyacrylamide gel in SDS, and the proteins stained with Coomassie Brilliant Blue, A and E, or silver, B, C, D, F, G, and H. Gels A-D are non-reduced, while gels E-H have been reduced with beta-mercaptoethanol. The gel patterns are characterized by the presence of AI, AII, reduced AII (AIIr), C, E, E-AII, and high molecular weight proteins (HMW), which are denoted by arrows. There are a number of additional protein bands, also denoted by arrows, having electrophoretic mobilities between AI and AII.

Some patients, represented by A.B., have apo HDL gel patterns that resemble normal apo HDL, except for increased amounts of apo E, E-AII, and high molecular weight components. Other patients, represented by K.Z., have apo HDL gel patterns that resemble more closely those of apo HDL from abetalipoproteinemic patients, having additional protein bands with electrophoretic mobilities intermediate between AI and AII.



**Figure 8.** Isoelectric focusing of HDL apoproteins from normal individuals and Anderson's disease patients. HDL from a normal individual (A); HDL<sub>1</sub> from A.B. (B); HDL<sub>1</sub> from M.K. (C); HDL<sub>3</sub> from A.B. (D); HDL<sub>3</sub> from M.K. (E); two patients with Anderson's disease; HDL<sub>1</sub> from S.L. (F); a patient with abetalipoproteinemia. The fractions were delipidated and isoelectric focusing performed over a pH 4–6.5 gradient. Some patients, as represented by A.B., have gel patterns similar to normals, while others, represented by M.K., have patterns similar to abetalipoproteinemic individuals.

the disease does not involve the deletion of B48 in the enterocyte. Although the structure of the stored protein has not yet been established, it can be suggested that some abnormality in the amino acid sequence or a posttranslational defect (glycosylation, phosphorylation, tertiary structure, etc.) prevents the protein from binding to lipids, or the chylomicron from being secreted. Other defects independent from normal chylomicron production might also interfere with the transport and exocytosis of lipoproteins, including dysfunction of the microtubular system.

Alternatively, lack of synthesis or maturation of other apoproteins (apo AI, AII, AIV) could be responsible for a defect in chylomicron secretion. Since the precise role of these apoproteins in intracellular lipoprotein processing is unknown, genetic disorders could help in understanding the miscellaneous processes of lipoprotein assembly and secretion. In this respect, it must be emphasized that apoproteins AI, AII, AIV, and C are present in reduced amounts in the patients' plasma; in addition, the immature pro apo AI form seems to be present in HDL (see Fig. 8 C), a finding that is under more extensive investigation. In any case, the present results attest to the importance of evaluating apoprotein synthesis at the cellular level in genetic diseases characterized by the absence or abnormally low plasma levels of lipoproteins. This is further underlined by our recent finding of a presence of apo B immunoreactive material in the intestinal cells from a child with abetalipoproteinemia (unpublished results). Previously reported immunofluorescence studies of patients with abetalipoproteinemia by Glickman et al. (14) failed to find any apo B in intestinal biopsies. Thus, presumably, the same phenotype, abetalipoproteinemia, could be the expression of different molecular genetic disorders.

In addition to the immunohistochemical findings, several other abnormalities were noted in patients with Anderson's dis-

ease. Levels of HDL were decreased in all our subjects in accordance with previously reported observations (6–8). Low HDL levels are not uncommon in other disorders involving apo B: normotriglyceridemic abetalipoproteinemia (9, 10), recessive abetalipoproteinemia (40), homozygous hypobetalipoproteinemia (41), and the syndrome described by Steinberg et al. (42). As compared with normal HDL<sub>2</sub> and HDL<sub>3</sub>, we found increased amounts of apo E, and similarly with cases of abetalipoproteinemia, found increased amounts of the E–AII complex (40, 43, 44). In patients having increased amounts of E–AII complex, HDL<sub>2</sub> and HDL<sub>3</sub> were found to have larger than normal particle diameters. Large HDL<sub>2</sub> rich in apo E have also been described in cases of abetalipoproteinemia (44). Finally, as for some cases of abetalipoproteinemia (40), some of our patients had additional proteins with electrophoretic mobilities intermediate between apo AI and apo AII and unidentified protein bands in the isoelectric focusing gels. The decreased levels of HDL can be interpreted as a consequence of a marked decrease or absence of intestinal triglyceride-rich lipoprotein secretion, whose normal plasma catabolism provides surface material (apo A, apo C, phospholipid) for the maturation of native HDL in the circulation (45). The heterogeneity among the patients with respect to the SDS gel and isoelectric focusing patterns, however, remains unexplained. Nascent HDL have a different apoprotein pattern, depending on their origins: hepatic pro HDL are rich in apo E, in contrast with intestinal pro HDL rich in apo As. Presumably defective secretion of intestinal lipoproteins could result in an HDL apoprotein pattern richer in apo E.

LDL might be expected to exhibit normal levels if the defect in Anderson's disease involves only the intestine. However, this is not the case: total LDL levels are, on the average, ~50% of normal, and this hypobetalipoproteinemia, in fact a reduced level of B100, is a characteristic feature of Anderson's disease.

Further, the LDL composition is markedly altered (in two patients) with an increased amount of triglyceride and phospholipid and decreased amounts of cholesterol. Note, however, that secondary and transient hypobetalipoproteinemia are frequent in other intestinal diseases, associated with severe diarrhea-like celiac disease or sprue. These secondary forms of hypobetalipoproteinemia could result from an increased catabolic rate of LDL or through an enhanced activity of hepatic-receptor-mediated uptake.

Since the primary defect in Anderson's disease seems to be a lack of lipoprotein secretion by the intestine, low levels of LDL and B100 that derive mainly from hepatic VLDL would suggest that B100 synthesis by the liver could be in some way regulated by the influx of B48 as chylomicron remnants. Alternatively, the virtual absence of alimentary fatty acids, a physiological inducer of apo B synthesis and a substrate for VLDL triglyceride synthesis, could result in a decreased VLDL secretion by the liver and subsequently low plasma levels of LDL and B100. Whatever the biochemical mechanism, some relationship seems to exist between chylomicron catabolism and VLDL production by the liver; for instance, in type I hyperlipemia, a primary defect of chylomicron catabolism, low levels of VLDL and LDL are frequently associated with hyperchylomicronemia.

The anomaly of the lipoprotein and apoprotein patterns in Anderson's disease patients involves, besides the apo B-containing lipoproteins, a number of other features: low levels of apo AI, AII, and C, increased amounts of apo E and E-AII complex in HDL, some nonidentified apoproteins bands including, perhaps, pro apo AI, abnormal size of HDL particles, etc. Whether this ensemble is secondary to a single genetic error involving intestinal apo B or to a disturbance in chylomicron secretion is, until now, unclear, and deserves further investigation.

## Acknowledgments

The authors are indebted to Dr. J. Rey (Hôpital des Enfants Malades, Paris), who initiated the study of Anderson's disease several years ago. Special thanks are due to our technicians, Mrs. N. Verthier for immunoperoxidase studies and Mrs. D. Catala for preparation of polyclonal antibodies. Part of this work was done in Prof. J. Polonovski's laboratory (Centre National de la Recherche Scientifique UA 524, Paris); we would like to thank Dr. S. Goldstein for determination of specificity of some monoclonal antibodies, Mrs. D. Pastier and M. Cagny for excellent technical assistance, and Mr. R. Rebouret for preparation of monoclonal antibodies. The authors are specially grateful to Mrs. N. Lachasinski, who collaborated on monoclonal antibodies characterization in the Luzzati laboratory (Centre de Génétique Moléculaire, Centre National de la Recherche Scientifique, Gif/yvette), to Mrs. E. Audran (Hôpital des Enfants Malades, Paris) for sucrose assays, to Dr. M. Aggerberck (Institut National de la Santé et de la Recherche Médical U.99, Paris), and to Dr. R. Bertolotti (C.G.M., C.N.R.S., Gif/yvette), who provided Hep G<sub>2</sub> cells.

## References

1. Anderson, C. M., R. R. W. Townley, and J. P. Freeman. 1961. Unusual causes of steatorrhea in infancy and childhood. *Med. J. Aust.* 11:617-621.
2. Salt, H. B., O. H. Wolff, J. K. Lloyd, A. S. Fosbrooke, A. F. Cameron, and D. V. Hubble. 1960. On having no betalipoproteins. A syndrome comprising abetalipoproteinemia, acanthocytosis and steatorrhea. *Lancet*. ii:325-329.
3. Lamy, M., J. Frezal, J. Rey, J. Jos, C. Nezelof, A. Herrault, and J. Cohen-Solal. 1967. Diarrhée chronique par trouble du transport intra cellulaire des lipides. *Arch. Fr. Pédiatr.* 24:1079. (Abstr.)
4. Silverberg, M., J. Kessler, P. Z. Neumann, and F. W. Wigglesworth. 1968. An intestinal lipid transport defect. A possible variant of hypo- $\beta$ -lipoproteinemia. *Gastroenterology*. 54:1271. (Abstr.)
5. Partin, J. C., and W. K. Schubert. 1970. Jejunal mucosa biopsy studies in two new types of hypo-betalipoproteinemia: light, electron microscopical and biochemical analysis. *Gastroenterology*. 58:1022. (Abstr.)
6. Polonovski, C., J. Navarro, J. L. Fontaine, F. de Gouyon, J. M. Saudubray, and L. Cathelineau. 1970. Maladie d'Anderson. *Ann. Pédiatr. (Paris)*. 17:342-354.
7. Rey, J. 1973. Disturbances in fat absorption in intestinal enzyme deficiencies and their nutritional implication. B Borgstrom, A. Dahlquist, and L. Hambraens, editors. *Swedish Nutrition Foundation Symposia XI, Uppsala*. 143-147.
8. Costil, J. 1976. Maladie d'Anderson. In *Journées parisiennes de Pédiatrie*. Flammarion, Paris. 229-239.
9. Malloy, M. J., J. P. Kane, A. Hardman, R. L. Hamilton, and K. B. Dalal. 1981. Normotriglyceridemic abetalipoproteinemia. Absence of the B100 apolipoprotein. *J. Clin. Invest.* 67:1441-1450.
10. Takashima, Y., T. Kodama, H. Lida, M. Kawamura, H. Aburatani, H. Itakura, Y. Akanuma, F. Takaku, and M. Kawade. 1985. Normotriglyceridemic abetalipoproteinemia in infancy: an isolated apolipoprotein B100 deficiency. *Pediatrics*. 75:541-546.
11. Buts, J. P., C. C. Roy, C. L. Morin, and C. M. Weber. 1978. Hypobetalipoproteinemia with a celiac like syndrome in childhood. *Acta Paediatr. Belg.* 31:104-105. (Abstr.)
12. Roy, C. C., A. Sniderman, R. Deckelbaum, J. Letarte, P. Brochu, A. Weber, C. L. Morin, J. P. Buts, and P. Green. 1982. Normal concentrations of serum and increased intestinal apo-B with failure of chylomicron secretion: a new disorder of lipid transport. *Pediatr. Res.* 16:175A. (Abstr.)
13. Glickman, R. M., J. Khorana, and A. Kilgore. 1976. Localization of apolipoprotein B in intestinal epithelial cells. *Science (Wash. DC)*. 193:1254-1255.
14. Glickman, R. M., P. H. R. Green, R. S. Lees, E. L. Samuel, and A. Kilgore. 1979. Immunofluorescence of apolipoprotein B in intestinal mucosa. Absence in abetalipoproteinemia. *Gastroenterology*. 76:288-292.
15. Weiser, M. M. 1973. Intestinal epithelial cells surface membrane glycoprotein synthesis. I. An indicator of cellular differentiation. *J. Biol. Chem.* 248:2536-2541.
16. Pessah, M., C. Salvat, N. Amit, and R. Infante. 1985. Isolation and characterization of rat intestinal polyribosomes and RNA during absorption of fat. Increased translation in vivo of apo-AIV. *Biochem. Biophys. Res. Commun.* 126:373-381.
17. Ballet, F., M. E. Bouma, S. R. Wang, N. Amit, J. Marais, and R. Infante. 1984. Isolation, culture and characterization of adult human hepatocytes from surgical liver biopsies. *Hepatology*. 4:849-854.
18. Bouma, M. E., N. Amit, and R. Infante. 1981. Localization of apo-B and apo-C in rat intestinal epithelium by immunoenzymatic techniques. *Biol. Cell*. 41:123-131.
19. Graham, R. C., U. Lundholm, and M. J. Karnovski. 1965. Cytochemical demonstration of peroxidase activity with 3 amino-9 ethyl-carbazole. *J. Histochem. Cytochem.* 13:150-152.
20. Salmon, S., S. Goldstein, D. Pastier, L. Heron, M. Berthelier, M. Ayrault-Jarrier, M. Dubarry, R. Rebouret, and B. Pau. 1984. Monoclonal antibodies to low density lipoprotein used for the study of low and very low density lipoprotein in Elisa and immunoprecipitation techniques. *Biochem. Biophys. Res. Commun.* 125:704-711.
21. Aggerbeck, L. P., F. Caron, N. Lachacinski, and M. E. Bouma. 1986. Isolation and characterization of three monoclonal antibodies to human serum low density lipoprotein apoprotein-B. *Biochimie*. 68:531-541.
22. Bouma, M. E., N. Amit, and R. Infante. 1979. Ultrastructural



localization of apo-B and apo-C binding to very low density lipoproteins in rat liver. *Virchows Arch. B. Cell Pathol.* 30:161-180.

23. Kane, J. P., D. A. Hardman, and M. E. Paulus. 1980. Heterogeneity of apolipoprotein B: isolation of a new species from human chylomicrons. *Proc. Natl. Acad. Sci. USA.* 77:2465-2469.

24. Havel, R., H. A. Eder, and J. H. Bragdon. 1955. The distribution and chemical composition of ultracentrifugally separated lipoproteins in human serum. *J. Clin. Invest.* 34:1345-1353.

25. Douste-Blazy, L., I. Beucler, V. Blaton, J. Canal, J. C. Fruchart, P. Gamber, R. Katterman, J. Peynet, J. Polonovski, J. Steinmetz, and J. P. Thouvenot. 1981. Definitive method for total serum cholesterol assay. *Ann. Biol. Clin.* 39:143-146.

26. Whaley, A. W. 1974. Triglycerides: determination after enzymatic hydrolysis. In *Methods in Enzymatic Analysis*. H. U. Bergmeyer, editor. Academic Press, Inc., New York. 4:1831-1835.

27. Takayama, M., S. Itoh, J. Nagasaki, and I. Tanimizu. 1977. A new enzymatic method for determination of serum choline containing phospholipid. *Clin. Chem. Acta.* 79:93-98.

28. Ayrault-Jarrier, M., D. Bobilewicz, D. Pastier, I. Beucler, and J. Polonovski. 1982. Dosage immunologique de l'apo-AI. *Ann. Biol. Clin.* 40:187-194.

29. Beucler, I., P. Laburre, and A. Legrand. 1984. Methode de dosage des apo- B. *Inform. Sci. Biol.* 10:227-230.

30. Laurell, C. B. 1981. Quantitative estimation of protein by electrophoresis in agarose gel containing antibodies. *Ann. Biochem.* 15:45-52.

31. Brown, W. V., R. I. Levy, and D. S. Fredrickson. 1966. Studies of the proteins in human plasma VLDL. *J. Biol. Chem.* 244:5686-5694.

32. Peterson, G. L. 1977. A simplification of the protein assay method of Lowry et al., which is more generally applicable. *Anal. Biochem.* 83:346-356.

33. Aggerbeck, L. P., and D. L. Peterson. 1985. Electron microscopic and solution X-ray scattering observations on the structure of hepatitis B surface antigen. *Virology.* 141:155-161.

34. Wrigley, N. G. 1968. The lattice spacing of crystal line catalase

as internal standard of length in electron microscopy. *J. Ultrastruct. Res.* 24:454-464.

35. Utermann, G., U. Langenback, U. Beisiegel, and W. Weber. 1980. Genetics of the apolipoprotein E system in man. *Am. J. Hum. Genet.* 32:339-347.

36. Laemmli, U. K. 1970. Cleavage of structural proteins during the assembly of the head of bacteriophage T4. *Nature (Lond.).* 227:680-685.

37. Fairbanks, G., T. L. Steck, and D. F. H. Wallach. 1971. Electrophoretic analysis of the major polypeptides of the human erythrocyte membrane. *Biochemistry.* 10:2606-2617.

38. Oakley, B. R., D. R. Kirsch, and N. R. Morris. 1980. A simplified ultrasensitive silver stain for detecting proteins in polyacrylamide gels. *Anal. Biochem.* 105:361-363.

39. Schonfeld, G., E. Bell, and D. H. Alpers. 1978. Intestinal apoproteins during fat absorption. *J. Clin. Invest.* 61:1539-1550.

40. Scanu, A. M., L. P. Aggerbeck, A. W. Krushi, C. T. Lim, and H. J. Kayden. 1974. A study of the abnormal lipoproteins in abetalipoproteinemia. *J. Clin. Invest.* 53:440-453.

41. Herbert, P. N., G. Assmann, A. M. Gotto, and D. S. Fredrickson. 1978. Familial lipoprotein deficiency. In *The Metabolic Basis of Inherited Disease*. J. S. Stanbury, J. B. Wyngaarden, and D. S. Fredrickson, editors. McGraw-Hill, Inc., New York. 589-621.

42. Steinberg, D., S. M. Grundy, H. Y. I. Mok, J. D. Turner, D. B. Weinstein, W. V. Brown, and J. J. Albers. 1979. Metabolic studies in an unusual case of asymptomatic familial hypobetalipoproteinemia and fasting chylomicronemia. *J. Clin. Invest.* 64:292-304.

43. Weisgraber, K. H., and R. Mahley. 1978. Apo-E-AII complex of human plasma lipoproteins. I. Characterization of this mixed disulfide and its identification in a HDL subfraction. *J. Biol. Chem.* 253:6281-6288.

44. Deckelbaum, R. J., S. Eisenberg, Y. Oschry, M. Cooper, and C. Blum. 1982. Abnormal HDL of abetalipoproteinemia: relevance to normal HDL metabolism. *J. Lipid Res.* 23:1274-1282.

45. Eisenberg, S. 1984. High density lipoprotein metabolism. *J. Lipid Res.* 25:1017-1058.