

Comparison of Spontaneous and Experimentally Induced Canine Prostatic Hyperplasia

D. P. DEKLERK, D. S. COFFEY, L. L. EWING, I. R. MCDERMOTT, W. G. REINER, C. H. ROBINSON, W. W. SCOTT, J. D. STRANDBERG, P. TALALAY, P. C. WALSH, L. G. WHEATON, and B. R. ZIRKIN, *The James Buchanan Brady Urological Institute, Department of Urology, Department of Population Dynamics, Division of Comparative Medicine, Department of Pathology, Department of Pharmacology and Experimental Therapeutics, and Department of Surgery, The Johns Hopkins University, Baltimore, Maryland 21205*

ABSTRACT Spontaneous prostatic hyperplasia in the beagle appears to progress with age from a glandular to a cystic histological appearance. Prostatic hyperplasia can be induced in young beagles with intact testes by treatment for 4 mo with either dihydrotestosterone or 5α -androstane- $3\alpha,17\beta$ -diol, alone, or with either of these steroids in combination with 17β -estradiol. In contrast, the induction of prostatic hyperplasia in young castrated beagles, in which the gland had been allowed to involute for 1 mo, requires the administration of both 17β -estradiol and either 5α -androstane- $3\alpha,17\beta$ -diol or dihydrotestosterone. Testosterone and 17β -estradiol, either singly or in combination, did not produce the hyperplastic condition in intact or castrated beagles. The experimentally induced prostatic hyperplasia is identical in pathology to the glandular hyperplasia that occurs naturally in the aging dog with intact testes. However, cystic hyperplasia was not produced by any of the treatments tested in young animals.

INTRODUCTION

Prostatic hyperplasia in the dog has been studied extensively (1-8) and is at present the only widely available animal model for the human disease (9). Canine prostatic hyperplasia is believed by many investigators to be an appropriate model for the study of human benign prostatic hyperplasia, although there are important differences between the conditions in the two species (5). Thus, the human disease is often a multinodular process thought to arise as a periurethral stromal nodule, which is then secondarily invaded by glandular

elements (10, 11). In contrast, canine prostatic hyperplasia is a diffuse epithelial or glandular process with less stromal involvement (12).

Considerable interest has been generated by the report of Walsh and Wilson (13) that prostatic hyperplasia can be induced in castrate mongrel dogs by the long-term administration of 5α -androstane- $3\alpha,17\beta$ -diol in combination with 17β -estradiol, and by the proposals of Jacobi et al. (14) on the possible mechanisms underlying this phenomenon. The experiments to be described were motivated by the belief that characterization and comparison of the spontaneous and experimentally induced prostatic hyperplasia in the dog may provide important insight into the etiology of the disease not only in this species but also in man.

In the first phase of this study, the incidence, pathology, and development of spontaneous prostatic hyperplasia were studied in 41 beagles of known age. In the second phase, prostatic hyperplasia was induced in young beagles by hormonal treatment (13) under controlled conditions. In the latter experiments a comparison has been made of the effectiveness in inducing prostatic hyperplasia of testosterone, dihydrotestosterone, and 5α -androstane- $3\alpha,17\beta$ -diol alone, and in combination with 17β -estradiol. In addition, the role of the testes and epididymides in the experimental induction of canine prostatic hyperplasia has been studied. The pathological and biochemical characteristics of the spontaneous and experimentally induced disease have been compared.

METHODS

Animals. 109 young male beagles (mean age \pm SD, 2.3 ± 0.3 yr; range, 1.6-3 yr), and an additional 35 beagles of various ages (range, 1.2-10.5 yr), were obtained from Laboratory Research Enterprises Ltd., Kalamazoo, Mich. and Buckshire Farms, Pa. The birthdate and pedigree of each animal was

Address reprint requests to Dr. Coffey, Department of Urology, The Johns Hopkins Hospital, Baltimore, Md. 21205.

Received for publication 24 January 1979 and in revised form 8 May 1979.

available. Body weights ranged from 7.0 to 18.6 kg (11.3±2.2 kg; mean±SD).

Drugs. Testosterone, dihydrotestosterone, and 17 β -estradiol were purchased from Steraloids, Pawling, N. Y., and were purified to homogeneity, if necessary. Melting points were determined on a Koffler Hot-Stage (Arthur H. Thomas Co., Philadelphia, Pa.) and were uncorrected. Thin layer chromatography was carried out with silica gel GF₂₅₄ and chloroform:acetone (9:1), unless stated otherwise. High pressure liquid chromatography was performed on a model 6000 high pressure liquid chromatograph with μ -Corasil C₁₈ reversed phase column (Waters Associates, Inc., Milford, Mass.) as the stationary phase and methanol:water (3:1) as the eluant.

Testosterone was recrystallized from aqueous acetone to give colorless needles mp 153°–154°C (154°–154.5°C [15]), which were homogeneous by thin layer chromatography (R_f , 0.34) and by high pressure liquid chromatography ($k' = 1.00$). Impurities were removed from dihydrotestosterone by recrystallization from ethyl acetate to give transparent needles, mp 180°–181°C (181.5°–182.5°C [16]), which were homogeneous by thin layer chromatography (R_f , 0.45) and high pressure liquid chromatography ($k' = 1.55$). 5 α -Androstane-3 α ,17 β -diol was prepared by sodium borohydride reduction of androstosterone. Subsequent recrystallization from aqueous methanol gave pure 5 α -androstane-3 α ,17 β -diol, mp 222°–224°C (223°C [17]), which was indistinguishable from an authentic sample by thin layer chromatography (R_f , 0.24) and by high pressure liquid chromatography ($k' = 2.08$). 17 β -Estradiol, mp 176°–177°C (176°–178°C [18]), was shown to be homogeneous by all chromatographic criteria (R_f , 0.63 in benzene:ethyl acetate (1:1); $k' = 0.97$) and was used without further purification.

Each androgen (25 mg/ml) was finely powdered and suspended in triolein (practical grade, Sigma Chemical Co., St. Louis, Mo.). 17 β -Estradiol was dissolved (0.25 mg/ml) in triolein. Triolein was found to have no androgenic or anti-androgenic activity in the rat ventral prostate bioassay (19) and no estrogenic or antiestrogenic activity in the immature female mouse uterine bioassay (20).

Injections. The steroids were administered by deep intramuscular injection as a suspension (androgens) or as a solution (17 β -estradiol) in 1 ml of triolein. Control animals received the vehicle only. The injection sites were rotated between the upper and lower, left and right hind leg. Suspensions were sonicated at 40°C for 2 h before administration. Injections were given on Monday, Wednesday, and Friday mornings.

The drugs were administered over a period of 4 mo, from September to January. Each dog received a total of 51 injections. The final injection was given 24 h before termination of the experiment.

Surgery. The initial laparotomy and castration as well as the final removal of organs were done under intravenous pentobarbital anesthesia (15–20 mg/kg). For the initial laparotomy the animals received atropine (0.02 mg/kg) and acetylpromazine maleate (0.2 mg/kg) as premedication. No premedication was given before the final examination of tissues.

For estimation of size before treatment, the prostates were measured at laparotomy in three dimensions (dorsoventral, craniocaudal, and transversely). By regarding the prostate as a cube, an apparent volume was calculated, and the weight was estimated by means of a nomogram (13). The nomogram had been generated in a separate experiment by determining the volume of the prostate from the above measurements and relating these values to the observed weights. A linear relationship was obtained (1 g prostate wt is equivalent to 1.53 cm³; $r = 0.99$). The prostates were not biopsied before treatment.

Where prescribed in the protocol, the castration was done at the time of laparotomy via the abdominal incision and both

epididymides and testes were removed. All animals were allowed 1 mo for recovery (and involution of the prostate in castrated dogs) before initiation of treatments.

Termination of the experiment. Exactly 24 h after the last injection, the animals were anesthetized by intravenous pentobarbital. A midline incision was made and the prostate was remeasured by calipers.

Histology. Two cross-sections were taken from each prostate: one from the left cranial portion and a second from the right midsegment. All sections included the urethral mucosa and the outer margin of the prostate. The tissues were imbedded in paraffin, mounted, and stained with hematoxylin, eosin, and orange G. A study of histological sections by light microscopy was made by a veterinary pathologist (Dr. Strandberg) who had no prior knowledge of the nature of the treatment or the weight of the gland from which each specimen was obtained. The reproducibility of the diagnoses was evaluated by a second examination of the same sections. In 79 of 84 specimens the diagnoses were identical. Ambiguity in five sections was in distinguishing normal histology from early glandular hyperplasia.

Prostate glands classified as normal (Fig. 1) were compound tubuloalveolar glands, which radiated from their duct openings into the urethra. The alveolar portions of the glands contained primary and secondary infoldings of secretory epithelium, which projected into the alveolar lumina. The lumina were not dilated and did not contain obvious secretory material. The alveoli were separated by a denser stroma that also contained smooth muscle cells. These smooth muscle septa were continuous with the capsular stroma surrounding the gland. They also connected with the smooth muscle and fibrous tissue located in the periurethral area.

Prostates were considered to have glandular hyperplasia (Fig. 2) when there was an obvious increase in the amount of secretory epithelium. Each of the lobules was larger and had more elaborate branchings. The alveoli were larger and contained more cells. As a result, the papillary projections of secretory epithelium into the alveoli were more elaborate. In addition, the size of the secretory epithelial cells was increased, principally because of an increase in the amount of cytoplasm. Glandular proliferation occurred in all portions of the sections. It appeared diffuse in the periphery of the prostate, but often assumed a more nodular pattern in the periurethral areas.

Cystic hyperplasia of the prostate (Fig. 3) was characterized by a complex series of changes, which included areas of glandular hyperplasia. These were intermingled with foci in which the secretory epithelium was atrophic and attenuated. In these atrophic areas there was a relative increase in stroma comprising both collagen and smooth muscle. Some of the alveoli were dilated and filled with eosinophilic material. These dilated alveoli formed the cysts that characterize this condition. The nature of the epithelium lining the cysts varied from plump columnar cells with eosinophilic cytoplasm to thin cuboidal cells without obvious morphologic evidence of secretory activity. Cysts were most often found in the periurethral area, although they could be present anywhere in the gland. Chronic inflammation commonly occurred in the stromal bands.

RESULTS

Spontaneous canine prostatic hyperplasia. 41 beagles of known ages were studied to determine the incidence of spontaneous prostatic hyperplasia and changes in prostatic size and pathology with age. The results of these studies are shown in Figs. 4 and 5.

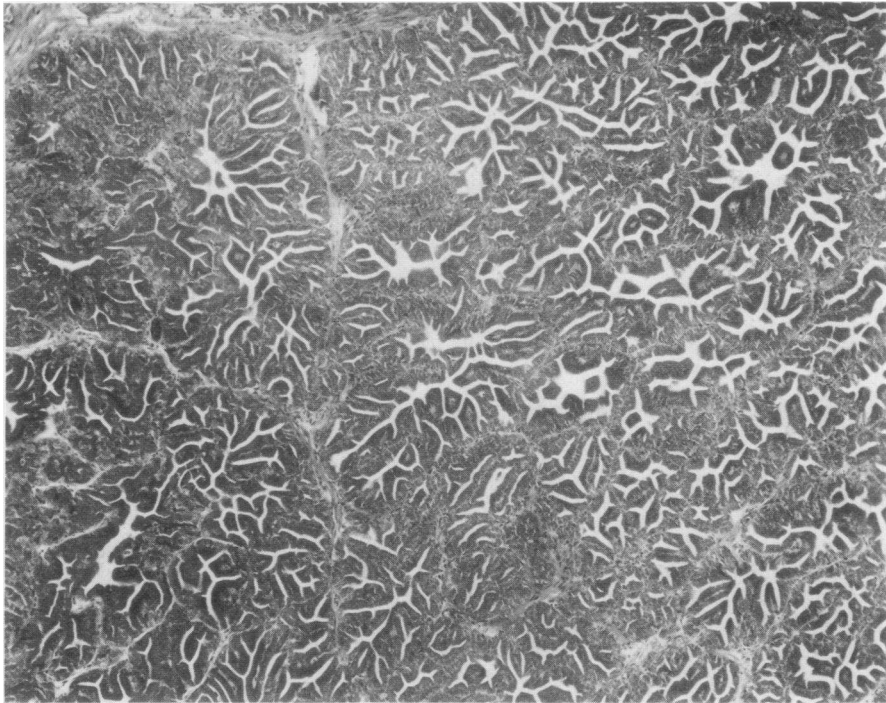


FIGURE 1 Histologically normal prostate gland with well-developed secretory epithelium forming papillary infoldings into alveoli. Interlobular stroma is relatively scant. $\times 60$.

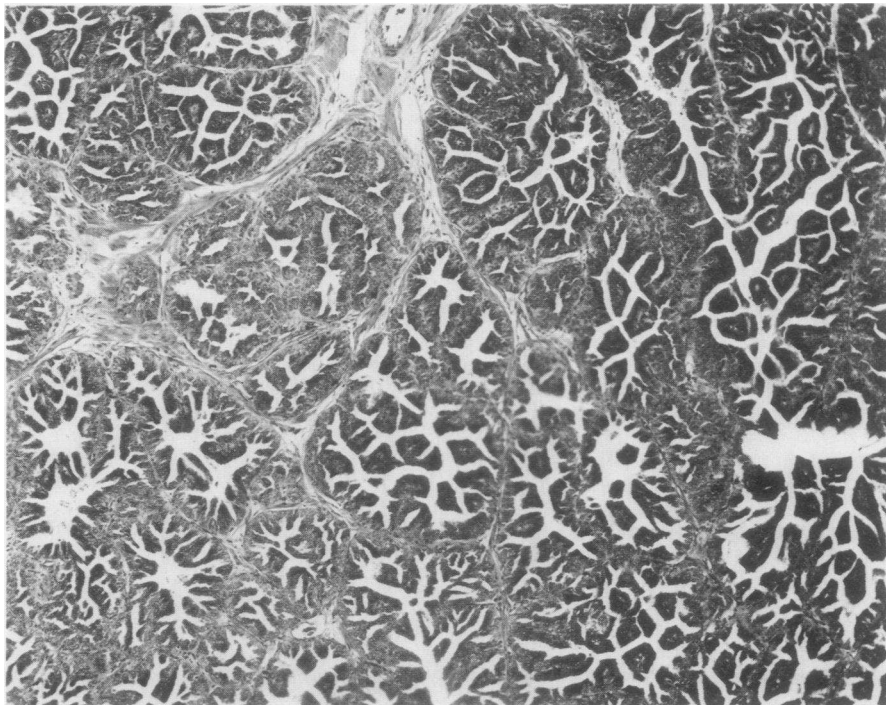


FIGURE 2 Glandular prostatic hyperplasia with increase in size of alveoli and in degree of papillary infolding. Secretory cells are also larger than normal. Amount of stroma is variable but not great. $\times 60$.

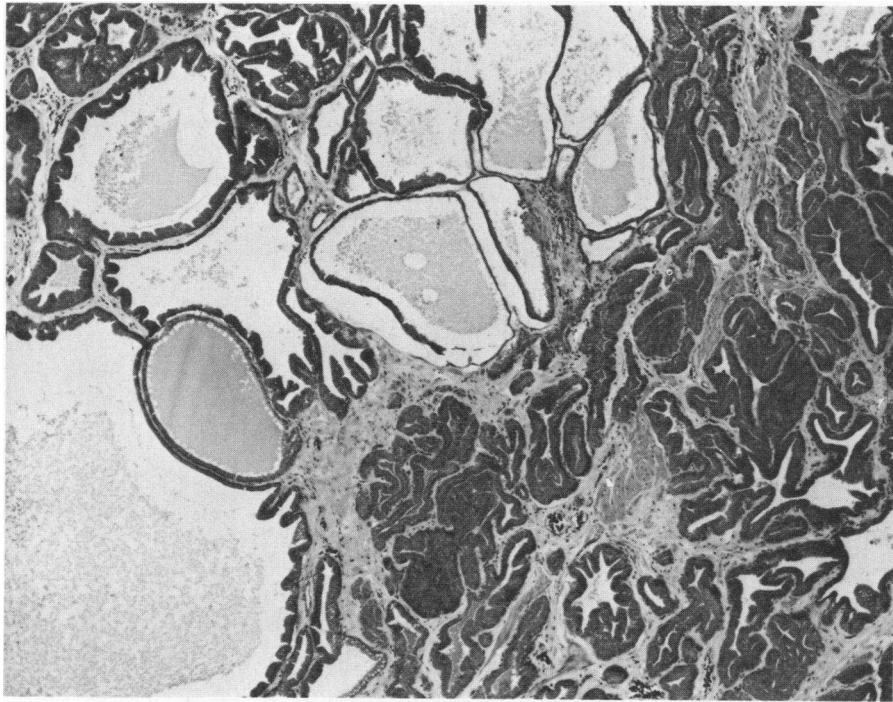


FIGURE 3 Cystic hyperplasia. The histologic picture is extremely varied with areas of glandular hyperplasia admixed with foci of atrophy. Many acini are cystically dilated and filled with eosinophilic material. Stroma is prominent and relatively dense. $\times 60$.

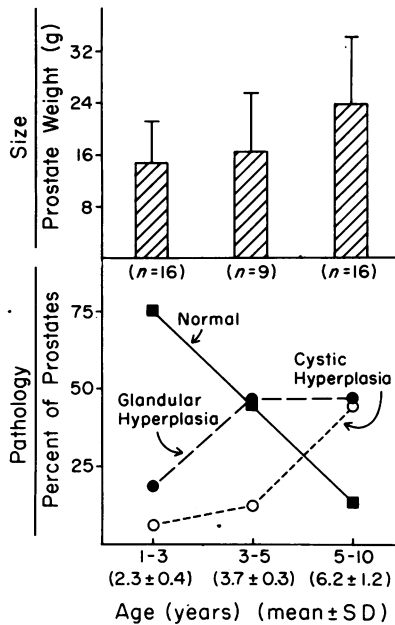


FIGURE 4 Effect of age on the measured weight and pathological appearance of the prostates of 41 beagles. The dogs were divided into the following age groups: 1-3 yr ($n = 16$); 3-5 yr ($n = 9$); and 5-10 yr ($n = 16$). The proportion of normal glands decreases as the weight of the prostates rises, and the incidence of glandular and cystic hyperplasia increases.

There was an increase in prostate wet weight with age from a mean of 14.7 ± 6.4 g (\pm SD) for animals 1-3 yr of age to 23.65 ± 10.45 g for those 5-10 yr old. Occasionally, the 1-3 yr old animals had hyperplastic prostates (cystic, 6%; glandular, 19%) but the majority of glands (75%) in this age group showed normal histology. In contrast, in older animals (5-10 yr) the prostates were frequently hyperplastic (cystic, 44%; glandular 44%), and only 12% were normal. Our observations

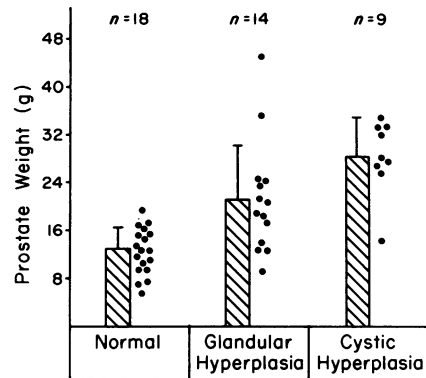


FIGURE 5 Correlation between prostatic weight and development of prostatic hyperplasia (glandular and cystic) in 41 beagles ranging in age from 1-10 yr.

suggest that canine prostatic hyperplasia may develop initially as an adenomatous disease, which later becomes cystic.

In this group of untreated dogs, all prostates (with a single exception) that weighed less than 12.8 g were histologically normal, whereas glands that weighed more than 18 g were hyperplastic. However, in the range of 12.8–18 g both normal and hyperplastic prostates were observed (Fig. 5).

These correlations of weight and histological appearance could not be applied to prostates of androgen-treated dogs, because in these animals, as will be shown below, prostates with normal histology occasionally exceeded 20 g wet wt.

Induced canine prostatic hyperplasia. The estimated prostatic weights (as determined during laparotomy before the initiation of treatment) of 105 beagles ranging in age from 1.5 to 3 yr are shown in Fig. 6. 22 animals had estimated prostatic weights >12.8 g (range, 12.8–42.3 g) and were excluded from the experiment on the induction of prostatic hyperplasia by hormones. 10 of these animals were assigned to other experiments. 12 beagles remained untreated. At autopsy, two had cystic and four glandular hyperplasia, whereas the remaining prostates were histologically normal. 83 dogs had estimated prostatic weights of 12.8 g or less (range, 2.58–12.8 g), and these were selected for hormone treatment.¹ 42 beagles were castrated.² The experimental group consisted of the 42 castrates and 41 intact animals. After a 1-mo recovery period, these 83 animals were treated for 4 mo with androgens and/or 17 β -estradiol, or served as controls, as shown in Table I.

The mean ages, pre- and post-treatment prostatic weights, and histology of castrated and intact dogs treated with androgen and/or 17 β -estradiol are shown in Table I. The mean animal body weight per group ranged from 9.1 to 13.0 kg before treatment (10.9 \pm 1.2 kg), and from 10.2 to 13.9 kg after treatment (12.0 \pm 1.2 kg). The mean estimated prostate weight before treatment ranged from 6.2 to 8.4 g in various groups.

During a 5-mo period, the weights of the prostates of castrated but otherwise untreated dogs decreased by 70% from the initial estimate, whereas in a comparable group of intact control animals the mean prostatic weight increased by 41% and one dog developed spon-

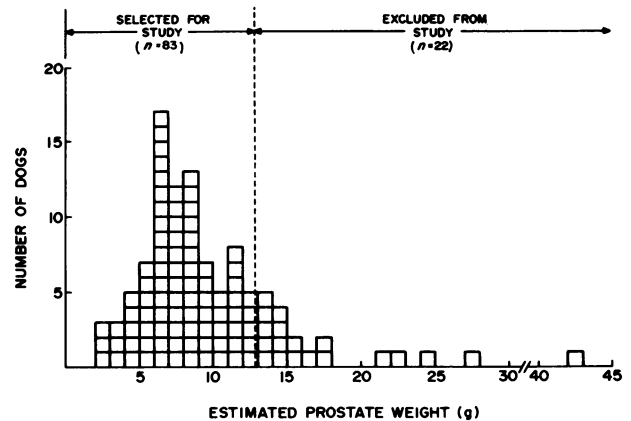


FIGURE 6 Distribution of the estimated weights of the prostates of 105 beagles, aged 1.5–3 yr. The 83 animals with initial prostate weights below 12.8 g were used for the experiments in which hyperplasia was induced by administration of steroid hormones as described in the text.

taneous glandular hyperplasia. In the groups of castrated dogs that had been treated with testosterone, dihydrotestosterone, or 5 α -androstane-3 α ,17 β -diol the prostate weights increased on an average by 120, 181, and 171%, respectively, but the incidence of histologically proven prostatic hyperplasia did not appear to be increased above that observed in the intact control animals.

In the castrated dogs treated with 17 β -estradiol in combination with testosterone, dihydrotestosterone, or 5 α -androstane-3 α ,17 β -diol, the prostatic weights increased on an average by 138, 508, and 451%, respectively. The animals treated with testosterone plus 17 β -estradiol did not show an increased incidence of prostatic hyperplasia (Fig. 4). In contrast, the two groups of dogs treated with dihydrotestosterone or 5 α -androstane-3 α ,17 β -diol in combination with 17 β -estradiol all had significant increases in the incidence of histologically proven glandular prostatic hyperplasia (Fig. 5). The prostatic weights of castrated dogs treated with 17 β -estradiol alone were significantly greater than those of castrated control animals. On histological examination, the prostatic epithelium of the 17 β -estradiol-treated dogs was atrophic, with prominent squamous metaplasia, and the stroma was increased compared with the prostates of castrate controls.

In contrast to the failure to obtain glandular hyperplasia in castrated animals treated with dihydrotestosterone or 5 α -androstane-3 α ,17 β -diol, administration of these androgens to intact animals resulted in a higher incidence of glandular hyperplasia than in untreated intact controls. Treatment of intact dogs with combinations of 17 β -estradiol and either dihydrotestosterone or 5 α -androstane-3 α ,17 β -diol increased the prostatic weight above that found after androgen administration alone, but produced a similar incidence of glandular

¹ The prostate glands of these animals were not biopsied to minimize traumatic artifacts of both local and systemic nature. The evidence supporting the assumption that the glands were histologically normal at the beginning of the experiment is indirect. However, the incidence of abnormal glands in this group is probably very small, because in a separate experiment (Fig. 5), only one gland weighing <12.8 g in 41 beagles ranging in age from 1.5 to 10 yr was abnormal (glandular hyperplasia).

² Bartsch, G., and H. P. Rohr. Personal communication.

TABLE I

Gravimetric and Histological Analyses of the Prostates of Castrate and Intact Beagles Treated with Steroid Hormones

Treatment	Number of dogs	Final age <i>mo</i>	Mean prostate weights (average \pm SD)				Pathology					
			Initial <i>g</i>	Final <i>g</i>	Change <i>%</i>	Atrophy				Hyperplasia		
						Normal	Severe	Focal	+ Squamous metaplasia	Glandular	Cystic	
Castrate												
Control	6	31 \pm 4	7.6 \pm 1.7	2.25 \pm 0.7	-70	0	6	0	0	0	0	
Testosterone	5	33 \pm 6	7.1 \pm 1.1	15.6 \pm 1.8	120	5	0	0	0	0	0	
Dihydrotestosterone	5	27 \pm 4	6.3 \pm 1.5	17.7 \pm 4.1	181	4	0	0	0	1	0	
Androstenediol	5	27 \pm 2	6.2 \pm 1.9	16.8 \pm 5.0	171	4	0	0	0	1	0	
Estradiol	5	26 \pm 2	7.7 \pm 3.1	6.7 \pm 1.0	-13	0	0	0	5	0	0	
Estradiol plus testosterone	5	25 \pm 1	7.4 \pm 2.8	17.6 \pm 8.0	138	3	0	1	0	1	0	
Estradiol plus dihydrotestosterone	5	28 \pm 3	8.0 \pm 3.5	48.6 \pm 23	508	1	0	0	0	4	0	
Estradiol plus androstenediol	6	27 \pm 3	7.6 \pm 2.3	41.9 \pm 12.6	451	0	0	0	0	6	0	
Intact												
Control	6	29 \pm 6	8.0 \pm 3.8	11.3 \pm 4.2	41	5	0	0	0	1	0	
Testosterone	5	28 \pm 2	7.6 \pm 3.1	22.7 \pm 5.0	199	3	0	0	0	2	0	
Dihydrotestosterone	5	29 \pm 3	8.2 \pm 2.7	32.1 \pm 8.3	291	1	0	0	0	4	0	
Androstenediol	5	27 \pm 2	8.1 \pm 1.4	29.0 \pm 5.8	258	1	0	0	0	4	0	
Estradiol	5	28 \pm 3	7.6 \pm 1.7	9.0 \pm 3.6	18	0	0	0	5	0	0	
Estradiol plus testosterone	5	27 \pm 4	8.1 \pm 1.0	17.8 \pm 4.4	120	3	0	2	0	0	0	
Estradiol plus dihydrotestosterone	5	27 \pm 4	8.3 \pm 3.7	39.6 \pm 11.5	377	1	0	0	0	4	0	
Estradiol plus androstenediol	5	30 \pm 5	8.4 \pm 3.5	50.5 \pm 14.0	501	0	0	0	0	5	0	
Intact—untreated (BPH initially present)												
Spontaneous—glandular	4	32 \pm 5	13.9 \pm 2.7	22.0 \pm 4.6	58	0	0	0	0	4	0	
Spontaneous—cystic	2	37 \pm 5	33.4 \pm 9.9	31.2 \pm 5.0	-7	0	0	0	0	0	2	

Abbreviations used in this table: Androstenediol, 5 α -androstane-3 α ,17 β -diol; BPH, benign prostatic hyperplasia.

hyperplasia. Testosterone alone, or in combination with 17 β -estradiol, did not increase the incidence of prostatic hyperplasia, although the prostate weights were increased in comparison with those of intact controls.

The experimentally induced glandular hyperplasia was histologically indistinguishable from the spontaneous disease. However, cystic hyperplasia was not produced by any of the hormonal treatments. Moreover, animals that received 17 β -estradiol alone had prominent squamous cell metaplasia of the prostate, whereas the combination of androgens with estrogen completely prevented these metaplastic changes.

DISCUSSION

To evaluate the experimentally induced canine prostatic hyperplasia, it was essential to characterize the properties of the spontaneous disease. An increase in size or weight of the prostate is insufficient to establish the diagnosis of prostatic hyperplasia (21). For ex-

ample, in untreated beagles both normal and hyperplastic glands are found in the 12–18 g range. It was therefore important to define the histology, age of onset, and natural progression of the disease. To our knowledge, this has not been established in a single breed of dogs of known ages.

The present study of spontaneous prostatic hyperplasia in the beagle, has confirmed that this is a disease that increases in frequency with age (22, 23), although the onset may occur as early as 2–3 yr of age. Two distinct types of spontaneous prostatic hyperplasia have been recognized (23, 24). Glandular hyperplasia is characterized by elaborate projections of a hypertrophic and hyperplastic epithelium into the lumina of enlarged alveoli. The histological appearance of glandular hyperplasia may vary considerably, from an early stage of the disease in which the appearance merges with that of the normal gland, to a picture that is markedly abnormal (23). We emphasize that the experimentally induced glandular hyperplasia could not

be distinguished from spontaneous glandular hyperplasia. Cystic hyperplasia is characterized by a cuboidal but hyperplastic epithelium, with the formation of large cysts, and an increase in the ratio of stromal to epithelial cells. Occasionally prostates are seen in various stages that appear to represent transition from glandular to cystic hyperplasia. Glandular hyperplasia may represent an earlier stage of development of the disease preceding the appearance of cystic hyperplasia. Cystic hyperplasia was not produced by any of the hormonal manipulations we have tested, nor, to our knowledge, has it been reported after any other experimental attempt to induce canine prostatic hyperplasia.

Walsh and Wilson (13) reported that 5 α -androstane-3 α ,17 β -diol induced canine prostatic hyperplasia in the castrate dog (with the epididymis left intact) and that 17 β -estradiol exerted a synergistic effect with this androstane diol on prostatic growth. They also showed that dihydrotestosterone in combination with 17 β -estradiol did not stimulate canine prostate growth. Earlier experiments from Wilson's laboratory (6, 7) had shown that neither testosterone nor dihydrotestosterone alone could induce canine prostatic hyperplasia.

In our studies, treatment with 5 α -androstane-3 α ,17 β -diol in combination with 17 β -estradiol induced prostatic hyperplasia in both intact and castrated dogs. However, in contrast to earlier reports (13), dihydrotestosterone in combination with 17 β -estradiol was equally effective in our experiments in inducing the disease. In addition, if the testes were left intact, either 5 α -androstane-3 α ,17 β -diol or dihydrotestosterone (without simultaneous 17 β -estradiol treatment) could induce prostatic hyperplasia. One possible explanation for this finding is that the prostates did not involute before initiation of treatment, but the possibility of the action of unknown testicular factors also requires consideration.

The ability of dihydrotestosterone alone or in combination with 17 β -estradiol to stimulate prostatic growth, in our study, is in sharp contrast to the results of Walsh and Wilson (13). The discrepancy in the findings may be attributed to differences in experimental design such as: (a) the age and breed of dog; (b) the technique of preparation of suspensions of the relatively insoluble steroids; and (c) the type of castration. In our experiments epididymides and testes were removed bilaterally. Walsh and Wilson (13) left the epididymis *in situ*, whereas Jacobi et al. (14) are not specific on this point; (d) the time interval between castration and the initiation of hormonal treatment, i.e., variable (13), no delay or 2 wk (14), or 1 mo (present study). This interval and the degree of associated involution of the glands may be important factors in governing the subsequent susceptibility to hormonal induction of the hyperplastic process.

The demonstration in our laboratory that dihydrotestosterone is capable of inducing prostatic growth

is consistent with previous reports that 5 α -androstane-3 α ,17 β -diol is rapidly metabolized *in vitro* to dihydrotestosterone (8) and that dihydrotestosterone is the major intranuclear androgen metabolite after administration of a variety of other androgens (25). In addition, although a high affinity, saturable prostatic binding protein for dihydrotestosterone has recently been demonstrated, a binding protein for 5 α -androstane-3 α ,17 β -diol has not been reported.

Administration of 17 β -estradiol maintained the size of the prostate of the intact dog and stimulated stromal growth of the prostate of the castrated dog. The 17 β -estradiol-induced stromal growth of the dog prostate has recently been quantitated morphometrically.² 17 β -Estradiol also produced squamous metaplasia of the epithelium in castrated and intact dogs, but this was not seen in any dog receiving a combination of androgens and estrogen. Therefore, the changes in prostate size cannot be caused by squamous metaplasia as androgen will prevent this estrogen-induced effect. We suggest that glandular hyperplasia and the increase in prostate size in those animals treated by androgen-estrogen combinations are the result of 17 β -estradiol-induced stromal changes,² which in turn by some unknown mechanism may stimulate epithelial hyperplasia.

Cystic hyperplasia was not induced by any of our treatments. It is unlikely that this failure is a function of the duration of treatment as continued administration by Walsh and Wilson (13) of 5 α -androstane-3 α ,17 β -diol and 17 β -estradiol for as long as 1 yr did not produce the cystic condition. Old age does not seem to be a requirement for the induction of glandular hyperplasia, but it is entirely possible that the cystic condition can only be produced in aging dogs.

It has been widely recognized that the development of spontaneous prostatic hyperplasia occurs in aging dogs with intact testes. Although our experiments do not throw light on the changes associated with aging, it may be suggested that some abnormality in testicular secretion, or in the subsequent metabolism of estrogens and 5 α -reduced androgens, may be responsible for the development of canine prostatic hyperplasia.

ACKNOWLEDGMENTS

It is a pleasure to acknowledge the able technical assistance of Carly Detweiler, Louise Hicks, Betty Higgenbottom, William Isaacs, Niels Kromann, and Bobby Trotter.

This study was supported by National Institutes of Health grant AM 19300. Dr. J. D. Strandberg was supported by RR 00130, and National Cancer Institute contract N01 CP 65768 from the National Institutes of Health.

REFERENCES

1. Huggins, C., and J. L. Sommer. 1953. Quantitative studies of prostatic secretion. III. Simultaneous measurement of

- size and secretion of the canine prostate and the interaction of androgenic and estrogenic substances thereon. *J. Exp. Med.* **97**: 663–680.
2. Huggins, C., and P. J. Clark. 1940. Quantitative studies of the prostatic secretion. II. The effect of castration and of estrogen injection on the normal and on the hyperplastic prostate glands of dogs. *J. Exp. Med.* **72**: 747–761.
 3. Neri, R. O., C. Casmer, W. V. Zeman, F. Fielder, and I. I. A. Tabachnick. 1968. Effects of an anti-androgen (6-chloro- Δ -1,2 α -methylene-17 α -hydroxyprogesterone acetate, cyproterone acetate) on canine prostatic hyperplasia. *Endocrinology*. **82**: 311–317.
 4. Neri, R. O., and M. Monahan. 1972. Effects of a novel nonsteroidal antiandrogen on canine prostatic hyperplasia. *Invest. Urol.* **10**: 123–130.
 5. Ofner, P. 1968. Effects and metabolism of hormones in normal and neoplastic prostate tissue. *Vitam. Horm.* **26**: 237–291.
 6. Gloyna, R. E., P. K. Siiteri, and J. D. Wilson. 1970. Dihydrotestosterone in prostatic hypertrophy. II. The formation and content of dihydrotestosterone in the hypertrophic canine prostate and the effect of dihydrotestosterone on prostate growth in the dog. *J. Clin. Invest.* **49**: 1746–1753.
 7. Wilson, J. D., R. E. Gloyna, and P. K. Siiteri. 1975. Androgen metabolism in the hypertrophic prostate. *J. Steroid Biochem.* **6**: 443–445.
 8. Jacobi, G. H., and J. D. Wilson. 1976. The formation of 5 α -androstane-3 α ,17 β -diol by dog prostate. *Endocrinology*. **99**: 602–610.
 9. Scott, W. W., and D. S. Coffey. 1975. Nonsurgical treatment of human benign prostatic hyperplasia. *Vitam. and Horm.* **33**: 439–465.
 10. Moore, R. A. 1943. Benign hypertrophy of the prostate: a morphological study. *J. Urol.* **50**: 680–710.
 11. Pradhan, B. H., and K. Chandra. 1975. Morphogenesis of nodular hyperplasia-prostate. *J. Urol.* **113**: 210–213.
 12. Huggins, C. 1947. The etiology of benign prostatic hypertrophy. *Bull. N. Y. Acad. Med.* **23**: 696–704.
 13. Walsh, P. C., and J. D. Wilson. 1976. The induction of prostatic hypertrophy in the dog with androstanediol. *J. Clin. Invest.* **57**: 1093–1097.
 14. Jacobi, G. H., R. J. Moore, and J. D. Wilson. 1978. Studies on the mechanism of 3 α -androstanediol-induced growth of the dog prostate. *Endocrinology*. **102**: 1748–1755.
 15. Ruzicka, L., and A. Wettstein. 1935. Sexualhormone VII. Über die künstliche herstellung des testikelhormons testosterone (androsten-3-on-17-ol). *Helv. Chim. Acta.* **18**: 1264–1275.
 16. Ruzicka, L., and H. Kägi. 1937. Sexualhormone XXVII. Über 17-*cis*- und 17-*trans*-isomere diole und oxyketone des androstans und androstens. *Helv. Chim. Acta.* **20**: 1557–1564.
 17. Ruzicka, L., M. W. Goldberg, and J. Meyer. 1935. Sexualhormone IV. Über derivate des synthetischen androsterons und eines seiner stereoisomeren. *Helv. Chim. Acta.* **18**: 210–218.
 18. Whitman, B., O. Wintersteiner, and E. Schwenk. 1937. β -Estradiol. *J. Biol. Chem.* **118**: 789–795.
 19. Scott, W. W., W. J. Hopkins, W. M. Lucas, and C. Tesar. 1957. A search for inhibitors of prostate growth stimulators. *J. Urol.* **77**: 652–659.
 20. Evans, J. S., R. F. Varney, and F. C. Koch. 1941. The mouse uterine weight method for the assay of estrogens. *Endocrinology*. **28**: 747–752.
 21. Berg, O. A. 1958. Parenchymatous hypertrophy of the canine prostate gland. *Acta. Endocrinol.* **27**: 140–154.
 22. Zuckerman, S., and T. McKeown. 1938. The canine prostate in relation to normal and abnormal testicular changes. *J. Pathol. Bacteriol.* **46**: 7–19.
 23. O'Shea, J. D. 1962. Studies on the canine prostate gland. I. Factors influencing its size and weight. *J. Comp. Pathol.* **72**: 321–331.
 24. Zuckerman, S., and J. R. Groome. 1937. The aetiology of benign enlargement of the prostate in the dog. *J. Pathol. Bacteriol.* **44**: 113–124.
 25. Bruchovsky, N. 1971. Comparison of the metabolites formed in rat prostate following the *in vivo* administration of seven natural androgens. *Endocrinology*. **89**: 1212–1222.