

Bleomycin-Induced Diffuse Interstitial Pulmonary Fibrosis in Baboons

B. McCULLOUGH, *Southwest Foundation for Research and Education, San Antonio, Texas 78284*

J. F. COLLINS, W. G. JOHANSON, JR., and F. L. GROVER, *Departments of Medicine, Biochemistry, and Surgery, The University of Texas Health Science Center at San Antonio and Veterans Administration Hospital, San Antonio, Texas 78284*

ABSTRACT Pulmonary fibrosis was induced in eight baboons with bleomycin; five untreated animals were controls. After 45–65 U/kg of bleomycin, lung volumes and diffusing capacity were reduced, and static lung pressure-volume curves were shifted to the right. Right middle lobes were resected at this time in five bleomycin-treated and two control animals. Compared to controls, right middle lobes from bleomycin-treated animals had increased weight and contained increased amounts of total protein, collagen, elastin, and DNA; synthesis of collagen and noncollagen protein were also elevated. Occasional alveolar septae were edematous and infiltrated by mononuclear inflammatory cells; a slight increase in collagen was demonstrable histologically. Four of six treated animals died with extensive diffuse interstitial fibrosis after 95 U/kg of bleomycin. Biochemical analyses revealed significantly elevated lobar contents of dry weight, protein, elastin, and collagen. Two animals survived 95 U/kg of bleomycin and were terminated 6 mo after treatment. In these animals, physiologic studies were indicative of restrictive lung disease, but lung histology was nearly normal. Lung weight, total protein, and DNA had returned to control values, but collagen and elastin were increased in amount and concentration. Bleomycin induces an intense inflammatory response in the lung. During this inflammation, connective tissue proliferation occurs in concert with proliferation of other tissue components. Cessation of bleomycin treatment is followed by resolution of inflammation manifested by decreases in tissue mass, cellular content, and nonconnective tissue protein. Collagen and elastin deposited

during inflammation are less successfully removed during resolution, leading to a stage characterized by increased concentrations of these proteins. A similar sequence of tissue alterations may occur in idiopathic diffuse interstitial fibrosis of man in response to various lung injuries.

INTRODUCTION

Diffuse interstitial fibrosis of the lungs occurs in humans in association with a number of systemic diseases, follows certain environmental exposures, and is a serious side effect of some drugs. In 30–40% of cases, no associated factor can be identified (1). The natural history of pulmonary fibrosis is usually one of progressive deterioration of lung function with death due to cor pulmonale and respiratory insufficiency (2, 3). The pathogenetic mechanisms which lead to pulmonary fibrosis are unknown. The consistent presence of mononuclear inflammatory cells within fibrosing lesions suggests that inflammatory or immunological mediators may be involved (2, 4).

An apparent increase in collagen is a prominent feature of the histopathology of pulmonary fibrosis. However, Fulmer et al. (5, 6) reported a poor correlation between concentration of lung collagen and lung histology or physiology in patients with diffuse interstitial fibrosis. In addition, collagen synthesis was similar in normal and fibrotic lung tissues (5, 6). This discrepancy between amount of biochemically measurable and histologically identifiable collagen may be due to nonuniform distribution or proportional increases in other tissue components. Quantification of elastin content in fibrotic lung tissue of patients has not been reported.

The objectives of the present investigation were to determine sequential changes in lung function, histology, and tissue composition during the development of diffuse interstitial fibrosis. For these studies we

This work was presented in part at the Annual Meeting of the Southern Section of the American Federation for Clinical Research, New Orleans, La., on 27 January 1977 and was reported in abstract form in 1977. *Clin Res.* 25: 38A.

Received for publication 28 June 1977 and in revised form 6 September 1977.

have produced a model of this lesion in baboons with the antineoplastic antibiotic bleomycin.

METHODS

Animals. 13 baboons (*Papio cynocephalus*), eight males and five females, 4–19 mo old and weighing 1.2–7.4 kg were used for this study. All were born in captivity, had no history of respiratory disease, and were free of parasites. They were caged individually, fed a standard pelleted ration for baboons (Ralston Purina Co., St. Louis, Mo.) and given water *ad libitum*.

Bleomycin. Five male and three female baboons were injected intramuscularly with 1.5 U/kg body weight of bleomycin sulphate (Blenoxane, Bristol Laboratories, Syracuse, N. Y., Lot Nos. A5050, A5051, and M5541) twice weekly. Treatment was interrupted when the accumulated dose reached 45 U/kg. After 3 mo, bleomycin treatments were reinstituted and continued until an additional 50 U/kg had been given. Three male and two female baboons served as untreated controls.

Total lung capacity by planimetry (TLC_p).¹ Using techniques described in detail elsewhere,² total lung capacity was monitored monthly. Briefly, the outlines of the lungs on posteroanterior and lateral chest radiographs, taken under standard conditions of lung inflation and exposure, were traced with a planimeter (compensating polar planimeter, Keuffel & Esser Co., Morristown, N. J.) to measure the respective area. The three areas were summed, and monthly values were expressed as percent of initial radiographic lung area.

Pulmonary function testing. The animals were anesthetized with ketamine, intubated with a cuffed endotracheal tube, and seated in a restraining chair. Functional residual capacity was measured during spontaneous breathing by nitrogen washout (7); if duplicate determinations varied by more than 15%, further measurements were performed until two successive values agreed within these limits. Additional subdivisions of lung volume were determined with the animals positioned in a flow-sensitive, pressure-compensated plethysmograph (8). Total lung capacity (TLC) and residual volume were defined as the volumes existing at airway pressures of 40 cm H₂O and -40 cm H₂O, respectively; these forced maneuvers were performed with a giant syringe (Hans Rudolph, Inc., Kansas City, Mo.). Muscular paralysis was induced by the intravenous injection of pancuronium, 0.03 mg/kg, for the performance of static pressure-volume (PV) curves. An esophageal balloon-catheter (length 3 cm, volume 0.4 ml) was positioned in the distal esophagus just cephalad to the region of maximal cardiac artifact. Transpulmonary pressure was recorded as the difference between esophageal and airway pressures by use of a differential transducer (MP 45±50, Validyne Engineering Corp., Northridge, Calif.). PV curves were obtained by incremental deflation from total lung capacity, using the plethysmograph signal for volume change. The diffusing capacity of the lung for carbon monoxide was measured by the rebreathing technique (9), using tidal volumes equal to 75% of the animal's in-

spiratory capacity. Gas concentrations were monitored with a mass spectrometer (model 1100, Perkin-Elmer Corp., Pomona, Calif.).

Right middle lobectomy. The right middle lobe of five bleomycin-treated and two control baboons was removed surgically. For the bleomycin-treated animals, three underwent lobectomy after 45 U/kg and two after 65 U/kg. A control animal was sampled with each bleomycin subgroup. Three transverse slices were taken from each lobe, representing hilar, central, and peripheral regions. These were fixed in modified Millonig's phosphate-buffered formalin (10). The remaining tissue was used for connective tissue biochemistry.

Terminal studies. All animals were subjected to a complete necropsy. Surviving animals, including controls, were terminated 6 mo after the last bleomycin treatment. Exsanguination via a femoral artery was accomplished with the animals deeply anesthetized with ketamine and paralyzed with pancuronium. Ventilation was maintained manually. The thoracic viscera were removed from the chest and the lungs dissected free. The right mainstem bronchus was tied at the trachea. The right lung was separated and fixed by intrabronchial instillation of modified Karnovsky's glutaraldehyde-formaldehyde fixative (11) with constant 30-cm fixative pressure for at least 6 h. The left lung was used for in vitro determination of the PV characteristics with air and saline. These studies will be the subject of a separate report.³ Upon completion of the in vitro PV curves, the left lung was used for connective tissue biochemistry. Representative pieces of all organ systems were fixed in modified Millonig's phosphate-buffered formalin. The left lung from one and the right lung from five bleomycin-treated animals which died were processed for light microscopy. The contralateral lungs from these animals were frozen for later connective tissue studies.

Biochemistry. Portions of resected right middle lobes and left upper and lower lobes taken at necropsy were analyzed. 2 g of each lobe were minced with scissors, divided into six samples, and incubated at 37°C in Dulbecco's modified Eagle's medium containing [¹⁴C]proline (12). At 1, 2.5, and 4 h, duplicate samples were harvested, washed with phosphate-buffered saline, and homogenized in 0.5 M acetic acid. Aliquots of each were used to determine total and newly synthesized hydroxyproline (13), noncollagen protein synthesis (12), DNA (14), protein (15), and specific activity of proline (12, 16). Since hydroxyproline comprises 12.5% of the weight of a baboon collagen chain (17), collagen content of each lung was computed by multiplying the mean hydroxyproline value of six aliquots by 8. Insoluble elastin was isolated by digesting 10–30 mg of lyophilized homogenate in 3 ml 0.1 N NaOH at 98°C for 50 min (18). The digest was centrifuged and insoluble material washed twice with water and lyophilized. Elastin content was measured with the micro-method of Naum and Morgan (19) using pancreatic elastase (Sigma Chemical Co., St. Louis, Mo.).

Light microscopy. Fixed tissues were dehydrated in graded ethanols, embedded in paraffin, sectioned at 5 µm, and stained with hematoxylin and eosin. 10–15 tissue blocks were processed for each lung obtained at necropsy. Serial sections of lung specimens were stained with the following: Masson's trichrome, Verhoeff-van Gieson elastica, Gomori's reticulin, and toluidine blue (pH 3).

Data analysis. Data obtained for bleomycin-treated animals were compared to that of controls by use of the Student *t* test for unpaired observations or the Mann-Whitney U test (20).

¹ Abbreviations used in this paper: PV, pressure-volume; TLC_p, total lung capacity determined by planimetry of chest radiographs; TLC, total lung capacity determined physiologically.

² McCullough, B., and W. G. Johanson, Jr. Planimetric determination of total lung capacity. Manuscript in preparation.

³ McCullough, B., J. F. Collins, and W. G. Johanson, Jr. Elastic behavior of lung tissue in experimental fibrosis. Manuscript in preparation.

RESULTS

Planimetry of thoracic radiographs revealed a progressive increase in total lung capacity in control baboons, reflecting their increasing body size (Fig. 1). TLC_p decreased in bleomycin-treated baboons after 15 wk of drug administration, an accumulated dose of 45 U/kg. This trend continued for 2 mo in the absence of bleomycin administration. When TLC_p returned towards control values at the 6th mo of study, bleomycin treatment was reinstituted, and TLC_p for the bleomycin group did not increase further. Body weight gain was linear for the control animals, and their weight doubled during 12 mo of study. In the same period, body weight of the bleomycin group increased by 46%.

Baboons receiving bleomycin developed circular ulcers in the skin over points of pressure, such as heels, wrists, fingers, and tail, after several weeks. Medial portions of the ischial callosities (cornified pads over the buttocks) were similarly affected. In addition, during the later stages of the second treatment series, generalized diffuse thickening of the skin was obvious, and contractures due to skin thickening, particularly affecting the hip and knee, were marked. Three animals developed ischemic necrosis of the digital extremities with eventual sloughing of portions of the affected digits. Histologic evidence of vascular lesions was not demonstrated. The cutaneous ulcerations regressed upon interruption of bleomycin treatment, but the skin thickening persisted.

After the administration of 45 U/kg, the bleomycin group demonstrated significantly reduced TLC, and vital capacity (Table I), and rightward shift of lung PV curves (Fig. 2A). To quantify the shift in PV curves, we calculated lung volume as percent of predicted TLC for each group at 15 cm H_2O transpulmonary pressure. The mean value \pm SEM was $82.6 \pm 3.9\%$ for the control group and $66.2 \pm 2.5\%$ for the bleomycin group ($P \leq 0.005$). At this time, diffusing capacity for carbon monoxide and the diffusing capacity for carbon monoxide per unit of alveolar volume were not significantly different from the control group. Similar reductions in lung volumes were found after 65 U/kg of bleomycin (Table I) and both the diffusing capacity for carbon monoxide and the diffusing capacity for carbon monoxide per unit of alveolar volume were significantly reduced in the bleomycin group (Table I). Lung PV curves of the bleomycin-treated animals were again shifted down and to the right (Fig. 2B). The percent of predicted TLC at 15 cm H_2O was $86.2 \pm 5.2\%$ for the control group and $66.7 \pm 5.5\%$ for the bleomycin group ($P \leq 0.025$). Two animals which survived 95 U/kg of bleomycin were studied at 6 wk and at 6 mo after discontinuance of the drug. Changes in lung volumes and diffusing capacity similar to those found during

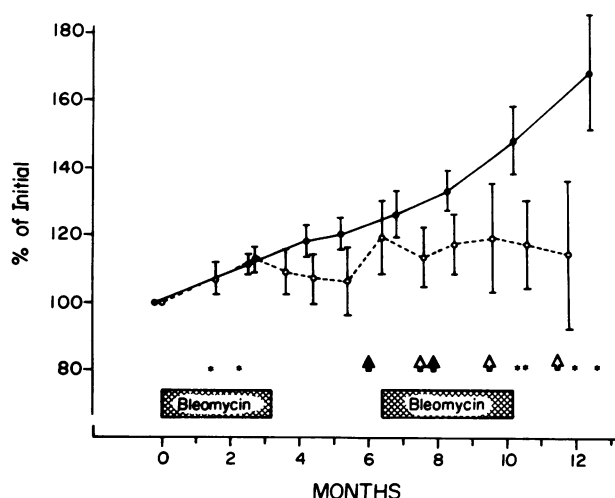


FIGURE 1 Total lung capacity determined by planimetry. Mean values \pm SEM, expressed as percent of initial value (ordinate), are shown for control (●—●) and bleomycin-treated (○---○) baboons. Periods of bleomycin treatment are indicated (crosshatched bars). Pulmonary function tests (open arrows) and right middle lobectomies (closed arrows) were performed. Animal deaths are marked (*).

the treatment period were observed at these times (Table I). Lung PV curves were shifted rightward as before (Fig. 3). Thoracotomy and resection of the right middle lobe had no discernible effect on lung function in either control or bleomycin-treated animals.

The lungs were grossly altered only in animals subjected to lobectomy after 65 U/kg of bleomycin. The pleural surfaces were pitted, and pin-point white foci were observable beneath the glistening pleura. Histologic examination of right middle lobes removed after 45 U/kg of bleomycin showed occasional alveolar septae to be edematous and infiltrated by mononuclear inflammatory cells. A slight increase in collagen was demonstrable with special stains in these thickened septae. After 65 U/kg of bleomycin, randomly distributed areas of alveolar septal inflammation were more numerous and intensely infiltrated (Fig. 4). Collagen was densely accumulated within these lesions, and often alveolar surfaces were in apposition. Increases in elastin were not apparent in Verhoeff-van Gieson elastica-stained sections. Intraalveolar exudation was minimal. The composition of the alveolar epithelium was not visibly abnormal. Pleural thickening varied from slight to moderate.

Five bleomycin-treated baboons died, and a sixth was killed *extremis*. The first died after 21 U/kg of bleomycin. All of the lung lobes had grossly visible foci of pleural fibrosis. Histological examination confirmed that these foci were composed of dense accumulations of collagen within the pleura and subpleural alveolar septae. Inflammation was minimal. The death

TABLE I
Physiologic Parameters in Control and Bleomycin-Treated Baboons

	Animals	Body weight	Total lung capacity	Vital capacity	Diffusing capacity	Diffusing capacity per alveolar volume
		kg	% predicted*	% predicted†	ml/min per mm Hg	ml/min per mm Hg/liter
Study 1						
Control	5	4.1±0.4§	88±4	90±4	1.71±0.24	10.66±0.40
Bleomycin (45 U/kg)	6	4.1±0.9	71±2	66±3	1.82±0.46	11.11±0.76
Study 2						
Control	5	4.3±0.4§	100±8	103±9	2.00±0.28	11.33±0.30
Bleomycin (65 U/kg)	6	4.1±0.8	73±6	57±7	1.29±0.33	8.06±0.97
Study 3						
Control	5	4.9±0.4	114±1	126±1	3.83±0.20	12.45±0.60
Bleomycin (95 U/kg)	2	6.0**	83	73	2.76	9.95
Study 4						
Control	2	5.5**	129	135	—	—
Bleomycin (6 mo after treatment)	2	6.1	80	84	—	—

* Predicted total lung capacity = $56.5 \times \text{body weight (kg)}^{1.1846}$.

† Predicted vital capacity = $50.9 \times \text{body weight (kg)}^{1.1364}$.

§ Mean±SEM.

^{||} Significantly less than controls by *t* test, $P \leq 0.1$.

^{||} Significantly less than controls by *t* test, $P \leq .02$.

** Mean.

of this animal was precipitated by severe chilling. The second baboon was asymptomatic. It had received 30 U/kg of bleomycin. Grossly, the lungs failed to collapse completely. They were moist, heavy, and firm with red mottling. In all lung regions, extensive

accumulation of interstitial and intraalveolar edematous collagenous connective tissue and infiltrating mononuclear inflammatory cells effaced the alveolar architecture (Fig. 5). Fibroblasts were frequently present within intraalveolar fibrinous exudate. In some

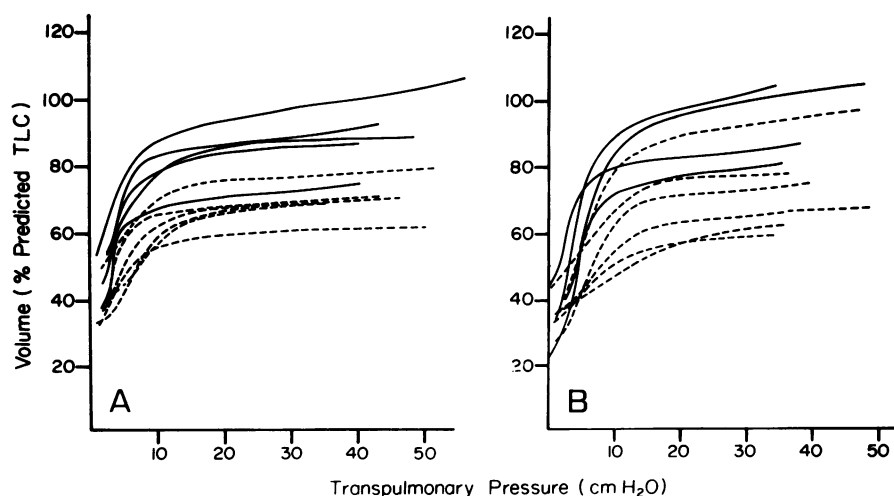


FIGURE 2 Static pressure-volume curves of lungs. Pressure-volume curves are shown for control (solid lines) and bleomycin-treated (dashed lines) baboons after accumulated doses of bleomycin of 45 U/kg (A) and 65 U/kg (B). Volume as percent of predicted TLC is plotted against transpulmonary pressure. Predicted TLC equals $56.5 \times \text{body weight (kg)}^{1.1846}$. Data were not available for one control animal after 65 U/kg.

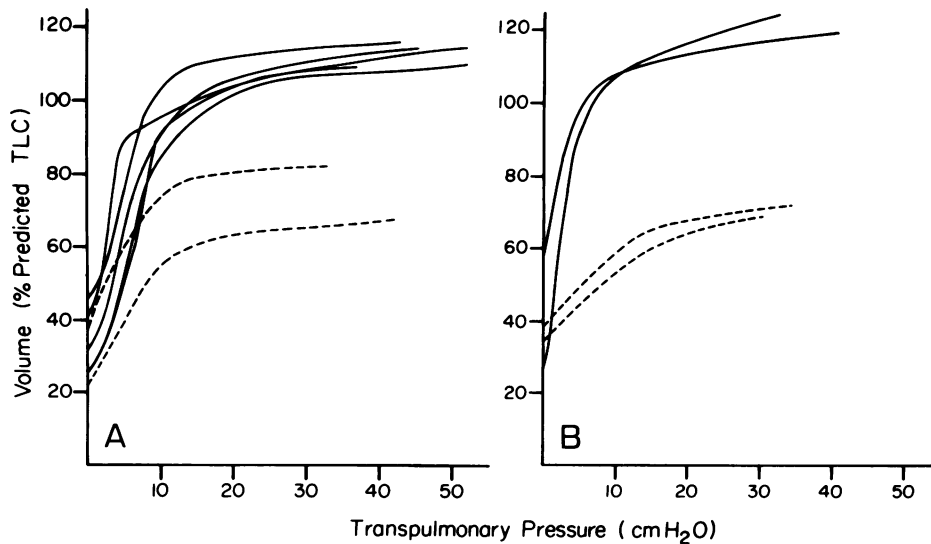


FIGURE 3 Static pressure-volume curves of lungs. Pressure-volume curves are shown for control (solid lines) and bleomycin-treated (dashed lines) baboons after total dose of 95 U/kg of bleomycin (A) and 6 mo after last treatment (B). Volume as percent of predicted TLC is plotted against transpulmonary pressure. Data were available for two controls only for the terminal studies.

instances, distinction between inter- and intraalveolar areas was not possible. Numerous alveoli were lined by cuboidal epithelial cells. Many large mononuclear cells, probably sloughed alveolar epithelial cells as well as macrophages, were present in alveolar spaces. Moderate numbers of lymphocytes were also observed.

Three baboons died 1, 2, and 8 wk after termination of bleomycin treatments (accumulated dose, 95 U/kg). Another was killed *in extremis* after 10 wk. Right middle lobectomy had been performed on the first three. The pleurae of their right lungs were markedly thickened posteriorly, and multiple adhesions were present. The consistency of the lung was more dense and firm than normal in two animals. In contrast to the lobectomy specimens, interstitial fibrosing inflammation was more intense and more generalized in its distribution (Fig. 6). The thickened alveolar septae contained prominent collagen bundles (Fig. 7), and fibroblasts were frequent. In general, alveolar epithelial cells were hyperplastic (Fig. 7), and focal squamous metaplasia of bronchoalveolar epithelium was observed in two animals. Some alveolar spaces contained fibrinous exudate, but hyaline membranes were present only occasionally.

The two bleomycin-treated baboons which survived had both undergone right middle lobectomy and had moderate pleural thickening over the right lung with dense adhesions. The pleura of the left lung was only slightly thickened. Except for the presence of scattered focal alveolar septal fibrosis in basilar regions, these lungs appeared normal histologically (Fig. 8) in marked

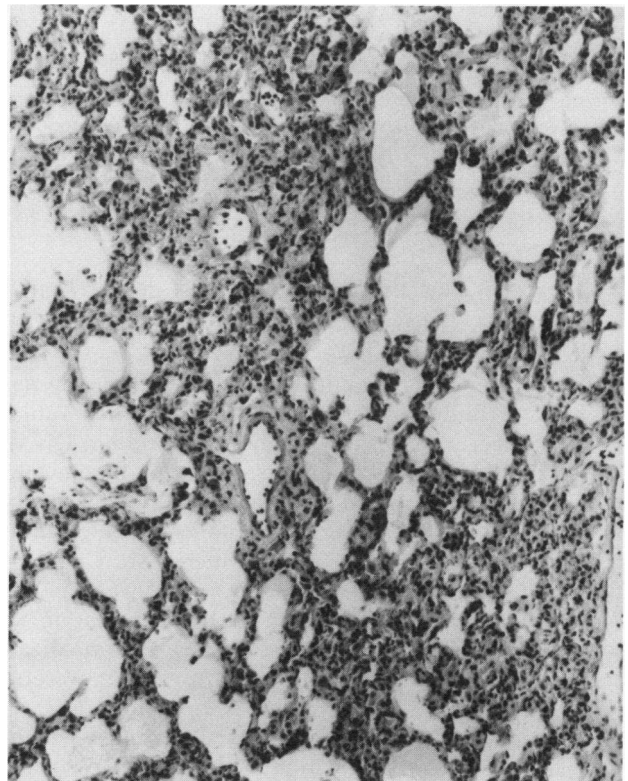


FIGURE 4 Section of right middle lobe of lung surgically resected from baboon after 65 U/kg of bleomycin. Alveolar septae are edematous and infiltrated by mononuclear inflammatory cells; a slight increase in collagen is present. Hematoxylin and eosin. Original magnification $\times 190$.

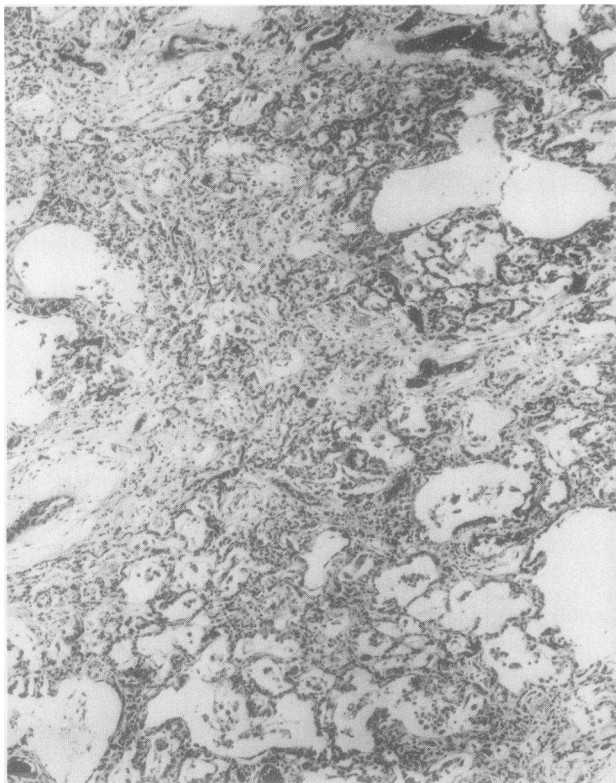


FIGURE 5 Section of right lower lobe of lung taken at necropsy from baboon which died after 30 U/kg of bleomycin. The alveolar architecture is effaced by inflammatory exudation and accumulation of connective tissue. Occasional "skip zones" composed of less severely affected alveoli are present. Hematoxylin and eosin. Original magnification $\times 70$.

contrast to the proliferative changes observed in the earlier lobectomy specimens from these animals, one of which is shown in Fig. 4.

The results of biochemical studies on surgically resected right middle lobe specimens are shown in Table II. Lobar wet weight, dry weight, total protein, DNA, collagen, and elastin were increased in the bleomycin group when expressed as content/kilogram body weight. Synthesis of collagen and noncollagen protein by minced lung in vitro was also increased. Concentration of collagen relative to lobe weight was similar in control and bleomycin groups, but concentration of elastin/milligram dry weight was increased. Normalization of lobar collagen and elastin by total protein or DNA content yielded similar relationships.

The left lungs of three bleomycin animals which died after 95 U/kg of bleomycin showed marked increases in dry weight, protein, DNA, elastin, and collagen (Table III). However, much of the increased lobe weight was due to nonconnective tissue substance, causing concentration of collagen relative to unit weight to be decreased, whereas the relative amount of

elastin with respect to dry weight was close to control levels. Agonal pulmonary edema may have contributed to this finding. Synthesis studies on necropsy specimens, performed after in vitro PV maneuvers, proved to be unreliable and will not be reported.

In the two bleomycin-treated animals sacrificed 6 mo after cessation of treatment, increases were found in lobe weight, protein, DNA, elastin, and collagen (Table III). Concentration of collagen relative to other tissue components was slightly increased, but elastin concentration was markedly elevated. Left upper and lower lobes were analyzed separately in both control and bleomycin-treated animals. Differences other than those explainable by the larger size of lower lobes were not demonstrated.

DISCUSSION

Pulmonary infiltration, dyspnea, and cough are well-known complications of bleomycin therapy (21, 22). The pathology of bleomycin-induced lung injury in

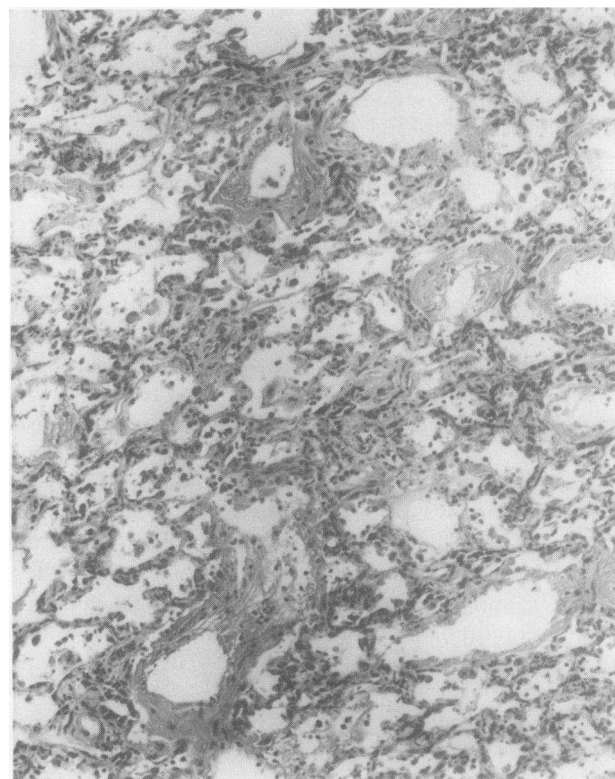


FIGURE 6 Section of right lower lobe of lung taken at necropsy from baboon which died after 95 U/kg of bleomycin. The alveolar septae are thickened by mononuclear inflammatory cells and connective tissue. Many lymphocytes and macrophages are present within alveolar spaces. Fibrinous exudate partially fills several alveoli. Hematoxylin and eosin. Original magnification $\times 190$.

man initially consists of interstitial edema and mononuclear inflammatory cell infiltration which progresses with larger doses to fibrinous exudation into alveolar spaces and proliferation of fibroblasts and type II alveolar epithelial cells (23–25). Our observations and those of others (26, 27) indicate that similar lesions may develop in experimental animals treated with bleomycin. The histopathology of bleomycin pulmonary toxicity mimics many features of “usual interstitial pneumonitis” (23) and appears to provide a suitable model for investigating the relationship of altered lung histology, biochemistry, and mechanical function associated with usual interstitial pneumonitis.

The mechanism of bleomycin-induced lung damage is not known with certainty and, although our studies were not directed at this question, they do provide a more complete view of the evolution of this pulmonary lesion. The early lesion is inflammatory and proliferative. Lobar weight is increased in association with widespread accumulations of inflammatory cells. Total protein, collagen, and elastin are increased in the lungs of treated baboons in proportion to in-

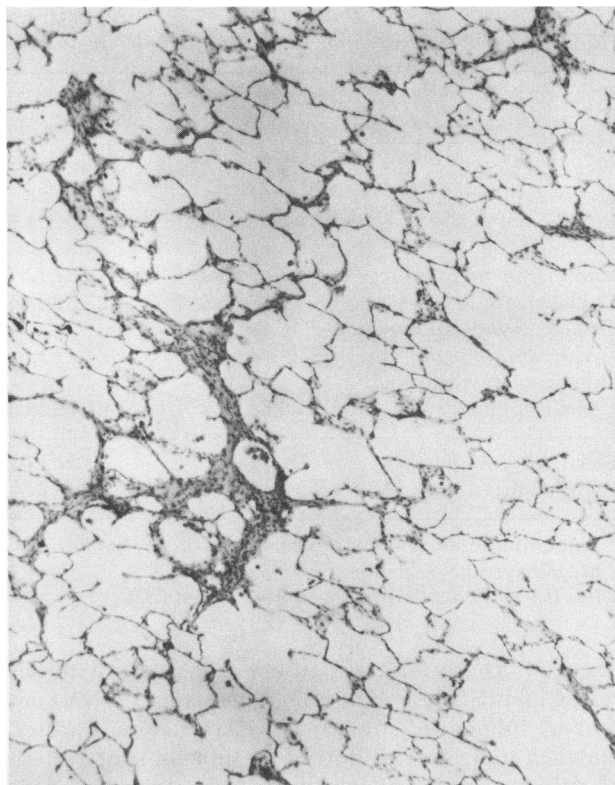


FIGURE 8 Section from right lower lobe of lung from previously biopsied baboon (Fig. 3). This tissue was taken at necropsy 6 mo after cessation of bleomycin treatments (accumulated dose, 95 U/kg). A focus of residual fibrosis is shown. The remaining alveolar septae have normal features. Hematoxylin and eosin. Original magnification $\times 70$.

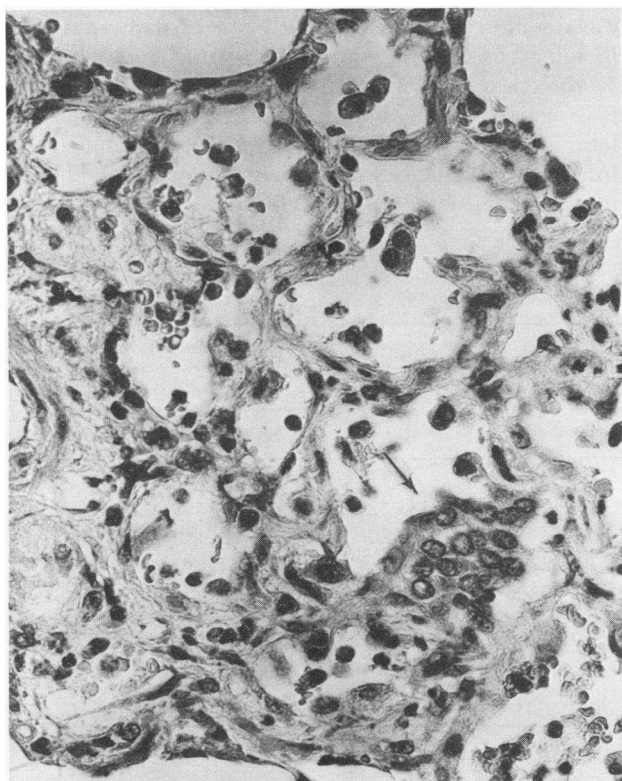


FIGURE 7 Higher magnification of section shown in Fig. 5. Connective tissue fibers are visible within the thickened septae. Inflammatory cells are located within interstitial and intraalveolar areas. Hyperplastic alveolar epithelial cells are present (arrow). Hematoxylin and eosin. Original magnification $\times 445$.

creased lobe weight, and synthesis rates of collagen and noncollagen proteins exceed those of untreated control animals. Aso et al. (28) reported that increased amounts of total phospholipids and disaturated lecithin are present in bronchoalveolar lavages of mice with bleomycin toxicity. These findings were attributed to numerous, hyperactive alveolar type II cells lining alveolar spaces. Thus, the bleomycin lesion involves a variety of cell types within the lung.

Biochemical analyses have been performed on fibrotic human lungs only recently. Fulmer and Crystal (5) and Fulmer et al. (6) studied lung tissue obtained by open-biopsy from eight patients with idiopathic diffuse interstitial fibrosis. In these specimens, DNA per dry weight was almost threefold higher than levels in control tissues, indicating that the cellularity of the fibrotic lungs was markedly increased. Collagen content per dry weight and rate of collagen synthesis per cell were decreased slightly in fibrotic lungs, and percent protein synthesis devoted to formation of collagen was less than 50% of control levels (5). The rate of noncollagen protein synthesis per cell was modestly

TABLE II
Biochemical Composition of Right Middle Lobe at Biopsy

	Controls (n = 2)	Bleomycin (n = 5)
Wet weight, g*	1.08±0.12‡	1.44±0.21
Dry weight, mg	101±20	142±28
Protein, mg	58.6±7.6	75.0±21.5
DNA, mg	3.3±0	4.3±1.3
Elastin, mg	2.2±0.4	4.3±1.5
Collagen, mg	18.6±2.2	27.5±4.8§
Collagen synthesis, nmol hydroxyproline/h)	2.4±0.6	4.2±1.8
Other protein synthesis (nmol proline/h)	43.8±0.3	61.7±25.3
Elastin/dry weight, %	2.2±0	3.2±1.0
Collagen/dry weight, %	19±1	20±2

* Right middle lobe content per kilogram body weight.

‡ Mean±average deviation.

§ $P \leq 0.1$ by two-tailed Mann-Witney U test (20).

elevated. These findings are not at variance with our results, which show that lung weights and DNA content are influenced strongly by inflammation. Further, our data indicate that during the inflammatory phase of pulmonary fibrosis, absolute amounts of collagen, elastin, and total protein in the lung do increase, but relative amounts are not different from controls.

Pulmonary function tests revealed similar abnormalities in bleomycin-treated animals at all stages and were

not helpful in predicting either histologic or biochemical findings. Bleomycin toxicity was associated with reduced lung volumes, reduced diffusing capacity, and a rightward shift of lung PV curves, as reported by others in man (21, 29, 30) and experimental animals (31). These findings fit established criteria for diagnosing pulmonary fibrosis (2) although, as our data show, such abnormalities in physiology may be associated with highly variable histology including nearly normal lung structure, intense inflammation, or marked fibrosis. Planimetry of chest radiographs provided a convenient means of comparing lung volume changes in control and bleomycin-treated animals. Total lung capacity and the area of the lungs in two projections are closely correlated in humans (32). Based on our data, it appears that planimetry of serial standardized posteroanterior and lateral chest radiographs should be evaluated in patients as a means of detecting the early pulmonary toxicity of bleomycin and other drugs known to affect the lungs.

The pulmonary toxicity of bleomycin progressed as long as the drug was administered. Histologic and biochemical findings in animals which died after 95 U/kg were similar to, but more extensive than, those documented by biopsy at early stages. However, the histology of the lungs in the two animals which were sacrificed 6 mo after discontinuance of bleomycin was nearly normal. Both had undergone right middle lobe resection earlier, and the specimens showed the inflammatory changes described. Compared to control middle lobes, mean dry weight of the middle lobes of

TABLE III
Biochemical Composition of Left Lung at Necropsy

	Left upper lobe			Left lower lobe		
	Controls	Bleomycin*		Controls	Bleomycin*	
		Spontaneous‡	Terminated§		Spontaneous‡	Terminated§
Number	5	3	2	5	3	2
Dry weight, mg	209±29¶	551±351¶**	261±21‡‡	326±52¶	1135±435¶**	416±62‡‡
Protein, mg	97±16	306±179**	124±8	165±29	689±271**	190±20
DNA, mg	6.0±1.1	9.3±5.3	7.1±0.2	9.4±0.7	19.1±7.3**	11.4±0.6§§
Elastin, mg	5.9±1.2	15.0±4.0**	15.9±0.4§§	9.0±1.7	24.1±4.0**	21.5±2.4§§
Collagen, mg	46±10	78±21	76±6§§	73±17	131±38§§	101±11§§
Elastin/dry weight, %	2.8±0.5	3.1±1.0	6.1±0.4§§	2.8±0.1	2.3±0.7	5.2±0.1§§
Collagen/dry weight, %	22±5	16±6	29±0	22±4	12±2**	25±1

* Total dose = 95 U/kg body weight.

‡ Died 2, 8, and 10 wk after last bleomycin treatment.

§ Killed 6 mo after last bleomycin treatment.

^{||} Lobar content per kilogram body weight.

¶ Mean±standard deviation.

‡‡ $P \leq 0.05$ by two-tailed Mann-Whitney U test (20).

** Mean±average deviation.

§§ $P \leq 0.1$ by two-tailed Mann-Whitney U test (20).

these two treated animals was increased by 22% and collagen content by 49%. Although cellular inflammation had regressed at the time of necropsy, elevations in lung connective tissue proteins persisted. In fact, elastin and collagen contents were similar to those of treated animals which died with extensive inflammatory lesions, despite the finding that lung weight was close to control levels. Thus, relative concentrations of lung elastin and collagen were increased only in those animals in which the inflammatory component of the lesion had resolved. The tissue changes which occur during the development of bleomycin-induced pulmonary fibrosis and resolution of the morphologic lesions are presented graphically in Fig. 9.

It is not known whether a similar sequence occurs following lung injuries other than that caused by bleomycin. The persistence of increased amounts of elastin in our material may be a unique feature of bleomycin toxicity, but quantitative analyses of elastin have not been reported for other fibrotic conditions.

Selective preservation of collagen and elastin in pulmonary fibrosis could be due to varying combinations of increased synthesis or decreased degradation. The

rate of collagen synthesis in the lungs increases soon after irradiation (33). We have found that collagen synthesis rates are depressed in late stages of pulmonary fibrosis induced by irradiation when concentration of collagen is increased and that, in general, collagen synthesis rates parallel changes in lobar DNA content.⁴ It is likely that selective retention of collagen and elastin during resolution of pulmonary fibrosis is due to a lesser capacity for hydrolysis of these proteins in the lung. The interplay between protein synthetic and degradative mechanisms in the lung appear to be of critical importance in the development and persistence of chronic parenchymal pulmonary diseases, such as diffuse interstitial fibrosis.

ACKNOWLEDGMENTS

We thank Marjorie Jones, Howard Waugh, Patty Reyes, Judy Odom, Wesley Cox, Marie Silva, and Carolyn Chappell for excellent assistance and Ronald C. Wackwitz for statistical analysis of the data.

This work was performed under contract N01-HR-5-3012 from the National Heart, Lung, and Blood Institute of the National Institutes of Health and with support from the Medical Research Service of the Veterans Administration.

REFERENCES

1. Liebow, A. A. 1975. Definition and classification of interstitial pneumonias in human pathology. *Prog. Respir. Res.* 8: 1-33.
2. Crystal, R. G., J. D. Fulmer, W. C. Roberts, M. L. Moss, B. R. Line, and H. Y. Reynolds. 1976. Idiopathic pulmonary fibrosis. Clinical, histologic, radiographic, physiologic, scintigraphic, cytologic, and biochemical aspects. *Ann. Intern. Med.* 85: 769-788.
3. Livingstone, J. L., J. G. Lewis, L. Reid, and K. E. Jefferson. 1964. Diffuse interstitial pulmonary fibrosis. *Q. J. Med.* 63: 71-103.
4. Fraire, A. E., S. D. Greenberg, R. M. O'Neal, J. G. Weg, and D. E. Jenkins. 1973. Diffuse interstitial fibrosis of the lung. *Am. J. Clin. Pathol.* 59: 636-647.
5. Fulmer, J. D., and R. G. Crystal. 1976. The biochemical basis of pulmonary function, *In* The Biochemical Basis of Pulmonary Function. R. G. Crystal, editor. Marcel Dekker, Inc., New York. 419-465.
6. Fulmer, J. D., R. S. Bienkowski, M. J. Cowan, K. H. Bradley, W. C. Roberts, and R. G. Crystal. 1976. Comparison of collagen concentration, distribution and synthesis in fibrotic and normal lungs. *Clin. Res.* 24: 384A. (Abstr.)
7. Darling, R. C., A. Cournand, J. S. Mansfield, and D. W. Richards, Jr. 1940. Studies on the intrapulmonary mixture of gases. III. An open-circuit method for measuring residual air. *J. Clin. Invest.* 19: 609-618.
8. Macklem, P. T. 1974. Procedures for standardized measurements of lung mechanics, [and] Leith, D. E. and J. Mead. Principles of body plethysmography. National Heart and Lung Institute, Division of Lung Diseases, Bethesda, Md. 1-21.

⁴ Collins, J. F., W. G. Johanson, Jr., and B. McCullough. Effects of compensatory lung growth on irradiation-induced regional pulmonary fibrosis in the baboon. Submitted for publication.

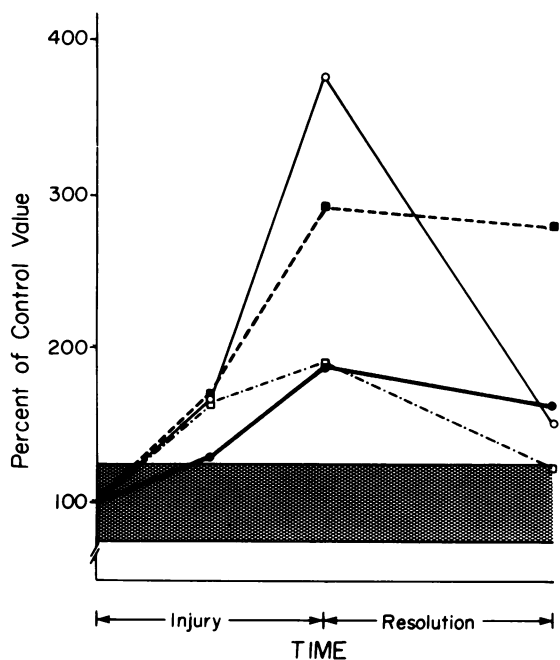


FIGURE 9 Tissue changes occurring during injury and resolution of bleomycin-induced fibrosis. The amount of each component present in the total lung was calculated by assuming that the right middle lobe represents 10% of total lung weight and that the left lung comprises 45% of total lung weight. Mean values for dry weight (○—○), DNA (□—□), collagen (●—●), and elastin (■—■) of the total lung are shown. The stippled area shows mean \pm 1 SD for all values in control specimens, expressed as total lung contents.

9. Sackner, M. A., D. Greenelch, M. S. Heiman, S. Epstein, and N. Atkins. 1975. Diffusing capacity, membrane diffusing capacity, capillary blood volume, pulmonary tissue volume, and cardiac output measured by a re-breathing technique. *Am. Rev. Respir. Dis.* 111: 157-165.
10. Carson, F. L., J. H. Martin, and J. A. Lynn. 1973. Formalin fixation for electron microscopy: a re-evaluation. *Am. J. Clin. Pathol.* 59: 365-373.
11. Nowell, J. A., J. Pangborn, and W. S. Tyler. 1972. Stabilization and replication of soft tubular and alveolar systems. A scanning electron microscope study of the lung. In *Proceedings of the Workshop on Biological Specimen Preparation Techniques for Scanning Electron Microscopy*, Chicago, 1972; Scanning Electron Microscopy—1972, Part 2. O. Johari and I. Corvin, editors. Illinois Institute of Technology Research Institute, Chicago, Ill. 305-312.
12. Bradley, K. H., S. D. McConnell, and R. G. Crystal. 1974. Lung collagen composition and synthesis. Characterization and changes with age. *J. Biol. Chem.* 249: 2674-2683.
13. Juva, K., and D. J. Prockop. 1966. Modified procedure for the assay of H³- or C¹⁴-labeled hydroxyproline. *Anal. Biochem.* 15: 77-83.
14. Burton, K. 1956. A study of the conditions and mechanism of the diphenylamine reaction for the colorimetric estimation of deoxyribonucleic acid. *Biochem. J.* 62: 315-323.
15. Lowry, O. H., N. J. Rosebrough, A. L. Farr, and R. J. Randall. 1951. Protein measurement with the Folin phenol reagent. *J. Biol. Chem.* 193: 265-275.
16. Troll, W., and J. Lindsley. 1955. A photometric method for the determination of proline. *J. Biol. Chem.* 215: 655-660.
17. Epstein, E. H., Jr., R. D. Scott, E. J. Miller, and K. A. Piez. 1971. Isolation and characterization of the peptides derived from soluble human and baboon skin collagen after cyanogen bromide cleavage. *J. Biol. Chem.* 246: 1718-1724.
18. Lansing, A. I., T. B. Rosenthal, M. Alex, and E. W. Dempsey. 1952. The structure and chemical characterization of elastic fibers as revealed by elastase and by electron microscopy. *Anat. Rec.* 114: 555-575.
19. Naum, Y., and T. E. Morgan. 1973. A microassay for elastin. *Anal. Biochem.* 53: 392-396.
20. Goldstein, A. 1964. *Biostatistics*. Macmillan, Inc., New York. 55-59.
21. Blum, R. H., S. K. Carter, and K. Agre. 1973. A clinical review of bleomycin—a new antineoplastic agent. *Cancer (Phila.)* 31: 903-913.
22. De Lena, M., A. Guzzon, S. Monfardini, and G. Bonadonna. 1972. Clinical, radiologic, and histopathologic studies on pulmonary toxicity induced by treatment with bleomycin (NSC-125066). *Cancer Chemother. Rep.* 56: 343-356.
23. Luna, M. A., C. W. M. Bedrossian, B. Lichtiger, and P. A. Salem. 1972. Interstitial pneumonitis associated with bleomycin therapy. *Am. J. Clin. Pathol.* 58: 501-510.
24. Perez-Guerra, F., L. E. Harkleroad, R. E. Walsh, and J. J. Costanzi. 1972. Acute bleomycin lung. *Am. Rev. Respir. Dis.* 106: 909-913.
25. Rudders, R. A., and G. T. Hensley. 1973. Bleomycin pulmonary toxicity. *Chest.* 63: 626-628.
26. Adamson, I. Y. R., and D. H. Bowden. 1974. The pathogenesis of bleomycin-induced pulmonary fibrosis in mice. *Am. J. Pathol.* 77: 185-198.
27. Fleischman, R. W., J. R. Baker, G. R. Thompson, U. H. Schaeppi, V. R. Illievski, D. A. Cooney, and R. D. Davis. 1971. Bleomycin-induced interstitial pneumonia in dogs. *Thorax.* 26: 675-682.
28. Aso, Y., K. Yoneda, and Y. Kikkawa. 1976. Morphologic and biochemical study of pulmonary changes induced by bleomycin in mice. *Lab. Invest.* 35: 558-568.
29. Pascual, R. S., M. B. Mosher, R. S. Sikand, R. C. De Conti, and A. Bouhuys. 1973. Effects of bleomycin on pulmonary function in man. *Am. Rev. Respir. Dis.* 108: 211-217.
30. Yagoda, A., B. Mukherji, C. Young, E. Etcubanas, C. La-Monte, J. R. Smith, C. T. C. Tan, and I. H. Krakoff. 1972. Bleomycin, an antitumor antibiotic. Clinical experience in 274 patients. *Ann. Intern. Med.* 77: 861-870.
31. Schaeppi, U., R. Phelan, S. W. Stadnicki, R. W. Fleischman, I. A. Heyman, V. Illievski, and R. A. Redding. 1974. Pulmonary fibrosis following multiple treatment with bleomycin (NSC-125066) in dogs. *Cancer Chemother. Rep.* 58: 301-310.
32. Harris, T. R., P. C. Pratt, and K. H. Kilburn. 1971. Total lung capacity measured by roentgenograms. *Am. J. Med.* 50: 756-763.
33. Pickrell, J. A., D. V. Harris, F. F. Hahn, J. J. Belasich, and R. K. Jones. 1975. Biological alterations resulting from chronic lung irradiation. III. Effect of partial ⁶⁰Co thoracic irradiation upon pulmonary collagen metabolism and fractionation in Syrian hamsters. *Radiat. Res.* 62: 133-144.