

The Relationship between Right Duct Lymph Flow and Extravascular Lung Water in Dogs Given α -Naphthylthiourea

MICHAEL B. PINE, P. MAYNARD BEACH, THOMAS S. COTTRELL, MILDRED SCOLA, and GERARD M. TURINO

From the Department of Medicine, College of Physicians and Surgeons, Columbia University, New York, 10032, and the Department of Pathology, New York Medical College, Valhalla, New York 10595

ABSTRACT The relationship between right duct lymph flow and extravascular lung water was studied in 3 normal dogs and 15 dogs with pulmonary edema induced by α -naphthylthiourea (ANTU). Right duct lymph was collected in a pouch created by ligating jugular, subclavian, and brachiocephalic veins. Extravascular lung water was measured in vivo by double indicator dilution and post-mortem by weighing lungs before and after drying. Cardiac output, pulmonary artery and pulmonary artery wedge pressures, and the concentration of protein and electrolytes in plasma and right duct lymph were determined. Eight lungs were examined by light and electron microscopy.

There was a direct relationship between right duct lymph flow (RDLF in milliliters per hour per gram dry lung) and extravascular lung water (Qwl in milliliters per gram dry lung) which was best described by the equation $RDLF = 0.75 - 0.26 Qwl + 0.03 (Qwl)^2$. Dogs with severe ANTU-induced edema had extensive lung capillary endothelial destruction but only mild interstitial swelling and no visible damage to type I alveolar epithelial cells. Cardiac output, pulmonary artery and wedge pressures, and protein and electrolyte concentrations did not correlate with either extravascular water or right duct flow.

Thus, in ANTU-induced pulmonary edema right duct

lymph flow was directly related to extravascular lung water with the highest flows occurring with severe edema. The absence of a rapid increase in lymph flow with small increases in extravascular water may be due to early sequestration of fluid in the alveolar space. Hemodynamic changes did not account for changes in lung water or lymph flow. The pulmonary interstitial factors relating increased extravascular water to lymph drainage remain to be determined.

INTRODUCTION

In 1896 Starling related the accumulation and removal of water from the interstitial space to fluid movement across the capillary membrane (1). In his model, the rate of fluid movement across this membrane was determined by a permeability coefficient and interstitial and vascular hydrostatic and osmotic pressures. Although this model explains the gross balance between intravascular and interstitial fluid, fine adjustments between these two compartments depend upon the flow of lymph from the interstitial space into the intravascular compartment.

The lung has an extensive lymphatic network and, in the 30 years since the pioneering work of Warren and Drinker (2), the flow and composition of pulmonary lymph have been described in normal dogs and in dogs with various conditions associated with increased extravascular lung water (3-16). However, the factors which govern pulmonary lymph drainage are not fully understood. In the present experiments, the relationship between extravascular lung water and right duct lymph flow was examined in dogs with varying degrees of

This paper was presented in part at the 45th Scientific Session of the American Heart Association, 17 November 1972, Dallas, Tex. An abstract of part of this work was published in 1972. *Circulation*. 46(Suppl. 2): 55.

Dr. Pine is the recipient of Special Fellowship 5 FO3 HE48180 from the U. S. Public Health Service.

Received for publication 4 October 1974 and in revised form 11 March 1976.

pulmonary edema induced by intravenous α -naphthylthiourea (ANTU).¹

METHODS

Right duct lymph was collected from 19 mongrel dogs weighing 15–26 kg. 16 of these dogs received intravenous injections of 0.25–0.75 ml/kg of a 1% solution of ANTU in propylene glycol 20–24 h before the lymph collection began. 3 dogs received no treatment before the study. All 19 dogs were anesthetized with intravenous sodium thiamylal and intubated with a cuffed endotracheal tube. The right femoral artery was cannulated. A Swan-Ganz flow-directed catheter was inserted into the right femoral vein and advanced into the pulmonary artery. A slow infusion of normal saline was administered through the catheter. Additional intravenous sodium thiamylal was given as needed to maintain active inner eye reflexes with outer eye reflexes occasionally present. The lungs were inflated maximally with an ambu bag, and 3–5 ml of a 0.5% aqueous solution of T-1824 was injected directly into the right lung via a 20-gauge needle inserted through the chest wall. The dogs were permitted to breathe room air spontaneously for the remainder of the experiment.

Right duct lymph was collected in a pouch constructed by ligating the right internal and external jugular, axillary, and brachiocephalic veins as described by Leeds et al. (17) (See Fig. 1). Since lymph from this pouch was often contaminated with blood, the pouch was opened and the orifices of small veins still patent were oversewn with 5–0 cardiovascular silk. The pouch was closed and a cannula sewn into place. From three to six 20-min collections of bloodless lymph were completed in all dogs except one which appeared to be in respiratory distress with fulminant pulmonary edema when the lymph collection was begun. In this single animal, two 15-min lymph samples were completed before the animal expired. Samples were collected in test tubes containing lithium heparin anticoagulant, and the volume of each sample was measured with a 1-ml tuberculin syringe.

Pulmonary artery, pulmonary artery wedge, and femoral artery pressures were recorded on a multichannel electronic photographic recorder (model DR-8, Electronics for Medicine Inc., White Plains, N. Y.) using a Statham P23Db transducer (Statham Instruments Div., Gould Inc., Oxnard, Calif.). These pressures were obtained during the first lymph collection period and approximately 10 min before the end of the final collection. At the time of each pressure determination, blood was withdrawn from the pulmonary and femoral arteries and analyzed for P_{O_2} , P_{CO_2} , and pH on a Blood Gas Analyzer (Instrumentation Laboratory, Inc., Lexington, Mass.). After the final measurement of pulmonary arterial pressure, 20 ml of pulmonary artery blood was removed for subsequent analysis and stored in test tubes containing lithium heparin anticoagulant. The flow-directed catheter was then withdrawn until a right ventricular pressure was recorded.

Immediately after the right-sided catheter was withdrawn into the right ventricle, extravascular lung water was measured by the double indicator dilution technique of Chinard and Enns (18). ¹²⁵I-Albumin was used as an intravascular indicator and [³H]water was the extravascular indicator. The indicators were injected into the right ventricle, and blood samples were collected from the right femoral artery into heparinized test tubes on a rotating turntable. Each

¹ Abbreviation used in this paper: ANTU, α -naphthylthiourea.

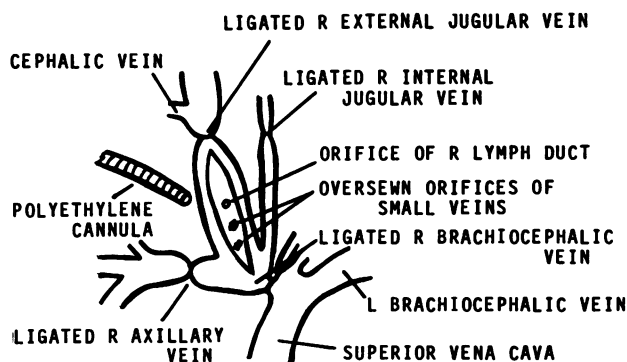


FIGURE 1 Preparation of a pouch to collect right duct lymph. The pouch is open and small veins not previously ligated are oversewn. When the pouch is closed, a cannula will be sewn in place to drain the bloodless right duct lymph.

tube received blood for 1 s. ¹²⁵I was counted on an Auto-Gamma spectrometer (Packard Instrument Co., Downers Grove, Ill.), and ³H was counted on a Tri-Carb liquid scintillation spectrometer (model 3003, Packard Instrument Co.). Indicator dilution curves were derived for both indicators with recirculation corrected by linear extension of the experimental curve on a semilogarithmic plot. Correction for the different water contents and pulmonary transit times of plasma and erythrocytes was made using the formula of Goresky et al. (19).

The lymph collection was discontinued immediately after completion of the in vivo lung water determination. Each dog was rapidly exsanguinated while its chest was opened, and pleural fluid, if present, was removed and measured. A 15-ml sample of pleural fluid was stored for later analysis in a test tube containing lithium heparin anticoagulant. The lungs were removed by cutting the main stem bronchi and the main pulmonary arteries and veins. The larger pulmonary arteries were dissected open, and gross blood was removed. Care was taken to avoid losing edema fluid from the bronchi. The lungs were weighed. A 300–500-mg section of lung was taken from the left upper lobe and also from both the left and right lower lobes. The hemoglobin contents of these three samples were used to estimate the intravascular water remaining in the lungs by the method of Levine and Mellins (20).

One lobe from each of eight dogs was prepared for light and electron microscopical examination by injecting into the bronchus a solution of 2.5% glutaraldehyde in Sorensen's phosphate buffer at pH 7.6. The lobes were then suspended in additional fixative. The fixed lung tissue was minced, washed in phosphate buffer, osmicated, and embedded in Araldite (Ladd Research Industries, Inc., Burlington, Vt.). Thin sections were stained with lead citrate and uranyl acetate and were examined with a Siemens Elmiskop 101 electron microscope (Siemens Corp., Iselin, N. J.). Tissues from similar regions were processed for light microscopy and stained with hematoxylin and eosin. Muscle, liver, and kidney sections were prepared and examined in a similar manner.

Pulmonary artery blood sampled about 5 min before death, pooled right duct lymph, and pleural fluid (if present) were centrifuged at 2,000 rpm for 30 min. In 10 experiments, the supernate was removed and analyzed for total protein, sodium, potassium, carbon dioxide, and chloride. Total protein was measured by the biuret reaction, using

a blank to determine the base line for each sample (21). Electrolyte concentrations were determined using automated sequential analysis as described by Skeggs and Hochstrasser (22). The pulmonary artery hematocrit was measured by centrifuging duplicate samples in Wintrobe tubes at 2,000 rpm for 30 min.

Postmortem extravascular lung water was measured by weighing both lungs immediately after death and suspending them in absolute alcohol for 24 h and in acetone for another 24 h. The lungs were then dried in an oven at 60°C for 72 h and weighed. Lobes suspended in glutaraldehyde were suspended in acetone for 24 h after small sections had been removed for microscopy. These lobes were then dried and weighed. Postmortem lung water was corrected for estimated intravascular water, and the dry weight of the lung was corrected for estimated residual hemoglobin content.

Data were analyzed using statistical methods described in Snedecor and Cochran (23). A coefficient of variation of successive measurements of right duct lymph flow in single experiments was computed. Hemodynamic measurements and protein and electrolyte concentrations in dogs with and without pulmonary edema were compared using a *t* test for unpaired samples. The rates of lymph flow during the first and last collections in each animal were compared using a *t* test for paired samples. A linear regression comparing postmortem and in vivo measurements of extravascular lung water, and a linear and a quadratic regression comparing right duct lymph flow and postmortem extravascular lung water were fitted by the method of least squares. Correlation coefficients were calculated, and the conditional error test

discussed by Graybill (24) was used to test for significant improvement of the quadratic over the linear equation.

RESULTS

Character of right duct lymph. In all 18 dogs reported in Table I, right duct lymph was clear and had a hematocrit of less than 1%. Opalescent right duct lymph was obtained from one dog. Since opalescence is an indication of contamination with thoracic duct lymph, data from the dog with opalescent right duct lymph were not used in any subsequent analyses. Right duct lymph and lymphatics were blue in all dogs except two. In these two dogs, lymph became clear blue within 2 min after a second injection of T-1824 directly into the right lung. In the 18 dogs studied, the rate of lymph flow in successive collections of right duct lymph in each dog had a coefficient of variation of 13%. Furthermore, in these 18 experiments, there was no significant difference in the rate of lymph flow between the first and the final collection. Thus, lymph flow in each experiment remained relatively constant during the period of observation. Right duct lymph was successfully collected in 13 of the last 22 consecutive attempts (59%).

Measurement of extravascular lung water. Extravascular lung water (Qwl) computed from wet weight,

TABLE I
Summary of Experimental Data*

Dog no.	Wt	Qdl	Qwl	idQwl	RDL flow	Pl. Eff	Qb	Mean BP			Hct	SaO ₂
								pa	paw	fa		
	kg	g	ml/g	ml/g	ml/h/g	ml	ml/kg	mm Hg			%	%
Controls												
1	21	28.3	3.8	2.4	0.19	0	100	22	5	145	33	93
2	22	30.7	4.0	2.1	0.15	0	112	10	3	125	42	97
3	20	28.0	4.3	2.3	0.23	0	120	12	6	180	52	96
Pretreated with ANTU												
4	18	29.8	3.4	2.0	0.18	0	113	16	3	150	44	97
5	22	37.8	3.5	2.3	0.11	0	152	16	3	150	43	95
6	16	27.0	3.6	2.9	0.23	0	139	16	4	130	34	95
7	16	22.9	3.8	2.5	0.28	0	97	10	—	120	44	85
8	22	33.9	4.0	2.5	0.32	0	132	18	5	135	38	95
9	21	26.7	4.6	2.1	0.30	0	133	19	6	165	43	93
10	17	24.4	4.9	3.2	0.35	0	65	—	—	150	56	94
11	20	31.4	5.1	3.2	0.25	120	99	16	4	120	46	94
12	17	28.0	6.0	4.2	0.47	160	226	23	—	195	52	90
13	19	26.0	6.9	4.2	0.52	60	135	18	10	90	51	60
14	15	23.4	7.1	3.5	0.50	25	110	16	5	155	51	92
15	16	25.6	7.6	—	0.23	300	107	18	5	110	75	80
16	16	25.6	8.0	5.0	0.68	55	96	15	4	145	52	82
17	26	44.5	9.3	—	1.22	165	—	14	4	115	73	40
18	20	37.0	10.1	—	1.35	0	149	16	6	90	72	42

* Qdl, dry lung weight; Qwl, extravascular lung water by weighing; idQwl, extravascular lung water by indicators; RDL, right duct lymph; Pl. Eff, pleural effusion; Qb, cardiac output by ¹³¹I-albumin; BP, blood pressure; pa, pulmonary artery; paw, pulmonary artery wedge; fa, femoral artery; Hct, hematocrit; SaO₂, arterial oxygen saturation.

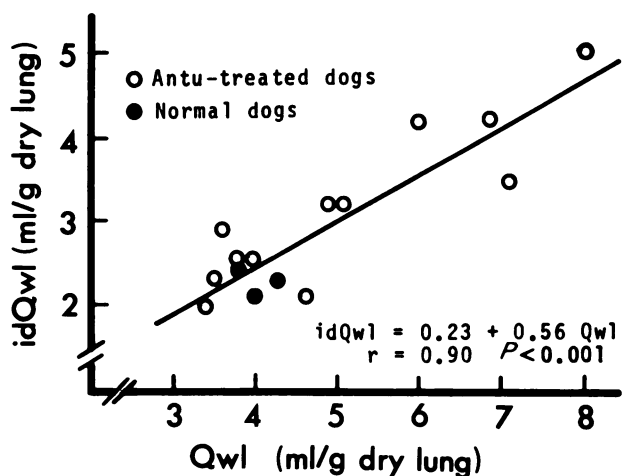


FIGURE 2 Relationship between extravascular lung water measured by weighing (Qwl) and extravascular lung water measured by double indicator dilution (idQwl).

dry weight, and hemoglobin content of lungs obtained post-mortem, and extravascular lung water measured in vivo by indicators (idQwl) are recorded in Table I. Extravascular lung water by weighing ranged from 3.8 to 4.3 ml/g dry lung in control dogs and from 3.4 to 10.1 ml/g dry lung in ANTU-treated animals. All dogs in which extravascular lung water exceeded 5 ml/g dry lung had gross evidence of pulmonary edema, i.e., clear fluid exuded from a cut section of lung which was gently squeezed soon after the dog was exsanguinated. No clear fluid was observed in similarly treated lungs from dogs where extravascular lung water was less than 5 ml/g dry lung. In vivo measurements of extravascular lung water were successfully completed in 15

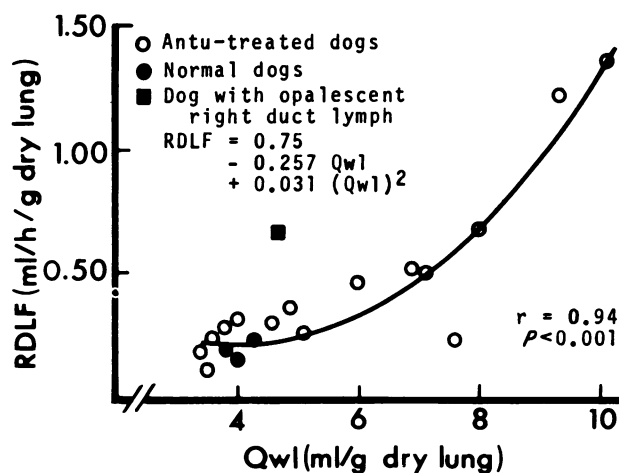


FIGURE 3 Relationship between right duct lymph flow (RDLF) and extravascular lung water measured by weighing (Qwl). Values for the dog with opalescent right duct lymph are not included in the regression equation.

of the 18 dogs with acceptable lymph collections. In two dogs (no. 15 and 18), early recirculation of tritiated water prevented the accurate completion of an indicator curve for tritiated water. One dog (no. 17) died suddenly immediately before the injection of the indicators but after all other in vivo data had been obtained.

Extravascular lung water measured by indicators averaged 61% of extravascular lung water measured by weighing. The statistically significant relationship between these two measures of extravascular lung water ($P < 0.001$) is illustrated in Fig. 2. The correlation coefficient of the best fit linear regression was 0.90, and neither exponential nor polynomial solutions resulted in any statistically significant improvement in the correlation coefficient, the standard deviation due to regression, or the F statistic.

Relation between right duct lymph flow and extravascular lung water. Right duct lymph flow (in milliliters per hour per gram dry lung) was directly related to extravascular lung water (in milliliters per gram dry lung) measured by weighing (Fig. 3). While a linear regression proved a significant correlation ($r = 0.88$), a quadratic regression represented a significant improvement (shown in Fig. 3) over the linear regression. There was no significant correlation between

TABLE II
Protein and Electrolyte Concentrations in Plasma, Right Duct Lymph, and ANTU-Induced Pleural Effusions

Dog no.	Fluid	Protein	Na ⁺	K ⁺	Cl ⁻	HCO ₃
		g/100 ml	meq/liter	meq/liter	meq/liter	meq/liter
2	Plasma	5.8	142	3.9	116	16
	Lymph	5.1	151	3.6	123	16
4	Plasma	5.7	143	3.1	114	13
	Lymph	4.3	140	3.0	119	16
5	Plasma	6.9	148	3.2	114	20
	Lymph	4.0	148	2.7	122	20
6	Plasma	4.8	144	4.4	113	17
	Lymph	3.0	157	3.7	123	17
11	Plasma	5.4	148	4.0	115	17
	Lymph	4.5	152	3.7	124	19
12	Effusion	4.5	147	3.9	120	20
	Plasma	5.9	141	3.9	108	19
13	Lymph	3.4	150	3.7	115	20
	Effusion	3.8	145	3.7	114	20
14	Plasma	4.7	143	4.1	109	15
	Lymph	3.3	142	3.4	113	17
16	Effusion	3.7	144	3.7	113	18
	Plasma	4.6	148	3.1	116	18
17	Lymph	3.7	150	3.2	120	23
	Plasma	4.6	147	3.5	115	20
18	Lymph	3.6	150	3.4	117	21
	Effusion	2.7	150	3.6	115	22
19	Plasma	6.1	137	5.1	109	17
	Lymph	4.5	140	4.2	112	20
20	Effusion	4.9	135	4.7	110	20
	Plasma	5.5	144	3.8	113	17
Mean	Lymph	3.9	148	3.5	119	19
	Effusion	3.9	144	3.9	114	20

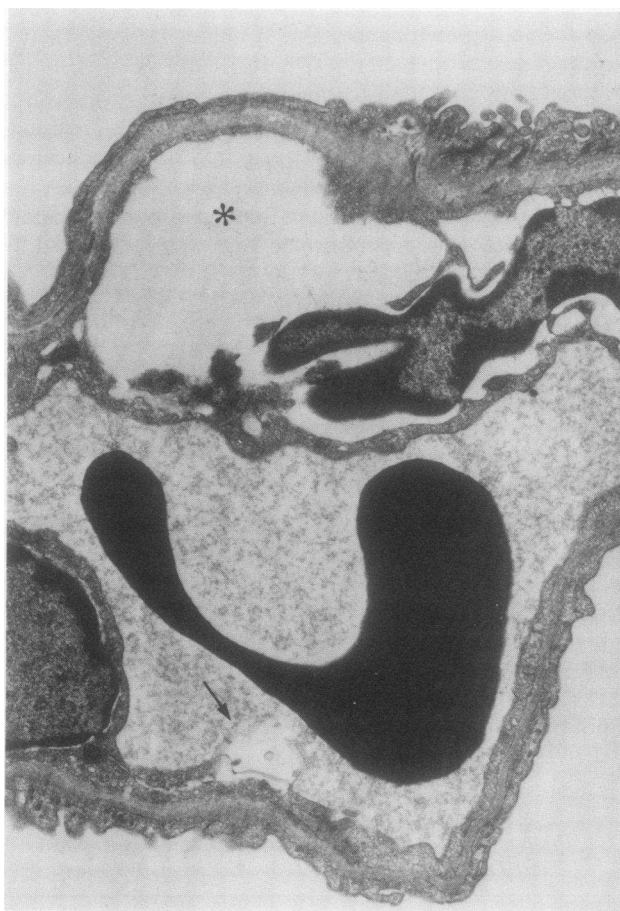

FIGURE 4 Changes in ANTU-treated lung associated with no increase in lung water. This electron micrograph shows an alveolar septum from the lung of an ANTU-treated dog which had no extravasated lung water. There is marked swelling (*) in the perinuclear endoplasmic reticulum of an endothelial cell, and vacuolization of the cytoplasm of another (→) ($\times 12,000$).

right duct lymph flow and either the quantity of pleural effusion measured post-mortem or the quantity of pleural effusion and extravascular lung water measured post-mortem. The ratio of right duct lymph flow to extravascular lung water was considerably higher in the dog with opalescent lymph than in other dogs with comparable post-mortem extravascular lung water (Fig. 3).

Lymph flow, extravascular lung water, and pulmonary hemodynamics. There was no significant relationship between right duct lymph flow or extravascular lung water and any of the following variables: (a) cardiac output, (b) mean pulmonary artery pressure, (c) mean pulmonary artery wedge pressure, and (d) pulmonary vascular resistance. When the group of 10 dogs with no gross evidence of pulmonary edema was compared to the group of 8 dogs with gross pulmonary edema,

cardiac output, mean pulmonary artery pressure, mean pulmonary artery wedge pressure, and pulmonary vascular resistance were not significantly different in the two groups.

Protein and electrolyte concentrations. Protein and electrolyte concentrations in plasma, right duct lymph, and ANTU-induced pleural effusions are summarized in Table II. There was no statistically significant difference between plasma protein and electrolyte concentrations in dogs with gross evidence of pulmonary edema (extravascular lung water greater than 5 ml/g dry lung) and plasma protein and electrolyte concentrations in dogs without gross evidence of pulmonary edema (extravascular lung water less than 5 ml/g dry lung). The ratio of the concentrations of sodium, potassium, chloride, and bicarbonate in right duct lymph to the concentrations of these electrolytes in plasma ranged from 0.92 to 1.11 and was similar in animals with and without gross edema. Right duct lymph contained significantly more sodium ($P < 0.05$), chloride ($P < 0.001$), and bicarbonate ($P < 0.01$) than plasma, while potassium was significantly higher ($P < 0.01$) in plasma than in lymph.

The ratio of the total protein concentration in right duct lymph to the total protein concentration in plasma was 0.71 and was similar in animals with and without gross pulmonary edema. In dogs with pleural effusions, the ratio of protein and electrolyte concentrations in right duct lymph to the protein and electrolyte concentrations in the effusions ranged from 0.95 to 1.02.

Anatomic changes in ANTU-induced pulmonary edema. Samples of lung from eight dogs were examined by light and electron microscopy. Two dogs (controls) were not pretreated with ANTU. Three dogs (group A) were pretreated with ANTU but showed no gross evidence of pulmonary edema. Three dogs (group B) were pretreated with ANTU and developed gross pulmonary edema. The mean extravascular lung water measured by weighing was 3.9 ml/g dry lung for the controls, 3.6 ml/g dry lung for group A, and 7.5 ml/g dry lung for group B.

Light microscopy revealed no difference between lungs from dogs in group A and lungs from control animals. Lungs from dogs in group B showed evidence of alveolar edema with only mild perivascular cuffing. The electron microscopic findings in control lungs were similar to the anatomy of lungs from normal dogs described by Cottrell et al. (25). Lungs from dogs in group A were similar to lungs from control dogs except for scattered areas of perinuclear swelling and vacuolization in the pulmonary capillary endothelium (Fig. 4). Lungs from dogs in group B showed extensive destruction of capillary endothelial cells with no visible anatomic changes in either type I alveolar epithelial

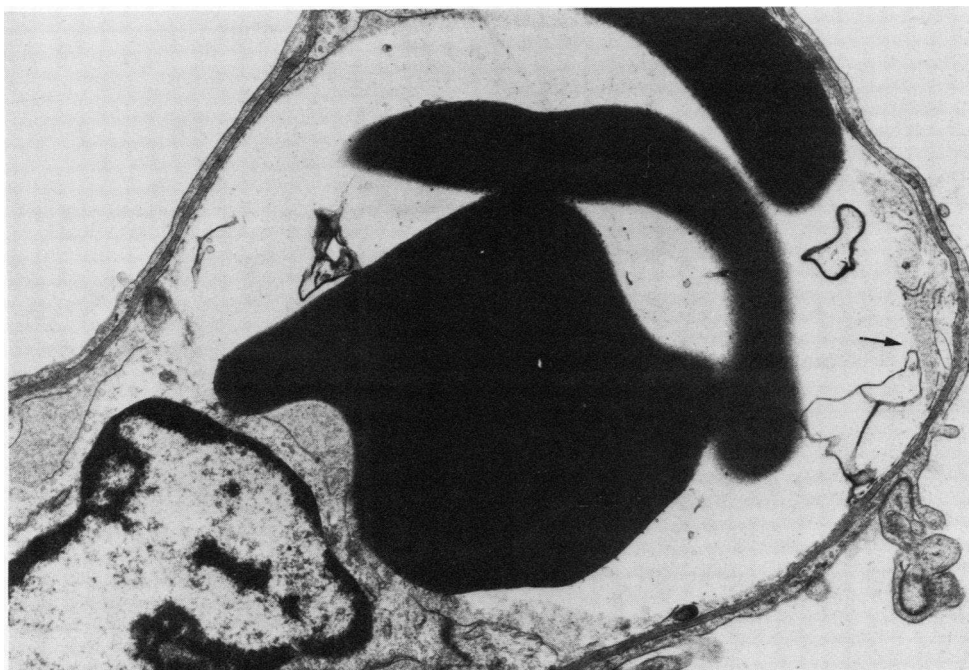


FIGURE 5 Endothelial destruction in ANTU-induced edema. This electron micrograph of an alveolar capillary from an ANTU-treated dog with severe pulmonary edema shows degenerated endothelial lining (\rightarrow). Normal appearing erythrocytes are seen in the capillary lumen. The basement membrane and the type I alveolar lining cell appear normal. ($\times 12,000$)

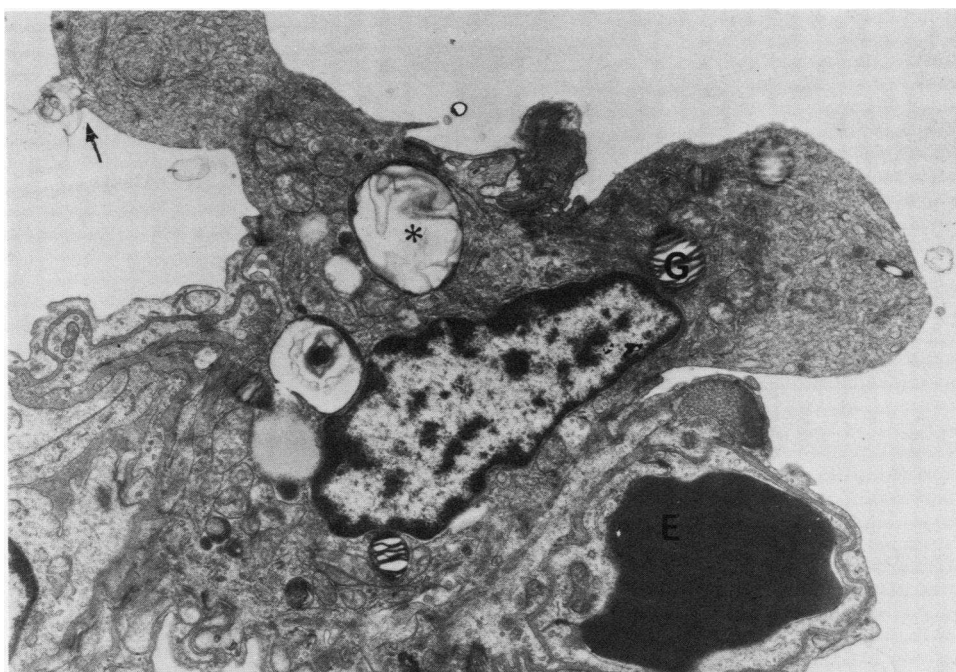


FIGURE 6 Changes in type II pneumocyte in ANTU-induced edema. In this electron micrograph a type II pneumocyte from an ANTU-treated dog shows loss of microvilli from its surface and focal degeneration of its cell surface membrane (\rightarrow). Normal lamellated bodies (G) are present along with abnormal ones (*). In the lower right, an alveolar capillary lumen is completely filled by an erythrocyte (E). ($\times 10,000$)

cells or in the endothelial basement membrane (Fig. 5). Definite morphologic changes were seen in type II alveolar epithelial cells (Fig. 6). These changes consisted of a loss of surface microvilli and focal degeneration of the cell surface membrane. There also appeared to be a diminution in the number of granules or lamellated bodies in these type II epithelial cells. In all group B animals, interstitial swelling was observed as compared with controls. However, compared to animals previously studied by Cottrell et al. (25) in which severe edema was induced by altered pulmonary capillary pressure, the anatomic evidence of interstitial swelling and disorganization of interstitial collagen bundles appeared less in ANTU-treated dogs with equivalent increases in measured extravascular lung water.

DISCUSSION

Morphological changes, right duct lymph flow, and extravascular lung water. Morphologic changes associated with ANTU-induced pulmonary edema have been studied extensively in the rat (26–31), but few studies have been reported in dogs (26). In the present study, perivascular and interstitial pulmonary edema in dogs with ANTU-induced edema was not as marked as the perivascular and interstitial pulmonary edema seen in dogs with comparable increases in extravascular lung water secondary to changes in capillary hydrostatic pressure and plasma oncotic pressure (25). Quantitative assessment of the relation between increases in interstitial fluid volume and increases in total lung water is not available for either model of pulmonary edema. However, the differences in anatomic evidence of interstitial edema accumulation in the two models indicated that the ratio of alveolar to interstitial edema was higher in the dogs studied in this experiment than in dogs with acute hydrostatic edema.

Although morphological alterations in pulmonary capillary endothelial cells were marked, no anatomic changes were seen in alveolar lining cells. However, changes in permeability can occur with anatomic changes which would be imperceptible using techniques employed in this study (32). Alterations in type II alveolar epithelial cells were observed in the ANTU-treated dogs which were absent in dogs with hydrostatically induced pulmonary edema. These alterations in type II cells could be associated with impaired surfactant production, and might be a factor in the accumulation of large amounts of alveolar water when interstitial water was only moderately increased.

Steady-state conditions with respect to edema formation or resolution in the present experiments were not conclusively established. However, since neither right duct lymph flow nor pulmonary artery or pulmonary capillary pressure changed significantly during the hour the animals were observed, it is reasonable to conclude

that neither edema formation nor edema resolution was occurring rapidly at the time of study. Thus, timing of the measurements in the present experiments most probably reflects the period after early rapid edema formation and the beginning of slow resolution of ANTU-induced edema (30).

While these experiments suggest that considerable increases in extravascular lung water must occur before right duct lymph flow increases significantly, Brigham et al. (32) observed severalfold increases in pulmonary lymph flow associated with no detectable change in extravascular lung water in sheep with increased pulmonary vascular permeability secondary to *Pseudomonas* bacteremia. There are several possible explanations for the difference in the relation of lymph flow and extravascular water in these two models. Firstly, the failure of lymph flow to increase substantially with mild increases in extravascular water in the ANTU experiments may be due to the reduction in lymphatic contractility and drainage found in anesthetized supine dogs (33) in contrast to awake upright sheep. Secondly, though extensive pulmonary capillary endothelial damage was observed in ANTU-induced edema, lymph flow and extravascular water were measured while pulmonary vascular resistance was normal. On the other hand, pulmonary capillary endothelial damage was not described in sheep after *Pseudomonas* bacteremia while pulmonary vascular resistance was nearly twice control values when steady-state lymph flow was recorded. These findings suggest that the route of fluid movement from the pulmonary vascular space into lung lymphatics may be different in ANTU and bacteremic pulmonary edema. Thirdly, there was little evidence of alveolar flooding in most of the sheep with increased lymph flow secondary to *Pseudomonas*, while increased lymph flow in ANTU poisoning was invariably accompanied by alveolar edema. Finally, the data of Brigham et al. (32) may represent an acute relationship between pulmonary lymph flow and interstitial edema, while the relation between lymph flow and lung water found in the present experiments may describe the resorption of interstitial and alveolar fluid in an early reparative phase after ANTU-induced capillary leakage has stopped.

In the present experiment and in the work of Erdmann et al. (34) no plateau for lymph flow was demonstrated. These findings contrast with the observations of Taylor et al. (35) in the dog hind limb where a plateau in lymph flow occurred when interstitial fluid pressure exceeded +2 mm Hg. Neither the existence of a relationship between pulmonary lymph flow and interstitial pressure nor a plateau of pulmonary lymph flow in specific types of pulmonary edema has been established.

Neither models of endotoxin injury to the lung nor the ANTU model used in these present studies can be considered to represent uniform steady-state conditions with respect to tissue damage. In both models increases in pulmonary water ranged from undetectable to lethal levels, and absolutely uniform distribution of vascular damage throughout the injured lung may not be assumed. It is therefore difficult to define the role of events occurring at different sites such as the capillary, precapillary, interstitial, or alveolar regions in relating lymph flow to lung water.

In ANTU-induced edema, right duct lymph flow per hour represented a substantial portion of excess extravascular water even though alveolar flooding was observed with only mild-to-moderate interstitial fluid accumulation and right duct flow is only a partial reflection of total pulmonary lymph drainage (36, 37). In models where pulmonary lymph flow increases before changes in extravascular lung water become measurable (32), the importance of the pulmonary lymphatics in lung fluid homeostasis is even more apparent.

In the present experiments, a consistent relationship between indicator dilution and gravimetric measurements of extravascular lung water was maintained over a wide range, despite the scatter observed mainly at lower levels of lung water. Thus, although there were substantial pleural effusions and extensive destruction of the pulmonary capillary endothelium, the double indicator dilution method reflected a consistent proportion of the amount of extravascular water present in ANTU-induced edema. The linear relationship found in the present study between in vivo indicator dilution and postmortem gravimetric measurements is consistent with a similar linear relationship obtained by Levine et al. (38) in closed chest dogs with pulmonary edema produced by changing hydrostatic and osmotic pressures. In both studies, these linear relationships appeared to remain valid with high postmortem water contents and significant alveolar flooding. In contrast to these findings, Pearce et al. (39) failed to detect significant increases in extravascular lung water in alloxan-treated animals using double indicator dilution. In their experiments the ratio of in vivo to postmortem lung water was less in alloxan-treated animals than in controls. When they produced pulmonary edema by raising pulmonary capillary hydrostatic pressure, the ratio of indicator dilution to gravimetrically measured water was greater than control values. However, a fourfold increase in cardiac output in the animals with hydrostatically induced edema was consistent with pulmonary capillary recruitment which can account for increases in the proportion of gravimetrically determined lung water actually measured by double indicator dilution (19). Thus, while the present study suggests

that chemically and hydrostatically induced edema may be compared using double indicator dilution in closed chest dogs with similar cardiac outputs and satisfactory recovery of extravascular markers, additional studies are needed to allow generalization to different experimental conditions and types of pulmonary edema.

Changes in blood and right duct lymph in ANTU-induced edema. The ratio of right duct lymph protein concentration to plasma protein concentration in non-edematous dogs in this study was 0.71 which is similar to the ratio of 0.65 found in normal dogs by Cameron et al. (7). The development of ANTU-induced pulmonary edema did not affect this ratio despite significant increases in lymph flow. On the other hand, augmenting right duct lymph flow by producing pulmonary venous hypertension is associated with reductions in right duct lymph protein concentration (2, 12, 32). Since no decrease in the ratio of lymph to plasma protein concentrations was observed in ANTU-induced edema, some increase in pulmonary capillary permeability probably occurred. Inasmuch as the ratio of lymph to plasma protein concentrations in ANTU-induced edema was the same as in normal dogs, changes in interstitial protein concentration do not appear to be responsible for the increased lymph flow seen in edematous animals. Similarly, while pulmonary vascular hydrostatic pressures, intravascular osmotic pressure, cardiac output, and pulmonary vascular resistance may have changed early in the development of ANTU-induced edema, the fact that they were all normal during the period of measurement in these experiments makes it unlikely that these factors were responsible for observed increases in pulmonary extravascular water volume or right duct lymph flow.

Extensive destruction of the pulmonary capillary endothelium was present in ANTU-induced edema, but erythrocytes were not seen in either the interstitial or alveolar space and no gross blood was present in right duct lymph collected from edematous dogs. On the other hand, in pulmonary edema produced by altering pulmonary capillary hydrostatic and osmotic pressures in dogs, erythrocytes were seen in the pulmonary interstitium (25), and right duct lymph became grossly bloody (2, 10). Thus the alveolar capillary endothelium may not be essential to prevent the movement of erythrocytes out of the vascular space if the capillary basement membrane remains intact and intravascular hydrostatic pressure is not elevated.

The rise in hematocrit observed in edematous animals in the present study is comparable to the hemoconcentration which accompanies pulmonary edema produced by other toxins (5, 7) or by increased pulmonary capillary hydrostatic pressure (10). This increased hematocrit is consistent with loss of vascular fluid into the lungs and pleural space with only minimal replace-

ment of intravascular fluid from other areas of the body.

Electron micrographs of skeletal muscle, liver, and kidney in three severely edematous dogs in the present study revealed no visible increase in interstitial water, and Latta (26) and Richter (27) found no evidence of fluid loss outside the lungs and pleural space in a wide variety of animals given lethal doses of ANTU. Thus, ANTU appears to selectively increase vascular permeability only in the pulmonary and pleural circulations (30).

Pulmonary lymph drainage and right duct lymph flow. Right duct lymph flow measured in the present experiments differs from total pulmonary lymph flow since the right lymph duct drains areas other than the lungs and pulmonary lymph drains through other lymph pathways. Changes in cardiac lymph flow through the right lymph duct could occur secondary to either a direct effect of ANTU on the heart or to changes in cardiac lymph drainage associated with hypoxia. However, there is no evidence indicating that ANTU-induced changes in vascular permeability occur outside the lungs and pleural space (26, 27), and the levels of arterial oxygen saturation in these experiments were not sufficient to significantly alter right duct lymph flow (40–42). Substantial amounts of pleural effusion were present in several ANTU-treated dogs, but previous observations by Starling and Tubby (43), Courtice and Simmonds (9), and Stewart and Burgen (44) indicate that reabsorption of pleural fluid through the right lymph duct is negligible in supine anesthetized animals. Furthermore, the absence of any correlation between right duct lymph flow and either the amount of pleural effusion or the amount of effusion plus extravascular lung water suggests that changes in right duct lymph flow were not significantly influenced by these effusions. In the present experiments, lymph from the right head, neck, and foreleg regions was not deliberately diverted from the pouch in which right duct lymph was collected. However, lymph flow from these regions is almost nonexistent unless the head or paw is manipulated (45). Finally, bronchial lymph drainage into the right duct and higher conductances in other lymphatic pathways might affect the relationship between measured flow and actual pulmonary lymph drainage, but are not likely to alter the relationship between measured and actual flow when control and edematous states are compared.

Drinker (4) studied pulmonary lymph drainage using India ink as a marker and concluded that, in the dog, the right lymph duct consistently drained the entire right lung and all of the left lung except the apex. However, Meyer and Ottaviano (36, 37), using more sophisticated techniques, concluded that about one-third

of pulmonary lymph flow was through the right duct. The difference between the fraction of lung anatomically drained by the right lymph duct and the smaller fraction of pulmonary lymph flow found in the right duct in Meyer and Ottaviano's experiments suggests that right duct lymph may cross over into the thoracic duct. However, despite this apparent crossover, the narrow range of right duct flows (in milliliters per hour per gram dry lung) observed in the present experiments in dogs with clear right duct lymph and normal extravascular lung water suggests a consistent relationship between right duct lymph flow and actual pulmonary lymph flow in nonedematous dogs. Finally, Meyer and Ottaviano (36) found that in alloxan-induced pulmonary edema, the fraction of total pulmonary lymph flow drained by the right duct was unchanged from the nonedematous state, making right duct lymph flow a reasonable indicator of changes in total pulmonary lymph flow associated with the development of pulmonary edema.

Factors relating pulmonary lymph flow to extravascular lung water. The factors which relate changes in pulmonary lymph flow to changes in fluid movement across the pulmonary capillary membrane remain to be determined. Under steady-state conditions, net flow out of the pulmonary vascular bed must equal pulmonary lymphatic drainage, but with changes in vascular permeability, a new steady state may occur because of changes induced in the pulmonary interstitium which in turn give rise to increased lymph flow. Thus, while it is probable that increases in extravascular lung water and residual changes in capillary permeability at the time of study were both related to the severity of the initial injury, it is difficult to postulate a direct relationship between residual capillary leakage and lymph flow without involving some change in the lung parenchyma which directly influences the flow of lymph out of the lungs.

In *Pseudomonas* bacteremia a marked increase in lymph flow was associated with small increases in lung water and little anatomic change. On the other hand, in ANTU-induced edema studied approximately 20 h after the initial insult, significant increases in lymph flow were present only when large quantities of extravascular water were present. The relation between right duct lymph flow and extravascular lung water in the present experiments may represent either a relatively slow removal of alveolar fluid during the reparative stage of ANTU-induced edema or a process in which alveolar fluid is essentially sequestered and the significant functional relationship is between right duct flow and interstitial rather than total lung water. In either case, the relation between right duct lymph flow and extravascular lung water in this study and the ob-

servations of Brigham et al. (32) in *Pseudomonas* bacteremia are not necessarily incompatible and are both consistent with great sensitivity of pulmonary lymph flow to small changes in interstitial as opposed to total lung water.

In the understanding of the exact relationship between lung lymph flow and extravascular water volume, the precise partition between interstitial and alveolar water could be of critical importance and is worthy of detailed investigation if suitable methods can be devised. Furthermore, the relationship between pulmonary extravascular water and right duct lymph flow in the present experiments represents data obtained at one stage in a particular model of pulmonary edema. There are no data available to indicate the relative rates of accumulation or resolution of edema at the time these animals were studied, and an association between lung water and lymph flow may exist only at certain stages in the edematous state. Furthermore, the relationship found in this study may be a direct result of the injury produced by ANTU rather than a general relationship between lung edema and lymph flow in all models. Definition of changes induced in the interstitium of the lung during edema formation secondary to different mechanisms may elucidate the factors which relate capillary permeability to lymph flow in the lung.

ACKNOWLEDGMENTS

This work was supported by grants HE 05741 and HE 15832 from the National Heart and Lung Institute, National Institutes of Health.

REFERENCES

1. Starling, E. H. 1896. On the absorption of fluids from the connective tissue spaces. *J. Physiol. (Lond.)*. 19: 312-326.
2. Warren, M. F., and C. K. Drinker. 1942. The flow of lymph from the lungs of the dog. *Am. J. Physiol.* 136: 207-221.
3. Warren, M. F., D. K. Peterson, and C. K. Drinker. 1942. The effects of heightened negative pressure in the chest, together with further experiments upon anoxia in increasing the flow of lung lymph. *Am. J. Physiol.* 137: 641-648.
4. Drinker, C. K. 1945. *Pulmonary Edema and Inflammation*. Harvard University Press, Cambridge, Mass. 106 pp.
5. Cameron, G. R., and F. C. Courtice. 1946. The production and removal of oedema fluid in the lung after exposure to carbonyl chloride (phosgene). *J. Physiol. (Lond.)*. 105: 175-185.
6. Courtice, F. C., and P. J. Phipps. 1946. The absorption of fluids from the lungs. *J. Physiol. (Lond.)*. 105: 186-190.
7. Cameron, G. R., F. C. Courtice, and R. H. D. Short. 1947. Disturbances of function induced by lewisite (2-chlorovinyl dichlorarsine). *Q. J. Exp. Physiol.* 34: 1-28.
8. Drinker, C. K., and E. Hardenbergh. 1949. Acute effects upon the lungs of dogs of large intravenous doses of alpha-naphthyl thiourea (ANTU). *Am. J. Physiol.* 156: 35-43.
9. Courtice, F. C., and W. J. Simmonds. 1949. Absorption of fluids from the pleural cavities of rabbits and cats. *J. Physiol. (Lond.)*. 109: 117-130.
10. Rabin, E. R., and E. C. Meyer. 1960. Cardiopulmonary effect of pulmonary venous hypertension with special reference to pulmonary lymphatic flow. *Circ. Res.* 8: 324-335.
11. Uhley, H. N., S. E. Leeds, J. J. Sampson, and M. Friedman. 1960. Right duct lymph flow in dogs measured by a new method. *Dis. Chest.* 37: 532-534.
12. Uhley, H., S. E. Leeds, J. J. Sampson, and M. Friedman. 1961. Some observations on the role of the lymphatics in experimental acute pulmonary edema. *Circ. Res.* 9: 688-693.
13. Uhley, H. N., S. E. Leeds, J. J. Sampson, and M. Friedman. 1962. Role of pulmonary lymphatics in chronic pulmonary edema. *Circ. Res.* 11: 966-970.
14. Said, S. I., R. K. Davis, and C. M. Banerjee. 1965. Pulmonary lymph. Demonstration of its high oxygen tension relative to systemic lymph. *Proc. Soc. Exp. Biol. Med.* 119: 12-14.
15. Uhley, H. N., S. E. Leeds, J. J. Sampson, N. Rudo, and M. Friedman. 1966. The temporal sequence of lymph flow in the right lymphatic duct in experimental chronic pulmonary edema. *Am. Heart J.* 72: 214-217.
16. Uhley, H. N., S. E. Leeds, J. J. Sampson, and M. Friedman. 1967. Right duct lymph flow in experimental heart failure following acute elevation of left atrial pressure. *Circ. Res.* 20: 306-310.
17. Leeds, S. E., H. N. Uhley, J. J. Sampson, and M. Friedman. 1959. A new method for measurement of lymph flow from the right duct in the dog. *Am. J. Surg.* 98: 211-216.
18. Chinard, F. P., and T. Enns. 1954. Transcapillary pulmonary exchange of water in the dog. *Am. J. Physiol.* 178: 197-202.
19. Goresky, C. A., R. F. P. Cronin, and B. E. Wangel. 1969. Indicator dilution measurements of extravascular water in the lungs. *J. Clin. Invest.* 48: 487-501.
20. Levine, O. R., and R. B. Mellins. 1971. The assessment of lung perfusion by measurement of extravascular lung water. In *Central Hemodynamics and Gas Exchange*. C. Giuntini, editor. Minerva Medica, Torino. 129-141.
21. Failing, J. F., Jr., M. W. Buckley, and B. Zak. 1960. Automatic determination of serum proteins. *Am. J. Clin. Pathol.* 33: 83-88.
22. Skeggs, L. T., Jr., and H. Hochstrasser. 1964. Multiple automatic sequential analysis. *Clin. Chem.* 10: 918-936.
23. Snedecor, G. W., and W. G. Cochran. 1967. *Statistical Analysis*. The Iowa University Press, Ames, Iowa. 6th edition. 593 pp.
24. Graybill, F. A. 1961. *An Introduction to Linear Statistical Models*. McGraw-Hill Book Co., New York. 1-463.
25. Cottrell, T. S., O. R. Levine, R. M. Senior, J. Weiner, D. Spiro, and A. P. Fishman. 1967. Electron microscopic alterations at the alveolar level in pulmonary edema. *Circ. Res.* 21: 783-797.
26. Latta, H. 1947. Pulmonary edema and pleural effusion produced by acute alpha-naphthyl thiourea poisoning in rats and dogs. *Bull. Johns Hopkins Hosp.* 80: 181-197.
27. Richter, C. P. 1952. The physiology and cytology of pulmonary edema and pleural effusion produced in rats by alpha-naphthyl thiourea (ANTU). *J. Thorac. Surg.* 23: 66-91.

28. Tobin, C. E. 1955. Lymphatic drainage of rat lungs, made edematous by intraperitoneal injection of ANTU. *Anat. Rec.* 121: 420. (Abstr.)
29. Teplitz, C. 1968. The ultrastructural basis for pulmonary pathophysiology following trauma. *J. Trauma.* 8: 700-714.
30. Cunningham, A. L., and J. V. Hurley. 1972. Alpha-naphthyl-thiourea-induced pulmonary oedema in the rat: A topographical and electron-microscope study. *J. Pathol.* 106: 25-35.
31. Meyrick, B., J. Miller, and L. Reid. 1972. Pulmonary oedema induced by ANTU, or by high or low oxygen concentrations in rat—an electron microscopic study. *Br. J. Exp. Pathol.* 53: 347-358.
32. Brigham, K. L., W. C. Woolverton, L. H. Blake, and N. C. Staub. 1974. Increased sheep lung vascular permeability caused by *Pseudomonas bacteremia*. *J. Clin. Invest.* 54: 792-804.
33. Yoffey, J. M., and F. C. Courtice. 1970. Lymphatics, Lymph and the Lymphomyeloid Complex. Academic Press Inc., Ltd., London. 942 pp.
34. Erdmann, A. J., III, T. R. Vaughan, Jr., K. L. Brigham, W. C. Woolverton, and N. C. Staub. 1975. Effect of increased vascular pressure on lung fluid balance in unanesthetized sheep. *Circ. Res.* 37: 271-284.
35. Taylor, A. E., W. H. Gibson, H. J. Granger, and A. C. Guyton. 1973. The interaction between intracapillary and tissue forces in the overall regulation of interstitial fluid volume. *Lymphology.* 6: 192-208.
36. Meyer, E. C., and R. Ottaviano. 1972. Pulmonary collateral lymph flow: Detection using lymph oxygen tensions. *J. Appl. Physiol.* 32: 806-811.
37. Meyer, E. C., and R. Ottaviano. 1974. Right lymphatic duct distribution volume in dogs: Relationship to pulmonary interstitial volume. *Circ. Res.* 35: 197-203.
38. Levine, O. R., R. B. Mellins, and A. P. Fishman. 1965. Quantitative assessment of pulmonary edema. *Circ. Res.* 17: 414-426.
39. Pearce, M. L., J. Yamashita, and J. Beazell. 1965. Measurement of pulmonary edema. *Circ. Res.* 16: 482-488.
40. Maurer, F. W. 1940. The effects of decreased blood oxygen and increased blood carbon dioxide on the flow and composition of cervical and cardiac lymph. *Am. J. Physiol.* 131: 331-348.
41. Ullal, S. R., T. H. Kluge, W. J. Kerth, and F. Gerbode. 1972. Flow and composition of cardiac lymph in dogs. *Ann. Surg.* 175: 299-304.
42. Ullal, S. R., T. H. Kluge, W. J. Kerth, and F. Gerbode. 1972. Changes in cardiac lymph of dogs during and after anoxia. *Ann. Surg.* 175: 472-478.
43. Starling, E. H., and A. H. Tubby. 1894. On absorption from and secretion into the serous cavities. *J. Physiol. (Lond.)* 16: 140-155.
44. Stewart, P. B., and A. S. V. Burgen. 1958. The turnover of fluid in the dog's pleural cavity. *J. Lab. Clin. Med.* 52: 212-230.
45. McCarrell, J. D. 1939. Lymphatic absorption from the nasopharynx. *Am. J. Physiol.* 126: 20-27.