

# Failure of Nitro Blue Tetrazolium Reduction in the Phagocytic Vacuoles of Leukocytes in Chronic Granulomatous Disease

DAVID G. NATHAN, ROBERT L. BAEHNER, and DON K. WEAVER

*From the Division of Hematology of the Department of Medicine, Children's Hospital Medical Center, and the Departments of Pediatrics and Anatomy, Harvard Medical School, Boston, Massachusetts 02115*

**ABSTRACT** The leukocytes of patients with chronic granulomatous disease (CGD) may be identified by their failure to reduce Nitro Blue Tetrazolium (NBT) during phagocytosis. This reaction, normally detected in the phagocytic vacuole, is absent or delayed in CGD monocytes and eosinophils as well as in neutrophils, even though sonicates of normal and CGD leukocytes contain equal activities of a cyanide insensitive enzyme system capable of reduction of NBT in the presence of pyridine nucleotide.

Enlargement of CGD phagocytic vacuoles appears to be inhibited. Histochemical estimates of the rate of release of alkaline phosphatase are normal in CGD cells. Peroxidase activity is released from CGD cells, but the rate appears to be somewhat slower than normal in some cases. The latter observation may be explained by the increased intensity of the peroxidase stain in resting and phagocytizing CGD cells.

The severity of the defect in NBT reduction within the phagocytic vacuoles of the leukocytes of patients and carriers is more variable than was previously appreciated. Some female carriers have profoundly reduced dye reduction and others are nearly indistinguishable from normal. Three brothers with CGD demonstrated significant, albeit delayed, NBT reduction in phagocytic vacuoles during prolonged incubation of their leukocytes. No obvious relationship exists, however, between the rate of reduction of NBT in vacuoles and the clinical severity of the disease.

## INTRODUCTION

During phagocytosis, normal granulocytes exhibit augmented aerobic metabolism (1), which may be governed

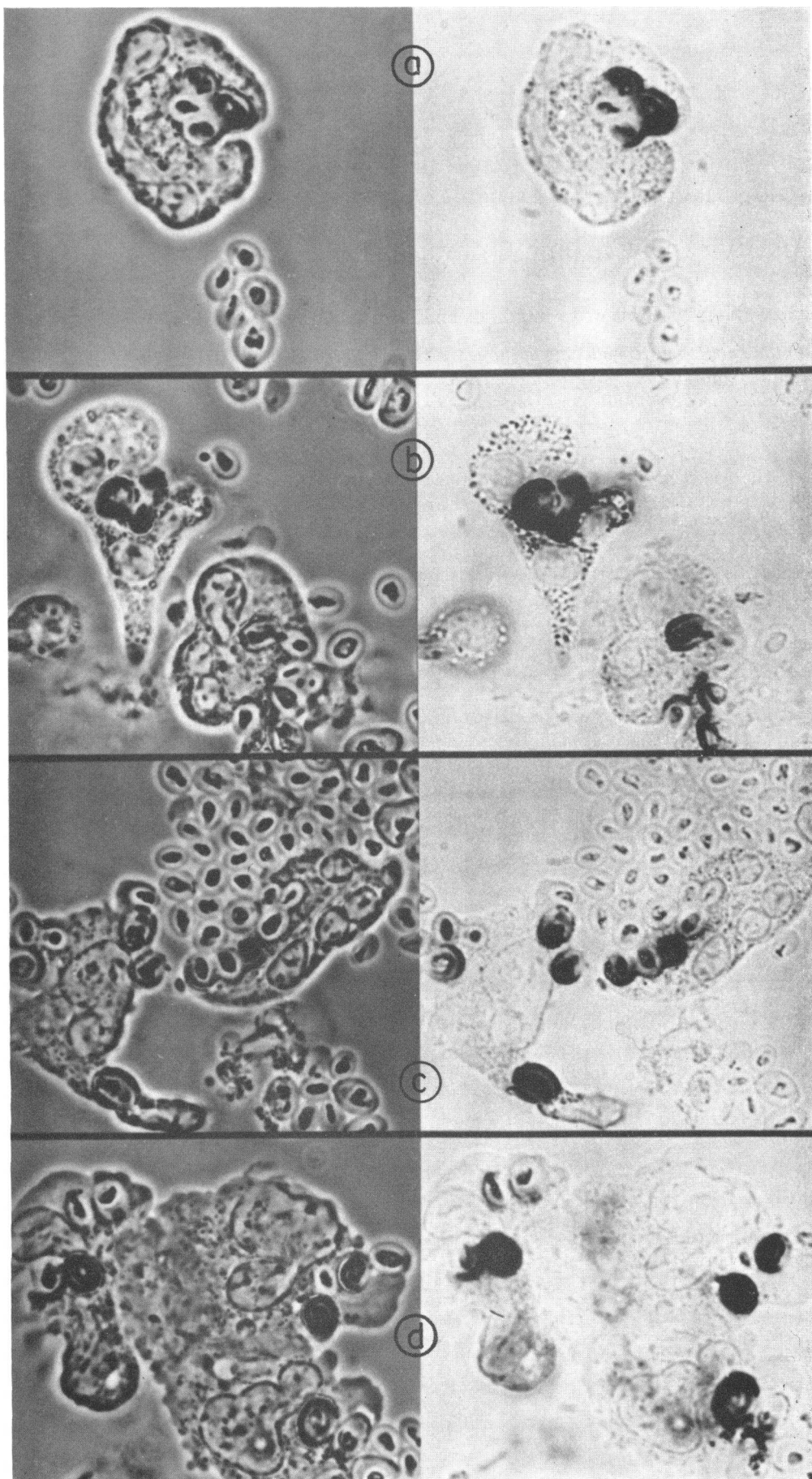
by NADH<sup>1</sup> oxidase activity (2, 3), and promptly reduce Nitro Blue Tetrazolium (NBT) to blue formazan (4-7). The granulocytes of patients with chronic granulomatous disease (CGD) ingest particles normally (8), but fail to kill certain bacteria (8-10), are deficient in NADH oxidase activity (3, 7), lack the respiratory burst (5, 11), and do not reduce NBT (4-7). The latter important difference has formed the basis of an accurate quantitative dye test (5) for the detection of this inherited disease and its carrier state (6, 7). Since the decreased NBT reaction which characterizes the CGD cell is likely to be intimately related to the metabolic and bactericidal deficiencies of these cells, closer examination of the characteristics of NBT reduction during phagocytosis might provide further information concerning both the pathogenesis of this severe disease and normal leukocyte metabolism.

The experiments presented in this paper are based on the fact that human leukocytes avidly engulf zymosan particles (12-14). This process, with concomitant peroxidase and alkaline phosphatase release, and NBT reduction, can be observed by bright-field and phase microscopy or with histochemical methods. When these techniques were applied to normal and CGD leukocytes, it was found that reduced NBT is localized mainly within or around the phagocytic vacuoles of normal neutrophils, eosinophils, and monocytes. The reduced dye appears very slowly, if at all, in phagocytic vacuoles of CGD granulocytes and monocytes despite the fact that CGD cell sonicates contain normal pyridine nucleotide: "NBT reductase" activity. Thus, the present results indicate that NBT reduction in normal leukocytes depends upon activation of an enzyme system in the phagocytic vacuole.

Some of these data have been presented in abstract form in *J. Clin. Invest.* 47: 3a.

Received for publication 12 December 1968 and in revised form 6 June 1969.

<sup>1</sup> Abbreviations used are: NADH, nicotinamide adenine dinucleotide, reduced form; NADPH, nicotinamide adenine dinucleotide phosphate, reduced form; CGD, chronic granulomatous disease; NBT, Nitro Blue Tetrazolium.



Such a system is present in CGD cells but it fails to operate within their phagocytic vacuoles. On the other hand, histochemical analyses of degranulation rates utilizing peroxidase and alkaline phosphatase stains have failed to provide convincing evidence of a delay in release of these enzymes in CGD.

The zymosan: leukocyte: NBT system provides valuable practical information regarding the number and type of phagocytes which contain reduced dye. It identifies CGD patients and certain female carriers and emphasizes the wide variation in severity of the cellular lesion. The system also reveals that CGD monocytes and eosinophils share the defect observed in CGD neutrophils.

## METHODS

Leukocytes were harvested from normal individuals, patients with CGD, and their parents by simple sedimentation methods. The blood was drawn in a heparinized 30 ml plastic syringe. The syringe was inverted and incubated for 30 min at 37°C. The white cell and platelet-rich plasma was expressed from the syringe into a plastic centrifuge tube which was then centrifuged at 500 *g* for 10 min at 4°C to provide a leukocyte button. The plasma was then removed and centrifuged at 3000 *g* for 10 min to decrease the number of platelets. The leukocytes were washed twice in Krebs-Henseleit buffer, pH 7.4, and then resuspended at a concentration of approximately 100,000 cells/mm<sup>3</sup> either in platelet-poor plasma, in fresh frozen (80°C) AB+ serum or in phosphate-buffered isotonic sodium chloride, pH 7.4, to which bovine serum albumin at a concentration of 1 g/100 ml was added. These cells suspensions were utilized in subsequent manipulations.

*Leukocyte sonicates.* Normal and CGD leukocyte sonicates were prepared by suspending 0.2 ml of cell concentrate in 1 ml of 0.34 M sucrose. This preparation was exposed to sonic disruption using a Medical Science Electronics Inc. ultrasonic power unit set at 110 v and 1.8 amp for 1 min. Normal and CGD cells were completely disrupted by this technique.

*Leukocyte incubation.* Incubations of leukocytes were performed either in plasma, serum, or buffer. NBT manufactured by Sigma was added to some of the incubates from a freshly prepared solution of 10 mg NBT dissolved in 10 ml physiological saline buffered with phosphate ion at pH 7.4. The final concentration of NBT when it was added to the incubates was 25 mg/100 ml. Powdered zymosan was purchased from Nutritional Biochemicals and boiled and washed according to the methods outlined by Hirsch (12). It was finally suspended in physiological saline and a volume of concentrated zymosan particles was added to some of the cell suspensions such that the numerical ratio of zymosan to leukocytes was approximately 10. For certain studies zymosan-bound NBT was prepared in the following manner. Zymosan was boiled, washed, and then suspended in buffered saline to which 0.1% NBT had been added. After incubation for 30 min at 37°C, the zymosan particles were twice washed in

the buffer so as to remove excess NBT. The presence of residual NBT bound to the washed zymosan particles was confirmed by the addition of isotonic alkaline sodium ascorbate to the particles, a procedure which promptly turned them blue. The plastic tubes which contained the cell suspensions with or without NBT and with or without zymosan or zymosan-bound NBT were incubated in a shaking water bath at 37°C for variable lengths of time.

*Morphology.* a. Direct observation and photomicrography of the cellular sites of NBT reduction were performed by phase, cine-phase, or bright-field microscopy of wet preparations of leukocytes during or after ingestion of zymosan particles in the presence of excess NBT or after ingestion of zymosan bound NBT. In the latter incubations excess NBT was not added to the medium.

b. Smears of CGD cells which had ingested zymosan-bound NBT were prepared on glass slides. They were then exposed to formalin vapor for 30 min, washed, and finally incubated for 2 min under an isotonic solution of alkaline sodium ascorbate. The cells were then examined microscopically for the presence of ingested blue zymosan.

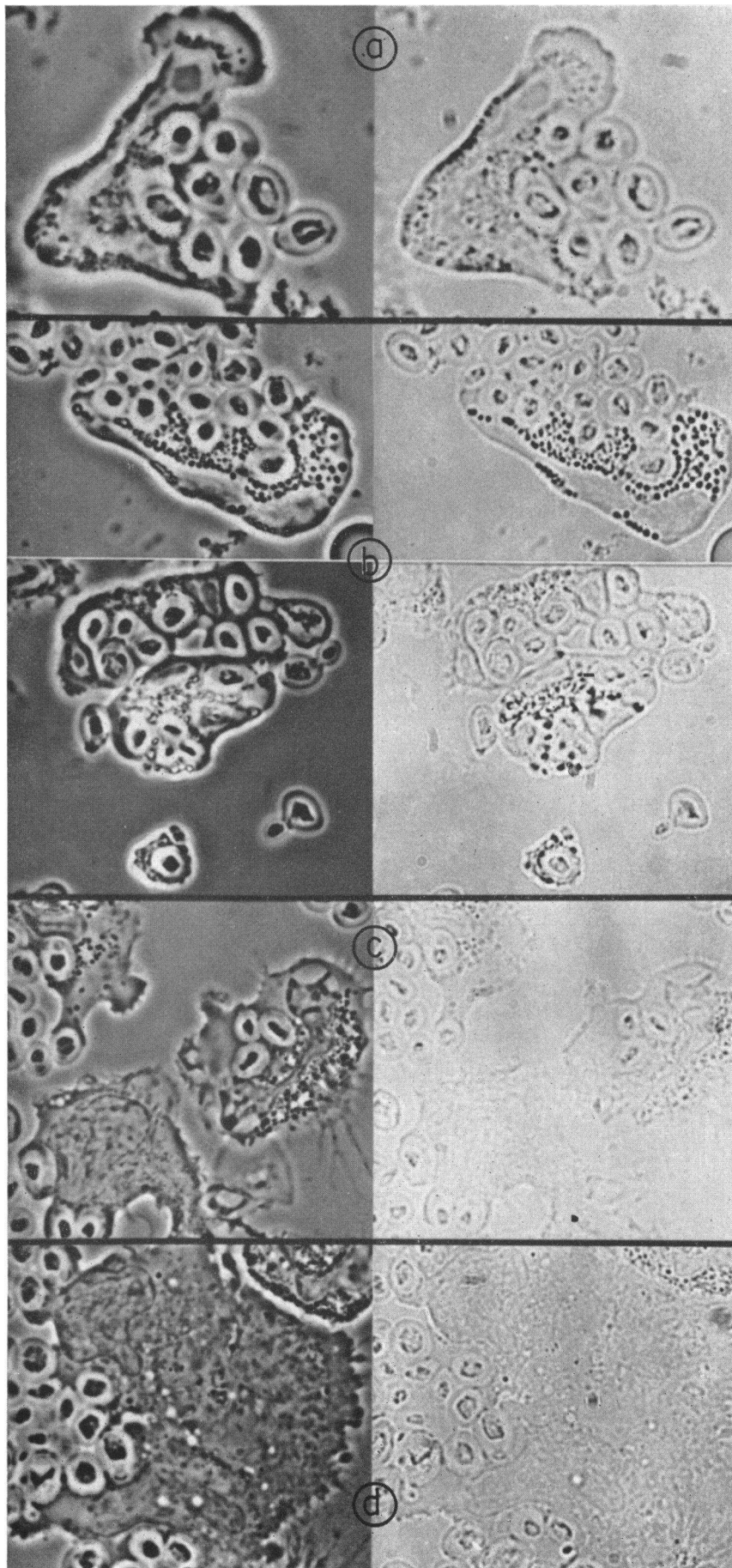
c. Aliquots of normal and CGD cell incubates were either smeared and air dried on glass slides and cover slips, or fixed in 2% v/v glutaraldehyde in phosphate-buffered isotonic sucrose (pH 7.0), or frozen on enamel plates which were mounted on solid carbon dioxide and sectioned in a cryostat. Some of the smears were fixed in formalin vapor or under 95% methanol for 30 min at 23°C. The formalin vapor-fixed and the frozen sectioned resting cells were incubated for 1 hr at 37°C under an isotonic phosphate-buffered sodium chloride solution (pH 7.0) which contained 10<sup>-8</sup> M NBT and 10<sup>-8</sup> M NADH. Some of the glutaraldehyde-fixed cells were washed with phosphate-buffered isotonic sucrose containing calcium chloride at a concentration of 50 mg/liter. The cells were then exposed to osmium, dehydrated with ethanol, and embedded in Araldite for sectioning with a glass knife on Porter Blum MT-1 microtome. The thick sections were stained with toluidine blue for light microscopy. Some of the thin sections were stained with lead citrate for electron microscopy.<sup>2</sup> Other sections were not stained.

d. The methanol-fixed cell smears were counter stained with safranin for enumeration of the number and kinds of leukocytes which contained reduced NBT in and around phagocytic vacuoles. Others of these preparations were stained for peroxidase and alkaline phosphatase activities by the methods of Kaplow (15, 16). The intensity of stain was classified either as zero or from 1 to 3+ in each of at least 100 cells by an unbiased observer and a staining score was thereby established. The per cent of the mean resting score at each period of incubation was determined. The average number of ingested zymosan particles in phagocytizing CGD and normal cells were indistinguishable at all intervals of incubation.

*Determination of "NBT reductase" activity in cell sonicates.* Whole sonicates containing 0.1–0.5 mg protein were

<sup>2</sup> The Araldite sections were prepared in the laboratory of Doctors Elizabeth Hay and Jean-Paul Revel and the electron micrographs prepared in an RCA electron microscope in the Department of Anatomy, Harvard Medical School.

FIGURE 1 Nearly simultaneous phase (left) and bright field (right) photomicrographs of normal neutrophil (a), eosinophil and neutrophil (b), neutrophil and monocyte (c), and neutrophil and two monocytes (d) 20 min after incubation with zymosan and NBT on a glass slide under a cover slip. Dye reduction is observed only on and around phagocytized zymosan. Extracellular zymosan is not stained.



added to 1.0 ml of 0.1 M pH 7.0 phosphate buffer,  $1 \times 10^{-3}$  M NADH or NADPH,  $1.0 \times 10^{-3}$  M KCN and  $1.0 \times 10^{-3}$  M NBT. After incubation for 30 min at 37°C, the reaction was stopped with 1 ml of 1 N HCl. The blue-colored formazan was extracted with 2 ml of pyridine and the absorbance determined at 560 mμ. A standard curve was constructed from known amounts of formazan prepared by treatment of NBT with alkaline sodium ascorbate.

## RESULTS

**Morphology and NBT reduction.** Microscopic observations of wet preparations of normal leukocytes ingesting zymosan in the presence of NBT revealed that blue formazan first appeared in neutrophils, eosinophils, and monocytes only in and around the phagocytic vacuoles. The localization within vacuoles was established by the fact that the ingested zymosan was stained (Fig. 1). After more than 15 min, there was progressive deposition of formazan in some cells around the ingested particles and a hazy veil of dye was sometimes observed to radiate from the vacuole throughout the cytoplasm and over the nucleus. Zymosan particles to which NBT was bound were stained blue after they were ingested by normal cells. CGD leukocytes ingested zymosan particles very readily, but failed to stain the ingested zymosan blue either in the presence of excess NBT or when zymosan-bound NBT was ingested (Fig. 2). On the other hand, the addition of alkaline sodium ascorbate to formalin vapor-fixed CGD cells which had ingested zymosan-bound NBT provoked light blue staining of the ingested particles.

Resting fresh normal neutrophils and eosinophils were not internally stained by NBT, although some of the cells had precipitates of blue formazan adherant to their outer membranes. A few normal monocytes were internally stained.

Internal punctate deposits of formazan were detected within normal resting leukocytes after they were either frozen sectioned or fixed with glutaraldehyde or formalin vapor and incubated in the presence of NBT and NADH (17).

Examination of fixed smears of leukocyte: zymosan: NBT incubates permitted quantitation of the number and type of cells with formazan-tinted zymosan particles in phagocytic vacuoles. Granulocytes frequently contained as many as four or five zymosan particles. Monocytes frequently contained no zymosan or only one or two particles. Within 5 min of incubation, nearly 100% of the normal phagocytizing neutrophils, eosinophils, or monocytes contained at least one blue-stained zymosan par-

ticle (Fig. 3). Phagocytizing CGD granulocytes and monocytes differed markedly from those of normal individuals. After 15 min of incubation of CGD cells there were no detectable formazan deposits within or around phagocytic vacuoles. Mixtures of equal numbers of normal and CGD cells revealed that 50% of the phagocytizing cells had at least one blue stained zymosan particle in 5 min. In two CGD patients, there was no detectable dye reduction for as long as 60 min. However, the three L brothers with CGD exhibited different findings. Within 15 min, there was no dye reduction but after 30 and 60 min of incubation, definite dye reduction was observed in phagocytic vacuoles. Similar studies were performed in female carriers. 50% of the phagocytizing leukocytes of female carrier D were found to contain blue zymosan particles. On the other hand, only 20% of the leukocytes of female carrier G, the mother of three boys who had died of chronic granulomatous disease (18), contained blue zymosan. Most interesting was female carrier L, the mother of the three L brothers who themselves had unusual dye reduction kinetics. Within 5 min, 40% rather than the normal 90% of her cells showed staining of ingested zymosan. Within 15 min and certainly within 30 min, nearly all of the phagocytic vacuoles in her cells were stained, and the preparation became indistinguishable from normal. The quantitative dye test helped to identify her as a carrier. Her cells

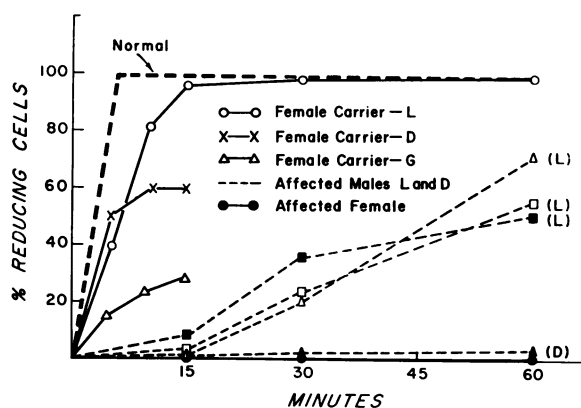


FIGURE 3 NBT reduction in phagocytic vacuoles of normal, CGD, and CGD carrier leukocytes after incubation with NBT zymosan. At least one hundred cells containing zymosan were counted and the cell was considered a "reducing cell" if at least one ingested zymosan was stained. The mean values found in five normal subjects are signified by the heavy interrupted line.

FIGURE 2 Nearly simultaneous phase (left) and bright field (right) photomicrographs of CGD neutrophil (a), two eosinophils and neutrophil (b), two neutrophils and monocyte (c), and two monocytes (d) 20 min after incubation with zymosan and NBT on a glass slide under a cover slip. Ingestion is normal but no dye reduction is observed within any of the cells. A zymosan particle with adherant eosinophil granules has broken away from the lower eosinophil in b.



reduced  $41 \mu\text{g}$  NBT/ $1.25 \times 10^7$  cells per 15 min, the normal range being  $52\text{--}88 \mu\text{g}$  NBT reduced.

*"NBT reductase" activity in cell sonicates.* Despite the fact that dye reduction during particle ingestion was impaired in CGD and in CGD female carrier cells, total cyanide insensitive "NBT reductase" activity with either NADH or NADPH as precursor was normal in CGD and carrier cell sonicates (Table I).

*Vacuole formation and degranulation.* Araldite sections stained with toluidine blue revealed that the phagocytic vacuoles in CGD tended to be considerably smaller than the vacuoles present in normal leukocytes (Fig. 4). This observation, previously made by Quie, White, Holmes, and Good (9) and by Andersen, Koch, Vejls-gaard, and Wilken-Jenses (19) was a variable phenomenon from cell to cell and also depended to a large extent upon the plane of section. But, in general, the large phagocytic vacuoles which often completely distorted normal leukocytes were not observed in the CGD cells. Electron micrographs of CGD and normal cells failed to demonstrate any obvious differences in granule

distribution in and around the phagocytic vacuoles. Actually, this technique revealed so much variation in the extent of "degranulation" among different normal phagocytizing cells, after incubation times which varied from 15 min to 2 hr, that a quantitative morphologic difference between normal and CGD cells would be nearly impossible to define.

*Rates of release of alkaline phosphatase and peroxidase.* Figs. 5 and 6 provide data on the rate of release of stainable alkaline phosphatase and peroxidase activities from normal cells and patients' cells by the scoring method described above. In only one CGD patient was there apparent delay in the release of alkaline phosphatase. The remaining curves fell within the range observed in five normal subjects. Peroxidase activity was released from CGD cells but the rate of release appeared to be somewhat slower than that observed in normals. On the other hand, it must be emphasized that this scoring technique, especially with regard to peroxidase activity, was subject to misinterpretation. Inspection of resting CGD leukocytes stained for peroxidase activity

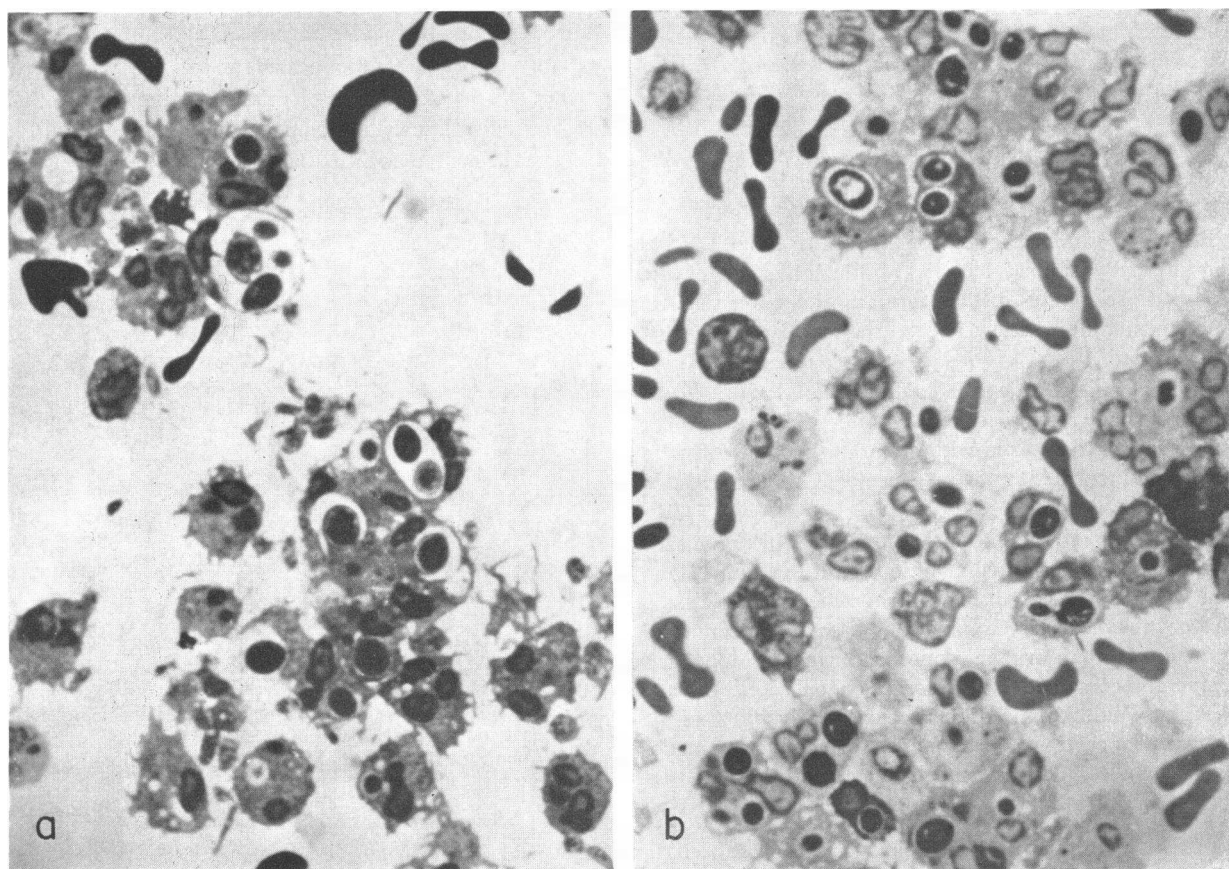


FIGURE 4 Thick Araldite sections of glutaraldehyde:osmium fixed normal (a) and CGD (b) leukocytes after 15 min incubation with zymosan. Note large distorting phagocytic vacuoles in normal cells and smaller vacuoles in CGD cells.

revealed that such cells were much more densely stained than were normal cells (Fig. 7). This may have been due to several factors including greater substrate permeability in CGD cells or the fact that the population of circulating CGD granulocytes may be younger and, therefore, richer in peroxidase than the more mature granulocytes of normal individuals. In any case, the more intense staining reaction led to higher histochemical scores at all intervals of incubation of CGD cells. Therefore, the rate of decline of peroxidase only *appeared* to decrease more slowly in CGD cells during phagocytosis. Despite this source of confusion, all of the patients exhibited loss of peroxidase activity during ingestion and only two patients demonstrated a definite deviation from normal. The others lost peroxidase activity normally or only slightly slower than did the cells of the five normal subjects.

## DISCUSSION

NBT reduction by phagocytizing normal leukocytes and absence of this reaction in CGD cells was first observed as a result of inquiries into the metabolism of CGD cells. The abnormality of dye reduction was initially ascribed to deficient NADH oxidase activity (5). The present studies were planned to extend our knowledge of the NBT response and were primarily designed to define the intracellular loci of NBT reduction, as well as to examine the possibility that the CGD metabolic defect might be present in several different blood cells.

The results show that NBT reduction is prominent only within the phagocytic vacuoles of normal neutrophils, eosinophils, and monocytes. This reaction is defective in all three phagocytic cells of individuals with CGD. The involvement of monocytes might have been

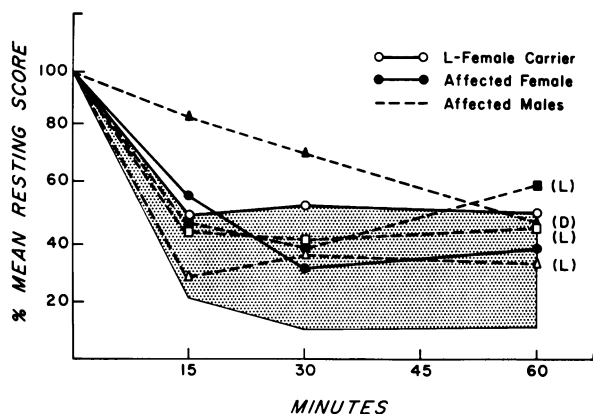


FIGURE 5 Rate of release of alkaline phosphatase activity from the phagocytes of five normal individuals (ranged in shaded area) and CGD patients and carriers during a 1 hr incubation with zymosan. The mean score of 100 ingesting cells was established at each time period and related to the mean resting score before ingestion had begun.

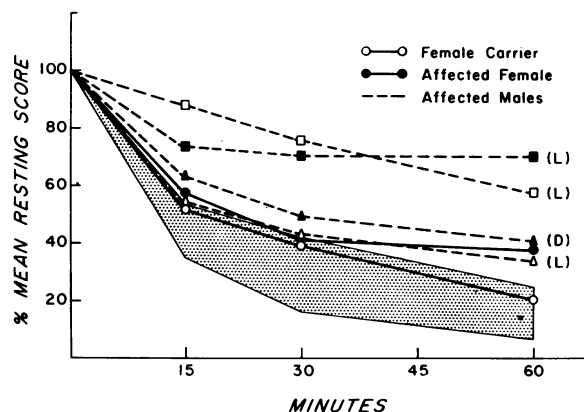


FIGURE 6 Rate of release of peroxidase activity. See legend to Fig. 5.

predicted from the early studies of CGD tissue histiocytes by Landing and Shirkey (20) and by the more recent studies of the same cells by Symchych, Wanstrup, and Andersen (21). In the past year Davis, Huber, Douglas, and Fudenberg (22) and Good et al. (23) have presented findings which suggest that CGD monocytes may have defective bactericidal function as well.

Although it is clear that the NBT reaction is only demonstrable in phagocytic vacuoles, similar redox reactions may occur in other parts of the cell to which the dye has insufficient access. Pearce (24) emphasizes that oxidized (yellow) NBT is positively charged and, therefore, it penetrates the membranes of fresh cells very poorly. In the reduced (blue formazan) state, the dye is insoluble. Our studies provide evidence that NBT does not enter fresh neutrophils or eosinophils at all unless it is swept into their phagocytic vacuoles by the ingested particle to which it is bound or in the fluid immediately surrounding the particle (25).<sup>8</sup> The dye penetrates fresh monocytes somewhat more readily.

The zymosan:leukocyte:NBT system described in this report is fairly simple and convenient. It seems to permit highly reliable detection of CGD patients, but the findings in female carrier L emphasize the importance of the quantitative test (5) in the diagnosis of the carrier state. It appears that X-inactivation and resultant mosaicism (28) is expressed in a highly variable manner in CGD with the result that in this system carriers such as Mrs. G seem quite deficient and Mrs. L virtually normal. The importance of standardizing the incubation time is emphasized by the results in the three L brothers, many of whose leukocytes did contain reduced NBT within phagocytic vacuoles when the in-

<sup>8</sup> Irregular penetration of resting cells by NBT may account for recently described false negatives and positives in simplified cytologic tests for CGD (26, 27).

cubation was prolonged. (The clinical state of these brothers is not particularly benign nor do their cells contain more NADH oxidase activity than the cells of male patient D.)

The failure of CGD cell phagocytic vacuoles to support NBT reduction is a particularly challenging problem because the three components which provoke dye reduction are present in CGD cells. CGD cell sonicates contain normal amounts of "NBT reductase," an enzyme system(s) capable of catalyzing the reduction of NBT in the presence of pyridine nucleotide. NBT enters the phagocytic vacuole of the CGD cell bound to or closely associated with the ingested zymosan, and the cell is capable of providing reduced pyridine nucleotide through glycolysis (5, 11, 29). A possible explanation for the absence of dye reduction might be that "NBT reductase" activity, though present in the whole cell, is

deficient within the phagocytic vacuole of the CGD cell. Deficiency of enzyme activity within the phagocytic vacuole might be due to an error of degranulation. In fact, the pathogenesis of CGD has been ascribed to defective degranulation by Quie and his coworkers (9). This theory is based in part upon White's observations (9) of diminished vacuole size in CGD cells which we and other investigators (19) have confirmed. The concept is not supported, however, by the histochemical studies reported here or by recently described histochemical analyses of Kauder, Kahle, Moreno, and Partin (30) and of Mandel and Hook (31). Admittedly, histochemical studies or routine electron micrographic analyses of degranulation provide very rough estimates, and the former are plagued by artifacts such as the differences in the staining characteristics of peroxidase activity in CGD cells described above. In this regard,

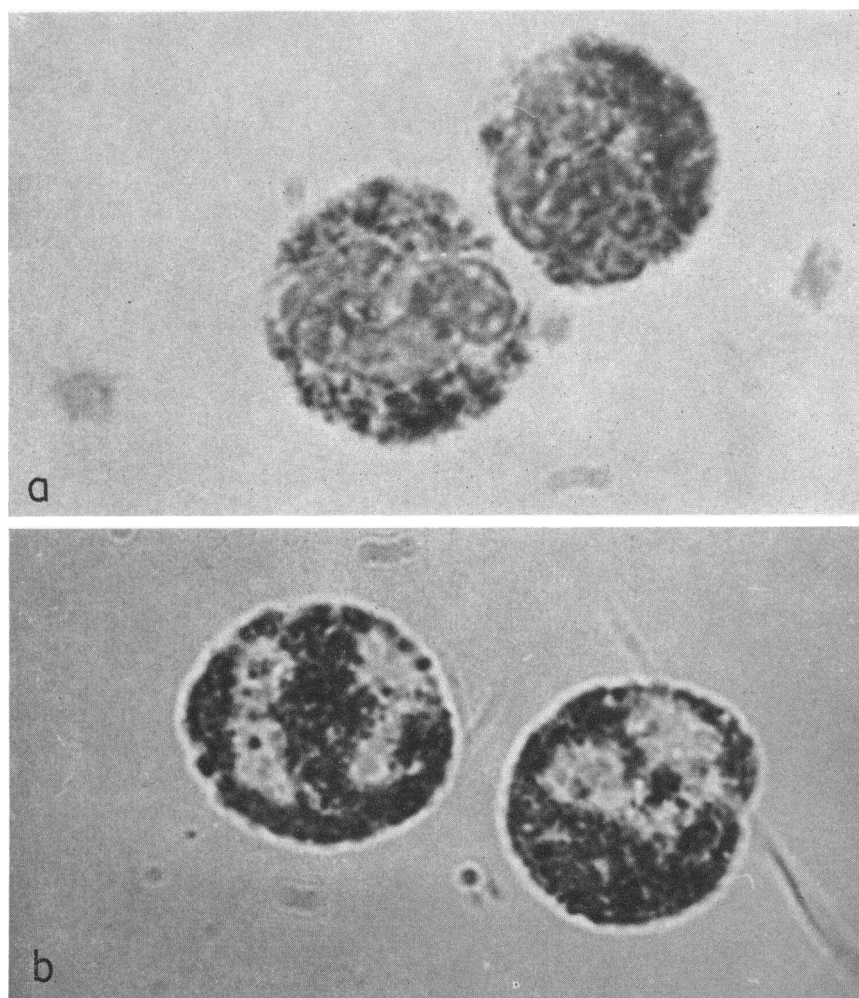


FIGURE 7 Peroxidase stain of resting normal (a) and CGD (b) neutrophils. Note the more intense stain in the CGD cells.



TABLE I  
NADH-NBT Reductase of Sonicates of Whole Cells\*

Subject	NBT reduced  μg/30 min per mg sonicate
Male—CGD	58.2
Male—CGD	66.6
Male—CGD	60.0
Female carrier	67.6
Control	78.0
Control	57.6
Control	62.0

\* The values found when NADPH was utilized in place of NADH were essentially identical.

the studies of Baehner, Karnovsky, and Karnovsky (32) are of particular importance since these workers utilized objective measurements of enzyme release and provided evidence that CGD cells degranulate perfectly normally.

Of course, it is entirely possible that only a small fraction of total leukocyte "NBT reductase" activity contributes to NBT reduction in phagocytic vacuoles and this small but critical fraction could be deficient in CGD. NADH oxidase activity, a system which can account for most of the oxygen consumption and some of the bactericidal activity of normal human leukocytes, is deficient in CGD cells (3). As previously suggested (5) this system might also qualify as the critical missing factor which results in the failure of NBT reduction in CGD phagocytic vacuoles. Evaluation of this theory awaits further clarification of the intricacies of the respiratory response to phagocytosis, studies in which the CGD cell will play a vital role.

#### ACKNOWLEDGMENTS

The authors are grateful to their colleagues who helped to make this work possible. Dr. Jean-Paul Revel and Dr. Elizabeth Hay of the Department of Anatomy and Dr. Morris Karnovsky of the Department of Pathology, Harvard Medical School provided laboratory space, instructions in electron micrographic techniques, and stimulating discussions. Dr. Arnold Weinberg, Department of Medicine, Massachusetts General Hospital and Harvard Medical School, made available the clinical studies and the blood of female carrier G. Dr. John M. Craig, Department of Pathology, Boston Hospital for Women and Harvard Medical School, made possible the studies of the NBT reaction in frozen sections of leukocytes. Finally, Dr. Manfred L. Karnovsky of the Department of Biological Chemistry, Harvard Medical School, gave freely of his advice, laboratory methods, and invaluable criticism.

This work was supported by U. S. Public Health Service Grants A1 08173, GM 00451, and T1 AM 05581 and by a grant from the John A. Hartford Foundation. Dr. Nathan is the recipient of U. S. Public Health Service Research Career Development Award 5 KO3-AM35371. Some of these clinical studies were performed in a clinical research center at the

Children's Hospital Medical Center supported by U. S. Public Health Service Grant FR 00128.

#### REFERENCES

1. Karnovsky, M. L. 1962. Metabolic basis of phagocytic activity. *Physiol. Rev.* **42**: 143.
2. Cagan, R. H., and M. L. Karnovsky. 1964. Enzymatic basis of the respiratory stimulation during phagocytosis. *Nature (London)*. **204**: 255.
3. Baehner, R. L., and M. L. Karnovsky. 1968. Deficiency of reduced nicotinamide-adenine dinucleotide oxidase in chronic granulomatous disease. *Science (Washington)*. **162**: 1277.
4. Baehner, R. L., and D. G. Nathan. 1966. Deficient glucose oxidation in intact leukocytes of chronic granulomatous disease. *Blood*. **28**: 1010.
5. Baehner, R. L., and D. G. Nathan. 1967. Leukocyte oxidase: defective activity in chronic granulomatous disease. *Science (Washington)*. **155**: 835.
6. Windhorst, D. B., B. Holmes, and R. A. Good. 1967. A newly defined X-linked trait in man with demonstration of the Lyon effect in carrier females. *Lancet*. **1**: 737.
7. Baehner, R. L., and D. G. Nathan. 1968. Quantitative nitroblue tetrazolium test in chronic granulomatous disease. *N. Engl. J. Med.* **278**: 971.
8. Holmes, B., P. G. Quie, D. B. Windhorst, and R. A. Good. 1966. Fatal granulomatous disease of childhood. An inborn abnormality of phagocytic function. *Lancet*. **1**: 1225.
9. Quie, P. G., J. G. White, B. Holmes, and R. A. Good. 1967. In vitro bactericidal capacity of human polymorphonuclear leukocytes: diminished activity in chronic granulomatous disease of childhood. *J. Clin. Invest.* **46**: 668.
10. MacFarlane, P. S., A. L. Speirs, and R. G. Sommerville. 1967. Fatal granulomatous disease of childhood and benign lymphocytic infiltration of the skin (congenital dysphagocytosis). *Lancet*. **1**: 408.
11. Holmes, B., A. R. Page, and R. A. Good. 1967. Studies of metabolic activity of leukocytes from patients with a genetic abnormality of phagocytic function. *J. Clin. Invest.* **46**: 1422.
12. Hirsch, J. G. 1962. Cinemicrophotographic observations on granule lysis in polymorphonuclear leukocytes during phagocytosis. *J. Exp. Med.* **116**: 827.
13. Cohn, Z. A., and E. Wiener. 1963. The particulate hydrolases of macrophages. II. Biochemical and morphological response to particle ingestion. *J. Exp. Med.* **118**: 1009.
14. Zucker-Franklin, D., and J. G. Hirsch. 1964. Electron microscope studies on the degranulation of rabbit peritoneal leukocytes during phagocytosis. *J. Exp. Med.* **120**: 569.
15. Kaplow, L. S. 1965. Simplified myeloperoxidase stain using benzidine dihydrochloride. *Blood*. **26**: 215.
16. Kaplow, L. S. 1963. Cytochemistry of leukocyte alkaline phosphatase: use of complex naphthol as phosphates in AZO dye coupling technics. *Amer. J. Clin. Pathol.* **39**: 439.
17. Rozenszajn, L., and D. Shoham. 1967. The demonstration of dehydrogenases and diaphorases in cells of peripheral blood and bone marrow. *Blood*. **29**: 737.
18. Janeway, C. A., J. Craig, M. Davidson, W. Downey, D. Gitlin, and J. C. Sullivan. 1954. Hypergammaglobulinemia associated with severe recurrent and chronic nonspecific infection. *Amer. J. Dis. Child.* **88**: 388.

19. Andersen, V., C. Koch, R. Vejlsgaard, and K. Wilken-Jenses. 1968. Fatal granulomatous disease. *Acta Paediat. Scand.* **57**: 110.
20. Landing, B. H., and H. S. Shirkey. 1957. Syndrome of recurrent infection and infiltration of viscera by pigmented lipid histiocytes. *Pediatrics.* **20**: 431.
21. Symchych, P. S., J. Wanstrup, and V. Andersen. 1968. Chronic granulomatous disease of childhood. A morphologic study. *Acta Pathol. Microbiol.* **74**: 179.
22. Davis, W. C., H. Huber, S. D. Douglas, and H. H. Fudenberg. 1968. A defect in circulating mononuclear phagocytes in chronic granulomatous disease of childhood. *J. Immunol.* **101**: 1093.
23. Good, R. A., P. G. Quie, D. B. Windhorst, A. R. Page, G. E. Rodey, J. White, J. J. Wolfson, and B. H. Holmes. 1968. Fatal (chronic) granulomatous disease of childhood: a hereditary defect of leukocyte function. *Seminars Hematol.* **5**: 215.
24. Pearse, A. G. E. 1960. *Histochemistry, Theoretical and Applied.* Little, Brown & Co., Boston. 2nd edition. 538.
25. Berger, R. R., and M. L. Karnovsky. 1966. Biochemical basis of phagocytosis. V. Effect of phagocytosis on cellular uptake of extracellular fluid, and on the intracellular pool of L- $\alpha$ -glycerophosphate. *Fed. Proc.* **25**: 840.
26. Park, B. H., S. M. Fikrig, and E. M. Smithwick. 1968. Infection and nitroblue-tetrazolium reduction by neutrophils. *Lancet.* **7**: 532.
27. Park, B. H., B. M. Holmes, G. E. Rodey, and R. A. Good. 1969. Nitroblue-tetrazolium test in children with fatal granulomatous disease and newborn infants. *Lancet.* **1**: 157.
28. Lyon, M. F. 1962. Sex chromatin and gene action in the mammalian X-chromosome. *Amer. J. Hum. Genet.* **14**: 135.
29. Holmes, B., and A. R. Page. 1966. Studies on the metabolic activity of leukocytes from patients with a genetic abnormality of phagocytic function. *J. Cell. Biol.* **31**: 48a. (Abstr.)
30. Kauder, E., L. L. Kahle, H. Moreno, and J. C. Partin. 1968. Leukocyte degranulation and vacuole formation in patients with chronic granulomatous disease of childhood. *J. Clin. Invest.* **47**: 1753.
31. Mandell, G., and E. Hook. 1968. Studies of the leukocyte defect in chronic granulomatous disease of childhood. *Clin. Res.* **16**: 332. (Abstr.)
32. Baehner, R. L., M. J. Karnovsky, and M. L. Karnovsky. 1969. Degranulation of leukocytes in chronic granulomatous disease. *J. Clin. Invest.* **48**: 187.