

**The effect of prednisolone on gastric mucosal histology, gastric secretion, and vitamin B 12 absorption in patients with pernicious anemia.**

G H Jeffries, ... , J E Todd, M H Sleisenger

*J Clin Invest.* 1966;45(5):803-812. <https://doi.org/10.1172/JCI105395>.

Research Article

**Find the latest version:**

<https://jci.me/105395/pdf>



## The Effect of Prednisolone on Gastric Mucosal Histology, Gastric Secretion, and Vitamin B<sub>12</sub> Absorption in Patients with Pernicious Anemia \*

GRAHAM H. JEFFRIES,† JEAN E. TODD, AND MARVIN H. SLEISENGER

(From the Division of Gastroenterology, Department of Medicine, Cornell University Medical College, and the Laboratory of Surgical Pathology, New York Hospital, New York, N. Y.)

The effect of corticosteroids on the gastric mucosa in patients with pernicious anemia is of particular interest in view of the possibility that atrophic gastritis, the primary pathologic lesion in pernicious anemia, may result from destruction of gastric glands by an autoimmune process (1).

The first observation which suggested that corticosteroids might enhance vitamin B<sub>12</sub> absorption in patients with pernicious anemia was made by Doig, Girdwood, Duthie, and Knox (2). Three of four patients treated with prednisolone exhibited a hematologic response with a reticulocytosis, an increase in hemoglobin and red blood cell count, and correction of the megaloblastic to normoblastic erythropoiesis. In several studies that were stimulated by this observation, it was suggested alternatively that prednisolone enhanced vitamin B<sub>12</sub> absorption in the absence of intrinsic factor (3) and that prednisolone stimulated the gastric secretion of intrinsic factor in these patients (4, 5). Kristensen and Friis (6) proved that the latter mechanism was responsible for the increase in vitamin B<sub>12</sub> absorption during corticosteroid therapy. They found that gastric juice collected from pernicious anemia patients with enhanced vitamin B<sub>12</sub> absorption during therapy with prednisolone contained intrinsic factor on *in vivo* assay.

\* Submitted for publication September 10, 1965; accepted February 8, 1966.

Supported in part by research grant CA 09386 from the National Cancer Institute and grant FR 47 from the Division of General Medical Sciences, National Institutes of Health, and in part by a grant from the John A. Hartford Foundation.

† Recipient of Research Career Development Award 5 K3-AM-14,153 from the U. S. Public Health Service.

Address requests for reprints to Dr. Graham H. Jeffries, New York Hospital, 525 E. 68th St., New York, N. Y. 10021.

There have been no studies correlating gastric secretion with gastric mucosal histology during corticosteroid therapy in patients with pernicious anemia. In the present investigation, gastric mucosal histology, gastric secretion of acid and intrinsic factor, vitamin B<sub>12</sub> absorption, and the titers of circulating antibodies to gastric parietal cell cytoplasm and intrinsic factor were studied before and during a period of prednisolone therapy in patients with pernicious anemia or atrophic gastritis.

In response to prednisolone therapy, parietal and chief cells reappeared in the gastric mucosa of three patients with pernicious anemia, in one patient with latent pernicious anemia, and in a patient with atrophic gastritis. Intrinsic factor was present in the gastric juice of each of these patients during steroid therapy, and acid was detected in stimulated secretion in three patients. There was an improvement in vitamin B<sub>12</sub> absorption in four of the patients with pernicious anemia and in the patient with latent pernicious anemia. The patients who responded to prednisolone therapy were those whose sera exhibited the highest titers of parietal cell antibody. The response of one patient (No. 1) with pernicious anemia to prednisolone therapy has been reported previously (7).

### Methods

**Patients.** Studies were carried out on six patients with pernicious anemia who were in hematologic remission, one patient with latent pernicious anemia, and one patient with atrophic gastritis without pernicious anemia. The pertinent clinical and laboratory data on these patients are summarized in Table I.

The criteria upon which the diagnosis of pernicious anemia was based were a megaloblastic anemia that responded to vitamin B<sub>12</sub> therapy, a subnormal Schilling test corrected with hog intrinsic factor, and an absence of acid and intrinsic factor in gastric juice collected

TABLE I  
Clinical and laboratory data

Patient no.	Sex	Age	Duration of anemia	Diagnostic criteria						Associated disease
				Megalo-blastic anemia	Achlor-hydrria	Schilling test*		Gastric antibodies		
						B <sub>12</sub>	B <sub>12</sub> -I.F.	Parietal cell	Intrinsic factor	
		<i>years</i>	<i>years</i>			%	%			
1	F	75	3	+	+	0.0	7.0	1/128	+	None
2	F	56	4	+	+	0.3	24.0	1/64	0	Hashimoto's thyroiditis, subacute combined degeneration
3	F	66	3	+	+	0.7	17.4	1/128	0	None
4	M	54	6	+	+	0.6	13.0	1/32	0	Postnecrotic cirrhosis
5	M	71	1	+	+	1.5	17.1	1/32	0	None
6	M	77	25	+	+	2.9	19.8	1/32	0	Chronic lymphatic leukemia
7†	F	46	0	0	+	3.4		1/512	+	Primary biliary cirrhosis
8‡	F	52	0	0	+	20.5		1/512	0	Hashimoto's thyroiditis, rheumatoid arthritis mitral stenosis

\* Forty-eight-hour urinary excretion of an oral dose of 0.5  $\mu$ g of vitamin B<sub>12</sub>-<sup>60</sup>Co. B<sub>12</sub> = Schilling test with vitamin B<sub>12</sub> alone; B<sub>12</sub>-I.F. = Schilling test with vitamin B<sub>12</sub> and hog intrinsic factor.

† Patient with latent pernicious anemia; see text for explanation.

‡ Patient with atrophic gastritis without pernicious anemia.

during histamine (0.04 mg per kg, subcutaneously) or betazole hydrochloride<sup>1</sup> (100 mg, subcutaneously) stimulation. The six patients with pernicious anemia had been treated with injections of vitamin B<sub>12</sub> for periods of 1 to 10 years; one patient (No. 6) had initially received injections of liver extract.

The patient with latent pernicious anemia (No. 7) had never been anemic, but secreted no acid or intrinsic factor during betazole hydrochloride stimulation and had a low serum concentration of vitamin B<sub>12</sub> (166 picograms per ml) and an abnormal Schilling test; a diagnosis of pernicious anemia had been suspected because both parietal cell and intrinsic factor antibodies had been detected in her serum. The patient with atrophic gastritis (No. 8) was achlorhydric but secreted intrinsic factor and had a normal Schilling test.

**Gastric secretory studies.** Gastric juice was collected by intermittent hand suction through a nasogastric tube after a subcutaneous injection of betazole hydrochloride (100 mg). The pH of the gastric juices from fasting and stimulated patients was measured with a Beckman pH meter using a glass electrode, and the acid content was measured by titrating to pH 7.0 (phenol red indicator) with 0.1 N sodium hydroxide. Intrinsic factor was assayed by an *in vitro* method using an antibody to intrinsic factor (8).

**Gastric mucosal biopsy.** Gastric mucosal biopsies were obtained from the body and fundus of the stomach through a hydraulic multiple biopsy tube positioned fluoroscopically (9). Forty-eight biopsy specimens were obtained for light microscopic study, twenty before prednisolone therapy and twenty-eight during therapy. Each biopsy

specimen was mounted on filter paper, fixed in formalin, embedded in paraffin, and sectioned at 6  $\mu$  at right angles to the surface of the mucosa; the serial sections were stained with hematoxylin and eosin. Coded slides were prepared so that the microscopist was unaware of the patient's name or prednisolone therapy. The type of cell present in the gastric glands and the extent of intestinal metaplasia were assessed; in particular, the presence or absence of chief and parietal cells was noted.

**Vitamin B<sub>12</sub> absorption.** A modification of the Schilling test was used (10). The 48-hour urinary excretion of a test dose of 0.2  $\mu$ g of <sup>60</sup>Co-labeled vitamin B<sub>12</sub> (B<sub>12</sub><sup>60</sup>-Co) was measured. In normal subjects more than 10% of the administered dose was excreted in the urine.

**Parietal cell and intrinsic factor antibody assays.** Sera obtained from each patient before and during the period of prednisolone therapy were stored at -20° C without added preservative. Parietal cell antibody titers were measured by an immunofluorescent technique with fresh-frozen sections of rat gastric mucosa and fluorescein-labeled antihuman  $\gamma$ G-globulin antiserum (11). Intrinsic factor antibody was assayed by the method of Jeffries, Hoskins, and Sleisenger (12).

**Prednisolone therapy.** Each patient was initially hospitalized for assessment. Analyses of gastric secretion, gastric biopsies, and vitamin B<sub>12</sub> absorption tests were performed, and serum was obtained for antibody assays. Prednisolone in doses varying from 10 to 40 mg was then given daily by mouth for periods of 2 to 8 months, and the above studies were repeated during the period of therapy. Patients with pernicious anemia continued to receive monthly injections of vitamin B<sub>12</sub> (100  $\mu$ g, intramuscularly) during the period of steroid therapy.

<sup>1</sup> Histalog, Eli Lilly, Indianapolis, Ind.

TABLE II  
*The effect of prednisolone on gastric secretion of acid and intrinsic factor*

Patient no.	Secretion before steroid therapy*				Secretion during steroid therapy*			
	Acid		Intrinsic factor†	Daily dose and duration of steroid therapy		Acid		Intrinsic factor†
	pH	mEq/hr		mg	weeks	pH	mEq/hr	
1	7.0	Nil	Nil	20	8	2.0	0.9	Present
				15	8			
				10	8			
2	7.0	Nil	Nil	20	19	5.8	0.1	Present
3	7.0	Nil	Nil	15	15	7.0	Nil	Present
4	7.5	Nil	Nil	15	27	7.5	Nil	Nil
5	7.5	Nil	Nil	15	4	6.8	Nil	Nil
				15	16			
				20	11			
6	7.3	Nil	Nil	20	11	6.8	Nil	Nil
7	6.5	Nil	Nil	15	9	6.5	Nil	Present
8	6.0	Nil	Present	40	8	2.9	0.3	Present

\* Gastric secretion after betazole hydrochloride injection (100 mg, subcutaneously).  
† Assayed by the method of Jeffries and Slesinger (8).

**Results**

*The effect of prednisolone on gastric secretion of acid and intrinsic factor.* Acid and intrinsic factor secretion in response to betazole hydrochloride stimulation is indicated in Table II. None of the patients secreted acid before prednisolone was given, and intrinsic factor could be detected in the gastric juice only in the patient with atrophic gastritis (Patient 8) who absorbed vitamin B<sub>12</sub> normally.

During prednisolone therapy, two patients with pernicious anemia (No. 1 and 2) and the patient with atrophic gastritis (No. 8) secreted both acid and intrinsic factor. Intrinsic factor alone was detected in the gastric juice from one patient with pernicious anemia (No. 3) and from the patient with latent pernicious anemia (No. 7). Schilling tests indicated an enhanced absorption of vitamin B<sub>12</sub> in these patients with manifest or latent pernicious anemia, and in each patient parietal cells were identified in the gastric mucosa during steroid therapy.

In three patients with pernicious anemia neither acid nor intrinsic factor could be detected in the gastric juice during prednisolone therapy (No. 4, 5, and 6).

*The effect of prednisolone on vitamin B<sub>12</sub> absorption.* The results of Schilling tests performed before and during prednisolone therapy are shown in Table III. During therapy, there was an increase in the urinary excretion of vitamin B<sub>12</sub> in four of the six patients with pernicious anemia

and in the patient with latent pernicious anemia. The Schilling test remained normal in the patient with atrophic gastritis (No. 8). With one exception (Patient 4) the improved absorption of vitamin B<sub>12</sub> corresponded to the presence of intrinsic factor in stimulated gastric juice; in one patient no intrinsic factor could be detected in gastric juice although vitamin B<sub>12</sub> absorption was enhanced.

TABLE III  
*The effect of prednisolone on the urinary excretion of vitamin B<sub>12</sub> (Schilling test)*

Patient no.	Schilling tests* before steroid therapy	Daily dose and duration of steroid therapy		Schilling tests* during steroid therapy
		mg	weeks	
1	0.0, 0.0, 0.9.	20	2	7.3
		20	8	21.0
		20	8	22.1
		15	8	
		10	8	
2	1.1	20	12	14.8
3	0.4	15	4	6.4
		15	15	7.9
4	1.0, 2.7	30	4	10.6
		15	12	9.4
		15	27	5.0
5	4.3, 2.3, 0.5	15	4	5.7
		15	16	3.5
6	2.0, 2.9	20	11	1.2
		20	15	1.6
7	5.4, 3.4	15	9	21.8
8	15.1	40	8	24.2

\* Schilling tests were performed with 0.2 µg of B<sub>12</sub>-<sup>60</sup>Co without intrinsic factor. The 48-hour urinary excretion of radioactivity is expressed as a percentage of the administered dose (normal excretion exceeds 10%).

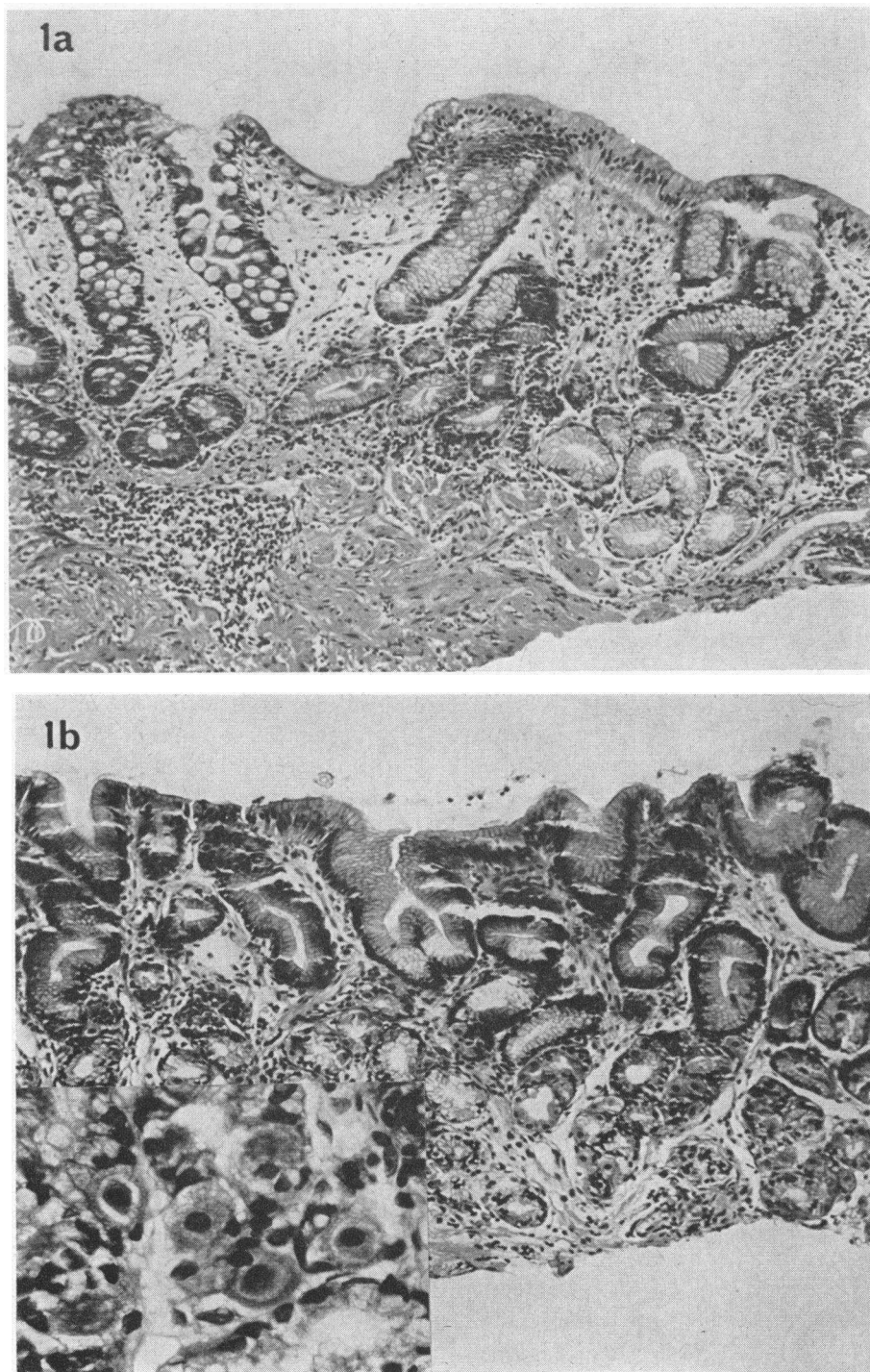


FIG. 1. GASTRIC MUCOSAL BIOPSIES FROM PATIENT 2 WITH PERNICIOUS ANEMIA. *a*) Before prednisolone therapy;  $\times 130$ ; there is mucosal atrophy with partial intestinal metaplasia. *b*) During prednisolone therapy;  $\times 130$ ; insert  $\times 500$ . Parietal and chief cells are present in the gastric glands. This patient secreted both acid and intrinsic factor and had a normal Schilling test during prednisolone therapy.

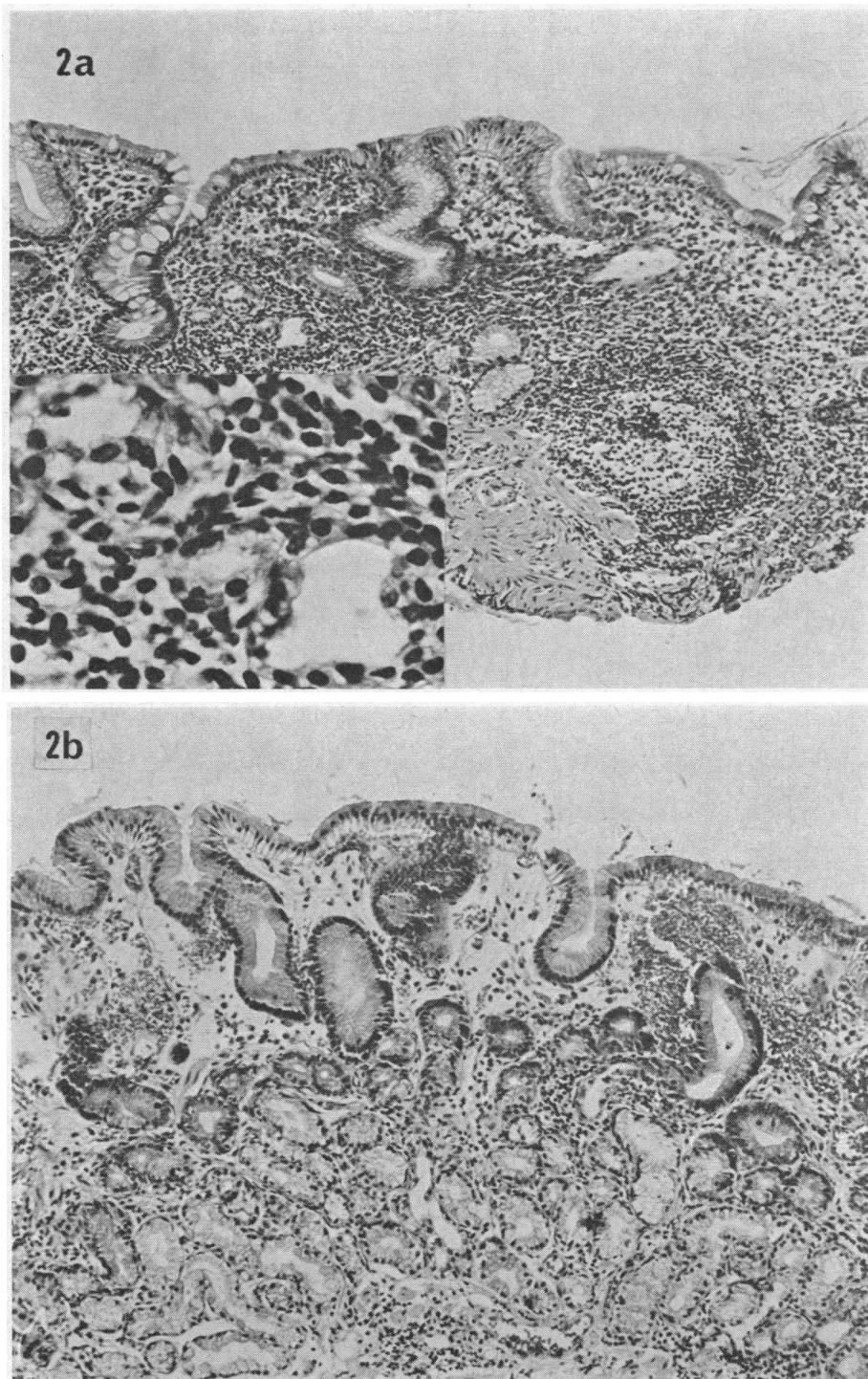


FIG. 2. GASTRIC MUCOSAL BIOPSIES FROM PATIENT 3 WITH PERNICIOUS ANEMIA. *a*) Before prednisolone therapy;  $\times 130$ ; insert  $\times 500$ . There is partial intestinal metaplasia; some of the atrophic gastric glands exhibit degenerative changes (insert). The lamina propria is heavily infiltrated with mononuclear cells. *b*) During prednisolone therapy;  $\times 130$ ; glandular acini lined by cuboidal undifferentiated and mucus-secreting cells and occasional parietal cells are present. There was an enhancement of vitamin B<sub>12</sub> absorption and secretion of intrinsic factor in the gastric juice during prednisolone therapy.



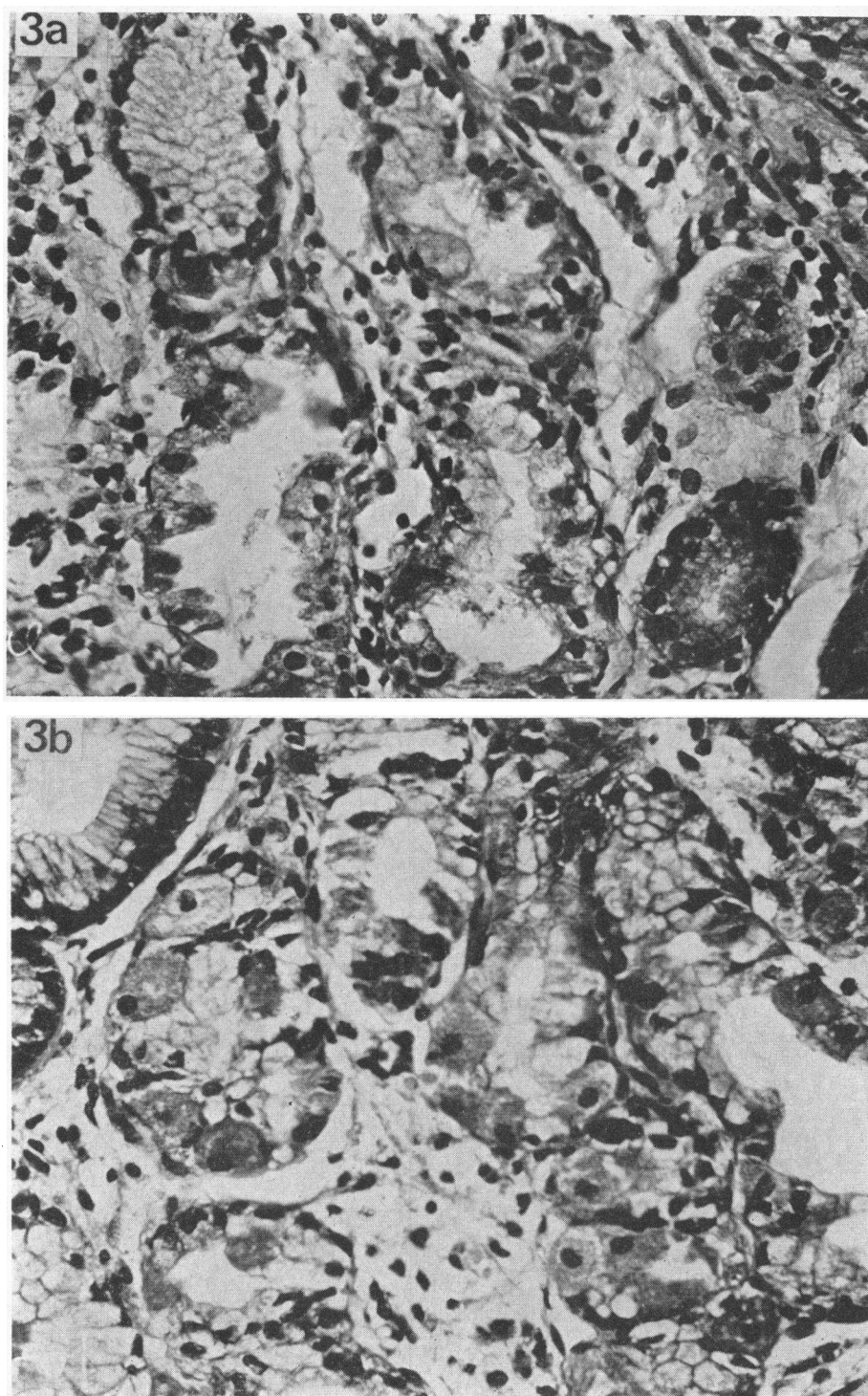


FIG. 3. GASTRIC MUCOSAL BIOPSIES FROM PATIENT 8 WITH ATROPHIC GASTRITIS. *a*) Before prednisolone therapy;  $\times 500$ ; the gastric glands are lined by degenerating cells; a few parietal cells are present in the mucosa. *b*) After prednisolone therapy;  $\times 500$ ; normal chief and parietal cells are present in the gastric glands.

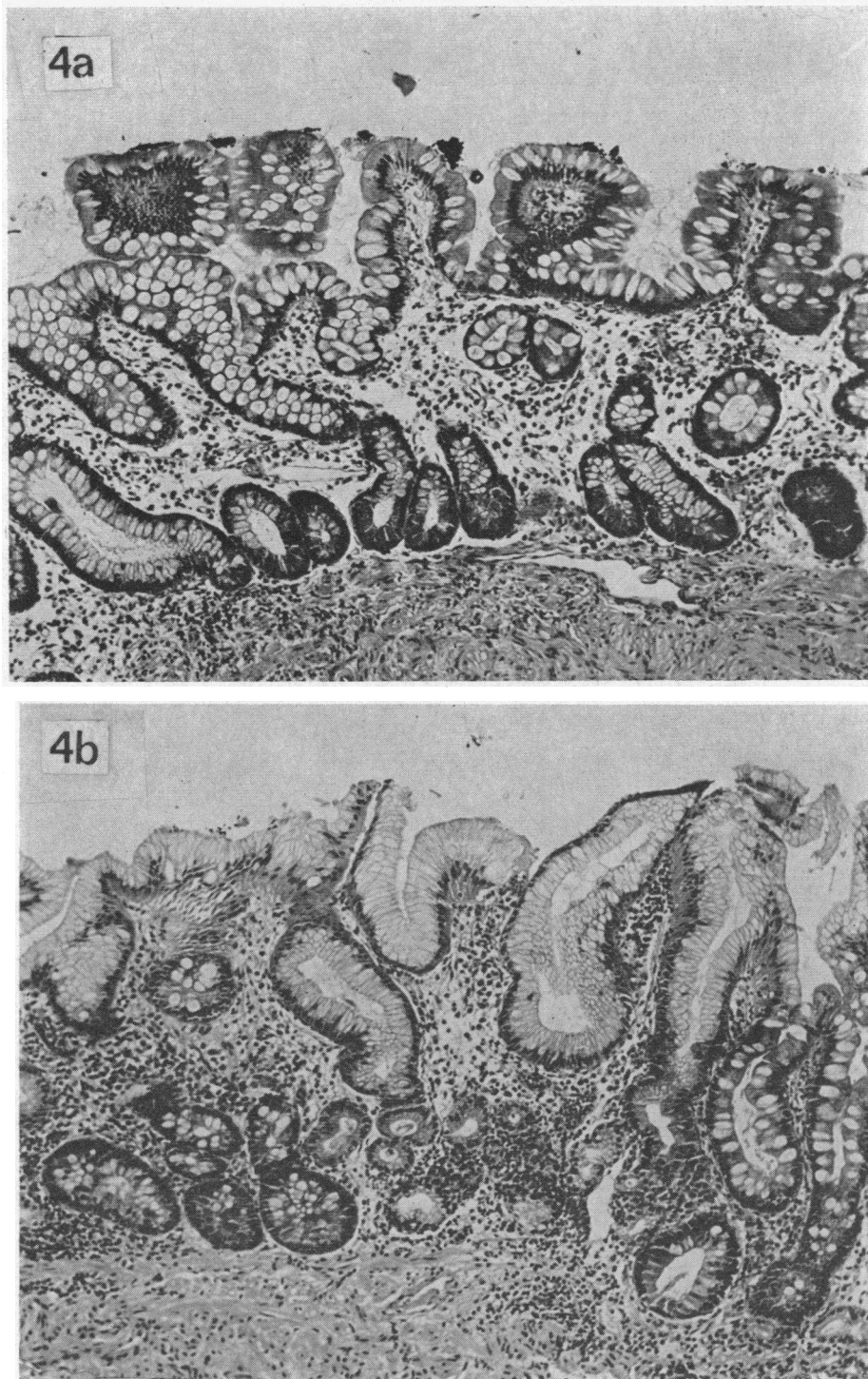


FIG. 4. GASTRIC MUCOSAL BIOPSIES FROM PATIENT 4 WITH PERNICIOUS ANEMIA. *a*) Before prednisolone therapy;  $\times 130$ ; there is complete intestinal metaplasia. *b*) During prednisolone therapy;  $\times 130$ ; there is partial intestinal metaplasia. No parietal cells are present in the gastric glands. No acid or intrinsic factor could be detected in this patient's gastric juice although there was an enhancement of vitamin B<sub>12</sub> absorption to subnormal levels.



*The effect of prednisolone on gastric mucosal histology.* The gastric mucosa was atrophic in each of the 20 biopsy specimens obtained before prednisolone administration. The residual gastric glands were usually formed by cuboidal mucous-secreting cells with basally compressed nuclei resembling pyloric gland cells (Figures 1a, 2a) or by undifferentiated cuboidal cells. Degenerating cells lined gland acini in several biopsy specimens (Figure 2a, insert; Figure 3a). A few parietal cells were identified in sections from one of five biopsy specimens obtained from one patient with pernicious anemia (No. 1, reference 7) and in one of the two biopsy specimens from the patient with atrophic gastritis (No. 8, Figure 3a); many of these cells in the latter biopsy appeared to be degenerating. Localized areas of intestinal metaplasia were present in many of the sections (Figures 1a, 2a); this metaplasia was more extensive in biopsies from three of the patients with pernicious anemia (No. 4, 5, and 6, Figure 4a). In each mucosal biopsy specimen the lamina propria was infiltrated with lymphocytes, plasma cells, and eosinophils, and in two biopsy specimens there was a lymphoid follicle (Figure 2a).

During prednisolone therapy, parietal cells were identified in each of the 15 biopsy specimens obtained from five patients (No. 1, 2, 3, 7, and 8). These cells were recognized by their eosinophilic staining and by their intracellular secretory canaliculi (Figures 1b, 2b, 3b). Gland acini containing more basophilic cells with granular cytoplasm (chief cells) were also present in these mucosae. Although both parietal and chief cells were present in gastric glands, the gastric mucosa did not recover its normal structure; the glandular compartment was shallow, and acini containing parietal and chief cells were separated by loose connective tissue that was still infiltrated by mononuclear cells. No parietal cells were seen in any of the biopsies from three patients with pernicious anemia (No. 4, 5, and 6). Extensive intestinal metaplasia was present in their gastric mucosa both before and during prednisolone therapy (Figure 4a,b).

*The effect of prednisolone on the titers of circulating antibody to gastric parietal cell cytoplasm and intrinsic factor.* Prednisolone, 10 to 30 mg daily, did not reduce the titer of parietal cell anti-

TABLE IV  
*The effect of prednisolone on the titers of gastric antibodies in sera*

Patient no.	Antibody titers before prednisolone therapy		Antibody titers after prednisolone therapy	
	Parietal cell*	Intrinsic factor†	Parietal cell*	Intrinsic factor†
1	1/128	18	1/128	8
2	1/64	0	1/64	0
3	1/128	0	1/128	0
4	1/32	0	1/32	0
5	1/32	0	1/32	0
6	1/32	0	1/32	0
7	1/512	3.4	1/512	0
8	1/512	0	1/64	0

\* The maximal serum dilution at which parietal cell immunofluorescence was detected.

† Millimicrograms of intrinsic factor-bound vitamin B<sub>12</sub> reacting with antibody in 1 ml of serum.

body in the sera of seven patients. In one patient (No. 8), however, who received 40 mg of prednisolone daily, there was a significant decrease in parietal cell antibody titer from 1/512 before therapy to 1/64 during therapy (Table IV). The titers of intrinsic factor antibody, present in sera from two patients (No. 1 and 7), decreased during prednisolone therapy.

Patients with the higher serum titers of parietal cell antibody were those who exhibited changes in gastric secretion, vitamin B<sub>12</sub> absorption, or gastric mucosal histology during prednisolone therapy.

## Discussion

Regardless of etiology, gastric mucosal atrophy characterized by an absence of parietal and chief cells in the gastric glands must result from a derangement of cell turnover in the mucosa. Either the capacity of the mucosa to regenerate gastric parietal and chief cells is reduced, or these cells or their precursors or both are destroyed at an increased rate. There is insufficient information relating to cell turnover in the glandular compartment of normal or atrophic human gastric mucosae to indicate which of these alternative mechanisms leads to mucosal atrophy in patients with pernicious anemia.

In the present study it has been shown that patients with pernicious anemia or atrophic gastritis may respond to prednisolone therapy. This response is characterized by an enhancement of vitamin B<sub>12</sub> absorption (3, 5, 6), secretion of acid and intrinsic factor (6), and the reappearance of

parietal and chief cells in the previously atrophic gastric mucosa; the improvement in gastric secretory function is thus the result of parietal cell regeneration rather than a stimulation of residual parietal cells in the atrophic mucosa.

In three of the patients who responded to prednisolone therapy (No. 1, 2, and 8), the reappearance of parietal cells in the mucosa was accompanied by acid and intrinsic factor secretion. In two patients, however, parietal cells were demonstrated in mucosal biopsies, but stimulated gastric juices contained intrinsic factor without acid (No. 3 and 7). In these patients with a small parietal cell population, the analysis of stimulated gastric juice for acid may be an insensitive test for parietal cell secretion. Hydrogen ions may be actively reabsorbed by metaplastic intestinal epithelial cells in the gastric mucosa or may diffuse from the gastric lumen through the damaged mucosa (13).

It is evident from our study that atrophic gastritis in patients with pernicious anemia is not due to a loss of the mucosal potential to regenerate parietal and chief cells. The mechanism of the steroid effect remains uncertain; the regeneration of gastric glands during therapy may have been due to a potentiation of cell regeneration or an inhibition of cell destruction in the mucosa. Animal studies, however, suggest that the latter mechanism may be operative; in experimental animals, adrenalectomy increases mitotic activity (14, 15), whereas corticosteroid administration decreases cell division in the gastric mucosa (16, 17).

The hypothesis that gastric mucosal glands in the body and fundus are selectively destroyed by autoimmune processes and that parietal cell regeneration may result from the immunosuppressive action of prednisolone is unproven. Although parietal cell and intrinsic factor antibodies are usually associated with chronic atrophic gastritis or pernicious anemia (18), there is no evidence that these antibodies are cytotoxic to gastric parietal cells; the regeneration of parietal cells in prednisolone-treated patients who exhibited no decrease in the serum titer of parietal cell antibody is evidence to the contrary. It is of interest, however, that patients who responded to prednisolone therapy were those with higher titers of circulating parietal cell antibody. High titers of parietal cell antibody, persisting for many years

after the diagnosis of pernicious anemia has been established (11, 18), may reflect a continuing stimulation of antibody production by parietal cell antigen released from degenerating mucosal cells. The three patients who did not respond to prednisolone therapy had low titers of parietal cell antibody and exhibited extensive intestinal metaplasia in their gastric mucosal biopsies. Widespread intestinal metaplasia may not only limit the mucosal potential to regenerate parietal cells, but may also lower the titer of circulating parietal cell antibody by decreasing the turnover of parietal cells, parietal cell precursors, or both in the mucosa.

The changes in gastric secretion, vitamin B<sub>12</sub> absorption, and mucosal histology during prednisolone therapy cannot be attributed to a decrease in the titer of intrinsic factor antibody first demonstrated by Taylor (19). Two patients who responded to therapy exhibited a decrease in the titer of intrinsic factor antibody; this antibody was not present, however, in sera from the other patients who were studied.

The role of autoimmune mechanisms in the pathogenesis of atrophic gastritis and pernicious anemia may be clarified when cell regeneration has been studied in the glandular compartment of normal and atrophic gastric mucosae. The effects of corticosteroids on gastric mucosal histology in pernicious anemia must be correlated not only with autoimmune phenomena, but also with cell regeneration and destruction in the mucosa.

### Summary

The effects of prednisolone therapy on gastric mucosal histology, gastric secretion of acid and intrinsic factor, vitamin B<sub>12</sub> absorption, and the serum titers of antibody to intrinsic factor and gastric parietal cell cytoplasm were studied in six patients with pernicious anemia, one patient with latent pernicious anemia, and one patient with atrophic gastritis.

Prednisolone therapy enhanced vitamin B<sub>12</sub> absorption (as measured by the Schilling test) in four patients with pernicious anemia and in the patient with latent pernicious anemia; absorption remained normal in the patient with atrophic gastritis. In five patients (three with pernicious anemia, one with latent pernicious anemia, and one

with atrophic gastritis), gastric glands containing parietal and chief cells were identified in mucosal biopsies during the steroid therapy. The reappearance of parietal cells in the mucosa was associated with acid secretion in three patients and with intrinsic factor secretion detected by an *in vitro* assay technique in each of the five patients. The serum titers of parietal cell antibody remained constant in seven patients during steroid therapy; in one patient who received the highest daily dose of prednisolone (40 mg), the titer of this antibody decreased. There was a decrease in the titers of intrinsic factor antibody in two patients.

This study indicates that the atrophic gastric mucosa in patients with pernicious anemia may retain its potential to regenerate parietal cells—that atrophy is not due to a loss of regenerative potential. Regeneration was seen in patients with the higher titers of parietal cell antibody and did not occur in patients with low titers who also exhibited extensive intestinal metaplasia. It is suggested that persisting high titers of gastric parietal cell antibody in patients with pernicious anemia may be stimulated by the release of antigen from degenerating cells in atrophic gastric glands.

### Addendum

In a recent publication, Ardeman and Chanarin (20) confirmed the results of the present study. Seven of eight patients with pernicious anemia treated with 30 or 40 mg of prednisone daily for 3 to 5 weeks exhibited an improvement in vitamin B<sub>12</sub> absorption. Intrinsic factor secretion was increased in four of five patients, and acid was detected in gastric juice from two of seven patients. Parietal and chief cells were demonstrated in gastric mucosal biopsies from two patients. The authors observed that there was no relation between the response to steroids and the presence of intrinsic factor antibody in the patients' sera.

### Acknowledgments

We are grateful for the technical assistance provided by Miss Irene S. Margolis and Mr. Lloyd L. Benjamin.

### References

1. Taylor, K. B., I. M. Roitt, D. Doniach, K. G. Couchman, and C. Shapland. Autoimmune phenomena in pernicious anaemia: gastric antibodies. *Brit. Med. J.* 1962, 2, 1347.
2. Doig, A., R. H. Girdwood, J. J. R. Duthie, and J. D. E. Knox. Response of megaloblastic anaemia to prednisolone. *Lancet* 1957, 2, 966.
3. Frost, J. W., and M. I. Goldwein. Observations on vitamin B<sub>12</sub> absorption in primary pernicious anemia during administration of adrenocortical steroids. *New Engl. J. Med.* 1958, 258, 1096.
4. Gordin, R. Vitamin B<sub>12</sub> absorption in corticosteroid-treated pernicious anaemia. *Acta med. scand.* 1959, 164, 159.
5. Kristensen, H. P. Ø., and T. Friis. Effect of prednisone on B<sub>12</sub> absorption in pernicious anaemia. *Acta med. scand.* 1960, 166, 249.
6. Kristensen, H. P. Ø., and T. Friis. The mechanism of prednisone effect upon B<sub>12</sub> absorption in pernicious anaemia. *Acta med. scand.* 1960, 168, 457.
7. Jeffries, G. H. Recovery of gastric mucosal structure and function in pernicious anemia during prednisolone therapy. *Gastroenterology* 1965, 48, 371.
8. Jeffries, G. H., and M. H. Sleisenger. The immunologic identification and quantitation of human intrinsic factor in gastric secretions. *J. clin. Invest.* 1963, 42, 442.
9. Flick, A. L., W. E. Quinton, and C. E. Rubin. A peroral hydraulic biopsy tube for multiple sampling at any level of the gastrointestinal tract. *Gastroenterology* 1961, 40, 120.
10. Schilling, R. F. Intrinsic factor studies. II. The effect of gastric juice on the urinary excretion of radioactivity after the oral administration of radioactive vitamin B<sub>12</sub>. *J. Lab. clin. Med.* 1953, 42, 860.
11. Jeffries, G. H., and M. H. Sleisenger. Studies of parietal cell antibody in pernicious anemia. *J. clin. Invest.* 1965, 44, 2021.
12. Jeffries, G. H., D. W. Hoskins, and M. H. Sleisenger. Antibody to intrinsic factor in serum from patients with pernicious anemia. *J. clin. Invest.* 1962, 41, 1106.
13. Davenport, H. W. Is the apparent hyposecretion of acid by patients with gastric ulcer a consequence of a broken barrier to diffusion of hydrogen ions into the gastric mucosa? *Gut* 1965, 6, 513.
14. Räsänen, T., and H. Teir. Adrenocorticotrophin and mitotic activity. *Growth* 1961, 41, 1106.
15. Clark, R. H., and B. L. Baker. Effect of adrenalectomy on mitotic proliferation of gastric epithelium. *Proc. Soc. exp. Biol. (N. Y.)* 1962, 111, 311.
16. Myhre, E. Regeneration of the fundic mucosa in rats. V. An autoradiographic study on the effect of cortisone. *Arch. Path.* 1960, 70, 476.
17. Räsänen, T. Mitotic activity in rat epidermis and gastric mucosa after gluco- and mineralocorticoid administration. *Growth* 1962, 26, 1.
18. Irvine, W. J., S. H. Davies, S. Teitelbaum, I. W. Delamore, and A. W. Williams. The clinical and pathological significance of gastric parietal cell antibody. *Ann. N. Y. Acad. Sci.* 1965, 124, 657.
19. Taylor, K. B. Inhibition of intrinsic factor by pernicious anaemia sera. *Lancet* 1959, 2, 106.
20. Ardeman, S., and I. Chanarin. Steroids and Addisonian pernicious anemia. *New Engl. J. Med.* 1965, 273, 1352.