FIGURE 1

FIG. 1. CASE 38, DIED ON FOURTH DAY OF PRIMARY SHOCK AT THE BEGINNING OF THE HYPOTENSIVE PHASE—THE OUTER CORTEX

Except for some swelling of the epithelial cells of proximal convolutions and dilatation of distal tubules, which appear empty, the renal elements are essentially normal. Magnification 150 ×.

FIGURE 2

FIG. 2. JUNCTION OF LOWER CORTEX AND MEDULLA SHOWING DILATATION OF PROXIMAL CONVOLUTIONS ENTERING THE MEDULLA AND OF ASCENDING LIMBS PASSING TO THE CORTEX. MAGNIFICATION 150 ×

FIGURE 3

FIG. 3. MID PORTION OF OUTER STRIPE OF OUTER ZONE OF THE MEDULLA

In the central lower half can be seen the irregular and diffuse pattern of dilated intertubular capillaries crowded with red blood cells. Magnification 150 ×.

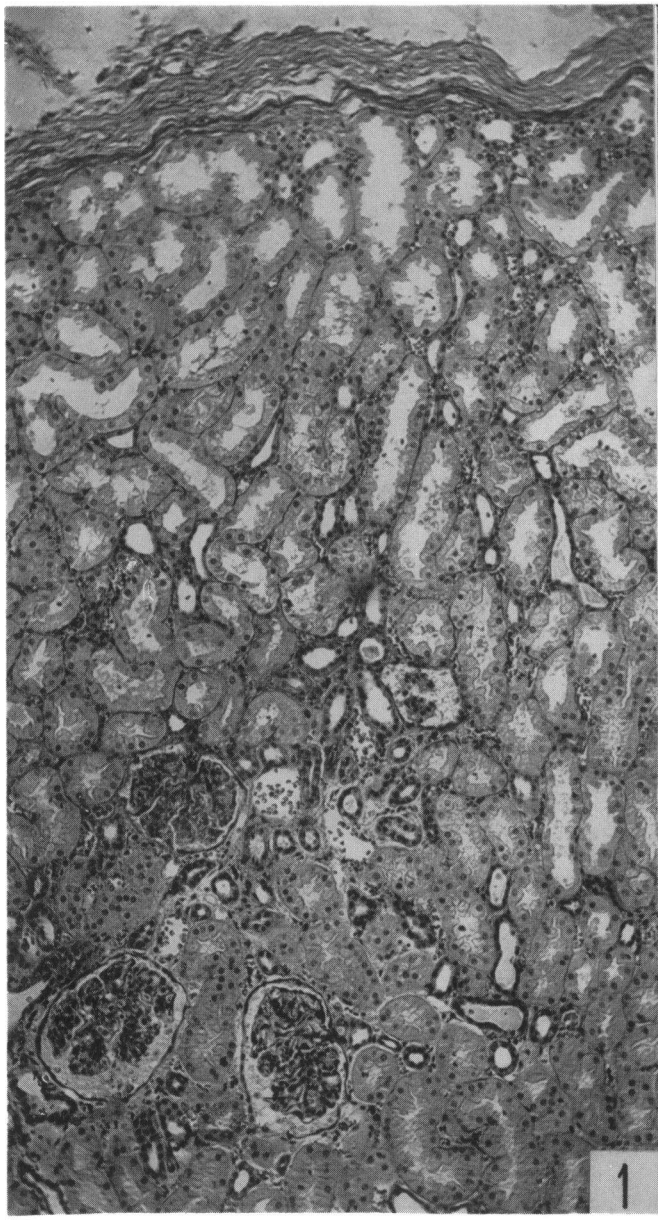
1

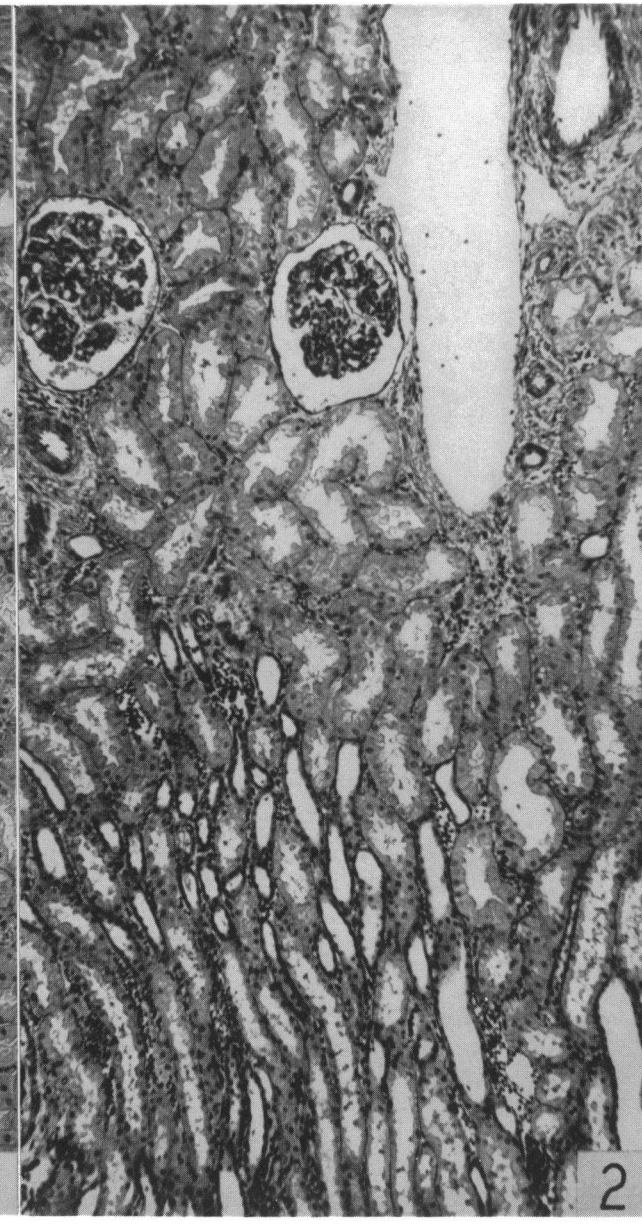
2

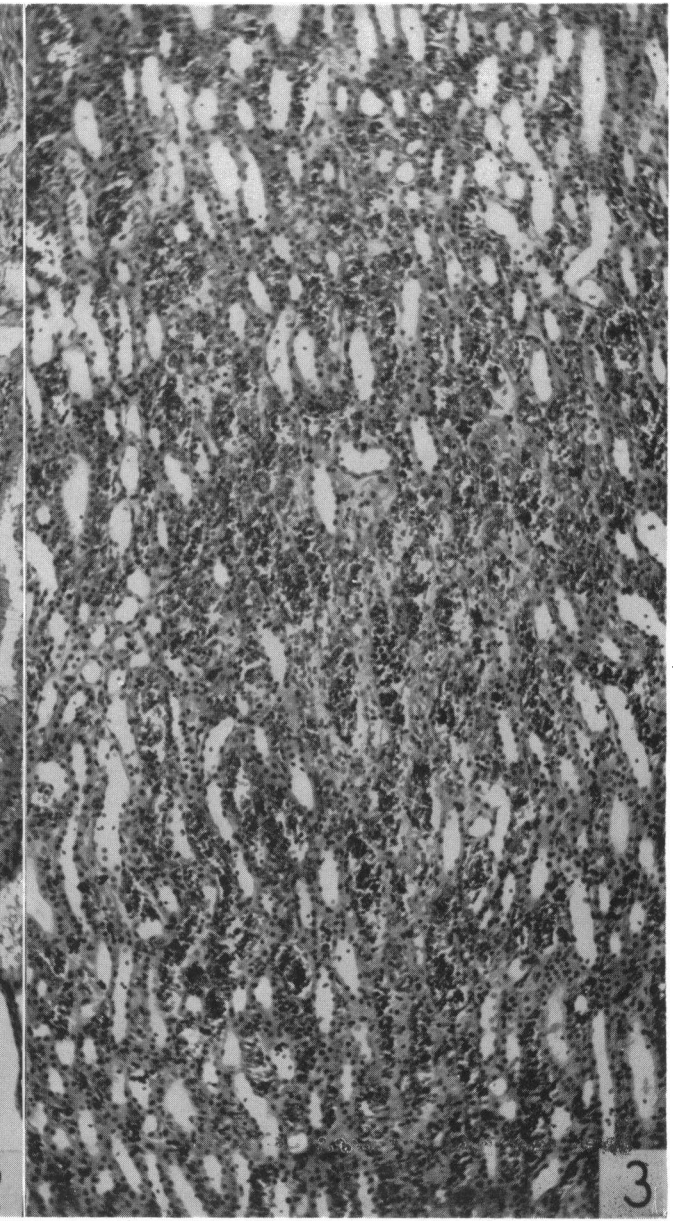
3

FIGURE 4

FIG. 4. THE CONGESTED AREA OF THE SAME KIDNEY AS SHOWN IN FIGURE 3

The thin endothelial walls of the intertubular capillaries are intact and their greatly dilated lumens are filled with discrete red cells, which gives the appearance of circulating blood. There is no hemorrhage. Magnification 300 ×.

FIGURE 5

FIG. 5. THE DEEP MEDULLA

The collecting tubules are well preserved; there is no great congestion but there is extensive intertubular edema. Magnification 150 ×.

FIGURE 6

FIG. 6. CASE 9, DIED ON THE FIFTH DAY IN THE HYPOTENSIVE PHASE OF PRIMARY SHOCK—AN AREA OF SUBCORTICAL CONGESTION SIMILAR IN LOCATION TO FIGURE 4

The thin endothelial walls of the intertubular capillaries are intact, their distended lumens crowded with red cells which have fused to hyaline masses, thus giving the appearance of stagnation of flow or stasis. Other cross sections are of tubules with flattened epithelium (thin loops?) containing hyaline casts. Magnification 300 ×.

4

5

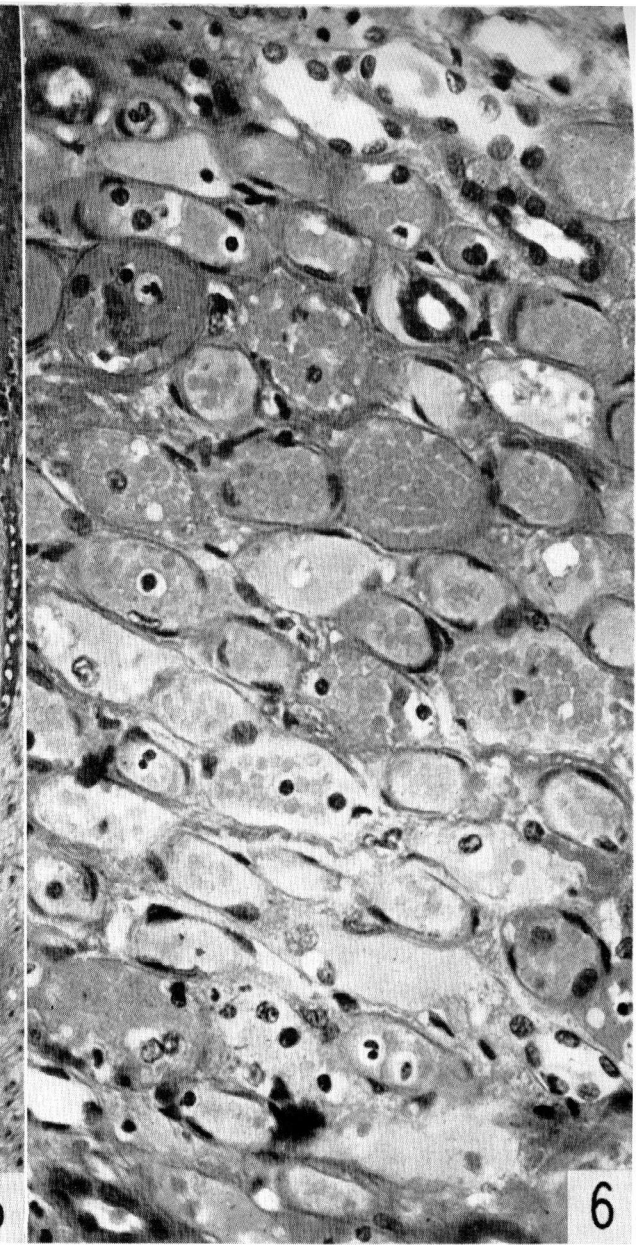
6

FIGURE 7

FIG. 7. MID-CORTICAL REGION SHOWING A GREATLY CONGESTED GLOMERULAR TUFT

There is considerable leakage of protein into Bowman's space. In the two cross sections of proximal convolution, beginning swelling and vacuolization are apparent. Magnification 500 ×.

FIGURE 8

FIG. 8. CASE 20, DIED OF PRIMARY SHOCK ON THE SEVENTH DAY IN THE HYPOTENSIVE PHASE—AN AREA OF CORTICAL INTERTUBULAR EDEMA SURROUNDING DISTORTED CROSS SECTIONS OF PROXIMAL CONVOLUTIONS THE EPITHELIUM OF WHICH SHOWS SCATTERED CLEAR VACUOLES—MAGNIFICATION 500 ×

FIGURE 9

FIG. 9. CASE 26, DIED ON THE SIXTH DAY OF PRIMARY SHOCK IN THE HYPOTENSIVE PHASE —EXTREME SWELLING OF THE PROXIMAL CONVOLUTIONS THROUGHOUT THE CORTEX WITH MARKED VACUOLIZATION OF THE EPITHELIAL CELLS—MAGNIFICATION 500 ×

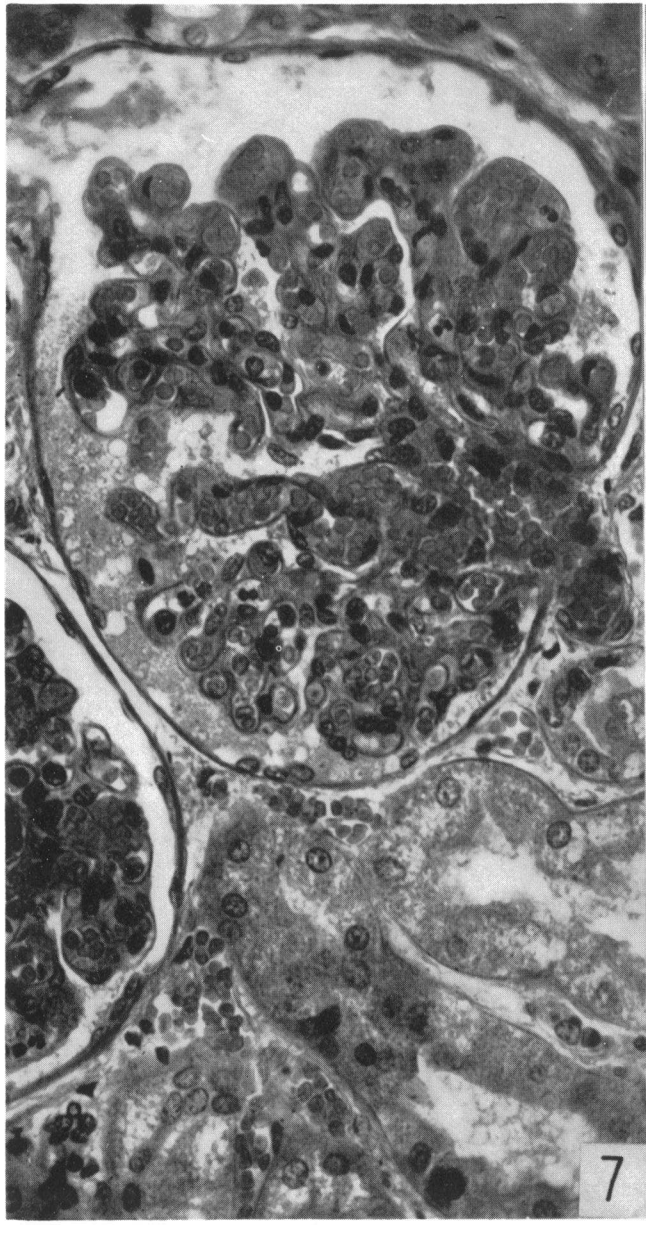
7

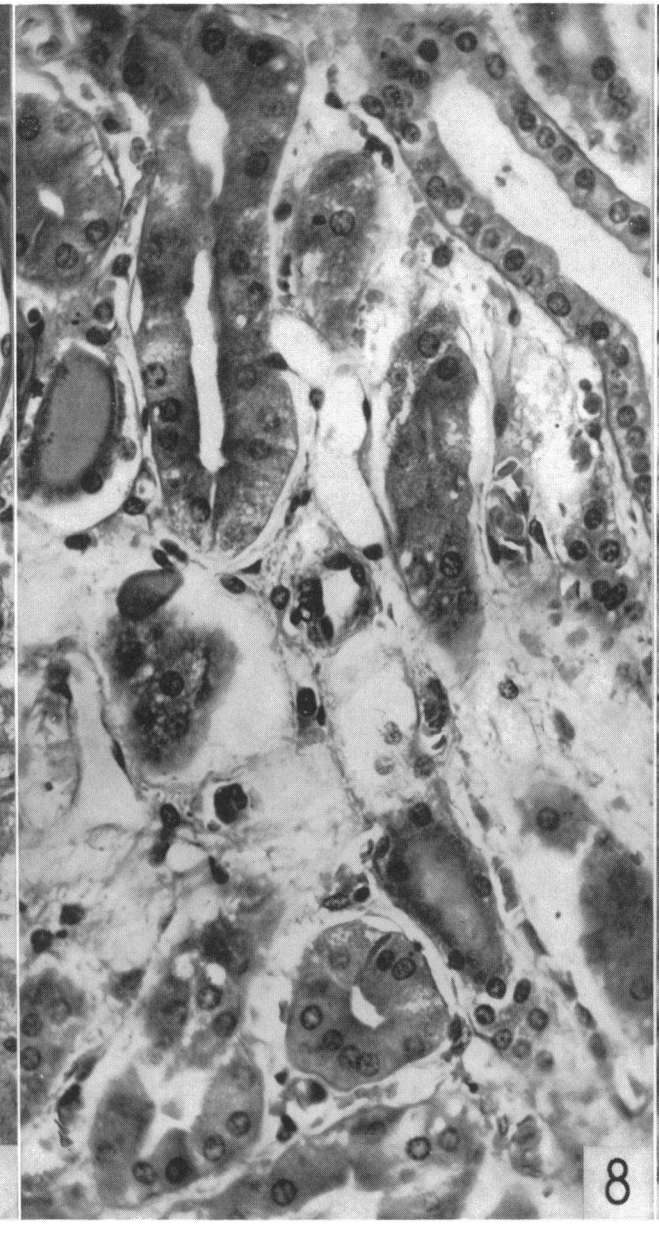
8

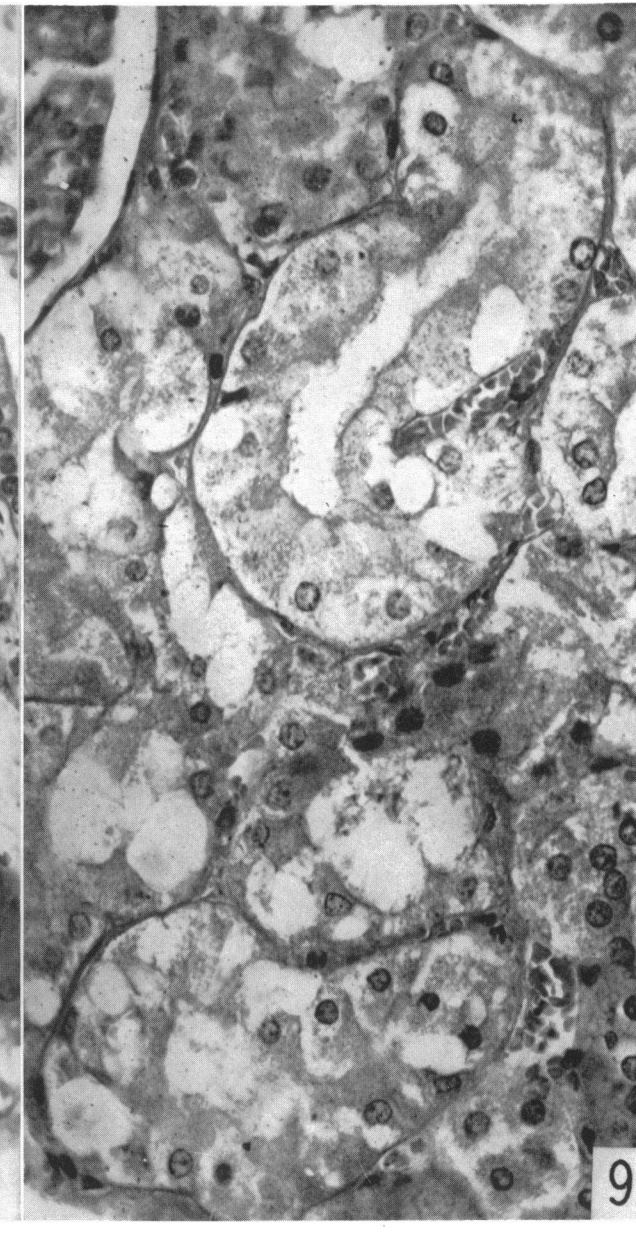
9

FIGURE 10

FIG. 10. CASE C, DIED ON THE EIGHTH DAY WITH PULMONARY EDEMA IN THE HYPOTENSIVE PHASE—TRANSITION OF CORTEX TO MEDULLA SHOWING EXTREME FINE VACUOLIZATION OF PROTOPLASM OF CELLS OF TERMINAL SEGMENT OF A PROXIMAL CONVOLUTION

Note the well preserved brush borders. Magnification 500 ×.

FIGURE 11

FIG. 11. VACUOLAR SWELLING OF TUBULAR EPITHELIUM IN CORTICAL PROXIMAL CONVOLUTION WITH EXTENSION INTO BOWMAN'S SPACE AND COMPRESSION OF GLOMERULAR TUFT—MAGNIFICATION 500 ×

FIGURE 12

FIG. 12. CASE A, DIED ON THE FIFTH DAY OF PRIMARY SHOCK IN THE HYPOTENSIVE PHASE—A MEDULLARY RAY IS SHOWN PASSING HORIZONTALLY THROUGH THE MIDDLE HALF OF THE FIGURE

The majority of the tubules (ascending limbs of Henle's loop) are filled with clear hyaline casts. Magnification 150 ×.

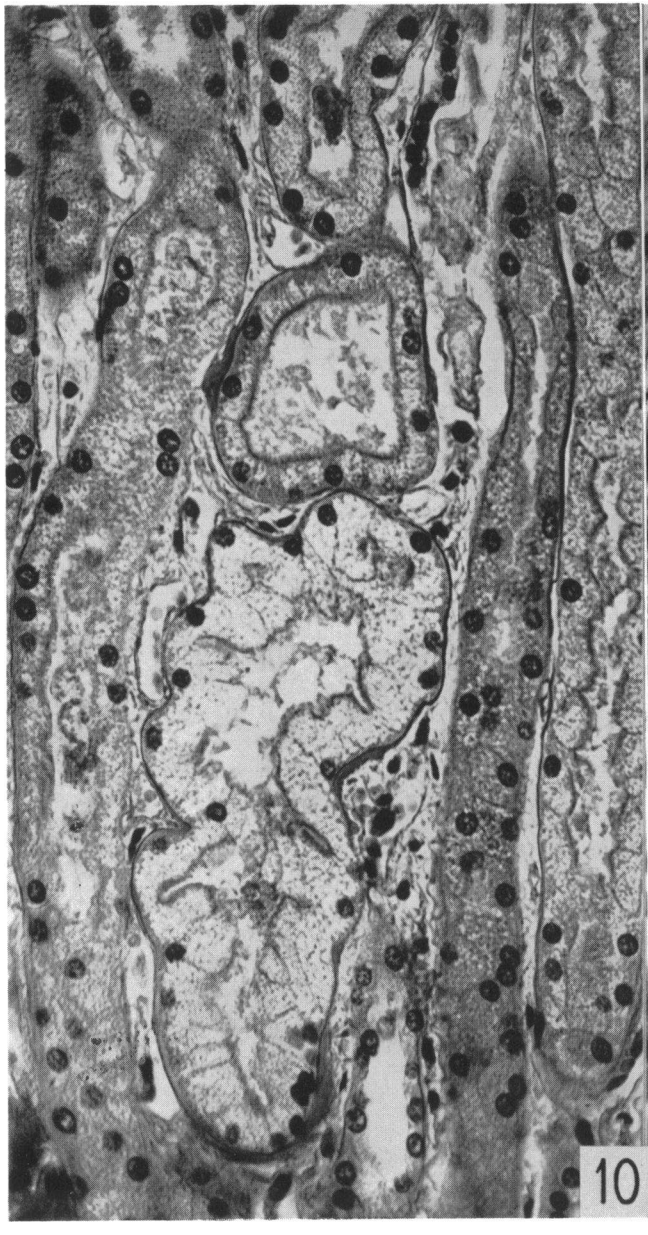

10

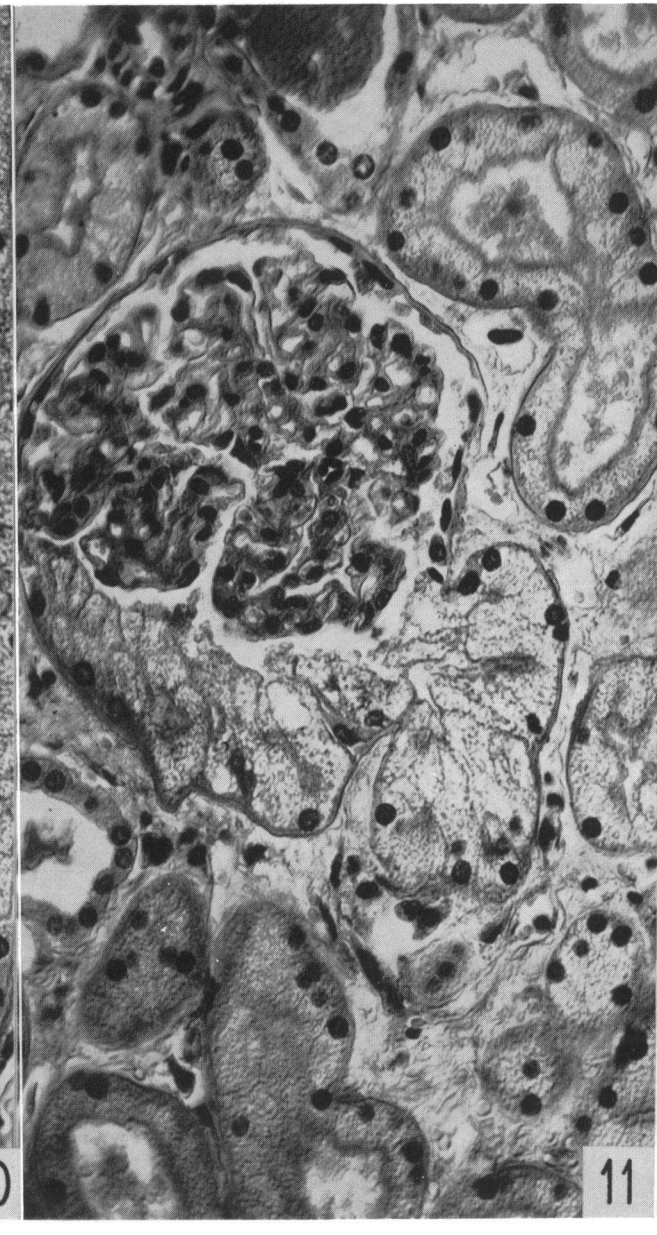

11

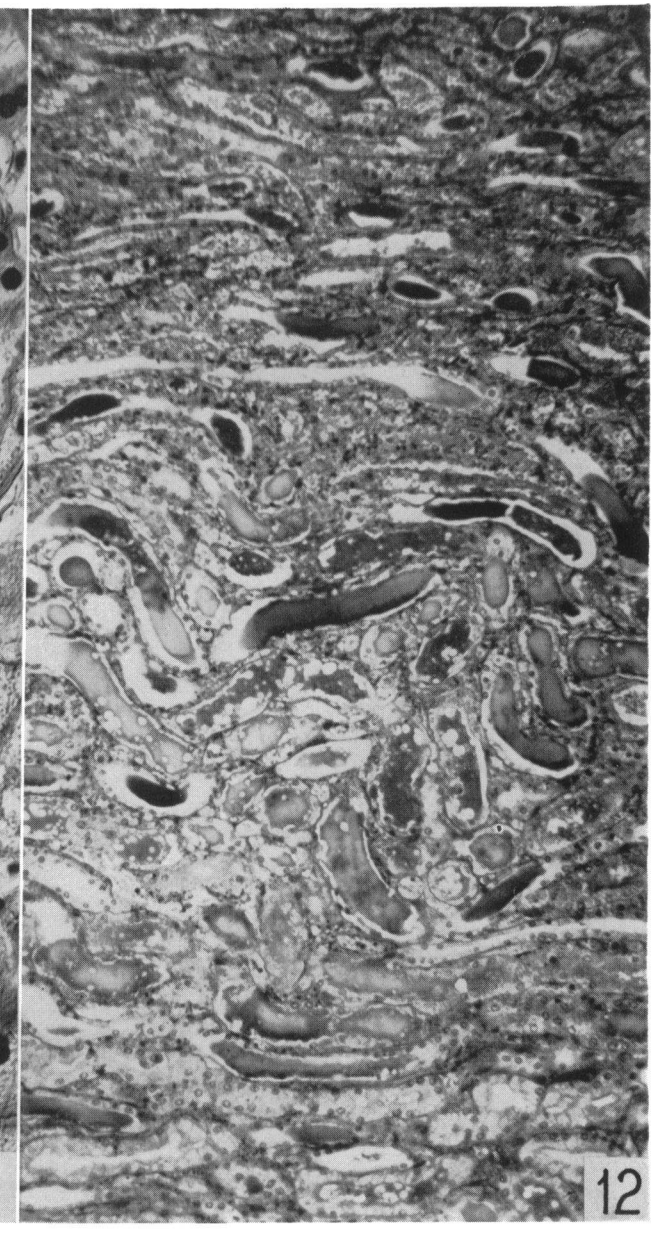

12

FIGURE 13

FIG. 13. TERMINAL SEGMENTS OF PROXIMAL CONVOLUTIONS LYING IN THE SUBCORTICAL ZONE OF CONGESTION SHOWING IRREGULAR COMPRESSION AND DISTENTION OF THEIR LUMENS WHICH CONTAIN COAGULATED PROTEINACEOUS MATERIAL

The lining epithelium is either flattened or filled with hyaline droplets. Magnification 500 ×.

FIGURE 14

FIG. 14. CASE 21, DIED ON SIXTH DAY OF PRIMARY SHOCK IN THE HYPOTENSIVE PHASE—HE RECEIVED 5 UNITS OF HUMAN SERUM ALBUMIN IN THE 36 HOURS PRECEDING HIS DEATH

Section of cortex, stained with Gram, showing practically all cross sections of proximal convolutions filled with Gram positive droplets. Magnification 100 ×.

FIGURE 15

FIG. 15. SAME PREPARATION AT HIGHER POWER

Every cross section of proximal convolution in the field is crowded and distended with Gram positive droplets. The nuclei of the epithelial cells, when visible, are well preserved. Magnification 500 ×.

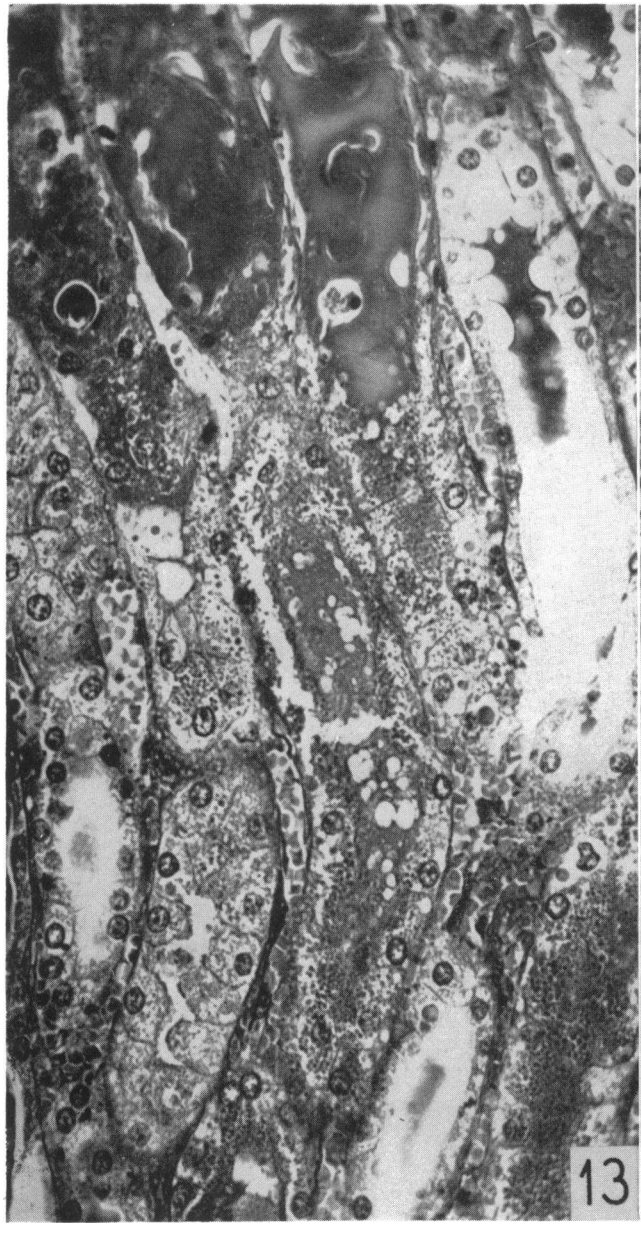
13

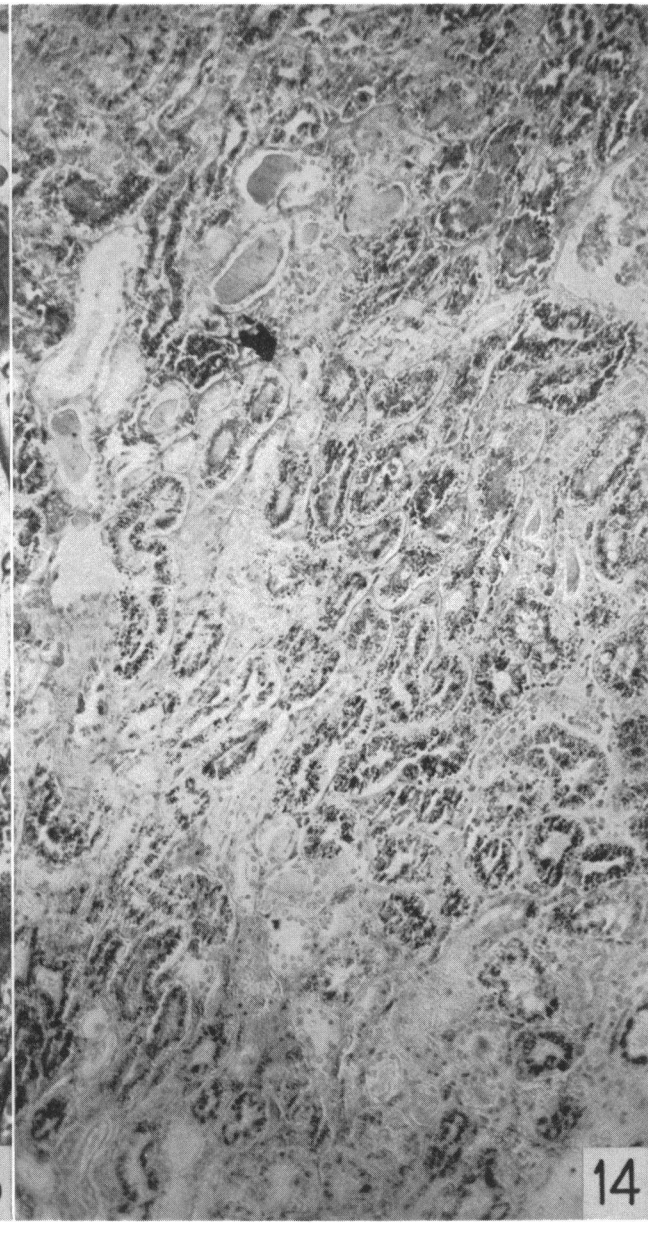
14

15

FIGURE 16

FIG. 16. CASE 39, DIED ON THE SEVENTH DAY OF SHOCK IN THE TRANSITION FROM THE HYPOTENSIVE TO THE OLIGURIC PHASE—ONE OF THE SCATTERED AREAS OF INTERTUBULAR EDEMA IN CORTEX

The epithelium of the proximal convolutions is swollen; a distal convolution contains a solid cast. Magnification 500 ×.

FIGURE 17

FIG. 17. ENTRAPMENT OF PROTEINACEOUS MATERIAL CONTAINING MANY DESQUAMATED EPITHELIAL CELLS IN "STRAIGHT TUBULES" LYING IN THE SUBCORTICAL ZONE OF CONGESTION

The intertubular capillaries are distended with red cells. Magnification 500 ×.

FIGURE 18

FIG. 18. THE PAPILLA, SHOWING EXTENSIVE EDEMA AND MARKED CONGESTION WITH BEGINNING HEMORRHAGE

The large ducts of Bellini contain the renal failure casts of Addis. Magnification 150 ×.

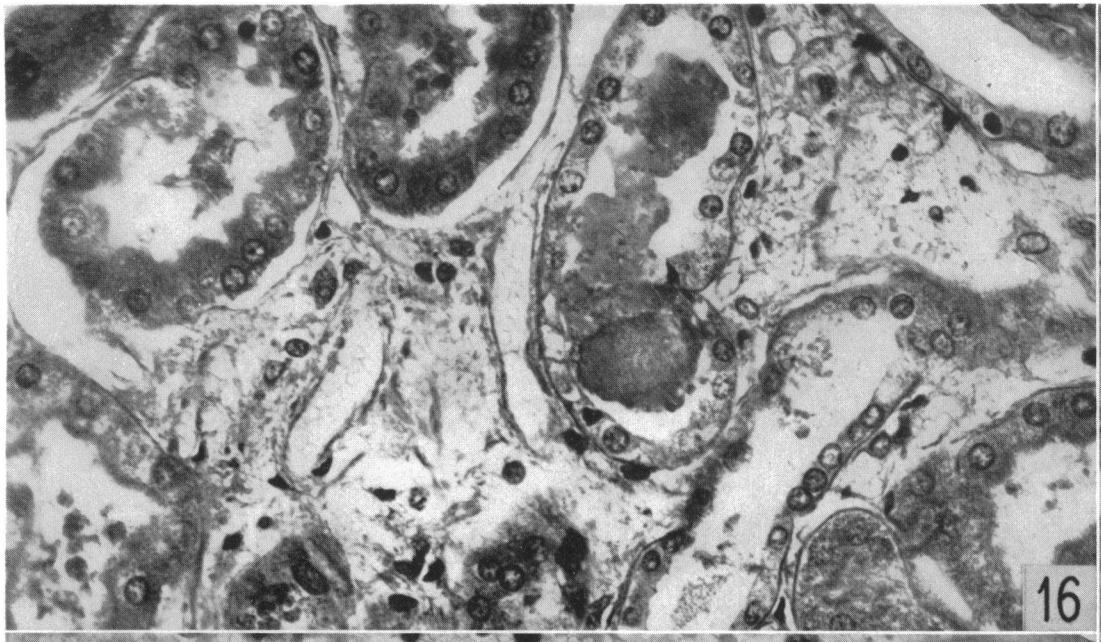
16

17

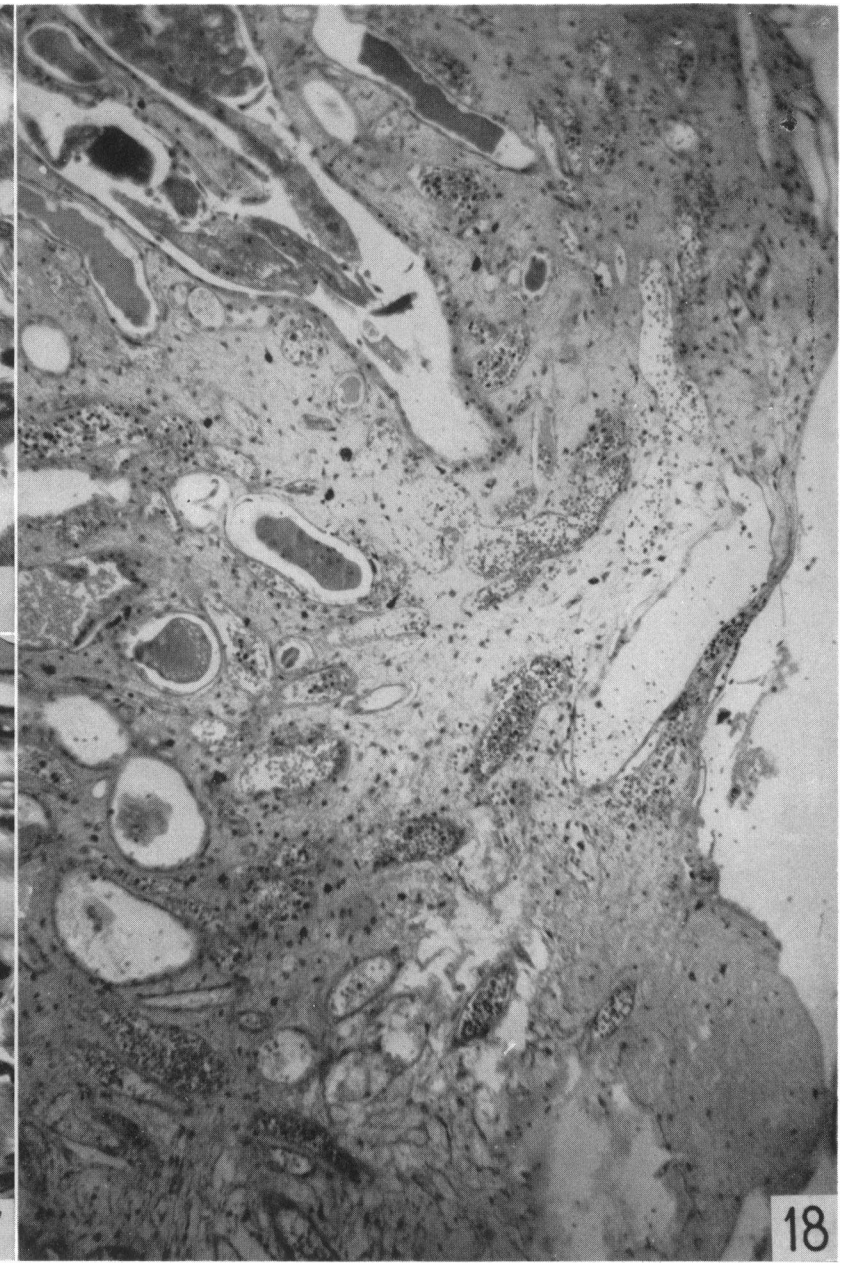
18

FIGURE 19

FIG. 19. CASE 28, DIED ON THE TENTH DAY OF TRANSITION SHOCK—THE SUBCORTICAL ZONE OF HEMORRHAGE

No remnants of the intertubular capillaries remain in a mass of crowded red blood cells which isolates and compresses enclosed degenerating and necrotic tubules; above, the remnant of a terminal segment of a proximal convolution; below, less damaged collecting tubules. Magnification 500 ×.

FIGURE 20

FIG. 20. THE CORTEX, SHOWING IRREGULAR EXTENSION OF THE INTERTUBULAR HEMORRHAGE FROM THE SUBCORTICAL MEDULLA

Proximal convolutions are surrounded and widely separated by the infiltration which reaches in places to the capsule. Magnification 150 ×.

FIGURE 21

FIG. 21. DETAIL OF CORTICAL INTERTUBULAR HEMORRHAGE AND ITS EFFECT ON THE ENCLOSED TUBULES

In the left center three cross sections show the typical appearance of the tubulorhexic lesion in histological section; in each, a portion of the entire wall is destroyed and yet the remaining cells and basement membrane are remarkably well preserved and intact. Magnification 500 ×.

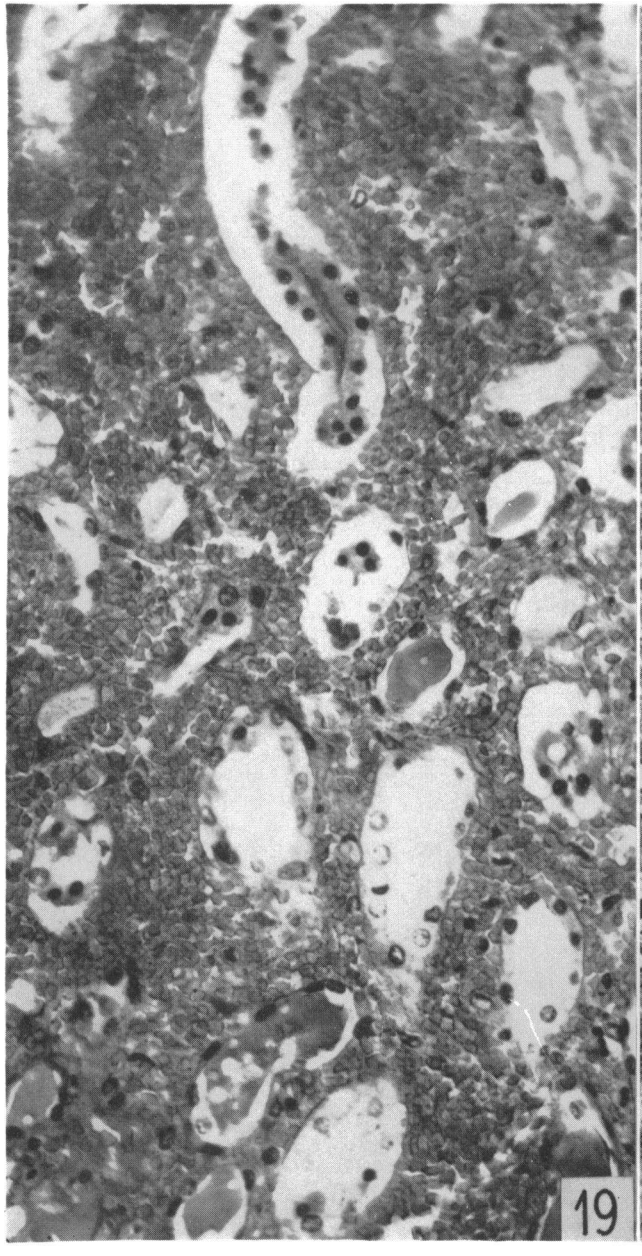
19

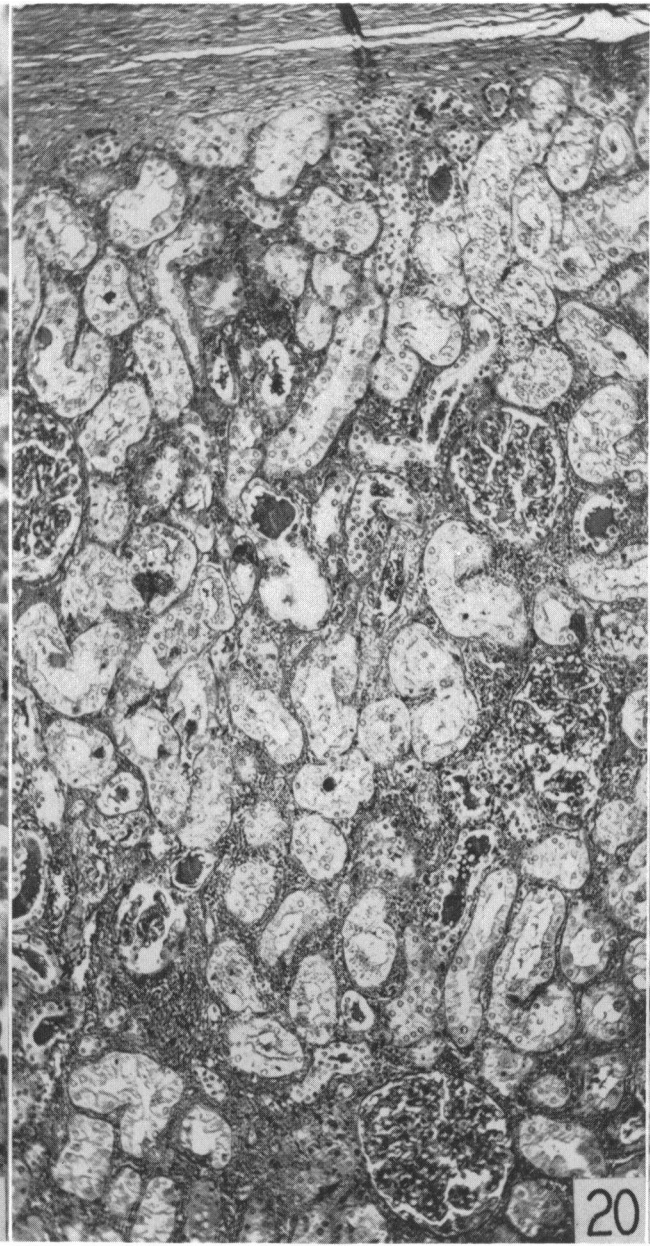
20

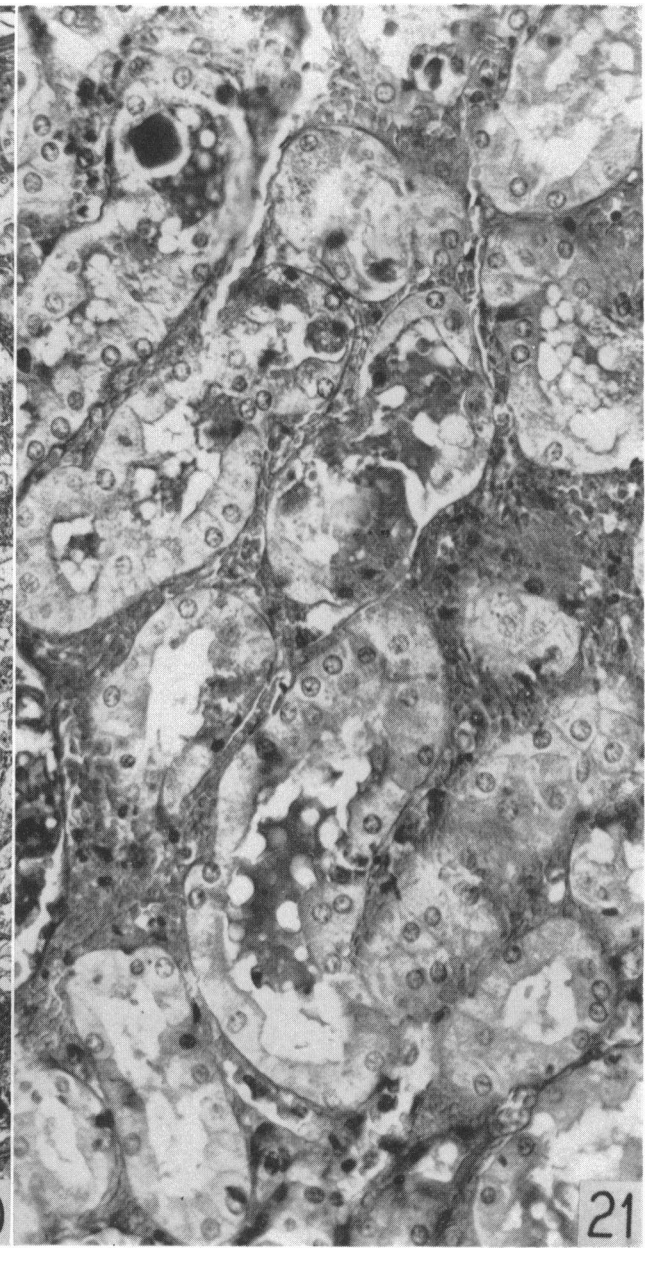
21

FIGURE 22

FIG. 22. MID-MEDULLA, SHOWING COMPLETE NECROSIS OF ALL TISSUES INCLUDING TUBULES, MOSTLY COLLECTING, WHICH STILL MAINTAIN THEIR EXTERNAL CONFIGURATION

To the right, stasis in engorged vessels crowded with compacted red cells; there is no extensive hemorrhage. Magnification 150 ×.

FIGURE 23

FIG. 23. THE PAPILLA—EXTENSIVE CONGESTION WITH STASIS AND HEMORRHAGE

The necrotic ducts of Bellini are still recognizable and are filled with huge renal failure casts. Magnification 150 ×.

FIGURE 24

FIG. 24. CASE 31, DIED ON THE ELEVENTH DAY IN THE OLIGURIC PHASE—THE TYPICAL APPEARANCE OF THE CORTEX IN THE STATE OF ESTABLISHED OLIGURIA

Dilatation of all urinary channels above the compression of the zone of intertubular hemorrhage. Bowman's space, proximal convolution and distal convolution (two cross sections contain solid debris) are greatly and evenly distended with resulting pressure effects on tufts and epithelium. Magnification 150 ×.

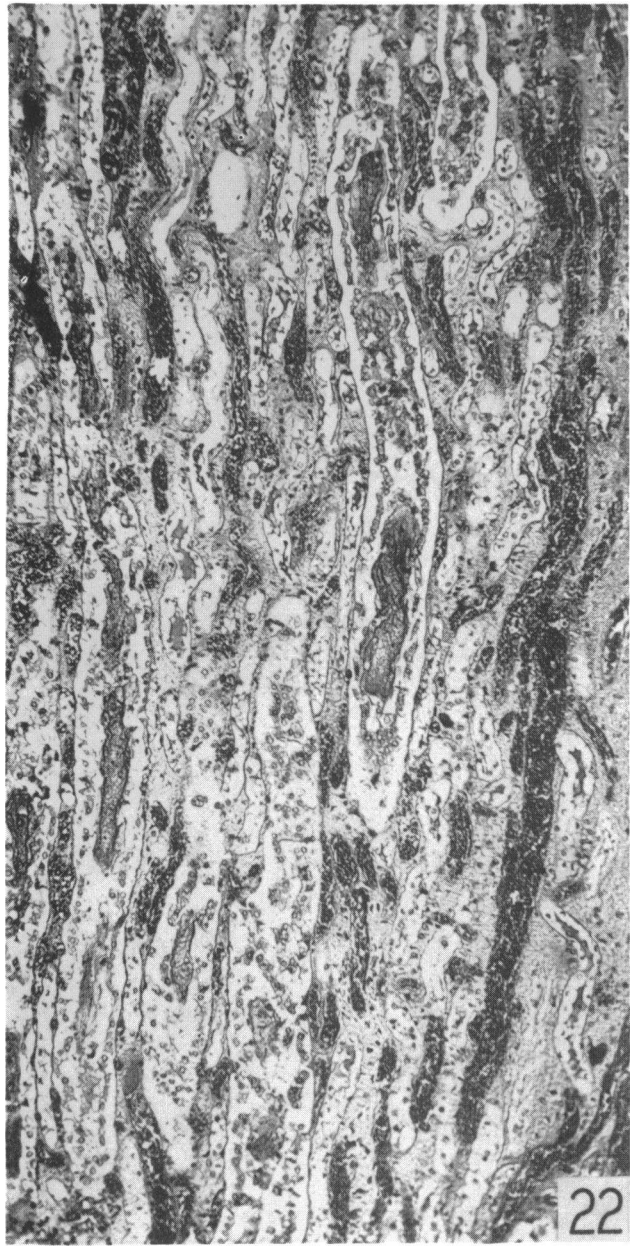
22

23

24

FIGURE 25

FIG. 25. OUTER STRIPE OF THE OUTER ZONE OF THE MEDULLA

Below, the intertubular hemorrhage is so extreme as to obliterate tubules; above, in the transition to the cortex is seen the beginning dilatation that extends into the cortical tubules shown in Figure 24. Magnification 150 ×.

FIGURE 26

FIG. 26. CASE 25, DIED ON THE TENTH DAY IN THE OLIGURIC PHASE

The large cross section of proximal convolution shows an irregular but living epithelium in which are two mitotic figures. Immediately above, in a smaller cross section, one-half of the tubular wall is composed of atypical regenerated epithelium, the other of invading intertubular connective tissues. Magnification 500 ×.

FIGURE 27

FIG. 27. CASE 41, DIED ON THE TENTH DAY IN THE OLIGURIC PHASE—ONE OF THE SCATTERED AREAS OF CORTICAL INTERTUBULAR EDEMA

The deforming effect of external pressure on the irregular dilatation of proximal convolutions is apparent. Magnification 500 ×.

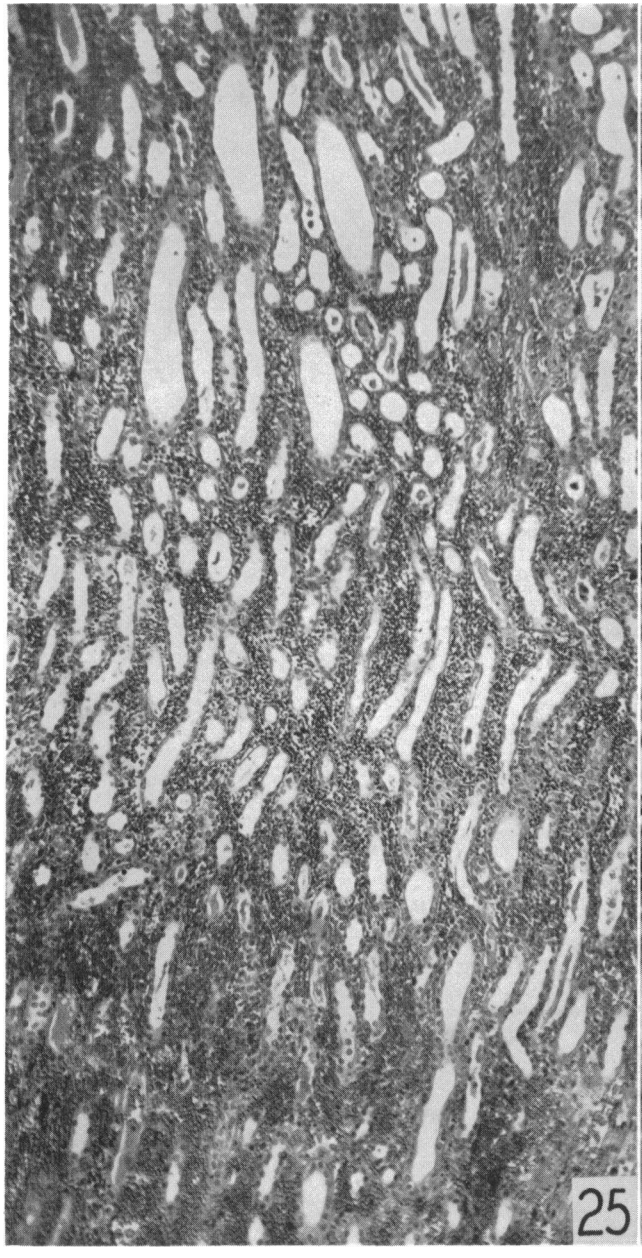
25

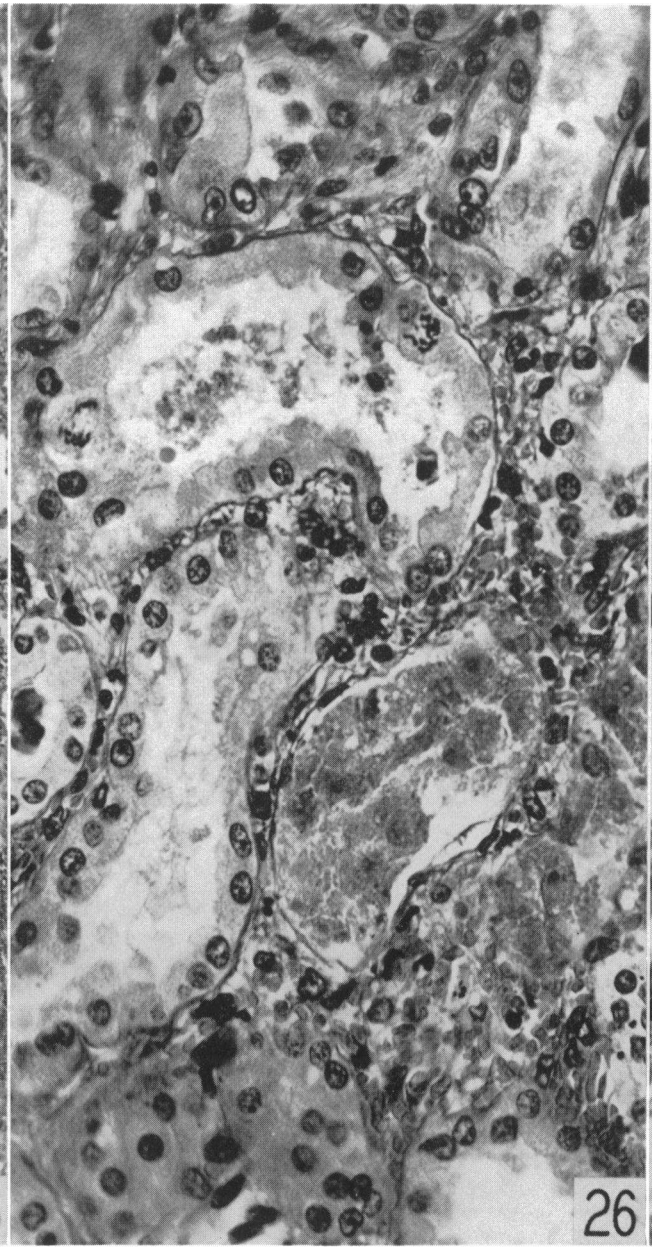
26

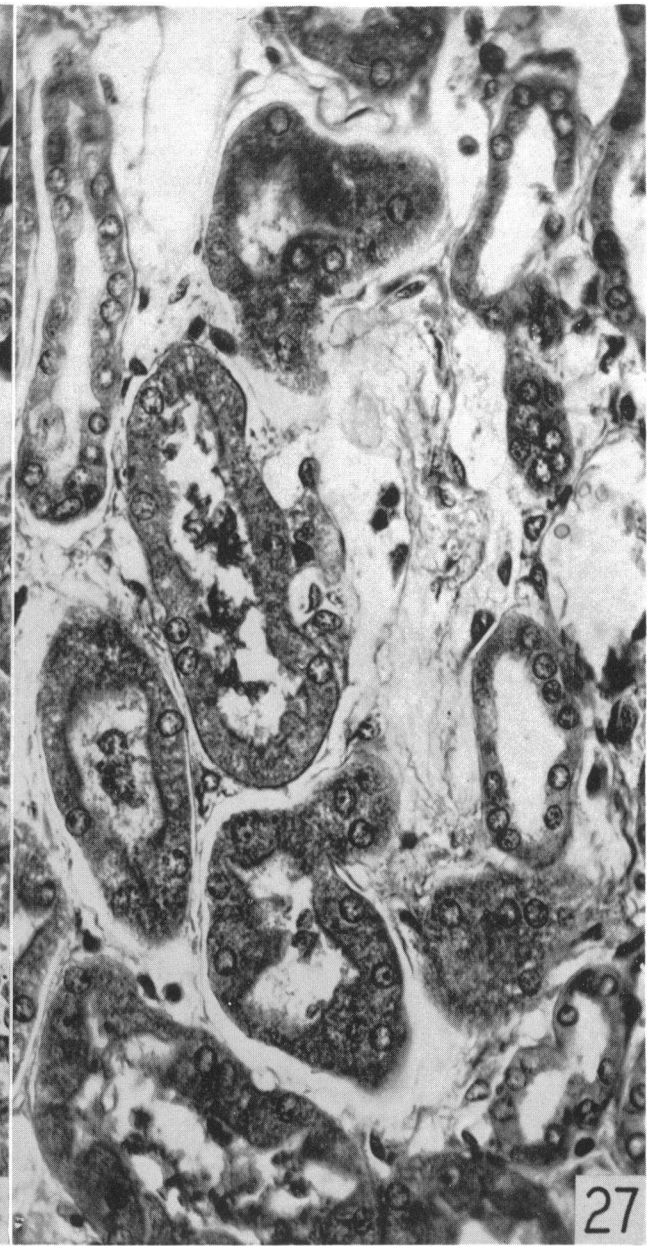
27

FIGURE 28

FIG. 28. CASE D, DIED ON THE FIFTEENTH DAY IN TRANSITION FROM THE OLIGURIC TO THE DIURETIC PHASE—DIFFUSE HEMORRHAGIC INFILTRATION THROUGHOUT THE PAPILLA

The contours and epithelial cells of the ducts of Bellini are still intact. Magnification 150 ×.

FIGURE 29

FIG. 29. OUTER ZONE OF THE MEDULLA

The external configuration of collecting tubules still persists but there is complete necrosis of all tissues. Magnification 150 ×.

FIGURE 30

FIG. 30. OUTER STRIPE OF OUTER ZONE SHOWING SUBCORTICAL AREA OF NECROSIS AND HEMORRHAGE

Extending down from the cortex are completely necrotic terminal segments of proximal convolutions. Magnification 500 ×.

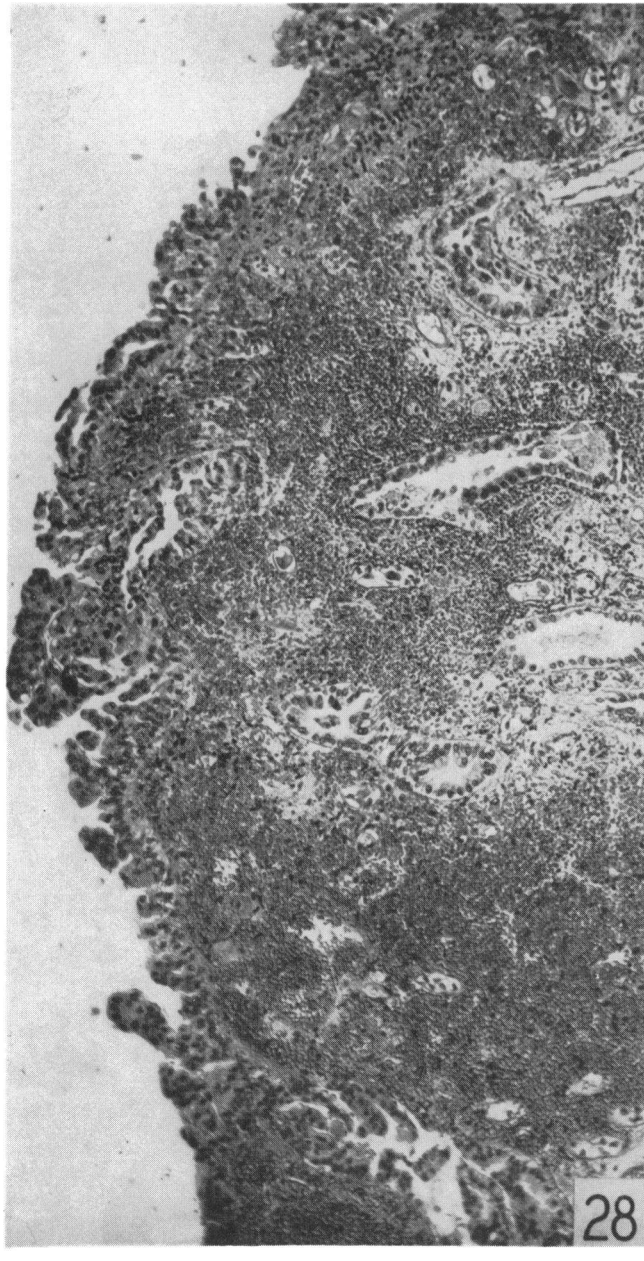

28

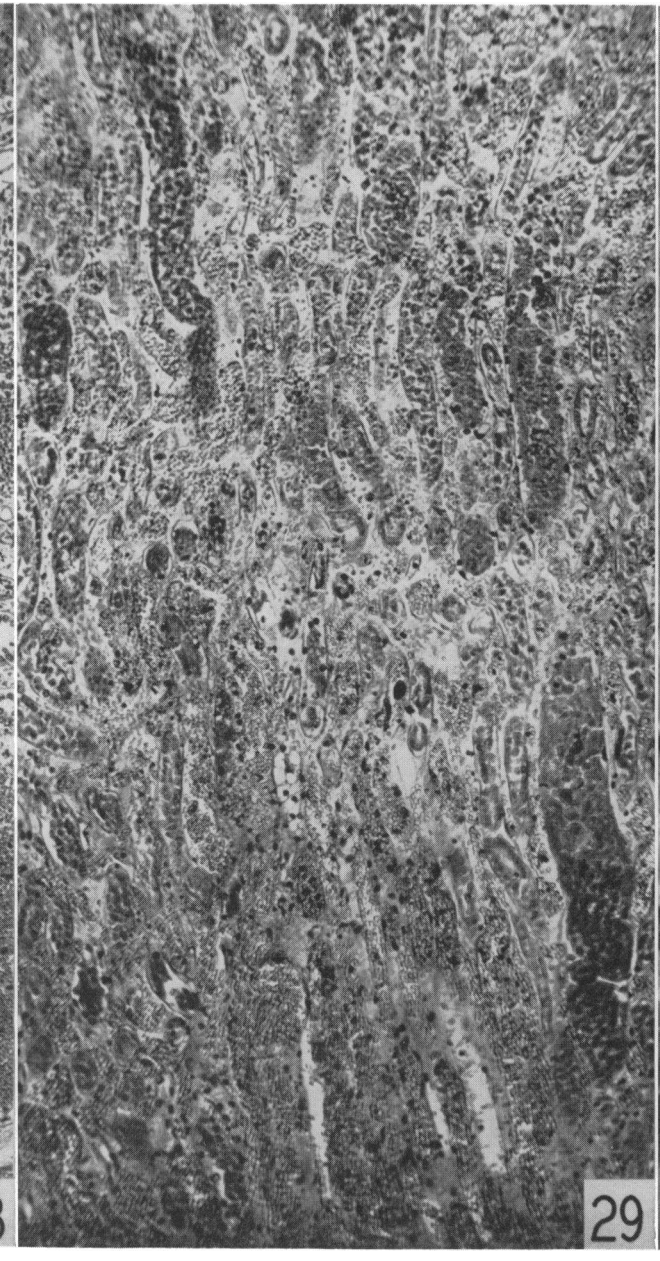

29

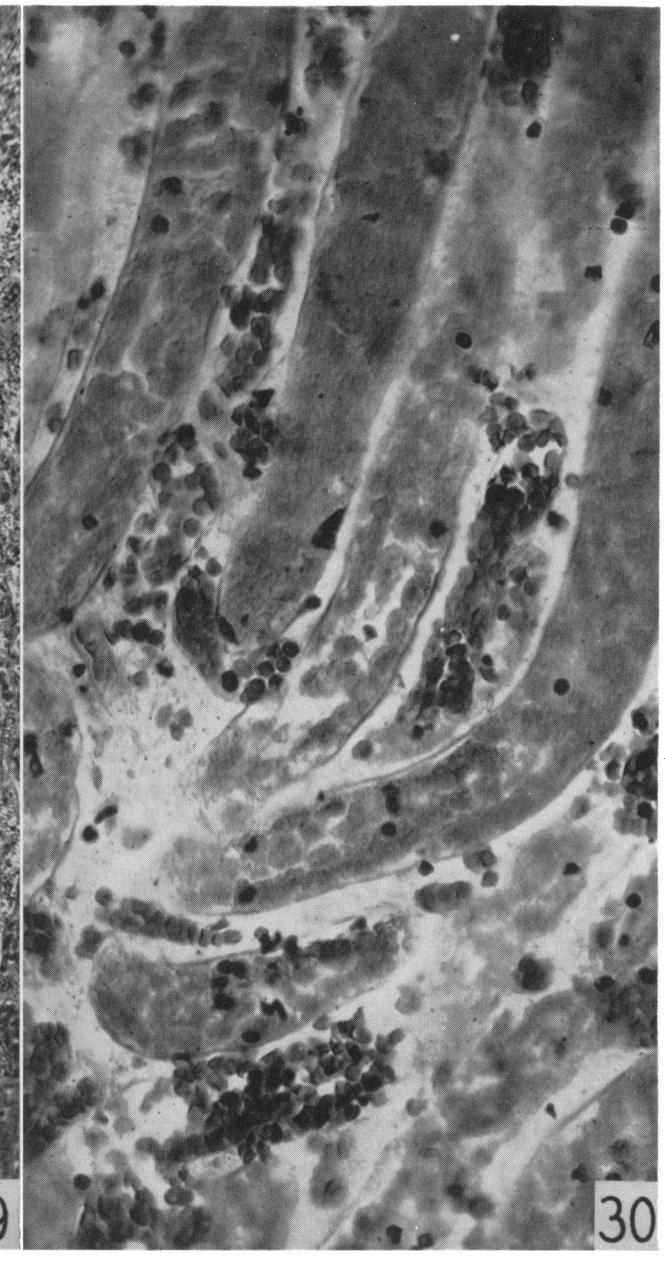

30

FIGURE 31

FIG. 31. SOMEWHAT DEEPER IN THE MEDULLA

In the upper left, necrotic terminal segments of proximal convolutions; below, wisp-like terminal segments with huge hyperchromatic giant-cell nuclei extend into the region of intertubular hemorrhage. Magnification 500 ×.

FIGURE 32

FIG. 32. CORTEX SHOWING THE PERSISTING OLIGURIC DILATATION OF CONVOLUTIONS, PROXIMAL AND DISTAL, AND OF BOWMAN'S SPACE—MAGNIFICATION 150 ×

FIGURE 33

FIG. 33. HIGHER POWER VIEW OF SAME DILATED CORTICAL PROXIMAL CONVOLUTIONS

The epithelium shows the oval and irregular nuclei of flattened regenerated cells which have replaced the original epithelium which had been destroyed by necrosis and desquamation. Magnification 500 ×.

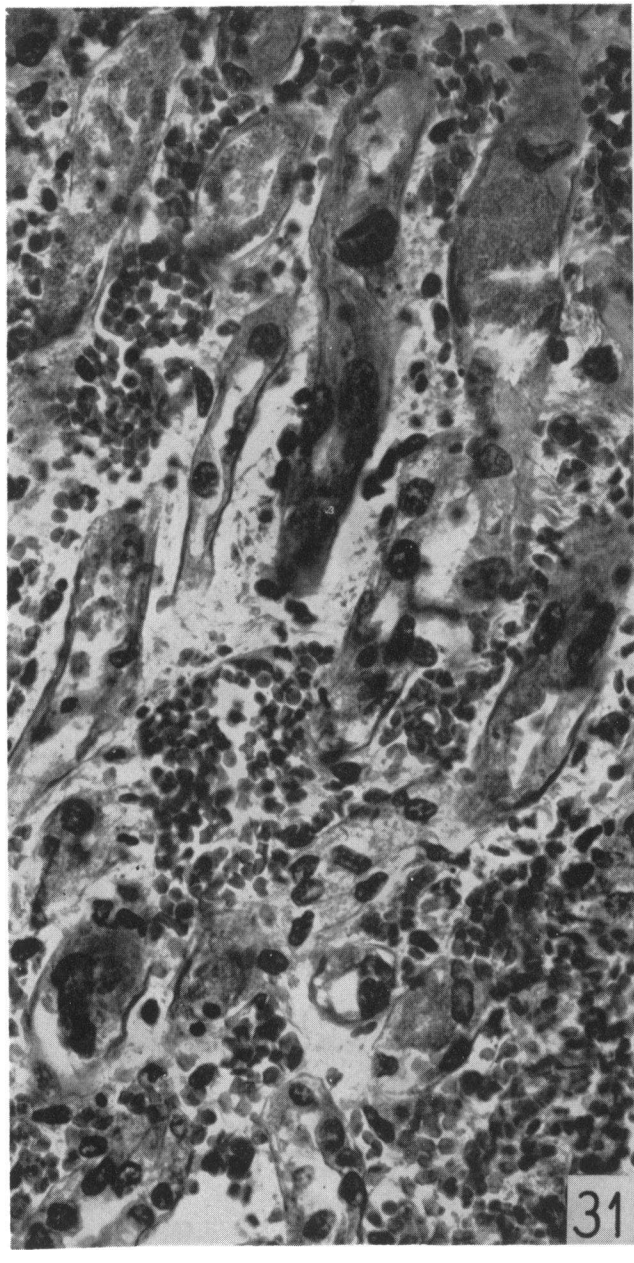
31

32

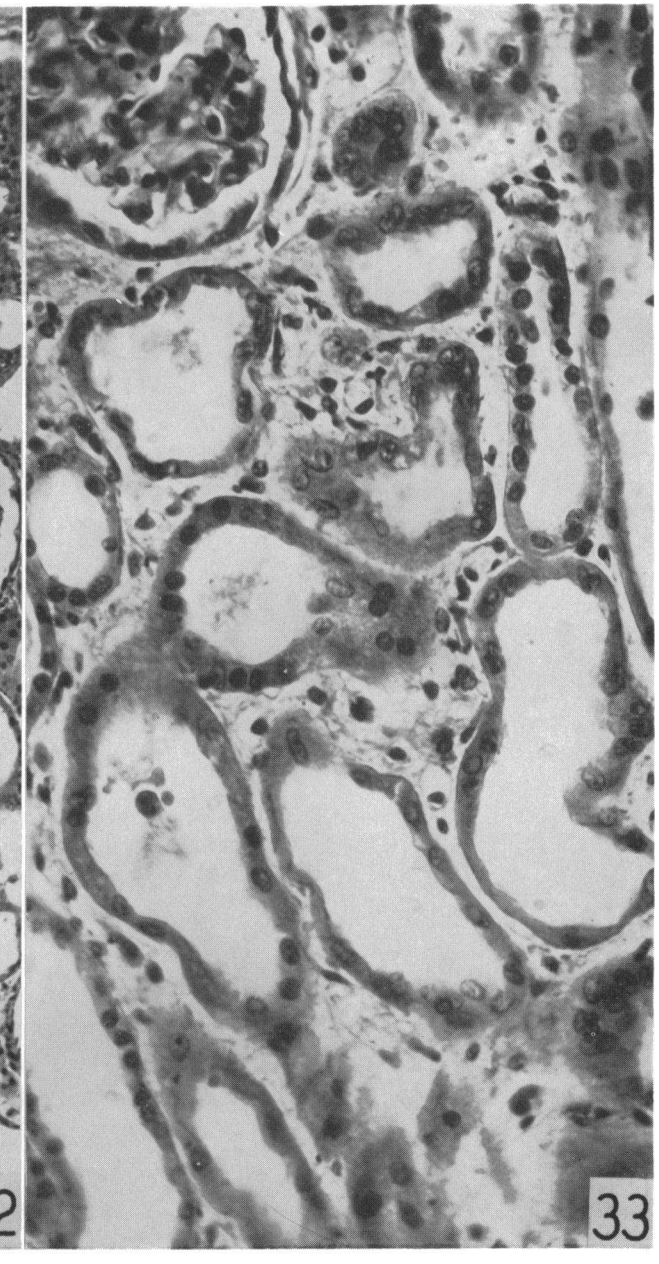
33

FIGURE 34

FIG. 34. CASE 43, DIED ON THE SIXTEENTH DAY OF HIS ILLNESS AND IN THE FIFTH DAY OF THE DIURETIC PHASE—OUTER CORTEX, CAPSULAR SURFACE TO LEFT

The proximal convolutions are lined with epithelium of their original normal type and the dilatation of the Oliguric Phase has disappeared. The appearance suggests that not much tubular damage had occurred at any previous phase of the disease. Magnification 150 ×.

FIGURE 35

FIG. 35. OUTER STRIPE OF OUTER ZONE OF MEDULLA

Extending down from the cortex are the terminal segments of proximal convolutions. They are lined with a deeply staining atypical regenerated epithelium. The destruction of the original cells of these tubules was the result of the intertubular hemorrhage in this region (*cf.* Figure 30); this hemorrhage is no longer apparent and the intertubular spaces are filled with fibroblastic tissue. Magnification 350 ×.

FIGURE 36

FIG. 36. A DEEPER LEVEL IN THE MEDULLA

Among areas of persisting intertubular hemorrhage ill-defined patches of resolution are seen where, between atypical hyperplastic tubules, mostly collecting, a fibroblastic connective tissue has replaced earlier hemorrhage. Magnification 150 ×.

FIGURE 37

FIG. 37. OUTER MEDULLA

The Masson stain shows the increase in fine collagenous fibrils between tubules in an area of resolution with thickening of the basement membranes of tubules. Magnification 350 ×.

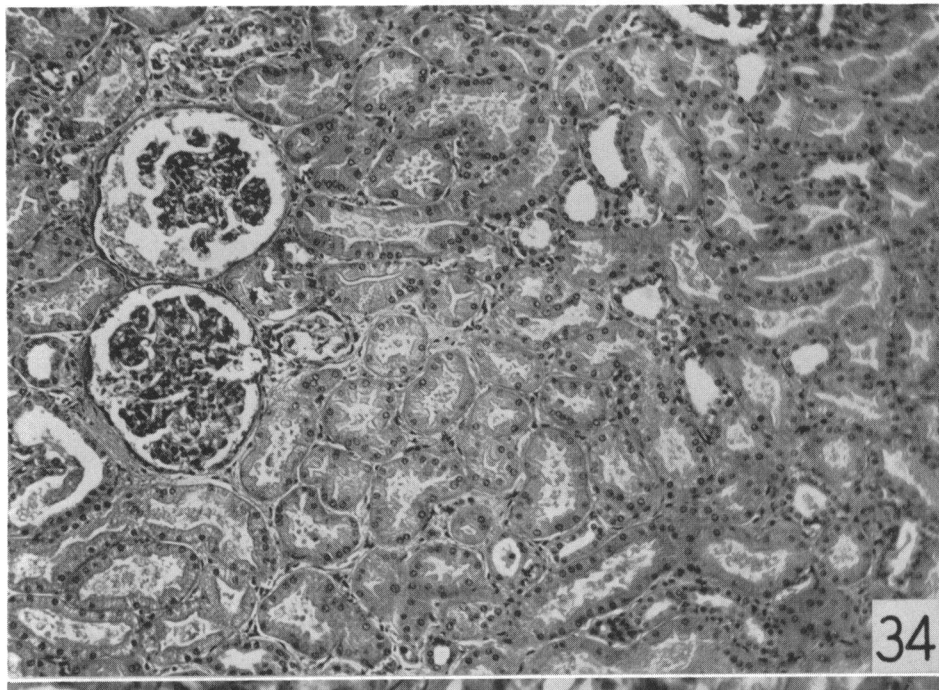
34

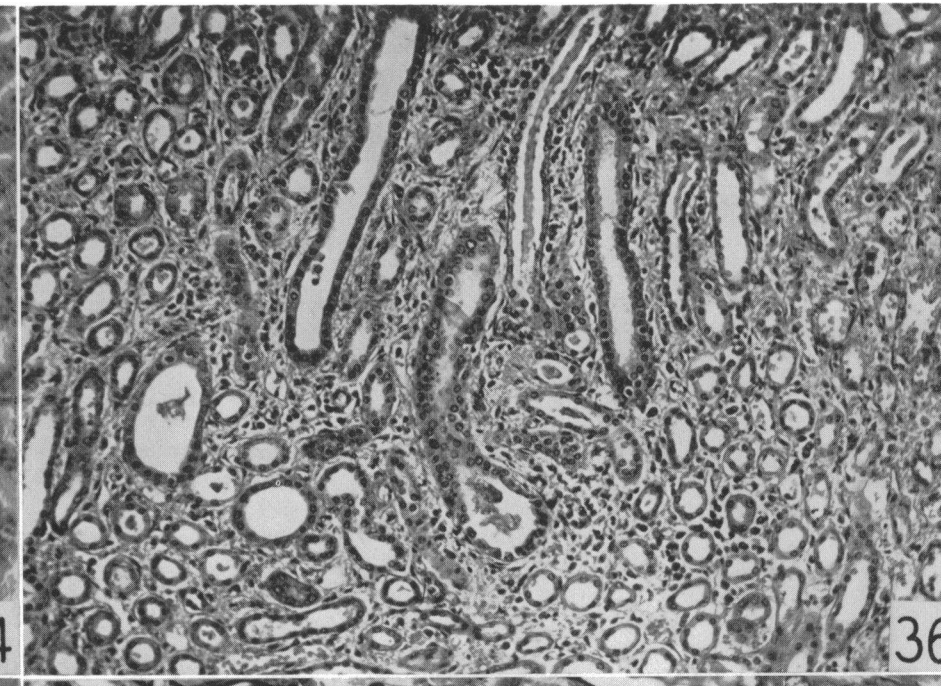
36

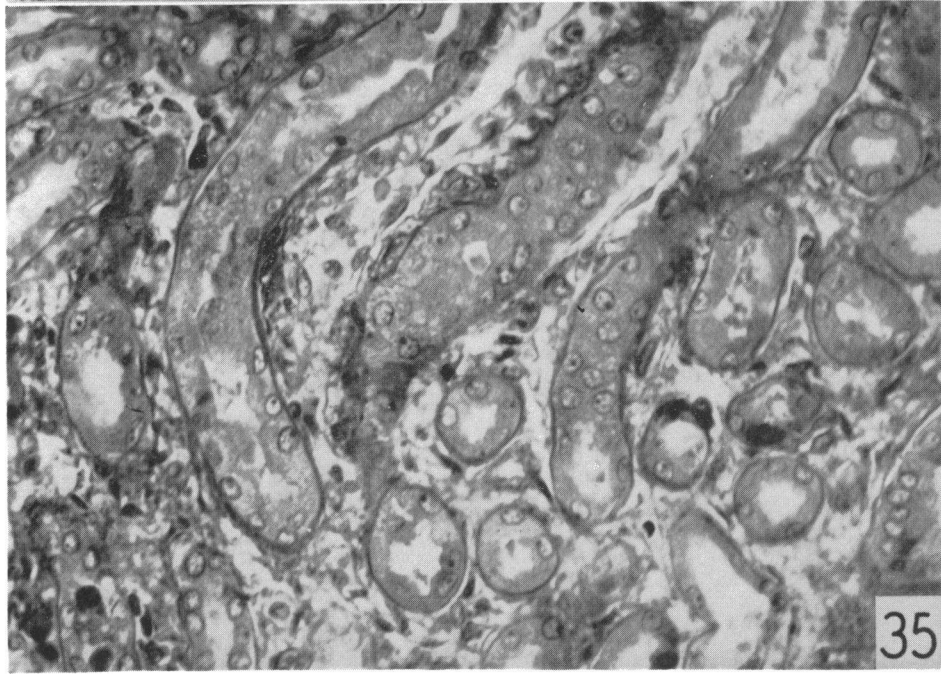
35

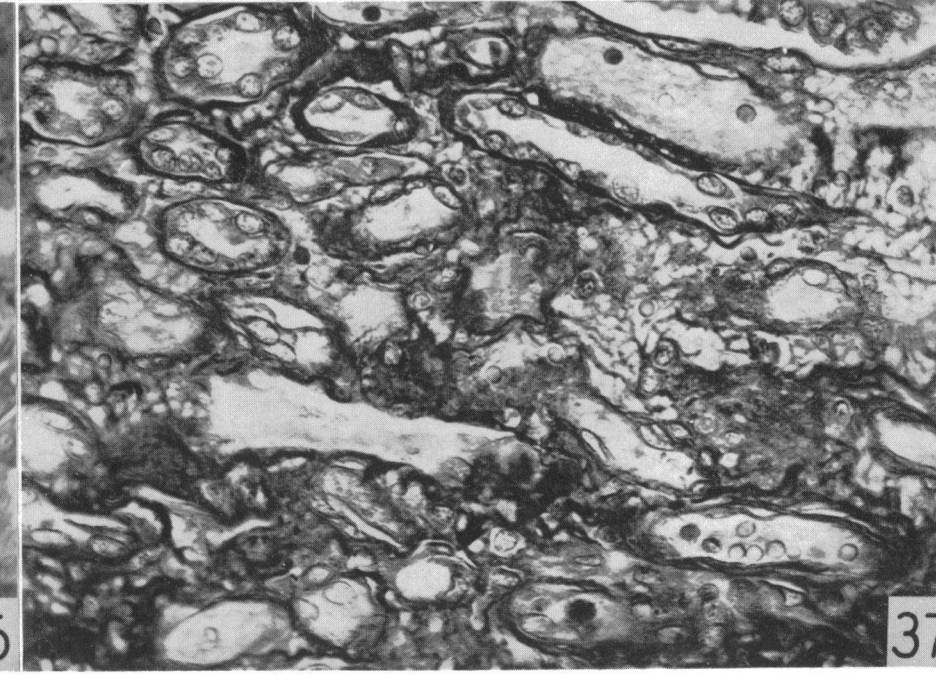
37

FIGURE 38

FIG. 38. AN EXTENSION OF FIBROUS CONNECTIVE TISSUE FROM THE SUBCORTICAL MEDULLA INTO THE LOWER CORTEX

As seen in Figure 34, the greater part of the cortex was free of any evidence of damage. Magnification 150 ×.

FIGURE 39

FIG. 39. CASE 19, DIED ON THE EIGHTEENTH DAY OF THE DISEASE AND ON THE NINTH DAY OF THE DIURETIC PHASE—AN AREA OF RESOLVED HEMORRHAGE IN THE OUTER MEDULLA SHOWING THE INCREASE IN FIBROBLASTIC CONNECTIVE TISSUE BETWEEN DISTORTED TUBULES—MAGNIFICATION 150 ×

FIGURE 40

FIG. 40. CASE 33, DIED ON THE NINETEENTH DAY OF THE DISEASE AND THE TENTH DAY OF THE DIURETIC PHASE—MID-CORTEX

Proximal convolutions are lined with a low and irregular layer of hyperplastic atypical epithelial cells. Although the lumen is consequently wide, there is no evidence of thinning of their walls from the tension of dilatation such as occurred in the Oliguric Phase (*cf.* Figure 24). Magnification 500 ×.

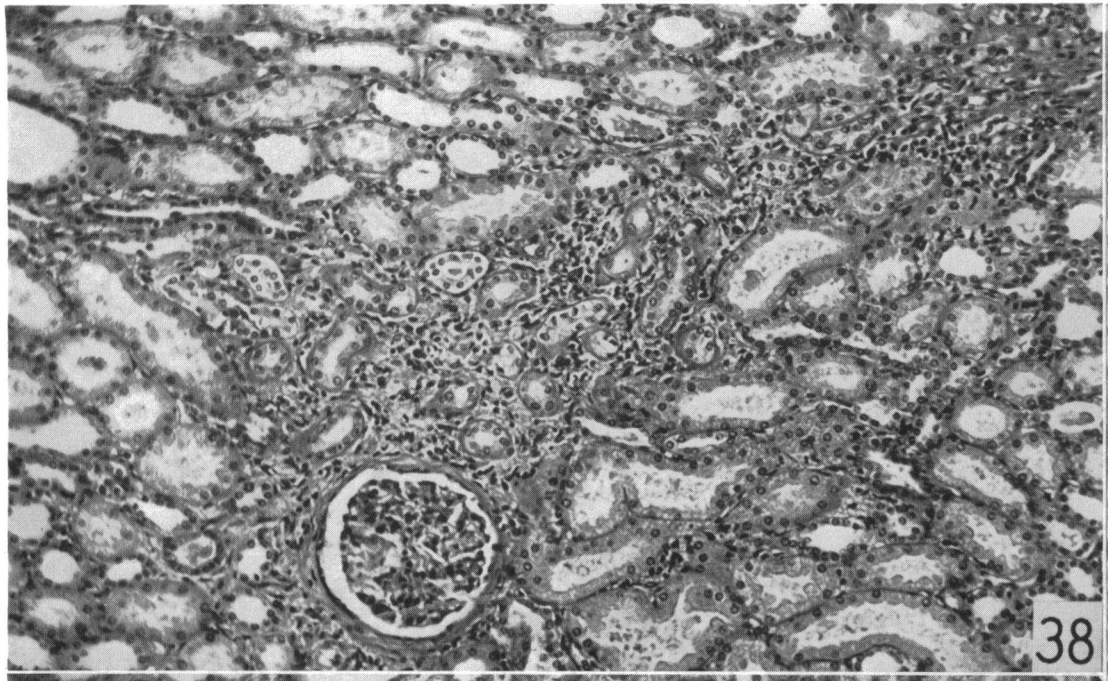
38

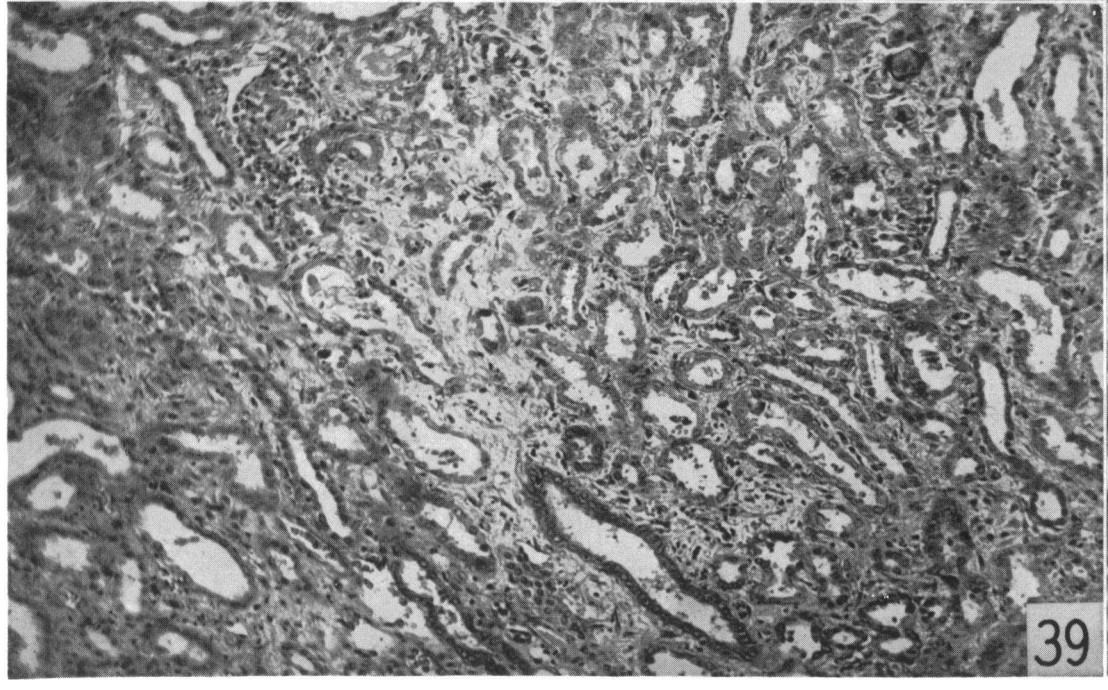
39

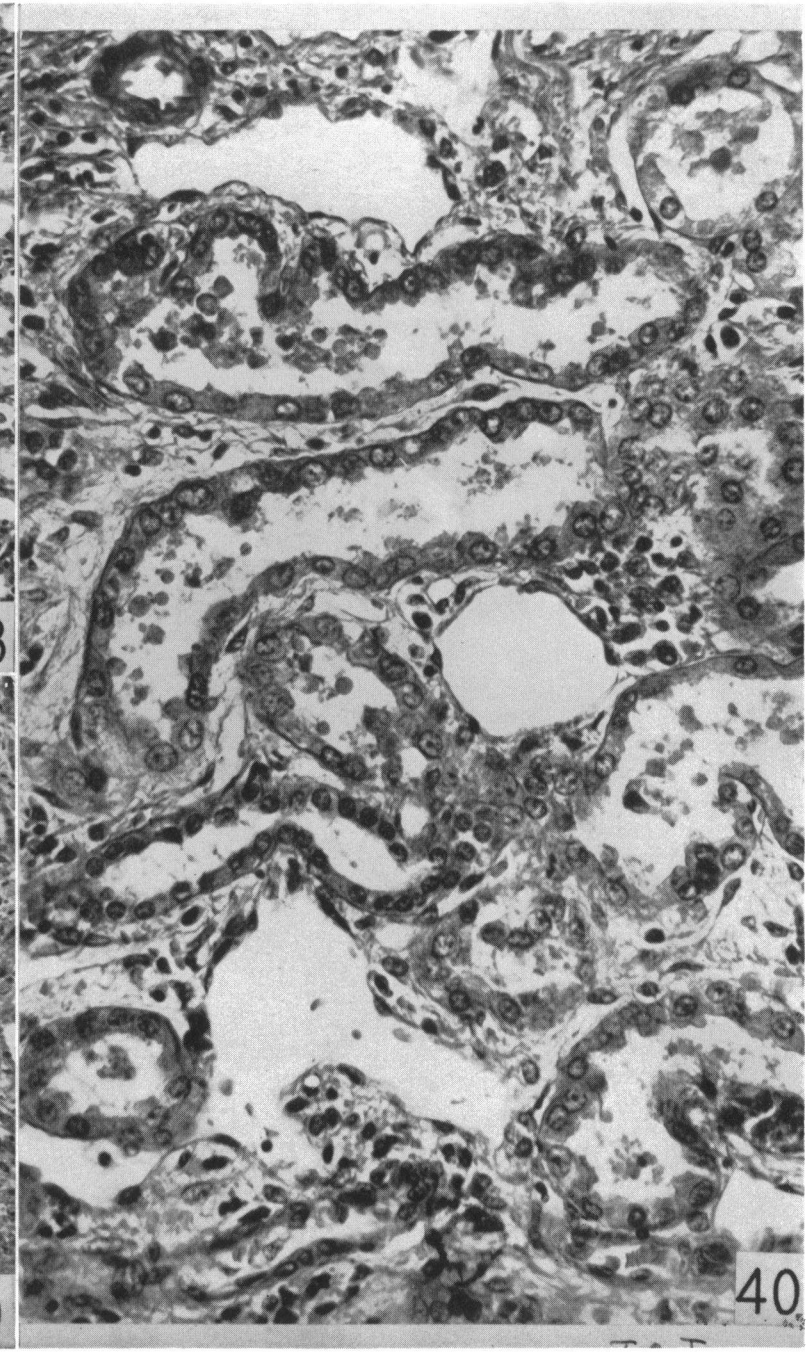
40

FIGURE 41

FIG. 41. MID-MEDULLA SHOWING AN AREA OF HEMORRHAGE SURROUNDING COLLECTING TUBULES WHICH ARE IRREGULARLY DILATED AND DISTORTED IN OUTLINE BY A MARKEDLY HYPERPLASTIC PROLIFERATION OF THEIR EPITHELIUM—MAGNIFICATION 300 ×

FIGURE 42

FIG. 42. CASE E, DIED OF CEREBRAL COMPLICATIONS 149 DAYS AFTER THE ONSET OF EHF—THE OUTER MEDULLA SHOWING AN AREA OF MODERATE FIBROSIS IN WHICH COLLECTING TUBULES ARE SEEN WITH A REDUNDANT HYPERPLASTIC EPITHELIUM—MAGNIFICATION 150 ×

FIGURE 43

FIG. 43. OUTER CORTEX

Both kidneys showed surface scarring which was more marked in the left. A long wedge-shaped fibrous scar extends from the mid-medulla to the capsule in which there is a heavy round cell infiltration and atrophy of enclosed glomeruli and tubules. Magnification 150 ×.

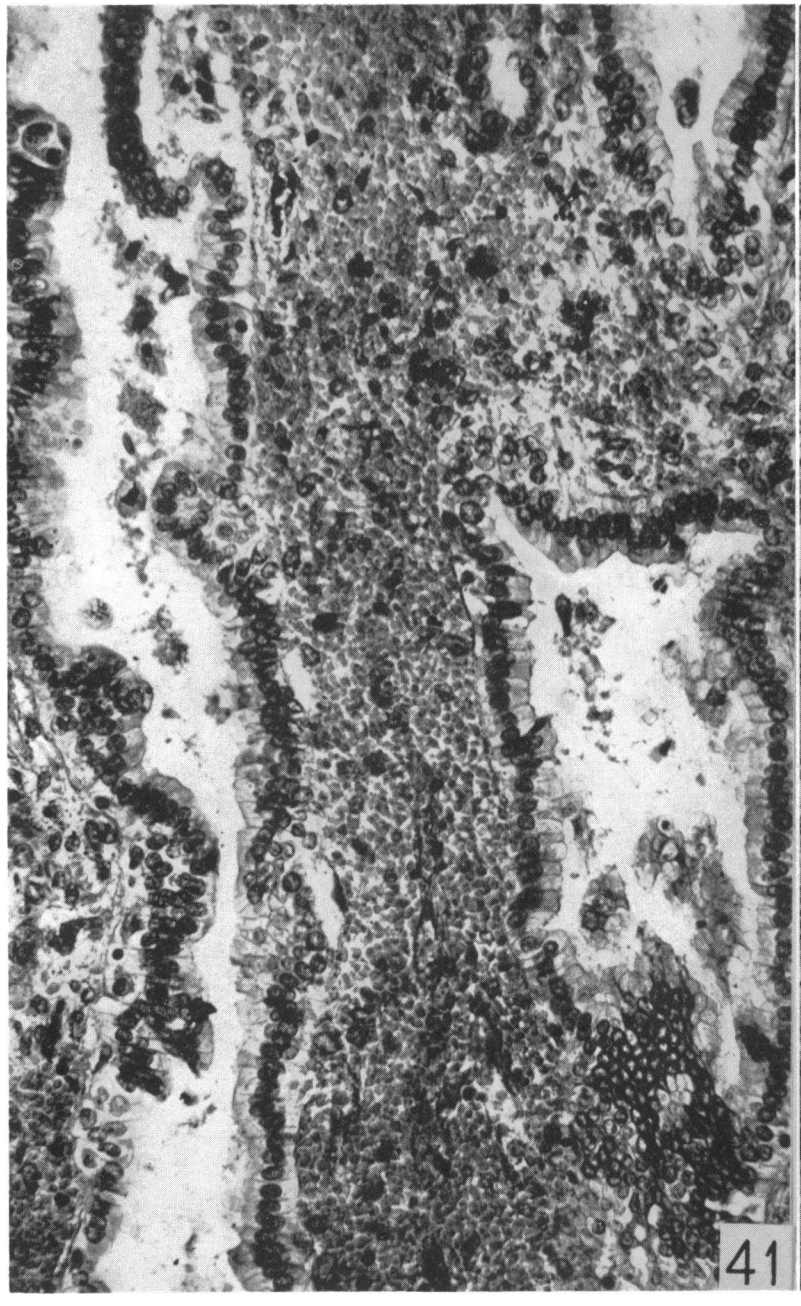
41

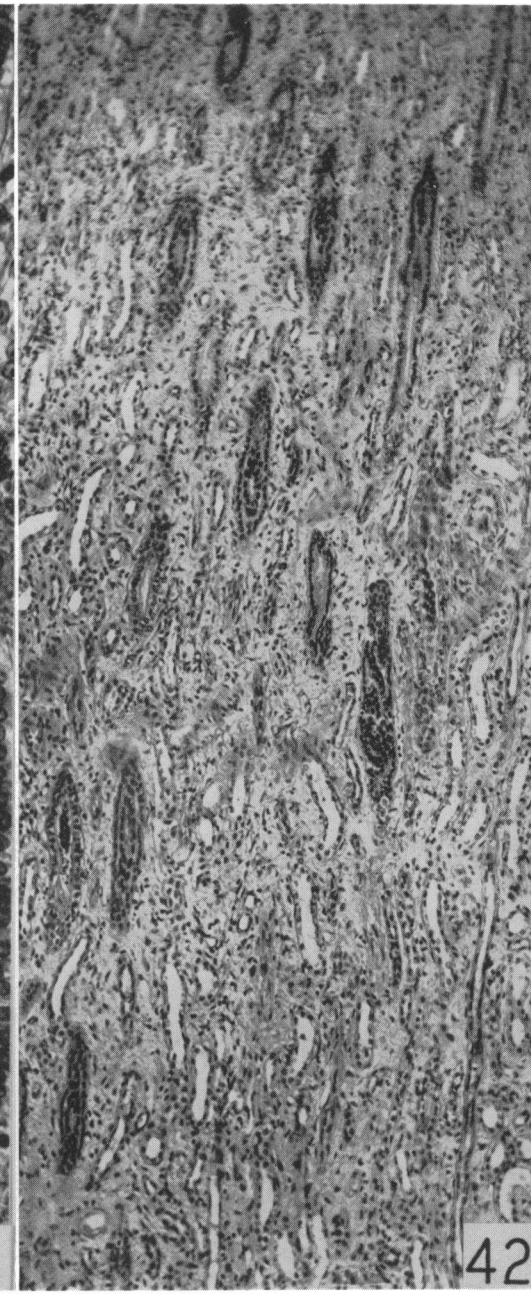
42

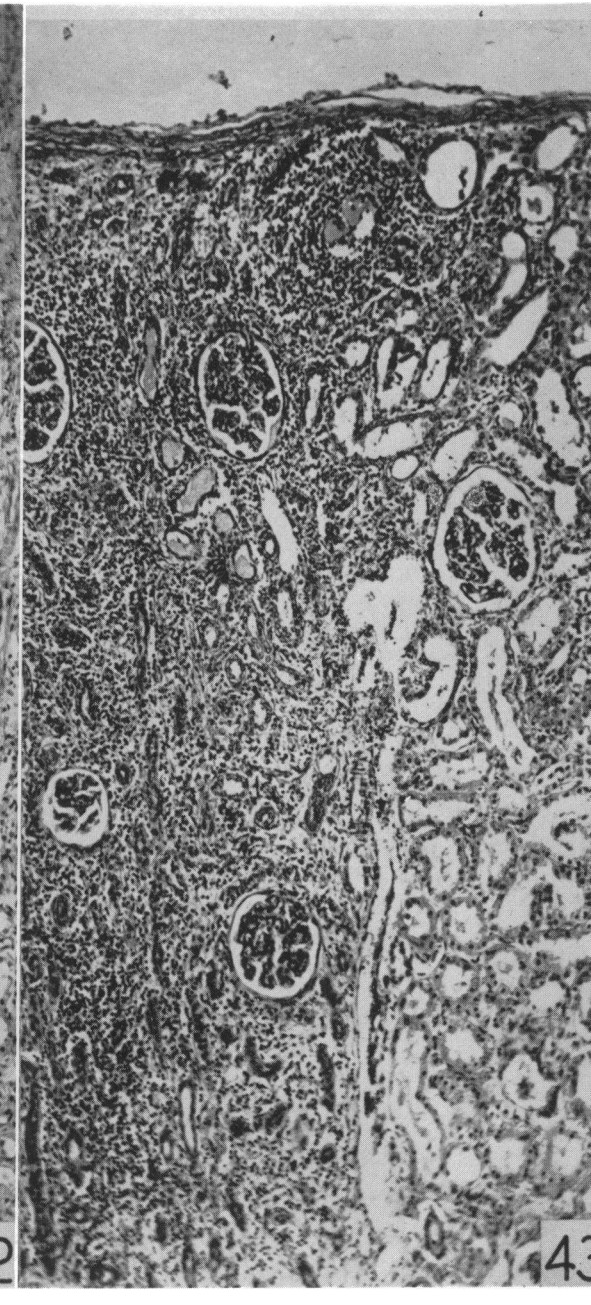
43

PLATE I (A TO F)

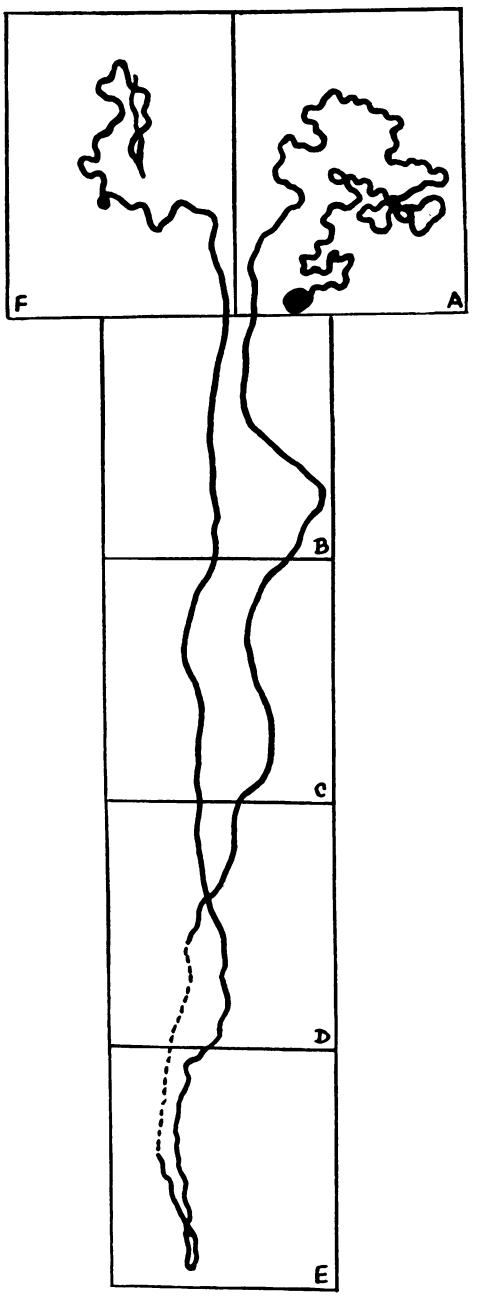

A complete nephron from Case 38. The orientation of the plates is shown in the line tracing. The alterations are so slight that this plate may be taken as showing, except where noted, the appearance of a normal dissected nephron stained with iron hematoxylin.

IA—The nuclei do not stain and so appear as clear round objects; the mitochondrial substance stains heavily, the rodlets and granules, individually invisible due to the thickness of the tubule, obscure the nuclei in the upper convolutions where, in conformity to the normal gradient, they are most concentrated. The glomerulus, dense black due to the mass of its tissue, is normal in configuration; the outline of the tuft within the capsule is faintly visible. Original magnification 200 ×, here reduced to 80 ×.

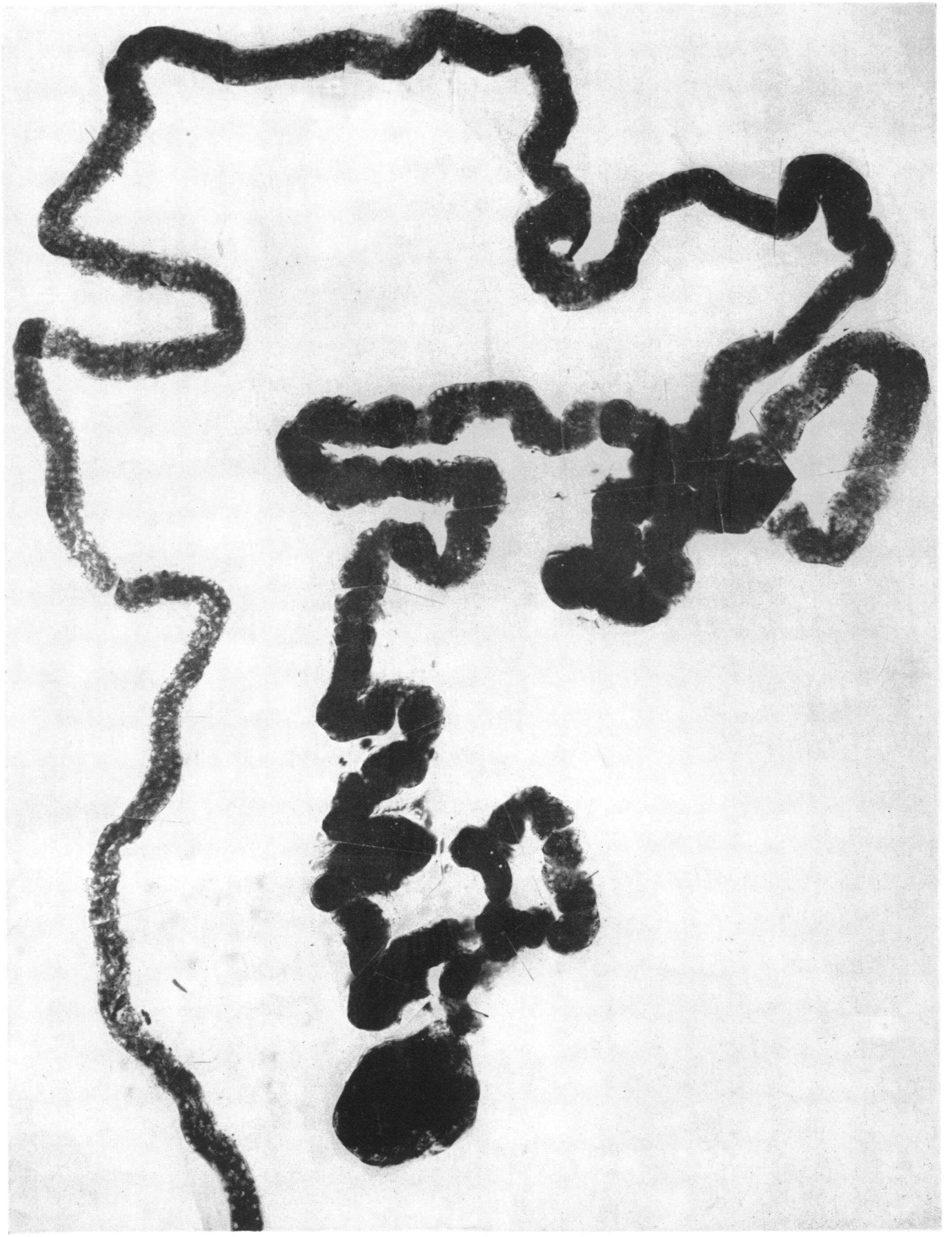

Plate IB

To the right the terminal segment of the proximal convolution. At *a,* it enters the subcortical zone of congestion. It is slightly compressed and as a result there is some irregularity of staining. To the left, the ascending limb is moderately dilated and consequently its irregularly thinned wall stains variably.

a

PLATE IC

As in IB, the middle third of the terminal segment of the proximal convolution appears more dense than normal due to the pressure of surrounding intertubular congestion.

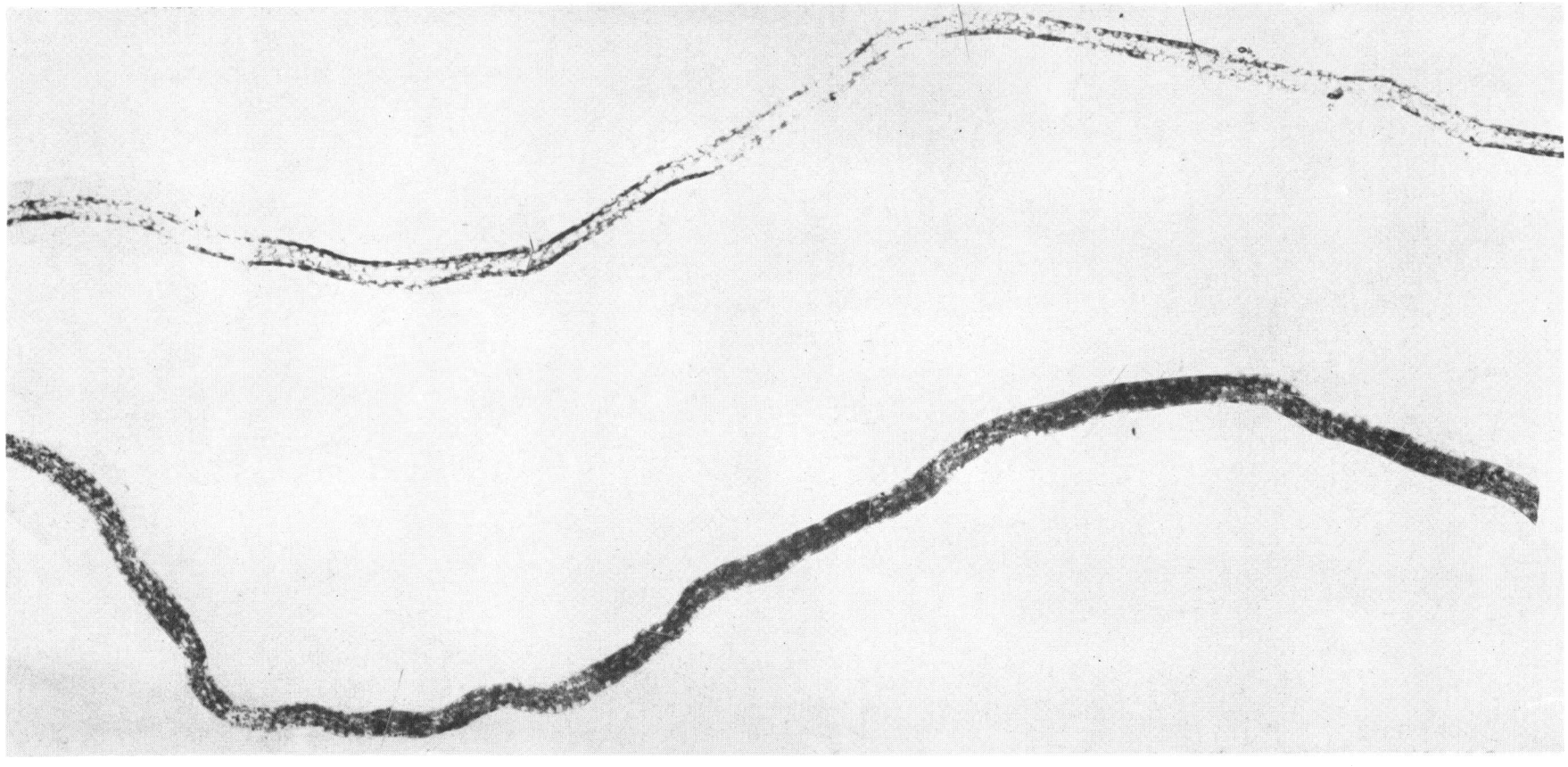

Plate ID

The termination of the proximal convolution to left; the capillary-like thin portion of Henle's loop was swept away during staining.

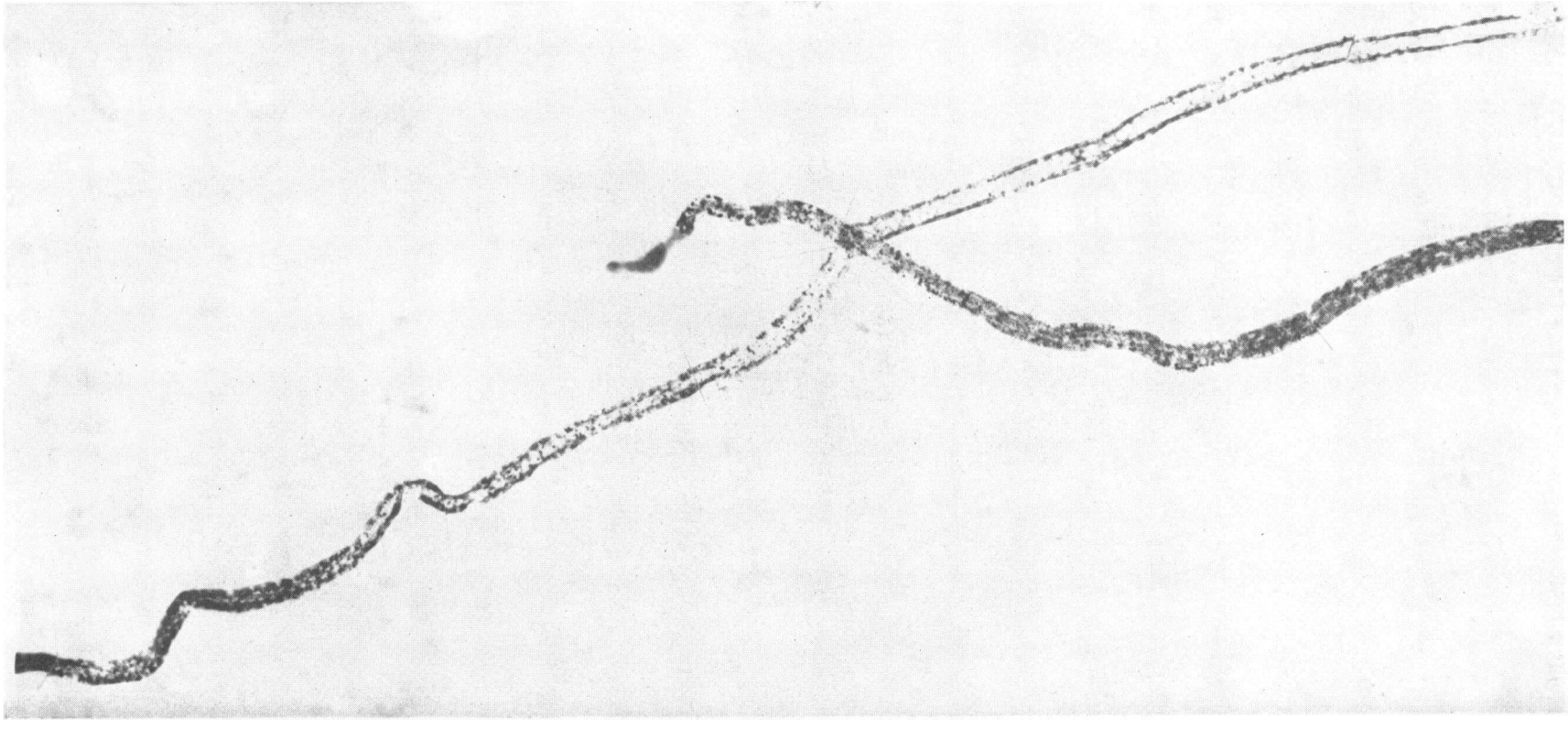

Plate IE

The loop of Henle; a remnant of the narrow portion remains and passes into the thick portion, which, still descending, turns through the loop into the broad ascending limb visible in ID, C, and B. Two small artifactual breaks are present near the loop.

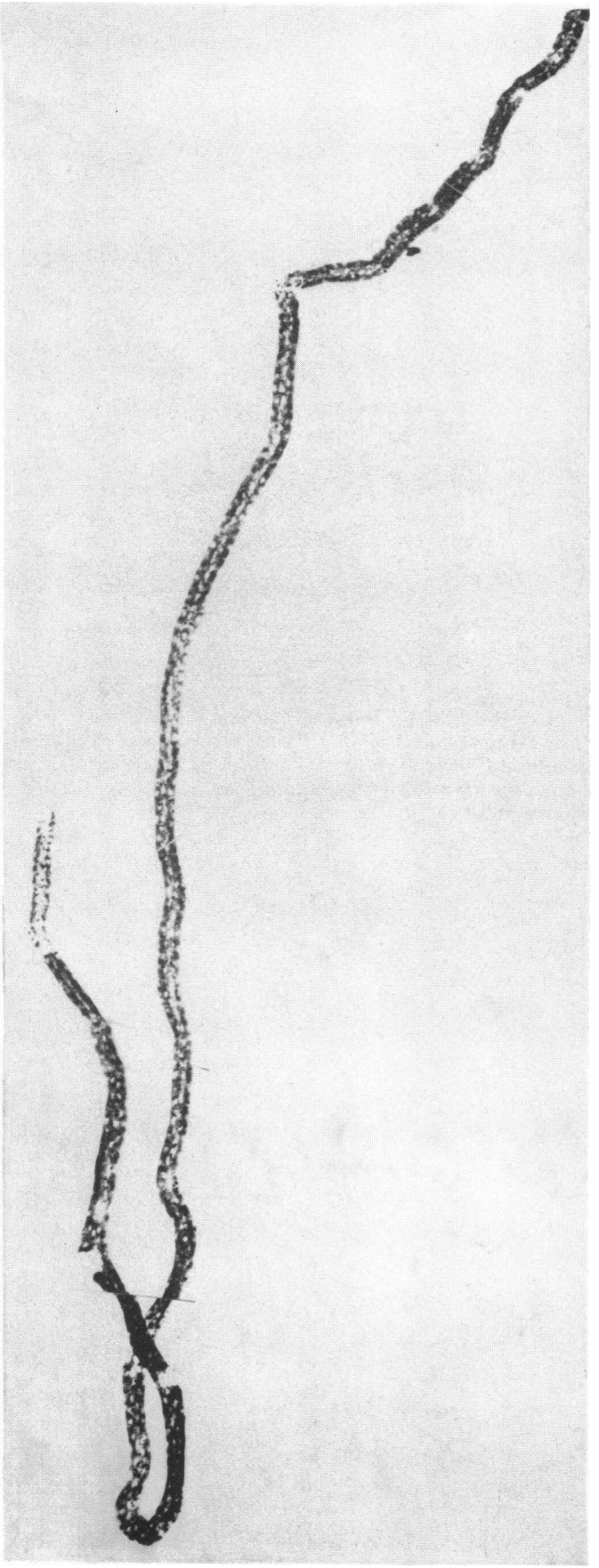

PLATE IF

Passage of the thick portion of the ascending limb into the distal convolution which lay intertwined in the proximal convolutions of IA. Except for an irregular dilatation (*cf.* Figure 1) which produces variable staining of its thin wall, the distal convolution is empty and normal in configuration. From the top of the plate the connecting tubule, not dilated, joins the origin of a peripheral collecting tubule.

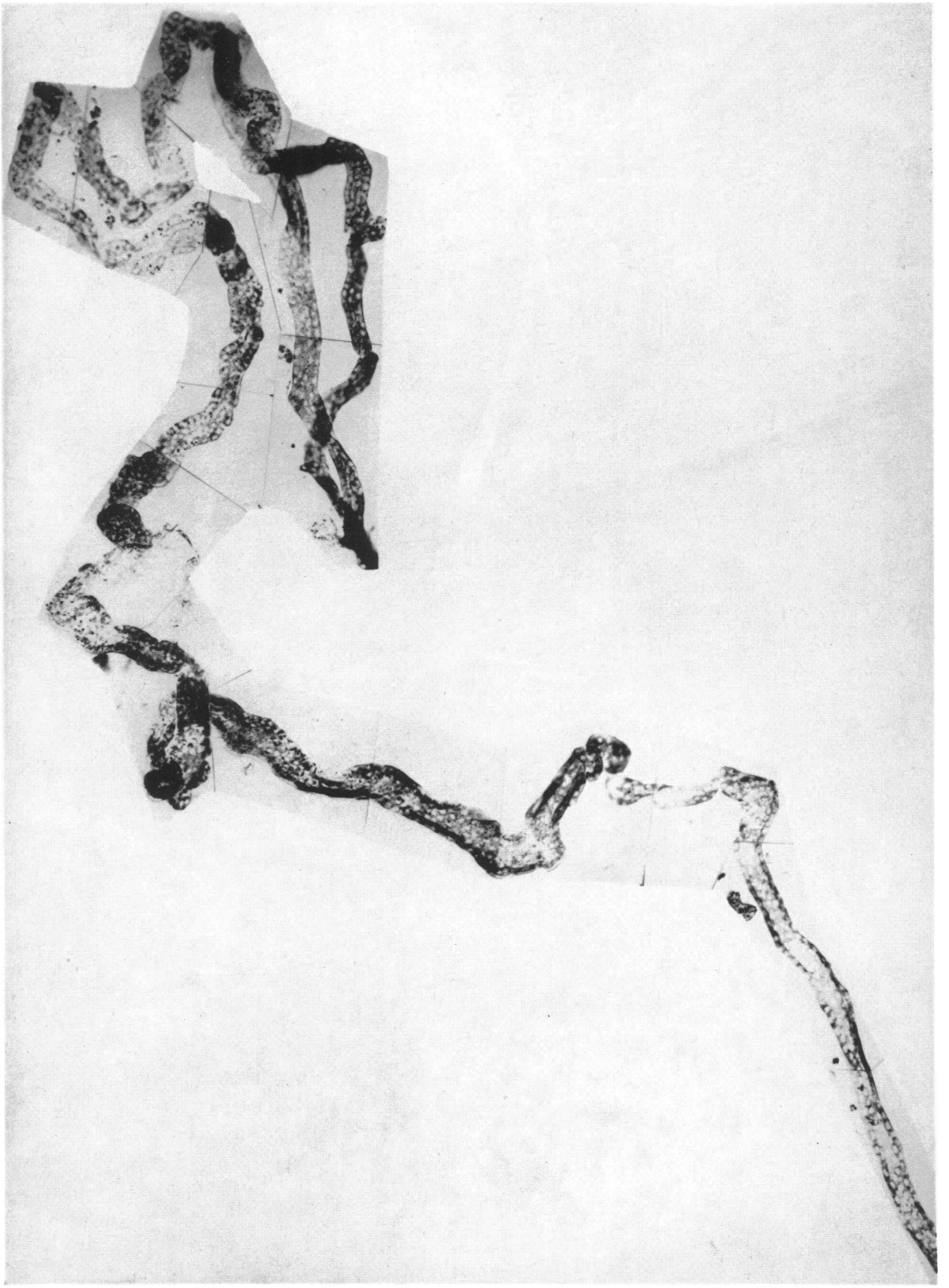

PLATE II. PORTIONS OF TERMINAL MEDULLARY SEGMENTS OF PROXIMAL CONVOLUTION WHICH LAY IN THE SUBCORTICAL ZONE

To the left can be seen the essentially normal cellular pattern of the terminal segment from the nephron of Case 38 shown in Plate I. Center, from Case 21, the tubule was surrounded by intertubular congestion. The cellular pattern is no longer visible for the compressed cells are filled with deeply stained hyaline droplets. To the right, a similar tubule from the same case. Droplets are seen throughout; in places the cell outlines filled with droplets can still be seen. At *a* the lumen is distended and filled with homogeneous lightly stained proteinaceous material. For appearance in histological section of a similar lesion, *cf.* Figure 13. Original magnification of 200 × is here reproduced.

a

PLATE III (A TO D)

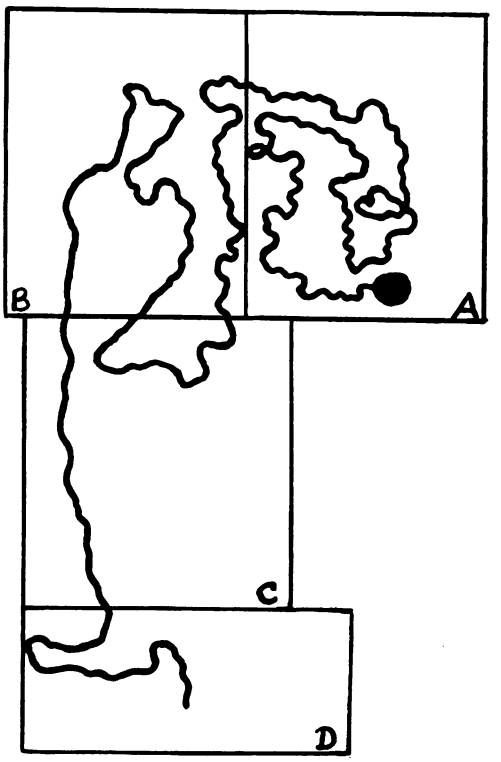

All that remained of a proximal convolution from Case 28; for orientation, see outline tracing.

IIIA. The irregularity of the glomerular contours is due to pressure of the cover glass; its configuration was normal. Beginning in the first loops of the convolution are irregular stretches of tubule (↑) showing the typical tubulorhexic disruption of anoxia; between these the tubule is better preserved. (Compare with Figures 20, 21, and contrast with Plate IA.) Original magnification of 200 ×, is here reduced to 80 ×.

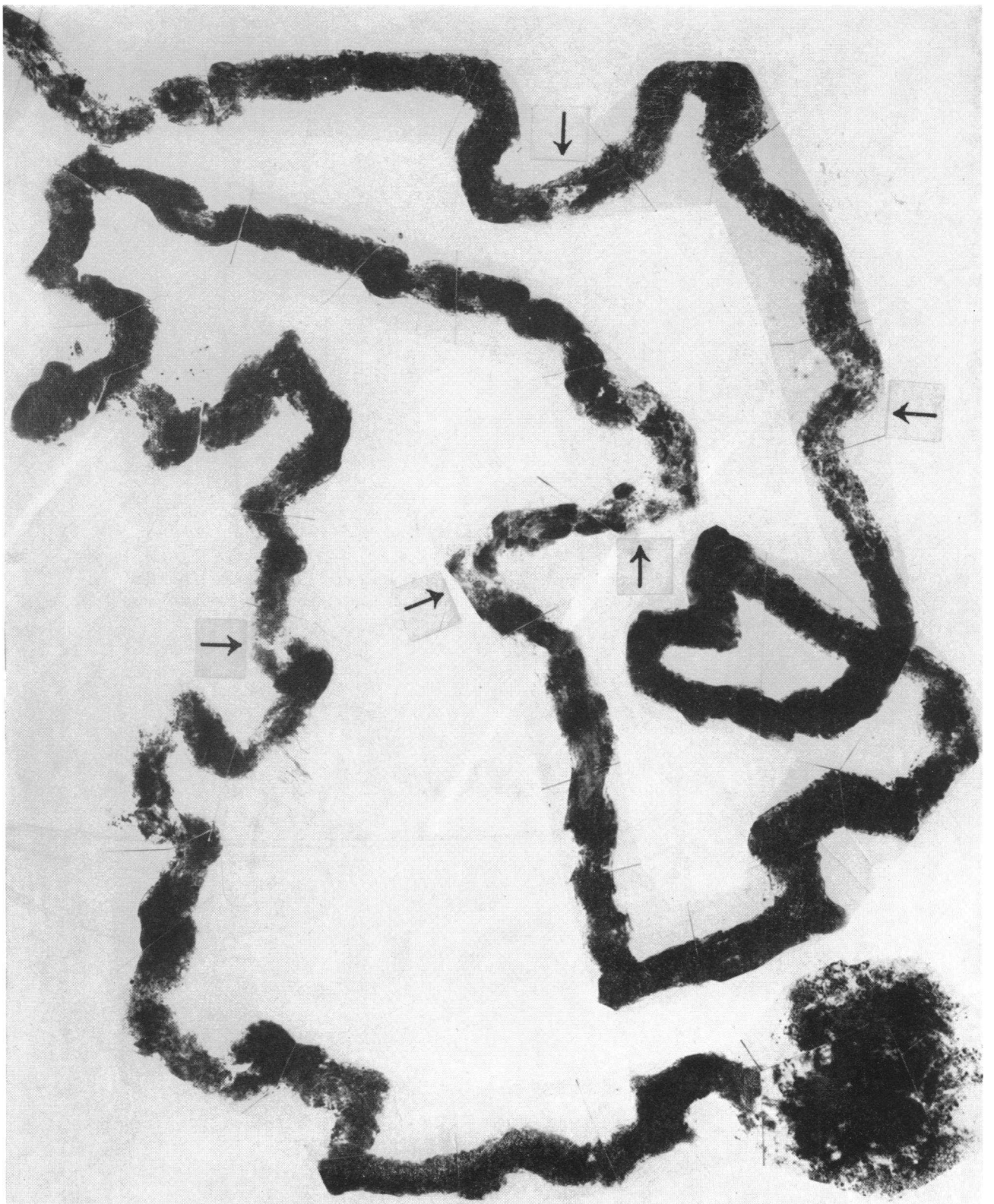

Plate IIIB

To the right, a loop of cortical proximal convolution which entered the zone of subcortical congestion and hemorrhage at *a*; to the left, loops of its medullary continuation show increasing disruptive damage.

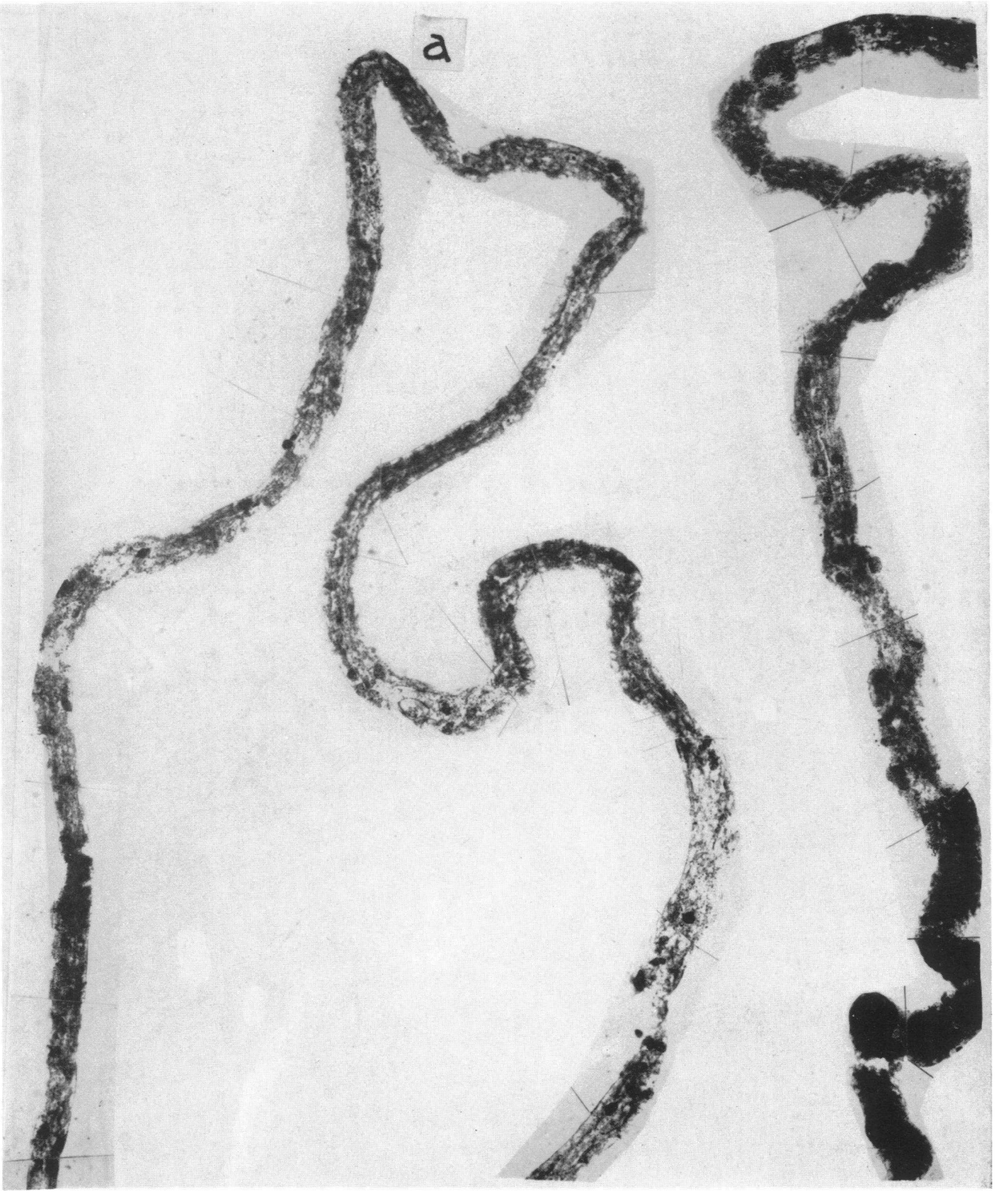
a