

# CHEMICAL, CLINICAL, AND IMMUNOLOGICAL STUDIES ON THE PRODUCTS OF HUMAN PLASMA FRACTIONATION.

## XXII. FIBRIN FILMS IN NEUROSURGERY, WITH SPECIAL REFERENCE TO THEIR USE IN THE REPAIR OF DURAL DEFECTS AND IN THE PREVENTION OF MENINGOCEREBRAL ADHESIONS<sup>1,2</sup>

BY ORVILLE T. BAILEY AND FRANC D. INGRAHAM

(From the Departments of Pathology and Surgery, Harvard Medical School, and the Surgical Services of the Peter Bent Brigham and The Children's Hospitals, Boston)

(Received for publication February 17, 1944)

The problem of repairing dural defects and of preventing adhesions between damaged cerebral cortex and adjacent tissues has never been satisfactorily solved. The question is particularly pressing at this time because of the large number of head injuries in combat which result in loss of dura and cerebral tissue. The variety of substances now in use by neurosurgeons provides good evidence that none of them is completely satisfactory. Those most widely employed have been fascia lata transplants, gutta percha sheets, preserved dura, rubber, amniotic membrane, and metals. The use of some one of these has generally been considered preferable to leaving a dural defect, although in some cases it is probable that the dural substitute is responsible for the subsequent convulsions, rather than the gliosis following or due to the injury itself.

Experimental and clinical data are presented which suggest strongly that the best solution to date for these and related neurosurgical problems is offered by the fibrin films prepared by Ferry and Morrison (1, 2) from the products of large scale plasma fractionation (3, 4).

### ANIMAL EXPERIMENTS

In order to determine what irritative effect the film might have on the normal cerebral cortex, it was implanted as a dural substitute in 6 large monkeys (*Macaca mulatta*)

<sup>1</sup> This work has been carried out under contract, recommended by the Committee on Medical Research, between the Office of Scientific Research and Development and Harvard University.

<sup>2</sup> This paper is Number 27 in the series "Studies on Plasma Proteins" from the Harvard Medical School, Boston, Massachusetts, on products developed by the Department of Physical Chemistry from blood collected by the American Red Cross.

under nembutal anesthesia. A midline incision was made in the scalp and the soft tissues reflected laterally. On the right side, an osteoplastic bone flap was turned down; on the left side, the bone was removed with rongeurs in an area corresponding in size to the bone flap (roughly  $2 \times 3.5$  cm.). The dura was removed throughout the extent of the bony opening and a piece of film, slightly larger than the defect, left *in situ*. The edges of the film were placed under the cut edge of the dura without suturing. Following this procedure, the bone flap was replaced on the right, the temporal muscle sutured over the defect on the left where a similar piece of film had been placed, and the scalp closed. The procedure was repeated in other monkeys with the following variations: (a) the cortex was traumatized by multiple needle punctures producing hemorrhages; (b) sulfadiazine was placed on both the normal and traumatized cortex before the film was implanted. These animals were observed for periods varying from 24 hours to 6 months. During this period, they were entirely free from any signs of cortical irritation or other physiological abnormalities. The monkeys were then sacrificed with an overdose of nembutal, the heads were removed, and excess tissue trimmed away. The skulls were fixed in 10 per cent formalin for 10 days in order to allow dissection of the area of operation without distortion of relationships. At the end of the period of fixation, the skull was carefully removed without opening the dura. After gross studies had been completed, blocks were selected, embedded in paraffin, and the sections stained with hematoxylin and eosin.

When the brains were studied in the gross, it was found that the films persisted for considerable periods of time. A monkey sacrificed 6 months after the implantation of film was particularly significant (Figure 1). In this animal, there were no adhesions between the cerebral cortex and the film on either side. The membrane had become incorporated as an integral part of the dura with fusion between the edges of the dura and the film so that the whole formed a continuous sheet. Figure 1 shows clearly the

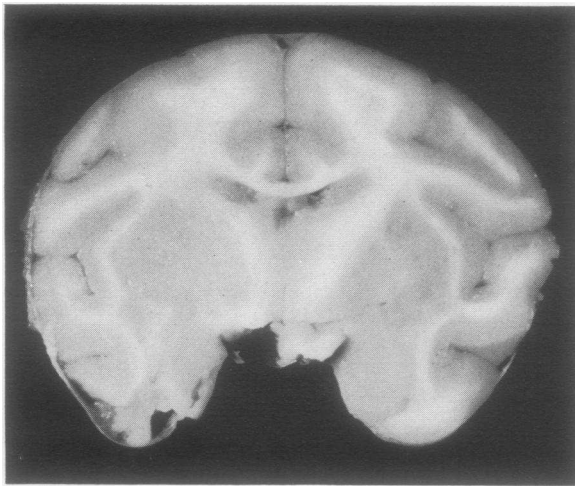

FIG. 1. CROSS SECTION OF MONKEY'S BRAIN SACRIFICED 6 MONTHS AFTER FILM WAS LEFT OVER THE CEREBRAL CORTEX TO CLOSE A DURAL DEFECT.

Notice that the film is still present. There are no adhesions between the cerebral cortex and the implanted film. The cerebral cortex appears entirely normal.

complete absence of adhesions and the normal condition of the underlying brain. Other monkeys sacrificed at shorter periods were comparable to this one.

In order to obtain a satisfactory base-line for microscopical studies, some fibrin films were fixed in formalin before implantation and stained with hematoxylin and eosin. Under these circumstances, the fibrin films appeared as uniform pink staining sheets without any trace of fibrillar structure.

In the monkeys sacrificed a short time after the films were implanted, there was a very slight infiltration with mononuclear leukocytes at the periphery of the films. Giant cells at this stage were entirely absent. The hematoxylin and eosin stain showed the same pink color of the films whether the films were in contact with living tissue or not. This was in contrast to the findings in sections stained with phloxine and methylene blue, described in the section of this paper devoted to fibrin films in human patients. The difference was regarded as dependent upon the staining technic rather than species difference. In monkeys sacrificed after 3 to 6 months, the films had become thinner and in some instances were invaded near the point of dural attachment by strands of fibrous tissue. Under

these circumstances, occasional giant cells made their appearance about isolated bits of film but there was no striking giant cell response.

When sulfadiazine was applied at the same time that the films were implanted, there was no change in the character or extent of the tissue reactions. No adhesions resulted.

#### CLINICAL USE OF FIBRIN FILMS

Fibrin films have been used to repair dural defects or placed between cortex and overlying damaged tissue, muscle, or bone in 59 patients. The material has been recovered at secondary operations in 18 instances. In the first few patients, it was used only where there were unusually large dural defects leaving the brain unprotected. In one such case, the film was recovered and replaced by a second one, as described in the following case history:

Case 1. An extremely ill 2-year-old child entered the hospital because of drowsiness and vomiting for 12 days. There was a very strong history of pica involving lead-containing paint. Physical examination indicated a pale, comatose child with right internal strabismus, marked papilledema, and cracked pot sound. Roentgenograms showed separation of the coronal sutures and typical "lead lines" in the long bones. On lumbar puncture, the cerebrospinal fluid pressure was found to be over 700 mm. of water; the total protein was 204 mgm. per cent. A diagnosis of lead encephalopathy was made and decompression done. This was accomplished by turning down an unusually large right fronto-temporo-parietal bone flap and removing the temporal bone with rongeurs. The dura was then opened widely and the ventricle tapped (spinal drainage was also continued throughout operation). The brain protruded markedly but without damage to the cortex. The large dural defect was covered with a sheet of fibrin film roughly  $10 \times 12$  cm., the bone flap left out, and the scalp closed. A week later the same procedure was performed on the left, except that on this occasion, it was possible to replace the bone flap. Eighteen days after the original operation the scalp was reflected in order to replace the first bone flap. It was thus possible to examine the original film *in situ*. There were no adhesions whatever between the film and overlying muscle or between film and cortex. This film was removed and replaced by a second similar film in order to carry out histological studies. The patient has made a very satisfactory recovery; cerebrospinal fluid pressure is normal and she has been symptom-free for one year.

Having recovered the film at reexplorations in several other patients, its use was extended to include defects which would ordinarily be covered by muscle. This group includes several sub-

occipital explorations, subtemporal decompressions, and laminectomies in which the film was left between the central nervous system tissue and adjacent muscle. The following case history will illustrate one such instance:

Case 2. A 2-5/12-year old boy was admitted with complaint of disturbance in gait. Physical examination showed signs of cervical cord compression. Lumbar puncture revealed evidence of block in the circulation of cerebrospinal fluid. On July 12, 1943, a laminectomy was performed with exposure of the spinal cord, which was markedly enlarged. A dorsal incision was made in the cord and, at a depth of 2 mm., a soft reddish-brown tumor was encountered. The incision of the cord was extended to the limits of the enlargement and a small fragment of tumor removed for histological study. A piece of fibrin film was then placed over the protruding tumor and spinal cord, the dura left open, and muscles sutured. The tumor proved to be a cellular astrocytoma. The wound was reopened 7 days later, at which time the film was easily removed, since it was not adherent to the spinal cord, tumor, or adjacent muscle. The tumor had largely extruded itself and could be almost entirely removed. It was felt that the local protection of the tissues by the film greatly facilitated the second stage. In order to leave as much room as possible in case of recurrence, the dura was again left open and a second piece of film left over the cord. At the present time, there is no perceptible interference with function.

Material for study of the tissue reactions of fibrin films in human patients was available in 18 instances. These films were removed at secondary operations from 14 hours to 81 days after the film had been left in place. Blocks were fixed in Zenker's fluid, embedded in paraffin, and the sections stained with phloxine and methylene blue. Films prepared for study by this technic, without implantation, were seen on microscopical study as uniform deep blue sheets. In the specimen obtained at 14 hours, the only change noted was the slight alteration in staining reaction at the periphery where the film was in contact with the tissues of the patient (Figure 2). This portion took the phloxine stain for a very narrow zone where the film was in contact with living tissue, while all the rest was uniform deep blue. In specimens removed after longer intervals, the same staining reaction was present,—the film was deep blue where not in contact with the tissues and red for a narrow zone where it was. This difference in staining reaction was not apparent when the tissues were stained with hematoxylin and eosin.

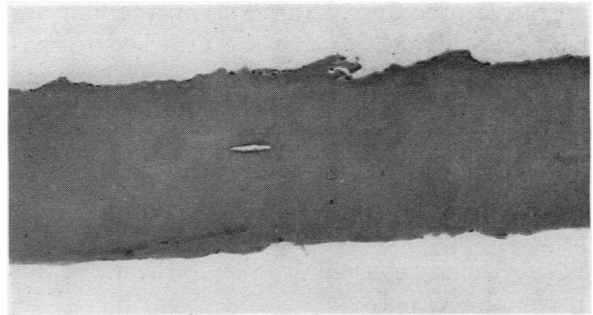


FIG. 2. LOW POWER PHOTOMICROGRAPH OF A FILM WHICH HAD BEEN IN PLACE OVER THE CEREBRAL CORTEX OF A HUMAN PATIENT FOR 14 HOURS

The homogeneous character of the film is indicated.

In specimens obtained 3 to 19 days after the films had been left in place, there was some aligning of fibrous tissue along the periphery, together with a slight infiltration with mononuclear cells and lymphocytes but polymorphonuclear leukocytes were rare. At the longer intervals, some infiltration of the film by connective tissue was noted. The specimens obtained after 81 days showed a continuation of these processes. There was a layer of fibrous tissue about the same width as the original film. Within this layer, there were scattered masses of fragmented film still present. About these bits of film were a few mononuclear cells and lymphocytes, and occasional giant cells were found about minute fragments of the film.

#### COMMENT

The problem of providing a dural substitute and of introducing a protective layer between tissues of the central nervous system and adjacent mesenchymal tissue is an extremely difficult one. Any material offered as a solution must be subjected to critical examination over a long period of time. The fibrin film used in the above animal experiments and in clinical problems would thus far seem to have distinct advantages over the substances previously available. It is transparent, flexible, easily cut, and can be placed to conform with a rounded surface. With reasonable care, it can be sutured to the surrounding dura or simply pressed under its free margin. If secondary exploration should be necessary, the film can be readily stripped out from the place where it was left, thus facilitating the identification of layers and shortening the

operative procedure. In addition, the film has whatever advantages may be attached to materials of human origin. There has been no physiological evidence of irritative phenomena either in the experimental animals or in the human patients. The gross anatomical study emphasizes the lack of adhesions between the film and adjacent tissues. The histological study did not reveal any contraindication to the use of this material. When sulfadiazine was placed in wounds where film had been implanted, the properties of the film were not altered and no irritative phenomena resulted. The gross and microscopical appearance after intervals were comparable to those in wounds in which film was implanted without sulfadiazine.

The films used in the patients reported in this paper have all been of the type which has been described by Ferry and Morrison (1). This is a tough and rubbery film which seems to possess the physical properties desirable in a dural substitute. However, the physical properties of the fibrin films can be varied over a considerable range by small alterations in the technic of their preparation. Should subsequent experience indicate that different physical properties were preferable in certain locations, films with these characteristics could be readily prepared.

From the information at hand, the fibrin films would seem to be definitely superior to metal foil, preserved dura, fascia lata, rubber, gutta percha, or amniotic membrane.

Additional illustration and discussion of the use of fibrin films has been presented elsewhere (5).

#### SUMMARY

Fibrin films have been tested as a protective layer for the central nervous system in a series of monkeys and patients.

These materials have been found very satisfactory for the repair of dural defects and the prevention of adhesions between damaged nervous tissue and adjacent structures.

#### BIBLIOGRAPHY

1. Ferry, J. D., and Morrison, P. R., Chemical, clinical, and immunological studies on the products of human plasma fractionation. XVI. Fibrin clots, fibrin films, and fibrinogen plastics. *J. Clin. Invest.*, 1944, **23**, 566.
2. Morrison, P. R., and Singer, M., Chemical, clinical, and immunological studies on the products of human plasma fractionation. XVII. A note on the absorption rates of fibrin films in tissue. *J. Clin. Invest.*, 1944, **23**, 573.
3. Cohn, E. J., Oncley, J. L., Strong, L. E., Hughes, W. L., Jr., and Armstrong, S. H., Jr., Chemical, clinical, and immunological studies on the products of human plasma fractionation. I. The characterization of the protein fractions of human plasma. *J. Clin. Invest.*, 1944, **23**, 417.
4. Edsall, J. T., Ferry, R. M., and Armstrong, S. H., Jr., Chemical, clinical, and immunological studies on the products of human plasma fractionation. XV. The proteins concerned in the blood coagulation mechanism. *J. Clin. Invest.*, 1944, **23**, 557.
5. Ingraham, F. D., and Bailey, O. T., The use of products prepared from human fibrinogen and human thrombin in neurosurgery. Fibrin foams as hemostatic agents; fibrin films in repair of dural defects and in prevention of meningocerebral adhesions. *J. Neurosurg.*, 1944, **1**, 23.