

## THE HEART IN THYROID DISEASE. II. THE EFFECT OF THYROIDECTOMY ON THE ELECTROCARDIOGRAM<sup>1</sup>

By EDWARD ROSE, FRANCIS C. WOOD AND ALEXANDER MARGOLIES

(From the Thyroid Clinic and the Robinette Foundation, Hospital of the University of Pennsylvania, Philadelphia)

(Received for publication March 28, 1935)

The purpose of these observations has been to determine (1) what abnormalities, if any, occur in the electrocardiograms of persons with either toxic or non-toxic goiter; and (2) the electrocardiographic effect of partial or subtotal thyroidectomy in the same subjects. The plan of study has been described in a previous communication (1).

This report is based on a study of preoperative and postoperative electrocardiograms in 106 patients: 27 with non-toxic goiter, 20 with toxic nodular goiter, and 59 with toxic diffuse goiter. The records of 31 other patients were excluded because the electrocardiographic data were incomplete or because digitalis had been administered when one or more of the electrocardiograms were made.

The electrocardiograms were accurately standardized (1 cm. = 1 millivolt). Overshooting was avoided. All tracings were taken with immersion electrodes with the patient sitting. Comparison of skin resistances at the times of the first and last examinations in each instance showed no marked variations and no constant direction of change. Normal tracings were differentiated from abnormal ones by the usual criteria. Any T wave in Lead I or II, one millimeter or less in height, and any QRS complex showing definite left axis deviation, were considered abnormal. Slight tremor of the string occurred in about half the thyrotoxic patients at the first examination, and in a few instances this was marked; it usually disappeared later in the course of observation. All the thyrotoxic patients were receiving iodine when the preoperative tracing was taken, and this may have tended to reduce the height of the T waves (2). In determining whether or not the electrocardiogram of any given patient had changed, alterations of less than 1 millimeter in

T waves, and of less than 5 millimeters in QRS complexes, were not considered significant.

The electrocardiographic changes in hyperthyroidism have been considered at length in the literature. The most important contributions are those of Krumbhaar (3); Hamburger, Lev, Priest, and Howard (2); Jonás and Wichterlová (4); Coelho (5); Goodall and Rogers (6); Gossels (7); Willius, Boothby, and Wilson (8); Smith and Colvin (9); White and Aub (10); and Don and Langley (11). Don and Langley report studies similar to those described here. Some writers (3, 12, 13) believe that the electrocardiogram in hyperthyroidism is usually characteristic with large P and T waves. Others (9, 10, 14) disagree with this view and state that the T waves may be large, small or inverted and bear no relation to the degree of toxicity. Similar disagreement is found with regard to the effects of treatment. Thus Hamburger and his co-workers (2) state that relief of hyperthyroidism is usually accompanied by reduction in the height of the T waves, while Don and Langley (11) could find no relation between reduction of the basal metabolic rate and changes in P and T waves.

Table I contains a classification of the electrocardiograms in patients with various types of goiter and the changes which occurred in them after thyroidectomy.

*P waves.* Twenty-five of the 79 toxic cases had P waves 3 mm. or more in height in one or more leads at the preoperative examination. All but 4 of these showed a reduction to less than 3 mm. at the last examination. Two of these 4 were incompletely relieved of their thyrotoxicosis; the third had hypertension; and the fourth, mitral stenosis. In no instance did normal P waves in a preoperative tracing increase to abnormal height at the last examination. One patient in the non-toxic group had a P wave 3 mm. high before operation, which was reduced to 2 mm. at the last examination. The T waves in this case were of

<sup>1</sup> Presented in abstract before the Section on General Medicine, College of Physicians of Philadelphia, April 23, 1934.

TABLE I

*Classification of electrocardiographic abnormalities in various types of goiter*

Types of goiter.....	Non-toxic					Toxic nodular					Toxic diffuse					
	A*	B*	C*	D*	Total	A	B	C	D	Total	A	B	C	D	Total	Total toxic
Number of patients.....	16	0	4	7	27	11	2	2	5	20	33	11	9	6	59	79
P wave 3 mm. or higher.....				1	1	5				5	8	4	6	2	20	25
QRS complexes increased in size immediately after operation.....					0					0	3	1			4	4
All QRS complexes smaller at last examination than at first.....	1				1					0	6	3	1	1	11	11
Shift of electrical axis toward the left from first to last examination.....	1		1	2	4	6	1	1	1	9	18	7	5	1	31	40
T waves 4 mm. or higher at first examination.....	3			3	6	4	1		1	6	8	4		1	13	19
T waves increased in size immediately after operation.....			1	1	1			1	1	2	8	3	5	2	18	20
Slight temporary reduction of T waves after operation.....	5		1	1	7	4		1	1	6	4	3		2	9	15
Temporary reduction of T waves to abnormal degree after operation.....	3				3	2				2	6	2	2	1	11	13
T waves smaller at last examination than at first.....	1			1	2	4	2			6	6	5			11	17
T waves larger at last examination than at first.....	2		4		6	3		2		5	4		4	1	9	14
T waves 4 mm. or higher at last examination.....	3†			3‡	6	3§			1	4	6	2¶	2		10	14

\* A—Normal at first and last examination.

B—Normal at first and abnormal at last examination.

C—Abnormal at first and normal at last examination.

D—Abnormal at first and abnormal at last examination.

† Present at first examination in 1 case.

‡ Present at first examination in all cases.

§ Present at first examination in 2 cases.

|| Present at first examination in 4 cases.

¶ Present at first examination in 1 case.

very low amplitude throughout, but there was no other evidence of cardiovascular disease, and nothing to indicate thyrotoxicosis. One thyrotoxic patient, whose other tracings were normal, showed inverted P waves in all leads at her last examination.

Auricular flutter was present before operation in one thyrotoxic patient; this was followed immediately after operation by auricular fibrillation. Normal rhythm was subsequently established. Auricular fibrillation was present in 12 other cases of hyperthyroidism. In 2 it was a temporary postoperative phenomenon. In 10 it was present at the first examination: in 7 of these it disappeared soon after operation, and in the other 3 it has persisted.

*P-R interval.* A minor grade of heart block was present throughout the period of observation in one non-toxic patient ( $P-R$  interval = 0.24 second). No other instance of disturbed auriculo-ventricular conduction was observed.

*QRS complexes.* Four toxic patients showed a temporary postoperative increase in the size of their QRS complexes. This was not seen in any

of the non-toxic group. In 11 of the toxic patients, the QRS complexes were definitely smaller in all leads at the last examination than at the first. This occurred in one of the non-toxic group. One toxic patient showed an excessively high complex before operation, which was later reduced to normal. In another instance left axis deviation appeared six months after operation but had disappeared one year after operation. One thyrotoxic woman, aged 29, showed a right bundle branch defect (new nomenclature) throughout the period of observation (3 years) and has shown no other evidence of cardiovascular disease.

The variations of the QRS complex described above were relatively infrequent, and their significance is difficult to determine. However, a definite shift of the electrical axis toward the left from the first to the last examination was noted in 40 (51 per cent) of the 79 toxic cases, and in only 4 (15 per cent) of the 27 non-toxic patients. When this tendency was first noted, it was believed to be due to increase in body weight following postoperative reduction of the basal metabolic rate. This explanation, however, is not supported

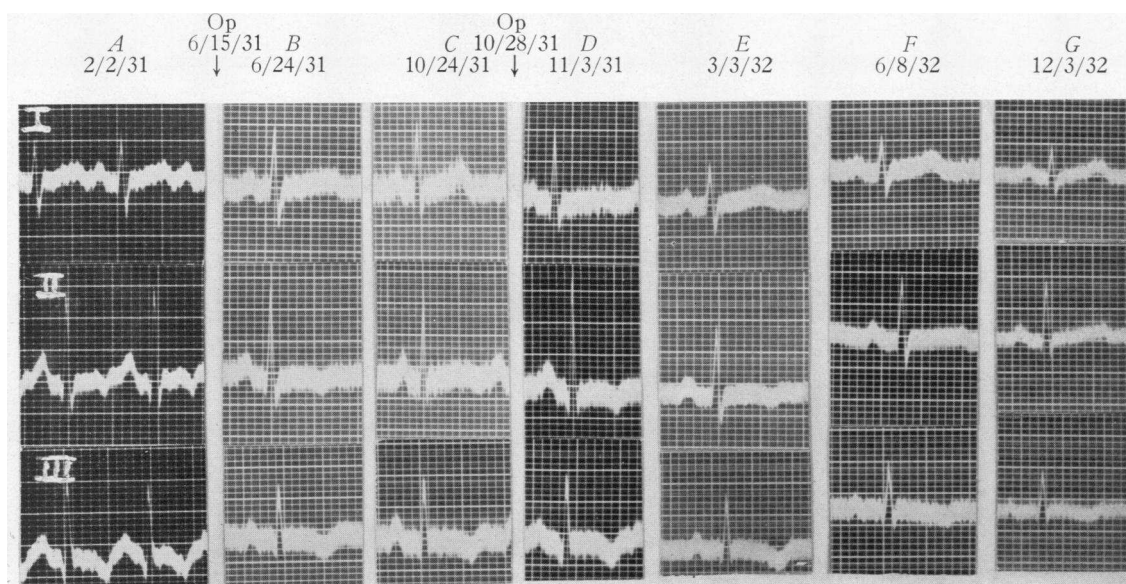


FIG. I. ELECTROCARDIOGRAMS OF V.O., A WOMAN OF 23 YEARS, WHO HAD A TOXIC DIFFUSE GOITER, DURATION 6 WEEKS, BASAL METABOLISM BEFORE OPERATION (JUNE 14, 1931) + 56 PER CENT.

Right lobectomy June 15, 1931. Left lobectomy October 28, 1931. Last basal metabolism on August 10, 1932 was + 18 per cent.

This figure shows:

(1) Marked changes in T waves.  $T_2$  was inverted February 2, 1931, less inverted June 24, 1931, upright October 24, 1931, inverted once more November 3, 1931, less inverted March 3, 1932, upright June 8, 1932, upright December 3, 1932.

(2) Shift of the electrical axis to the left (patient gained 7 lbs.). Index on February 2, 1931 = -8. Index on December 3, 1932 = -3.

(3) P waves were large at first and subsequently reduced in size.

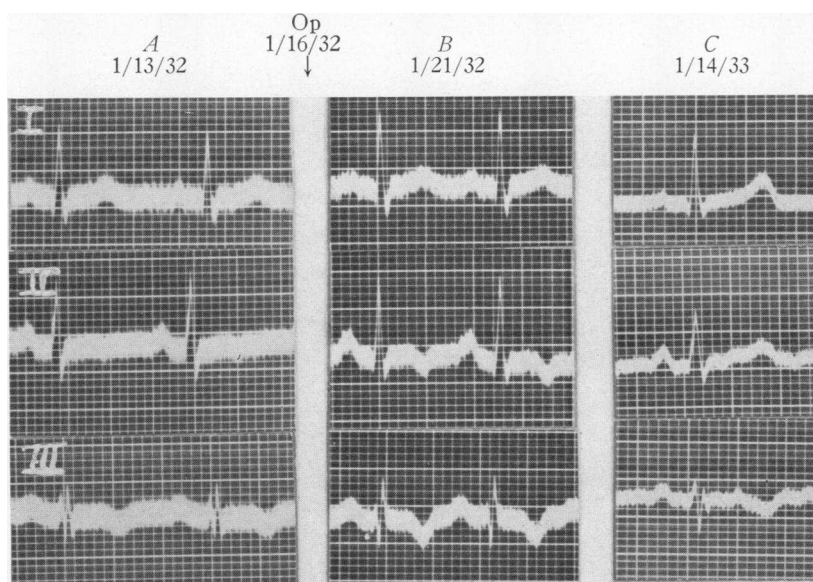


FIG. II. ELECTROCARDIOGRAM OF B.S., A WOMAN OF 33 YEARS, WITH A NON-TOXIC NODULAR GOITER

Thyroidectomy was done on January 16, 1932.

This figure shows that marked changes may occur in the T waves of a non-toxic patient. On January 13, 1932,  $T_2$  was slightly inverted. On January 21, 1932, five days after operation,  $T_2$  was more deeply inverted. On January 14, 1933,  $T_2$  was normal. She had received no digitalis.

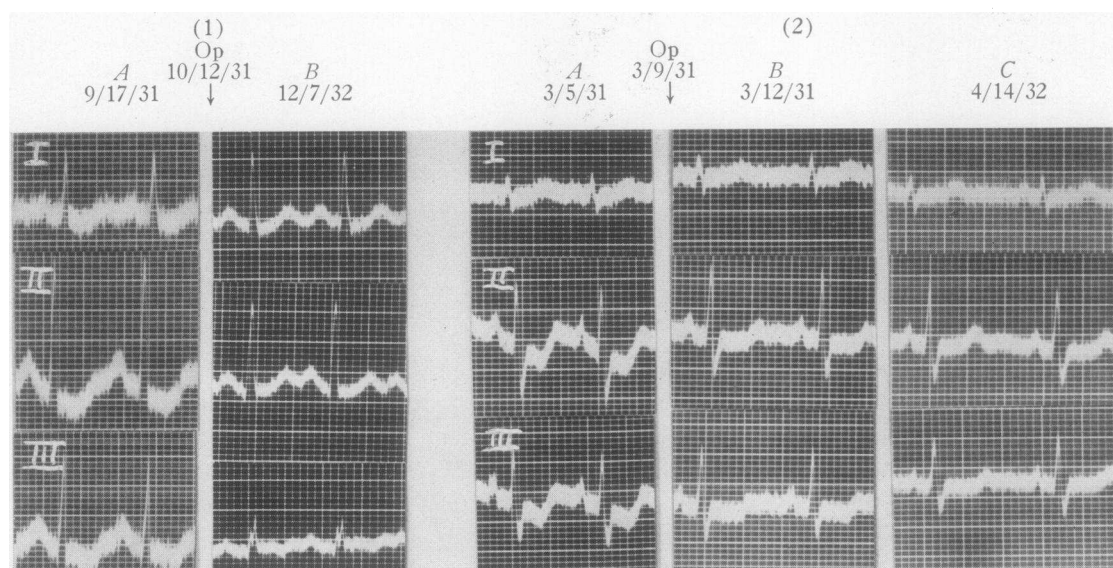


FIG. III. THIS FIGURE SHOWS R S-T INTERVAL DEVIATIONS IN (1) A TOXIC PATIENT AND IN (2) A PATIENT WITH A NON-TOXIC NODULAR GOITER.

(1) Electrocardiograms of J.R., a woman of 30 years, who had a toxic diffuse goiter, duration 4 years; basal metabolism before operation (September 22, 1931) + 71 per cent; basal metabolism 14½ months later (December 7, 1932), + 35 per cent.

A. First tracing September 17, 1931, heart rate 130; depression of the R S-T interval in all leads. The patient had received no digitalis. Immediately after operation (October 12, 1931) she was digitalized because of an attack of auricular fibrillation and developed deeply inverted T waves.

B. Last tracing December 7, 1932, heart rate 130. She had not received digitalis since shortly after her operation. The R S-T interval deviations had disappeared, despite the fact that the patient's thyrotoxicosis was only partially relieved by thyroidectomy.

In addition to the R S-T interval changes, this tracing shows (a) large P waves in the first tracing which became smaller in the last tracing and (b) a marked shift of the electrical axis toward the left in the last tracing, as compared with the first one, from  $-4$  to  $+5$ . (The patient gained 30 lbs.).

(2) Electrocardiograms of M.McC., a woman of 37 years, who had a non-toxic nodular goiter, duration 12 years; basal metabolism before operation (March 4, 1931) + 14 per cent; one year later + 3 per cent.

The first tracing, A, taken on March 5, 1931 showed a depression of the R S-T interval. No digitalis had been administered. The change of R S-T interval had disappeared to some extent seven days later, B. It had vanished completely one year after operation, C. The patient gained 10 lbs. during the year. The electrical axis did not change.

by more careful analysis of the data. The cases were studied with reference to (a) the changes in axis, calculated on the basis of White's (15) index,<sup>2</sup> (b) the change in body weight, and (c) any cardiovascular or other conditions which might have influenced the electrical axis. Although the largest average gain of weight occurred in the group showing shift of the axis to the left, the change in the individual case was not necessarily proportional to change in weight. In the toxic group, for example, eight cases which showed gains of 10 lbs. or less showed a definite shift of electrical axis toward the left. On the other hand, six cases which gained from 30 to 50 lbs. showed either no change or a shift to the right. This change in axis was not accompanied by any characteristic changes in the T wave in Lead III. It cannot be correlated with changes in heart rate. Moreover the cases which failed to show this phenomenon were not necessarily those whose hyperthyroidism had not been relieved by operation. Many thyrotoxic patients show prominence and increased pulsation of the pulmonary artery, which tend to disappear when the thyrotoxicosis is relieved. This phenomenon, which suggests overaction of the right ventricle in thyrotoxicosis, may be related to the change of axis under consideration. However, a review of our cases, with this thought in mind, failed to elicit corroborative data. The presence and subsequent disappearance of prominence and increased pulsation of the pulmonary artery did not occur more frequently in those groups which showed a definite shift of electrical axis to the left. There may be some relationship between these two phenomena, but our methods failed to demonstrate it. We, therefore, feel that this shift in electrical axis, which so often accompanies surgical relief from hyperthyroidism, cannot be satisfactorily explained at present.

*S-T interval.* Four patients showed deviation of the S-T interval from the isoelectric line before operation—a depression in Leads II and III in each case. This abnormality disappeared in all instances before the first postoperative tracing was taken. There was no history of administra-

tion of digitalis prior to the first electrocardiogram in any of the 4 patients. The first patient had a non-toxic goiter; the second, a toxic nodular goiter; and the third, a toxic diffuse goiter; the final tracing was normal in each instance. The fourth patient had a toxic diffuse goiter; the final tracing showed isoelectric T waves in all leads. (The third patient was digitalized after operation and does not appear in the Table.)

*T waves.* (a) *Changes at the first and last examination.* Examination of Table I will show that our findings do not support the belief that the height of the T waves is directly proportional to the degree of thyrotoxicosis. Although 17 toxic patients showed smaller T waves at the last examination than at the first, 14 showed the reverse. Two patients with postoperative hypothyroidism developed small T waves, but similar changes occurred in 8 patients who did not show postoperative thyroid deficiency. Furthermore, in 10 patients who were incompletely relieved of their thyrotoxicosis, 3 had larger T waves at the last examination than at the first, 3 had smaller T waves, and 4 showed no change in size.

The incidence of T waves 4 mm. or more in height, in both the toxic and non-toxic groups, was about the same at the first and last examinations. T waves which had been normal before operation sometimes became abnormal at the last examination, and the reverse was also occasionally noted.

(b) *Immediate postoperative changes.* These likewise seemed to follow no definite rule. Seven non-toxic and 15 toxic patients showed slight reduction in the height of the T waves in the first postoperative tracing. Three non-toxic and 13 toxic patients showed a temporary reduction after operation, sufficient to be considered abnormal. However, one non-toxic and 20 toxic patients showed an increase in the amplitude of the T waves in the first postoperative tracing. This phenomenon was slightly more common in the group which had been toxic for 2 years or more (9 of 27 cases) than in the remainder of the toxic group (11 of 52 cases). Parade and Haas (16) report inversions of T waves immediately after operation in a series of cases of hyperthyroidism but stated that their patients received verodigen 0.5 gram and quinidin 0.2 gram three times daily from the fifth day before to the third day after

<sup>2</sup> The index of shift is the figure obtained by calculating the index according to White's formula for the first and last tracings of each individual patient and subtracting the former from the latter.

operation. Kämmerer and Obermaier (17) noted T wave negativity after thyroidectomy in 20 per cent of their (toxic?) cases. In order to evaluate this phenomenon properly it would be necessary to take daily tracings after operation, which we did not do. However, the time which elapsed between operation and the taking of the first postoperative tracing in our cases did not seem to be of importance in connection with the reduction of height of the T waves. We have not been able to find any satisfactory report of cases studied after other types of operation to serve as a control series. The fact that some patients with non-toxic goiter showed T wave changes similar to those seen in the toxic group casts some doubt upon the belief that the thyrotoxicosis itself is the determining factor.

The severity of the postoperative reaction, the type of anesthetic used, the presence of substernal extension of the thyroid, the occurrence of injuries to the recurrent laryngeal nerves, and the age and sex of the patients, all bore no apparent relation to the incidence of postoperative T wave inversion in our cases. Some patients showed such inversion after only one stage of a two-stage operative procedure. One individual showed an increase in size of T waves after her second operation but not after her first.

It thus appears that, while marked T wave changes may occur immediately after partial or subtotal thyroidectomy in hyperthyroidism, they are not all of the same type; their occurrence is at present unpredictable, and they follow no apparent pattern. Similar changes occur less frequently after the removal of non-toxic goiters.

(c) *Other changes.* A few patients showed T wave changes in addition to those noted above. Two toxic male patients, aged 27 and 32, developed inverted T waves in Lead I resembling "coronary" T waves, without any other evidence of coronary occlusion. In the first case this change appeared only in the last tracing, taken 18 months after operation. In the other, it appeared only in the tracing taken 4 months after operation and had disappeared 8 months later when the final examination was made.

Two female patients, aged 27 and 38, showed abnormal T waves throughout the period of observation with no other evidence of cardiovascular disease. The first had a toxic nodular goiter: T<sub>1</sub>

was isoelectric, T<sub>2</sub> and T<sub>3</sub> inverted throughout. (This patient was followed for only seven months after operation and does not appear in the Table.) The second patient had a toxic diffuse goiter: the preoperative tracing showed T<sub>1</sub> isoelectric, T<sub>2</sub> and T<sub>3</sub> inverted. The last tracing, taken 2 years after operation, showed T<sub>1</sub> upright, T<sub>2</sub> diphasic, and T<sub>3</sub> inverted.

Two female patients, thyrotoxic and desperately ill on admission, with congestive heart failure and auricular fibrillation, showed normal electrocardiograms one year after operation. All evidence of cardiovascular disease had disappeared. The first and second tracings may have been influenced by digitalis administration during the preoperative period and cannot be accurately interpreted.

Only 3 patients in the toxic group showed no electrocardiographic changes whatever throughout the entire period of observation. One of these patients had an enlarged heart and showed auricular fibrillation throughout. Despite digitalization the T waves remained upright and unchanged in size or appearance.

It is possible that the T wave in thyrotoxic persons is subject to more frequent changes in size and shape and is more labile than in other individuals. Marked changes may appear in normal persons as a result of exercise. Thus an upright T wave may become higher immediately after exercise and be inverted ten minutes later (18). It is possible that in thyrotoxicosis with instability of the vegetative nervous mechanism the T wave may be more readily altered by psychic and physical disturbances. Further investigation is necessary to support this suggestion. Whether or not this explanation is valid, the fact remains that T wave inversion appears quite frequently as a transient phenomenon in patients with thyrotoxicosis. Consequently in this disease caution is necessary in interpreting the significance of inverted T waves. T wave abnormalities in patients with thyrotoxicosis do not necessarily indicate the presence of chronic myocardial disease.

We have been unable to find any significant relationship between electrocardiographic changes and variation in heart size in our patients. In the toxic group the smaller variations in heart size occurred without any characteristic electrocardiographic accompaniment. Those patients who showed more marked variations in size had

usually been in congestive failure and hence had received digitalis at some time during the period of observation; in their interpretation of the electrocardiograms was not possible. Most of these patients are not included in the analysis of the orthodiagraphic data. In the non-toxic group enlarged hearts were usually associated with other cardiovascular abnormalities, thus making interpretation of the tracings difficult.

Likewise no relation could be found between electrocardiographic changes and (*a*) variation in heart rate, (*b*) the degree of relief from thyrotoxicosis obtained by operation, (*c*) the duration or severity of the thyrotoxicosis, or (*d*) the age of the patients.

An attempt was made to determine the prognostic value of the electrocardiogram in patients who were to be subjected to thyroidectomy. The records of all patients who died in the hospital on all surgical services after thyroidectomy, from January, 1931, to October, 1934, were studied. There were ten such patients. Seven of these had electrocardiograms taken during the month preceding operation; all were thyrotoxic. Of these 7 cases, 5 had tracings which were within normal limits except for simple tachycardia. The sixth patient showed auricular fibrillation, the QRS and T waves being normal. The seventh showed diphasic T waves in Leads I and II.

Three of the 137 patients in our series died during the period of observation, after leaving the hospital, none as a direct result of operation. One died of "edema of the larynx" three months after operation; her electrocardiogram was normal except for transient postoperative auricular fibrillation. One died two months after operation of unknown cause; he had had auricular fibrillation throughout with flat T waves and numerous ventricular extrasystoles. The third patient (who had been in auricular flutter on admission) died one year after operation of carcinoma of the liver.

Although these facts are rather meager, they do not suggest that routine electrocardiograms *per se* have any value in determining whether thyrotoxic patients will live through (*a*) the immediate postoperative period or (*b*) the year following thyroidectomy.

Finally, we were unable to discover any tendency of the various changes in P waves, QRS

complexes or T waves, listed in Table I, to group themselves in any characteristic fashion in individual patients.

#### SUMMARY

Electrocardiographic studies have been made in 102 thyrotoxic patients and 35 patients with non-toxic goiter. These studies were made before partial or subtotal thyroidectomy and at successive intervals thereafter, up to one year in most instances. The records of 8 patients with non-toxic goiter and 27 with hyperthyroidism have been excluded from our analysis. Our findings have been analyzed with respect to the following: (1) the frequency of abnormal electrocardiograms before operation and the effect of operation upon them; (2) the occurrence of changes in the P waves, P-R interval, QRS complexes, electrical axis, S-T interval and T waves; the nature of these changes; and the effect of operation upon them; (3) the incidence of abnormalities of cardiac rhythm and the effect of operation upon them; (4) the relation between electrocardiographic abnormalities and (*a*) variations in size of the heart, (*b*) the presence of substernal goiter, (*c*) variation in heart rate, (*d*) duration and severity of thyrotoxicosis, (*e*) severity of postoperative reaction, (*f*) type of anesthesia employed, (*g*) injury to the recurrent laryngeal nerve, (*h*) degree of relief of thyrotoxicosis obtained by operation, (*i*) age, (*j*) sex and (*k*) the state of cardiac compensation.

#### CONCLUSIONS

1. Abnormal electrocardiograms occur with about the same frequency in patients with toxic and non-toxic goiter (45 and 41 per cent respectively in our series).

2. Changes in normal electrocardiograms after partial or subtotal thyroidectomy are more common in patients with hyperthyroidism than in those with non-toxic goiter (97 per cent as compared with 56 per cent in our series).

3. Large P waves (3 mm. or more in height) are common in hyperthyroidism. They are usually reduced to less than 3 mm. after successful thyroidectomy.

4. Following partial or subtotal thyroidectomy in hyperthyroidism, the electrical axis of the heart shifts to the left in about half the cases.

The cause of this shift is unknown; it is apparently not due to changes in body weight alone.

5. Marked T wave changes occur before and after thyroidectomy in hyperthyroidism, but they follow no apparent pattern, and their occurrence is unpredictable. The T waves in hyperthyroidism are not characteristically larger than normal, nor do they necessarily become reduced in size when the hyperthyroidism is relieved.

6. T wave inversion in thyrotoxicosis does not necessarily indicate the presence of chronic myocardial disease. It occurs quite frequently as a transient phenomenon.

7. The electrocardiographic changes seen in patients with toxic and non-toxic goiter do not seem to be related to (a) changes in heart size, (b) heart rate, (c) postoperative improvement in thyrotoxicosis, (d) duration or severity of thyrotoxicosis, (e) age, (f) sex, (g) the state of cardiac compensation, (h) the presence of substernal goiter, (i) operative injuries to the recurrent laryngeal nerve, (j) the type of anesthesia employed or (k) the severity of the postoperative reaction.

#### BIBLIOGRAPHY

1. Margolies, A., Rose, E., and Wood, F. C., The heart in thyroid disease. I. The effect of thyroidectomy on the orthodiagram. *J. Clin. Invest.*, 1935, **14**, 483.
2. Hamburger, W. W., Lev, M. W., Priest, W. S., and Howard, H. C., The heart in thyroid disease. I. Changes in the T wave of the human electrocardiogram following iodine medication and thyroidectomy. *Arch. Int. Med.*, 1929, **43**, 35.
3. Krumbhaar, E. B., Electrocardiographic observations in toxic goiter. *Am. J. M. Sc.*, 1918, **155**, 175.
4. Jonás, V., and Wichterlová, M., Étude Électrocardiographique chez les Hyperthyroïdiens. *Rev. franc. d'endocrinol.*, 1932, **10**, 307.
5. Coelho, E., Les Troubles Cardiaques dans la Maladie et de Basedow et le Myxoedème—Étude Électrocardiographique. *Ann. de méd.*, 1931, **30**, 272.
6. Goodall, J. S., and Rogers, L., The electrical and histological manifestations of thyrotoxic myocarditis. *Brit. M. J.*, 1927, **1**, 1141.
7. Gossels, C., Klinischer Beitrag zur Frage des Elektrokardiogramms bei Schilddrüsenveränderungen. *Deutsches Arch. f. klin. Med.*, 1932, **173**, 597.
8. Willius, F. A., Boothby, W. M., and Wilson, L. B., The heart in exophthalmic goiter and adenoma with hyperthyroidism, *M. Clin. North America*, 1923, **7**, 189.
9. Smith, F. J., and Colvin, L. T., Certain cardiovascular features of hyperthyroidism. *Ann. Clin. Med.*, 1927, **5**, 616.
10. White, P. D., and Aub, J. C., The electrocardiogram in thyroid disease. *Arch. Int. Med.*, 1918, **22**, 766.
11. Don, C. S. D., and Langley, G. J., Some aspects of the electrocardiogram in toxic goitre. *Quart. J. Med.*, 1932, **1** (n.s.), 9.
12. Dameshek, W. E., The heart in hyperthyroidism. *Boston M. and S. J.*, 1924, **190**, 487.
13. Leidner, J., Über das Elektrokardiogramm bei Morbus Basedowi und seine Beeinflussung durch kühle Moorbäder. *Ztschr. f. Balneologie*, 1918, **11**, 119. (Quoted by Dameshek.)
14. McGuire, J., and Foulger, M., The influence of thyroid extract and hyperthyroidism on the electrocardiogram, with special reference to the T waves. *Am. Heart J.*, 1932, **8**, 114.
15. White, P. D., *Heart Disease*. MacMillan Co., New York, 1931, p. 256.
16. Parade, G. W., and Haas, M., Was leistet die Operative Behandlung des Morbus Basedow. *Munch. med. Wchnschr.*, 1931, **78**, 228.
17. Kämmerer, H., and Obermaier, A., Elektrokardiographische Untersuchungen an Thyreotoxikosen vor und nach der Operation mit besonderer Berücksichtigung der T-Zacke. *Deutsches Arch. f. klin. Med.*, 1932, **174**, 117.
18. Unpublished observations: F. C. Wood.